

# A feasible approach for His bundle pacing using a novel mapping system in patients receiving pacemaker therapy



Wei Hua, MD, FHRS, Yi-ran Hu, MD, Min Gu, MD, Chi Cai, MD, Xu-hua Chen, MD, Hong-xia Niu, MD, Shu Zhang, MD, FHRS

*From the State Key Laboratory of Cardiovascular Disease, Arrhythmia Center, Fuwai Hospital, National Center for Cardiovascular Diseases, Chinese Academy of Medical Sciences and Peking Union Medical College, Beijing, China.*

## Introduction

Permanent His bundle pacing (HBP) has emerged as a new, promising approach to deliver physiological pacing, maintaining long-term ventricular synchrony and left ventricular performance unlike conventional right ventricular apical pacing, for treatment of patients with symptomatic bradycardia.<sup>1</sup> Traditionally HBP is performed under fluoroscopic guidance, which entails significant exposure to radiation. A novel nonfluoroscopic three-dimensional (3D) cardiac imaging and navigation system, the KODEX-EPD system (EPD Solutions, Philips, Best, The Netherlands), offers an efficient way of guidance via high-definition (HD) computed tomography-like cardiac imaging and visualization of the His bundle region. It allows precision navigation with spatial resolution of 0.27 mm, HD anatomical imaging, tissue imaging, and physical property imaging. Less complicated than other 3D mapping systems, this electroanatomic mapping system was automatic without an electrophysiology (EP) catheter. We present a case of a 76-year-old man with sick sinus syndrome, in whom the KODEX-EPD system was successfully used to guide an implant of a dual-chamber pacemaker with HBP.

## Case report

A 76-year-old man with symptomatic sick sinus syndrome was referred for permanent pacemaker implantation. Using the KODEX-EPD system for HBP was considered and an informed consent was signed by the patient prior to the operation.

The procedure of pacemaker implantation was performed in a cardiac catheterization laboratory. Under local

---

**KEYWORDS** Cardiac imaging and navigation system; KODEX-EPD system; Nonfluoroscopic three-dimensional (3D) cardiac imaging; Permanent His bundle pacing; Physiological pacing (Heart Rhythm Case Reports 2019;5:433–435)

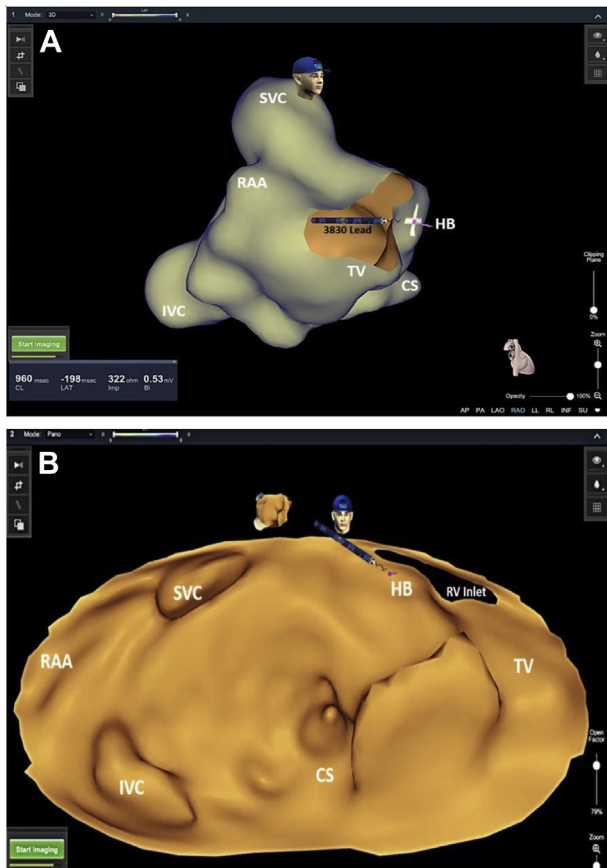
---

**Address reprint requests and correspondence:** Dr Shu Zhang, Fuwai Hospital, No 167 North Lishi Rd, Xicheng District, Beijing, China. E-mail address: zsfuwai@vip.163.com.

## KEY TEACHING POINTS

- The KODEX-EPD cardiac imaging and navigation system (EPD Solutions, Philips, Best, The Netherlands) is a novel noncontact type of mapping system.
- Without an electrophysiological catheter, this electromagnetic-based imaging system allows real-time visualization of intracardiac catheters as well as a display of cardiac images in a number of different formats.
- The KODEX-EPD system provides an alternative, extremely lower fluoroscopic approach for His bundle pacing.

anesthesia, the left subclavian vein was punctured and a C315 His sheath (Medtronic, Minneapolis, MN) was advanced into the right atrium (RA) over a guidewire. Thereafter, the 3830 His lead (Medtronic, Minneapolis, MN) was advanced to the tip of the sheath. With the distal tip and ring tip of the lead extended out of the sheath appropriately, bipolar sites at the proximal end of the lead were connected to the KODEX-EPD system. Based on the radio wave transmitting from the lead, the anatomy of the superior vena cava, inferior vena cava, RA appendage, and coronary sinus was imaged by moving the sheath up and down without fluoroscopy (Figure 1). Based on the acquired 3D image depicting the particular cardiac anatomical landmarks, the His bundle electrograms were recorded and then the lead was screwed in the region of the His bundle using 4–5 clockwise rotations (Figure 2). Similarly, the 4574 lead (Medtronic, Minneapolis, MN) was placed in the RA appendage imaged by the system without fluoroscopy. The optimal position of the implanted leads was confirmed by the minimal fluoroscopy and therefore they were connected to a permanent pacemaker



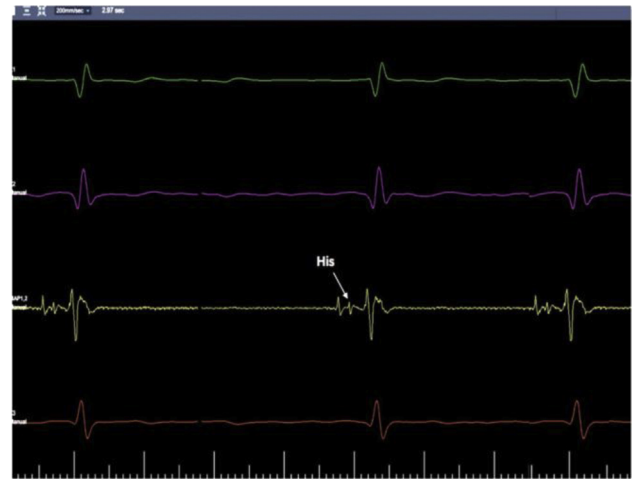**Figure 1** Right atrial anatomy and final permanent His bundle lead position imaged by KODEX-EPD (EPD Solutions, Philips, Best, The Netherlands). **A:** Right anterior oblique view. **B:** Panoramic view. All anatomical landmarks were correctly depicted and the His bundle position was tagged. CS = coronary sinus; HB = His-bundle; IVC = inferior vena cava; RAA = right atrial appendage; RV = right ventricle; SVC = superior vena cava; TV = tricuspid valve.

(Figure 3). The final HBP had a capture threshold of 1.5 V at a pulse width of 1.0 ms, with an R wave of 4.6 mV (Supplemental Figure 1).

At 1-month follow-up, the pacing threshold was still 1.5 at a pulse width of 1.0 ms, with an R wave of 3.8 mV.

## Discussion

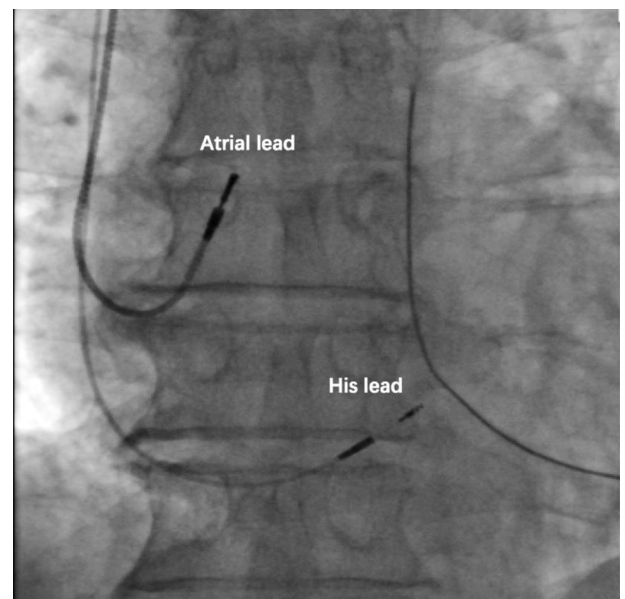
The KODEX-EPD cardiac imaging and navigation system is a novel catheter-based cardiac EP system. Acquiring the electromagnetic information through all conductors in touch with the patient's body, the system allows extremely accurate real-time localization and visualization of any intracardiac catheter, as well as acquisition and display of HD computed tomography-like cardiac images, either as a conservative reconstructed 3D image or as a flattened 3D panoramic view (PANO). Furthermore, the KODEX-EPD system can operate with any standard affordable sensorless EP catheter as well as pacing leads. Only a few hospitals have used this advanced system so far, and the cumulative clinical experience is limited to the field of therapeutic guided catheter



**Figure 2** Intracardiac signals of His potential obtained from the KODEX EPD system (EPD Solutions, Philips, Best, The Netherlands).

ablation. To the best of our knowledge, this is the first report of the use of the KODEX-EPD system to guide HBP and implant a pacemaker.

Utilization of nonfluoroscopic 3D cardiac electroanatomical mapping and navigation has become the standard of care in catheter-based arrhythmia management.<sup>2</sup> These breakthrough systems can effectively guide even the most challenging complex EP procedures and reduce radiation exposure.<sup>3,4</sup> Nevertheless, device implantations, including HBP procedures, are still mostly carried out under fluoroscopic guidance. To date, usage of a 3D mapping systems to guide HBP was reported in only 2 case reports. Ringwala and colleagues<sup>5</sup> conducted the first 3D mapping system (NavX; St. Jude Medical, St. Paul, MN)-guided permanent His bundle lead implantation, followed by



**Figure 3** Fluoroscopic imaging of the pacing leads with the atrial lead and the His lead.

atrioventricular node ablation, in a 92-year-old man with respiratory distress and rapid atrial fibrillation. Another case was reported by Cay and colleagues,<sup>6</sup> who used the same 3D mapping system to guide HBP in a 63-year-old man with symptomatic atrioventricular block. In both cases the procedure was composed of 2 stages. In the first stage, a detailed 3D electroanatomical mapping of right-heart structures with the His cloud was obtained using EP catheters (a 4-mm ablation catheter and a standard steerable decapolar catheter, respectively, both introduced via the femoral vein). In the second stage, the His bundle region was reached using specialized dedicated tools and the His bundle lead was placed. KODEX-EPD-guided HBP does not require any change in the customary procedure flow. Instead of first using an EP catheter to acquire an RA map and localize the His bundle region, the pacing lead itself can be used to image and guide the whole procedure in full. We expect that KODEX-EPD-guided HBP might be a substantial technological enhancement that warrants further assessment and might facilitate widespread adaptation of HBP in the future.

## Conclusion

A novel nonfluoroscopic 3D cardiac imaging and navigation system, the KODEX-EPD system provides a feasible approach for HBP in patients receiving pacemaker therapy.

## Acknowledgments

The authors thank Prof Shlomo Ben-Haim for assistance with the manuscript.

## Appendix Supplementary data

Supplementary data associated with this article can be found in the online version at <https://doi.org/10.1016/j.hrcr.2019.06.003>.

## References

1. Vijayaraman P, Chung MK, Dandamudi G, et al. His bundle pacing. *J Am Coll Cardiol* 2018;72:927–947.
2. Lemery R. Interventional electrophysiology at the crossroads: cardiac mapping, ablation and pacing without fluoroscopy. *J Cardiovasc Electrophysiol* 2012; 23:1087–1091.
3. Ventura R, Rostock T, Klemm HU, et al. Catheter ablation of common-type atrial flutter guided by three-dimensional right atrial geometry reconstruction and catheter tracking using cutaneous patches: a randomized prospective study. *J Cardiovasc Electrophysiol* 2004;15:1157–1161.
4. Wittkampf FH, Wever EF, Derksen R, et al. Localisa: new technique for real-time 3-dimensional localization of regular intracardiac electrodes. *Circulation* 1999; 99:1312–1317.
5. Ringwala S, Knight BP, Verma N. Permanent His bundle pacing at the time of atrioventricular node ablation: A 3-dimensional mapping approach. *HeartRhythm Case Rep* 2017;3:323–325.
6. Cay S, Ozcan F, Ozeke O, Aras D, Topaloglu S. 3-Dimensional electroanatomic mapping guided selective His bundle pacing. *JACC Clin Electrophysiol* 2018; 4:415–417.