

Spontaneous complete regression of large uterine fibroid after the second vaginal delivery

Case report

Myounghwan Kim, MD*

Abstract

Rationale: Fibroids are common, hormone-dependent, benign uterine tumors. It is estimated that they occur in 20% to 40% of women during their reproductive years. The prevalence of fibroids among pregnant women is 10.7%. Most fibroids do not increase in size during pregnancy. Pregnancy has a variable and unpredictable effect on fibroid growth. The influence of pregnancy on uterine fibroid size still remains unclear. Researchers evaluating fibroids have reported an inverse association between parity and fibroids, suggestive of a protective effect. Pregnancies that occur while fibroids are small would be protective; whereas pregnancies occurring before fibroid development or after the tumors reach some critical size would not be protective. Herein, the case of a woman with a large uterine fibroid that was spontaneously regressed after a second successful vaginal delivery is reported. To our knowledge, the complete regression of a large fibroid after delivery has not yet been reported.

Patient concerns: A 35-year-old gravida 1 para 0 woman was referred from a private clinic with a history of pelvic mass, adnexal mass and 19 weeks of amenorrhea.

Diagnosis: Ultrasonographic examination indicated a solid mass at the uterine fundus (12.1 × 8.3 cm) suggestive of a uterine fibroid and complex echogenic mass at the right adnexa (7.7 × 6.0 cm).

Interventions: Usually, cesarean sections are performed after myomectomy due to the risk for rupture when attempting vaginal delivery. So, the patient decided against the myomectomy, because she did not have any myoma-related symptoms after the first vaginal delivery and wanted to have more children via vaginal birth.

Outcomes: Six months postpartum she becomes pregnant again. The patient had another vaginal birth. Four years after second delivery, the large myoma completely regressed.

Lessons: Fibroids can regress with postpartum involution. Even though fibroid-related pregnancy complication is 10% to 30%, prophylactic myomectomy is not recommended. In addition, given the protective effect of parity, conception and delivery are reasonable option and could allow treatment to be deferred in women planning a pregnancy.

Keywords: delivery, pregnancy, regression of uterine fibroid, vaginal birth

1. Introduction

Fibroids are common, hormone-dependent, benign uterine tumors. It is estimated that they occur in 20% to 40% of women during their reproductive years.^[1] They can cause significant morbidity and symptoms mostly depend on their size and position in the uterine cavity.^[2] Symptoms include pelvic pain, infertility, pregnancy complications, and excessive uterine bleeding that can lead to anemia. Obstetric complications

related to fibroids include early and late miscarriage, preterm birth, fetal malpresentation, placental abruption, post-partum hemorrhage, and a higher risk of cesarean delivery.^[3,4] The complication rate of fibroid-related pregnancies is 10% to 30%.^[4] Although fibroids grow in reproductive years, up to one-fifth of fibroids in premenopausal women may spontaneously regress.^[5] The prevalence of fibroids among pregnant women is 10.7%^[3] and differs with ethnicity: 18% in African Americans, 8% in whites, and 10% in Hispanics based on first-trimester sonography.^[6]

Although most fibroids do not increase in size during pregnancy, pregnancy can have a variable and unpredictable effect on fibroid growth. This is likely dependent on individual differences in fibroid gene expression, circulating growth factors, and fibroid-localized receptors.^[7–9] A recent systematic review concluded that fibroids do appear to have a linear growth pattern in the first trimester of pregnancy. However, the growth patterns in later gestations remain contentious with inconsistent evidence.^[10] It suggests that in that study by Vitagliano et al,^[11] a definite conclusion regarding the relationship between uterine fibroids size and the pregnancy could not be arrived at due to the poor evidence of data regarding the overall modifications of such tumors during pregnancy and puerperium. Other studies on fibroids have reported an inverse association between parity and

Editor: N/A.

The authors have no conflicts of interest to disclose.

Department of Obstetrics and Gynecology, Sanggye Paik Hospital, Inje University, School of Medicine, Seoul, Korea.

* Correspondence: Myounghwan Kim, 1342 Dongil-ro, Nowon-gu, Seoul 139-707, Korea (e-mail: myankim@paik.ac.kr).

Copyright © 2018 the Author(s). Published by Wolters Kluwer Health, Inc. This is an open access article distributed under the terms of the Creative Commons Attribution-Non Commercial-No Derivatives License 4.0 (CCBY-NC-ND), where it is permissible to download and share the work provided it is properly cited. The work cannot be changed in any way or used commercially without permission from the journal.

Medicine (2018) 97:45(e13092)

Received: 19 June 2018 / Accepted: 11 October 2018

<http://dx.doi.org/10.1097/MD.00000000000013092>

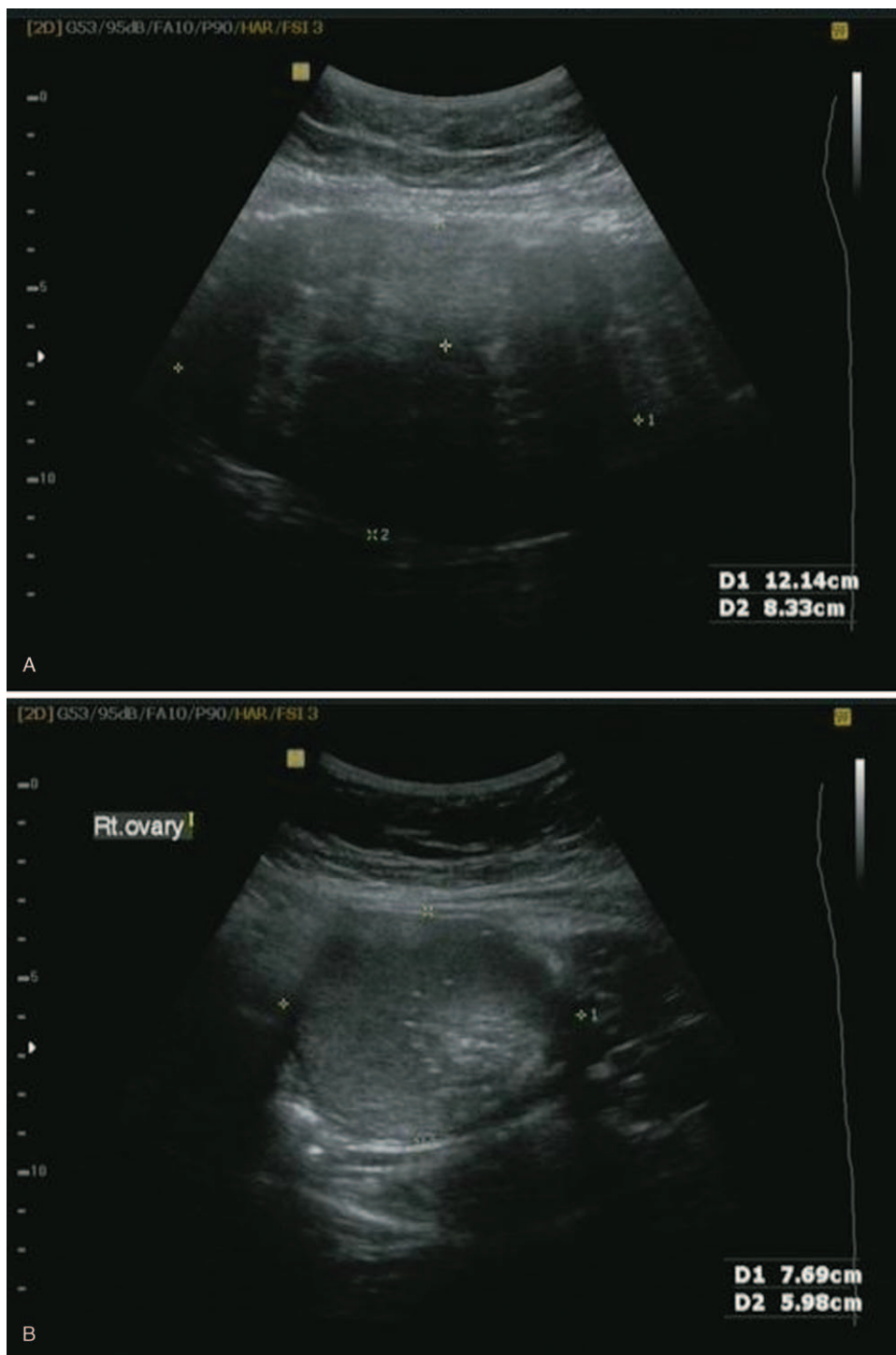


Figure 1. The ultrasound scan during first pregnancy showing a solid mass (12.1 × 8.3 cm) at the uterine fundus (A), and complex echogenic mass (7.7 × 6.0 cm) at the right adnexa (B) at 19 weeks of pregnancy. (C) Showing change of internal echo of uterine fibroid, suggestive degeneration at 34 weeks of pregnancy.

fibroids, suggesting that pregnancy may prevent fibroid growth.^[12–14] Specifically, a pregnancy that occurs while fibroids are small would be protective, whereas pregnancies occurring before fibroid development or after the tumors reach a certain critical size would not be protective.^[15] Herein, the case of a woman with a large uterine fibroid that was spontaneously regressed after a second successful vaginal delivery is reported. To our knowledge, the complete regression of a large fibroid after delivery has not yet been reported.

This study was approved by the Institutional Review Board of the Sanggye Paik hospital. Informed written consent was obtained from the patient for publication of this case report and accompanying images.

2. Case report

A 35-year-old gravida 1 para 0 woman was referred from a private clinic with a history of pelvic masses, adnexal mass, and

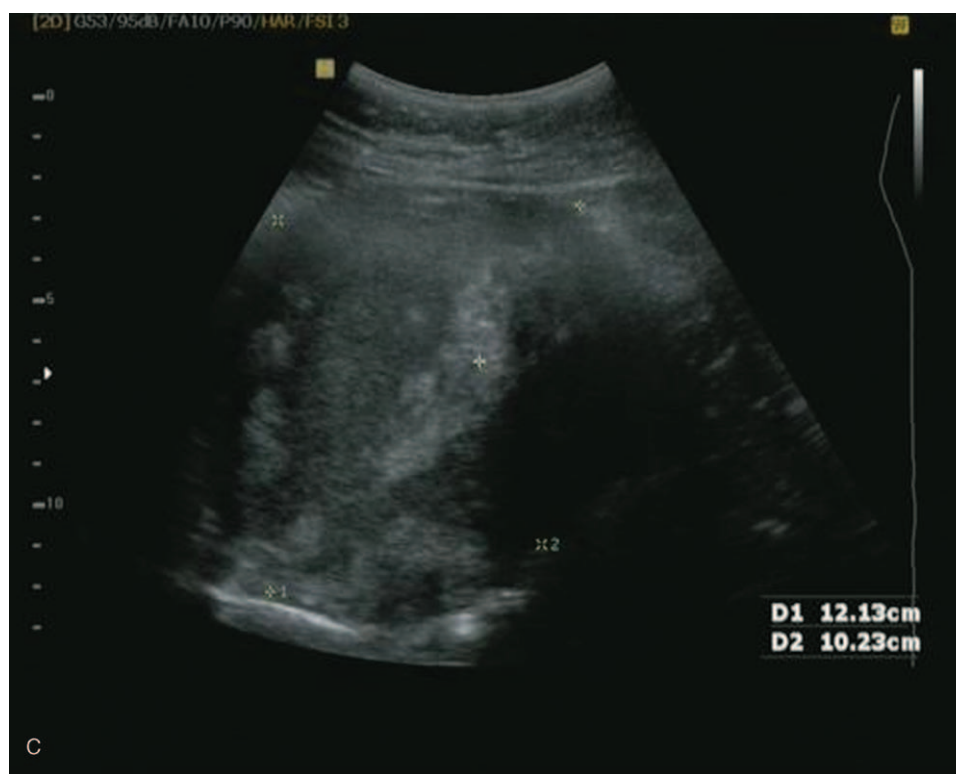

Figure 1. Continued.

19 weeks of amenorrhea. Three months before presentation, when confirming the pregnancy, she was informed that a large pelvic mass and adnexal mass were detected on ultrasonography. The examination indicated a solid mass at the uterine fundus (12.1×8.3 cm; Fig. 1A) and complex echogenic mass at the right adnexa (7.7×6.0 cm; Fig. 1B). The provisional diagnosis was uterine fibroid and mature cystic teratoma of the ovary. We decided to treat these postpartum. Uterine fibroid and adnexal tumor remained stable during antenatal care except for a change in the internal echo of the uterine fibroid at 34 weeks, suggestive of degeneration (Fig. 1C). She was diagnosed with oligohydramnios and fetal intrauterine growth restriction at 38 weeks of gestation. Labor was induced. The patient delivered a healthy male infant (2135 g) at 38 2/7 weeks of gestation via vaginal birth. Uterine fibroid size decreased to 8.7×5.7 cm 4 months postpartum and the adnexal mass remained stable. She decided against the myomectomy at this time, because she did not have any myoma-related symptoms and wanted to have more children via vaginal deliveries. Therefore, we only removed the adnexal mass. A large myoma at the fundus and right ovarian tumor was noted when the entering abdominal cavity via laparoscopy (Fig. 2). Laparoscopic right ovarian cystectomy was performed, and the myoma was left for future vaginal delivery because a protective effect of parity on the myoma was also expected. The right ovarian tumor was pathologically diagnosed as a mature cystic teratoma of the ovary. The patient was discharged from the hospital on the third day postoperatively without any complications. Two months later, she visited the hospital to confirm another pregnancy. Ultrasonographic examination indicated a solid mass at the uterine fundus measuring 9.1×5.0 cm (Fig. 3A), and a single live fetus with a crown-rump length corresponding to that of a fetus with a gestational age of 6 weeks and 1 day. The

patient underwent routine antenatal care. The uterine myoma remained stable during antenatal care. Finally, the patient delivered a healthy male infant (3430 g) at 37 6/7 weeks of gestation via vaginal birth. The myoma size decreased to 6.5×4.5 cm 6 weeks postpartum (Fig. 3B). The patient did not have any symptoms related to the myoma, and follow-up was scheduled for every 6 months. Four years after the second delivery, the myoma completely regressed (Fig. 3C). The myoma did not grow again, according to an annual routine gynecologic examination 2 years after complete regression.

3. Discussion

Uterine leiomyomata, or fibroids, are benign tumors with an estimated prevalence of at least 15% in white women and 40% in black women by age 35.^[6] While fibroids grow during reproductive years, up to one-fifth of may spontaneously regress in premenopausal women.^[5] Fibroid regression had been assumed to occur only after menopause secondary to the reduction in circulating ovarian steroids; in fact, a study showed that there is a dramatic reduction in clinical diagnoses after menopause.^[15] A minority of fibroids in that study demonstrated evidence of spontaneous regression, which is an unexpected finding in premenopausal women. Authors have speculated that individual fibroids may have regressed secondarily to local effects, such as a change in vascularity.^[5] Shimada et al^[16] also observed that 19 tumors from 14 women showed spontaneous shrinkage. Those tumors were further analyzed using magnetic resonance imaging and none had gadolinium enhancement, which is consistent with loss of arterial blood flow and necrosis.^[15,16] Peddada et al^[17] demonstrated that fibroids in 1 patient often have different growth rates despite having a similar

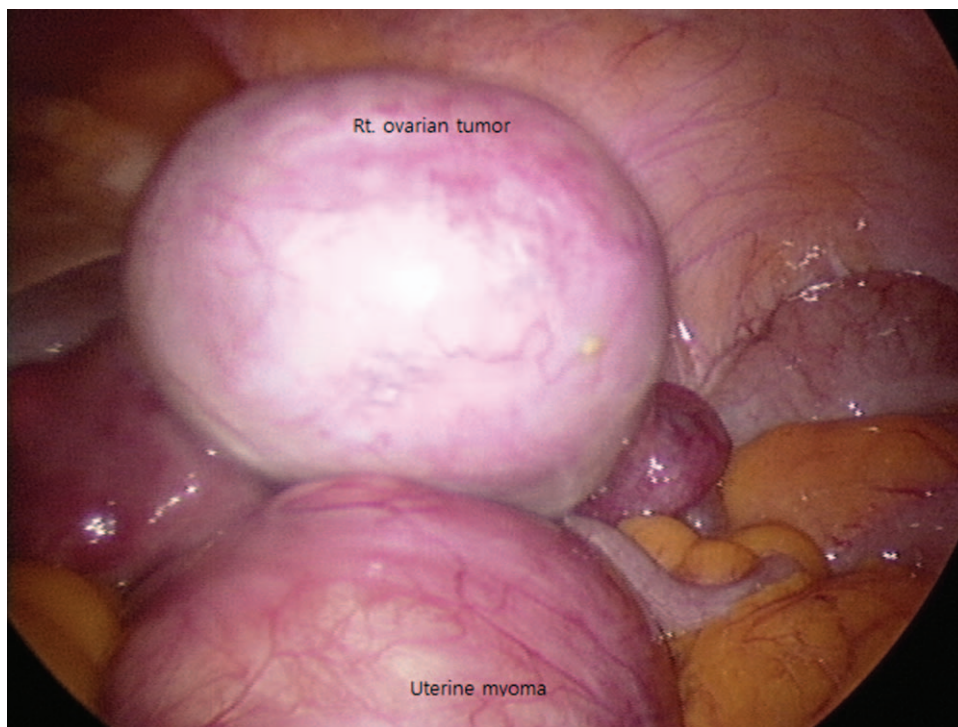


Figure 2. Laparoscopic view for right ovarian cystectomy between first and second pregnancy: Right ovarian tumor and myoma at the uterine fundus.

hormonal milieu. This is compatible with the fact that each myoma arises from a single clone. They also observed spontaneous regression in a small percentage of fibroids, which is surprising in premenopausal women.

The influence of pregnancy on uterine fibroid size remains unclear. It was commonly thought that myomas often became enlarged during pregnancy due to hormonal stimulation. However, data now suggest that most fibroids do not increase in size during pregnancy. However, pregnancy has a variable and unpredictable effect on fibroid growth, which is likely dependent on individual differences in fibroid gene expression, circulating growth factors, and fibroid-localized receptors.^[7-9] A recent systematic review concluded that fibroids do appear to have a linear growth pattern in the first trimester of pregnancy. However, the growth patterns in later gestations remain contentious with inconsistent evidence.^[10] It suggests that in that study by Vitagliano et al,^[11] a definite conclusion regarding the relationship between uterine fibroids size and the pregnancy could not be arrived at due to the poor evidence of data regarding the overall modifications of such tumors during pregnancy and puerperium. Studies on pregnancy-related fibroids report an inverse association between parity and fibroids, suggestive of a protective effect.^[12-14] Higher parity is associated with reduced fibroid risk in most epidemiologic studies. Fibroid risk is also lower among women with more recent pregnancies than with remote pregnancies.^[18] A pregnancy that occurs while fibroids are small may be protective, whereas pregnancies occurring before fibroid development or after the tumors reach some critical size would not be protective.^[15] A first pregnancy late in life may also have limited effect because some tumors could have become too large to be regressed by remodeling.^[15] In their study, Peddada et al^[17] observed that the largest initial fibroid volume that showed maximal reduction (88.5%) was 39.3 cm³. Its

diameter was approximately 4.3 cm. Fibroid regression was common between early gestation and 3 to 6 months postpartum.^[13] In this case a large uterine fibroid (12.1 × 8.3) was detected in 35-year-old gravida 1 para 0 woman early in her first pregnancy. Fibroid size is much larger than that reported in Peddada et al study. Fibroid size decreased to 3.6 × 2.9 cm 3 years after the second delivery and was no longer there 4 years later. To our knowledge, the complete regression of a large fibroid after delivery such as seen in this case has not yet been reported. Although fibroid regression is common 3 to 6 months postpartum, in our case, fibroids continued to decrease in size 4 years postpartum. The protective effect of parity presumably lasted longer than 3 to 6 months postpartum or spontaneous regression was combined in this case.

The complex mechanical and cellular mechanisms related to birth and uterine involution may play a role in fibroid elimination and shrinking. The timing of fibroid regression (during pregnancy, at birth, or postpartum) and the mechanism of action is unknown. Burbank suggested that birth and placental delivery, with its associated hypoxia, would induce regression.^[19] Baird et al^[15] hypothesized that the protective effect of pregnancy on fibroids is associated with postpartum uterine involution. Studies in rats show high levels of apoptosis during involution and proliferation.^[20] These findings indicate that the involution process is not a simple decreasing in size of existing tissue, but rather a remodeling process.^[15]

In their study, Laughlin et al reported that the reduction in diameter associated with submucous fibroids was greater (1.8 cm change) than the reduction associated with intramural (0.2 cm), subserous (0.6 cm), or pedunculated (0.5 cm) fibroids.^[12] Fibroids in the lower segment were associated with a greater change in fibroid diameter (1.4 cm) than fibroids in the corpus (0.5 cm) or fundus (0.4 cm). Submucous fibroids had a higher likelihood of

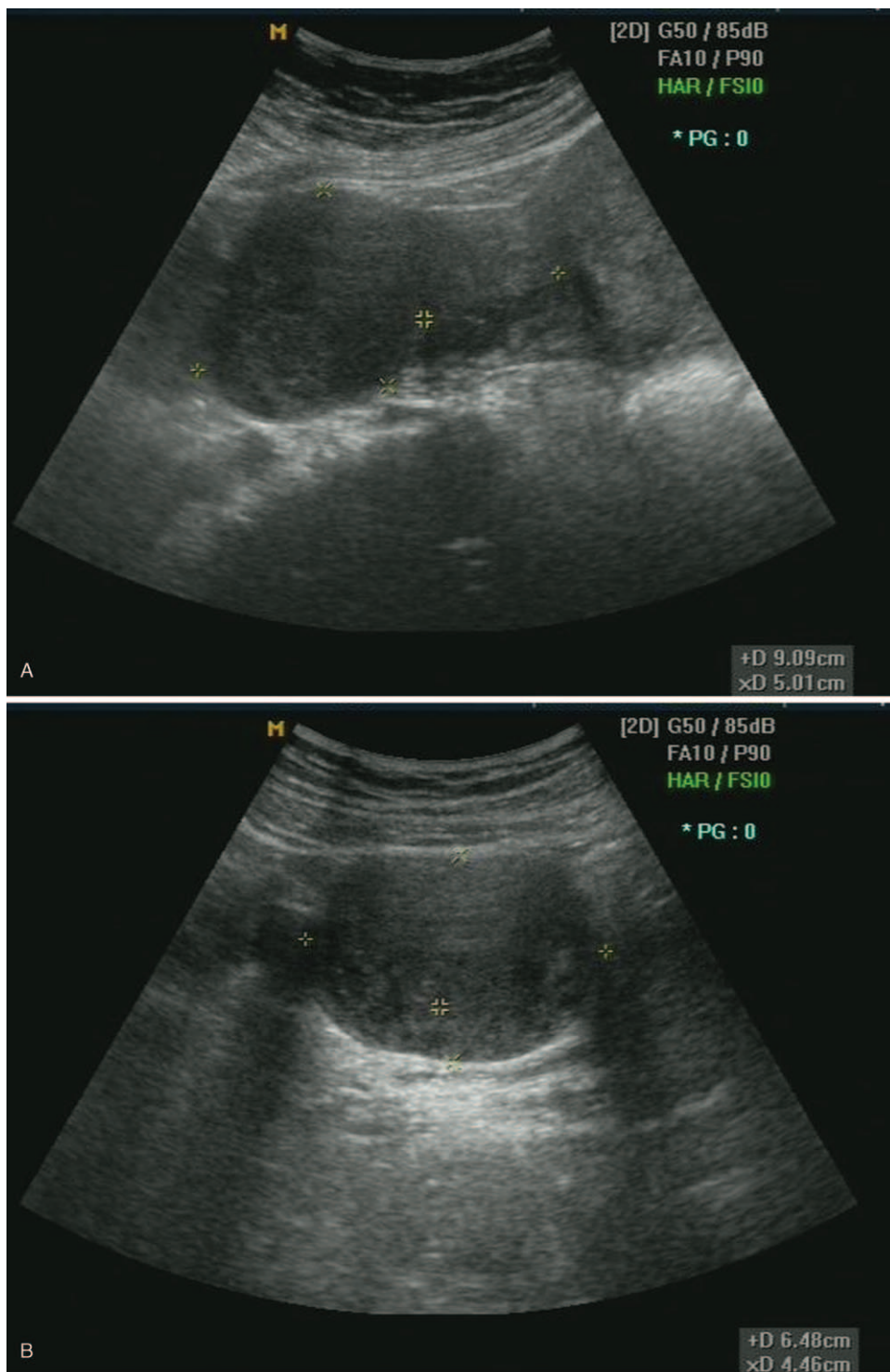


Figure 3. The ultrasound scan during second pregnancy. (A) a decreased myoma (9.1 × 5.0 cm) at the uterine fundus at 6 weeks of pregnancy. (B) myoma size decreased to 6.5 × 4.5 cm (C) myoma completely regressed 4 years later after second delivery.

regressing than the most common type (subserosal).^[12] Subserosal myoma located in the fundus was regressed in this case.

In the Negish study, uterine size was smaller after vaginal delivery than after cesarean section in the puerperium.^[21] Laughlin et al anticipated differences in fibroid regression between those with cesarean and those with vaginal delivery.

Marginally fewer fibroid regression was shown in those with cesarean deliveries compared with those having vaginal deliveries (68% vs 74%), but this difference is not significant.^[12]

Miscarriages also influence fibroid regression. Compared with women who had live births, these women were significantly less likely to exhibit fibroid regression. Miscarriages before 8 weeks had less fibroid regression than miscarriages after 8 weeks when

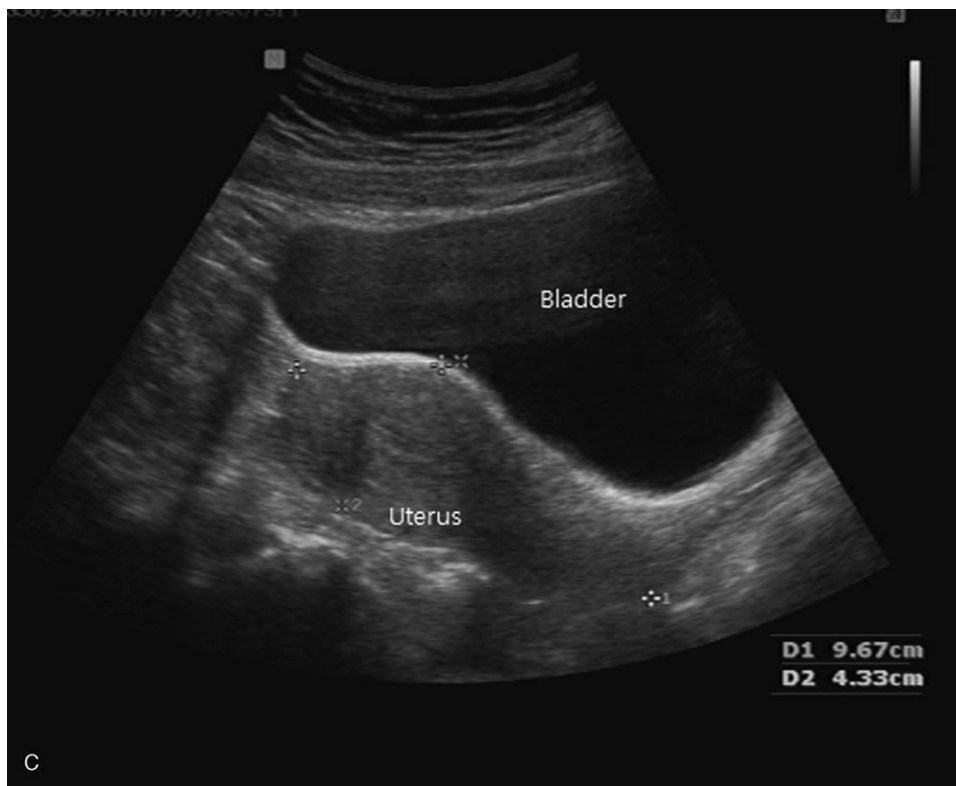


Figure 3. Continued.

compared with live births.^[13] The longer the duration of pregnancy is, the more regressed fibroids are.

Breast feeding and menses delay reduce ovarian steroidogenesis. It can be speculated that breast feeding and menses delay may eliminate fibroids, but are not associated with fibroid regression.^[13] In this case, the patient did not breastfeed her baby.

4. Conclusion

Pregnancy has a variable, and unpredictable, effect on fibroid growth. Some fibroids grow and some fibroids decrease in size during pregnancy. Many fibroids regress with pregnancy or postpartum involution. Although pregnancies after the tumors reach some critical size would not be protective,^[15] a large fibroid was regressed after the second delivery in this case. If a woman diagnosed with fibroids, interventions should be planned only after a period of observation to establish tumor behavior in the individual case. For an asymptomatic woman diagnosed with fibroids who desires fertility in the near future, conception may be attempted before treating fibroids if fibroids are not the cause of infertility, even if fibroids are large. Even though fibroid-related pregnancy complication is 10% to 30%,^[4] prophylactic myomectomy is not recommended. In addition, given the protective effect of parity, conception and delivery are reasonable option and could allow treatment to be deferred in women who want to get pregnant.

Author contributions

Conceptualization: Myounghwan Kim.

Data curation: Myounghwan Kim.

Formal analysis: Myounghwan Kim.

Investigation: Myounghwan Kim.

Methodology: Myounghwan Kim.

Project administration: Myounghwan Kim.

Resources: Myounghwan Kim.

Software: Myounghwan Kim.

Supervision: Myounghwan Kim.

Validation: Myounghwan Kim.

Visualization: Myounghwan Kim.

Writing – original draft: Myounghwan Kim.

Writing – review & editing: Myounghwan Kim.

References

- [1] Ryan GL, Syrop CH, Van Voorhis BJ. Role, epidemiology, and natural history of benign uterine mass lesions. *Clin Obstet Gynecol* 2005;48:312–24.
- [2] DeWaay DJ, Syrop CH, Nygaard IE, et al. Natural history of uterine polyps and leiomyomata. *Obstet Gynecol* 2002;100:3–7.
- [3] Vitale SG, Tropea A, Rossetti D, et al. Management of uterine leiomyomas in pregnancy: review of literature. *Updates Surg* 2013;65:179–82.
- [4] Milazzo GN, Catalano A, Badia V, et al. Myoma and myomectomy: poor evidence concern in pregnancy. *J Obstet Gynaecol Res* 2017;43:1789–804.
- [5] Ghosh S, Naftalin J, Imrie R, et al. Natural history of uterine fibroids: a radiological perspective. *Curr Obstet Gynecol Rep* 2018;7:117–21.
- [6] Laughlin S, Baird D, Savitz D, et al. Prevalence of uterine leiomyomas in the first trimester of pregnancy: an ultrasound-screening study. *Obstet Gynecol* 2009;113:630–5.
- [7] Muram D, Gillieson M, Walters JH. Myomas of the uterus in pregnancy: ultrasonographic follow-up. *Am J Obstet Gynecol* 1980;138:16–9.
- [8] Rosati P, Exacoustos C, Mancuso S. Longitudinal evaluation of uterine myoma growth during pregnancy. A sonographic study. *J Ultrasound Med* 1992;11:511–5.

- [9] De Vivo A, Mancuso A, Giacobbe A, et al. Uterine myomas during pregnancy: a longitudinal sonographic study. *Ultrasound Obstet Gynecol* 2011;37:361–5.
- [10] Laganà AS, Vergara D, Favilli A, et al. Epigenetic and genetic landscape of uterine leiomyomas: a current view over a common gynecological disease. *Arch Gynecol Obstet* 2017;296:855–67.
- [11] Vitagliano A, Noventa M, Di Spiezio , et al. Uterine fibroid size modifications during pregnancy and puerperium: evidence from the first systematic review of literature. *Arch Gynecol Obstet* 2018;297:823–35.
- [12] Laughlin S.K., Herring AH, Savitz DA, et al. Pregnancy-related fibroid reduction. *Fertil Steril* 2010;94:2421–3.
- [13] Laughlin SK, Hartmann KE, Baird DD. Postpartum factors and natural fibroid regression. *Am J Obstet Gynecol* 2011;204:496.e1-6.
- [14] Hammoud AO, Asaad R, Berman J, et al. Volume change of uterine myomas during pregnancy: do myomas really grow. *J Minim Invasive Gynecol* 2006;13:386–90.
- [15] Baird DD, Dunson DB. Why is parity protective for uterine fibroids. *Epidemiology* 2003;14:247–50.
- [16] Shimada K, Ohashi I, Kasahara I, et al. Triple-phase dynamic MRI of intratumoral vessel density and hyalinization grade in uterine leiomyomas. *AJR* 2008;182:1043–50.
- [17] Peddada SD, Laughlin SK, Miner K, et al. Growth of uterine leiomyomata among premenopausal black and white women. *Proc Natl Acad Sci USA* 2008;105:19887–92.
- [18] Wise LA, Palmer JR, Harlow BL, et al. Reproductive factors, hormonal contraception, and risk of uterine leiomyomata in African-American women: a prospective study. *Am J Epidemiol* 2004;159:113–23.
- [19] Burbank F. Childbirth and myoma treatment by uterine artery occlusion: do they share a common biology. *J Am Assoc Gynecol Laparosc* 2004;11:138–52.
- [20] Takamota N, Leppert PC, Yu SY. Cell death and proliferation and its relation to collagen degradation in uterine involution of rat. *Connective Tissue Res* 1998;37:163–75.
- [21] Negishi H, Kishida T, Yamada H, et al. Changes in uterine size after vaginal delivery and cesarean section determined by vaginal sonography in the puerperium. *Arch Gynecol Obstet* 1999;263:13–6.