

Multifocal Renal Carcinoid Tumor Arising in Horseshoe Kidney with Metastases to the Thyroid

Matthew S. Hartman, Pardeep Mittal, Melinda Lewis

Primary renal carcinoid tumor is a rare tumor of the kidney. Less than 40 cases of primary and metastatic renal carcinoids have been reported. There is a strong association of renal carcinoid tumors with horseshoe kidneys [1, 2]. The radiographic appearance is non-specific and overlaps that of renal cell carcinoma. Histopathologic differentiation between these two entities is essential because the treatment and prognosis are entirely different. We report a unique case of multifocal carcinoid tumor within a horseshoe kidney with metastases to the thyroid gland. It has been postulated that the renal carcinoid horseshoe subtype carried a more favorable prognosis; however, our case with multifocal involvement and distant metastases suggests the possibility for a more aggressive course.

Case Report

A 32-year-old male sought treatment for abdominal pain in an emergency room in December 2002. Contrast enhanced CT revealed a horseshoe kidney with bilateral enhancing, partly cystic renal masses. The largest enhancing mass, within the right kidney, measured 11 x 7 cm. The patient was lost to follow up for two years without a tissue diagnosis.

He presented two years later to a different emergency room with abdominal and neck pain. Physical examination revealed thyromegaly and a palpable mass in the mid abdomen. Computed Tomography (CT) of the abdomen revealed innumerable enhancing lesions of variable size within both kidneys and within the isthmus. The largest lesion within the right renal moiety measured 14.5 x 10.5 cm (Fig. 1A). There was mild bilateral hydronephrosis thought to be secondary to the renal masses. He was also noted to have a 2.5 x 1.9 enhancing left adrenal lesion (Fig.

1B). CT revealed no hepatic lesions. CT scan through the thorax revealed multiple 1-2 cm low density nodules scattered throughout both lobes of the thyroid gland, which were confirmed on ultrasound (Fig. 1C), and a 1 cm low density lesion along the left lateral pleural surface. Magnetic resonance imaging (MRI) of the brain was negative for metastatic involvement. Pertinent laboratory values included a normal thyroid stimulating hormone (TSH) and a normal calcitonin.

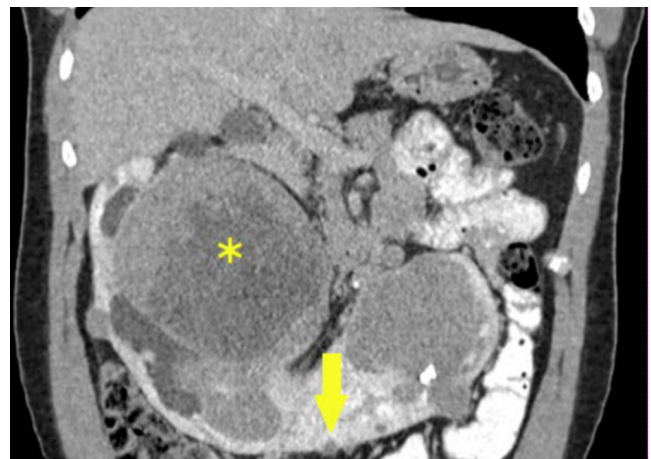

Figure 1A. 32-year-old male with multifocal renal carcinoid and thyroid metastases. Contrast-enhanced coronal reformatted CT shows horseshoe kidney with enhancing nodules within the isthmus (arrow) and a large enhancing lesion within right moiety with an area of necrosis (*); additional lesions are present.

Citation: Hartman MS, Mittal P, Lewis M. Multifocal renal carcinoid tumor arising in horseshoe kidney with metastases to the thyroid. *Radiology Case Reports*. [Online] 2006;1:31.

Copyright: © Matthew S. Hartman. This is an open-access article distributed under the terms of the Creative Commons Attribution-NonCommercial-NoDerivs 2.5 License, which permits reproduction and distribution, provided the original work is properly cited. Commercial use and derivative works are not permitted.

Abbreviations: CT, Computed Tomography, MRI, magnetic resonance imaging, TSH, thyroid stimulating hormone, FNA, fine needle aspiration, RCC, renal cell carcinoma, TTF-1, thyroid transcription factor.

Matthew S. Hartman (Email: mshhartman@hotmail.com) and Pardeep Mittal are from the department of radiology, Emory University School of Medicine, Atlanta, GA, United States of America.

Melinda Lewis is from the department of pathology, Emory University School of Medicine, Atlanta, GA, United States of America.

DOI: 10.2484/rcr.v1i3.31

RCR Radiology Case Reports | radiology.casereports.net

Multifocal Renal Carcinoid Tumor Arising in Horseshoe Kidney with Metastases to the Thyroid

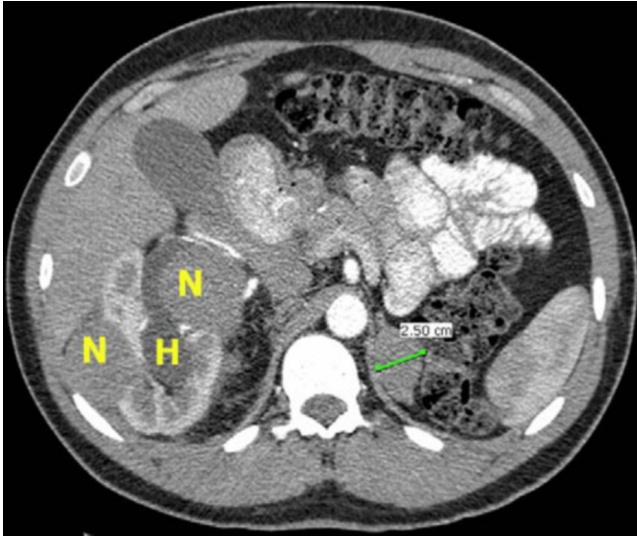


Figure 1B. 32-year-old male with multifocal renal carcinoid and thyroid metastases. Contrast-enhanced axial CT shows multiple enhancing nodules (N) within the right moiety, mild right hydronephrosis (H) and a 2.5 cm left adrenal mass.

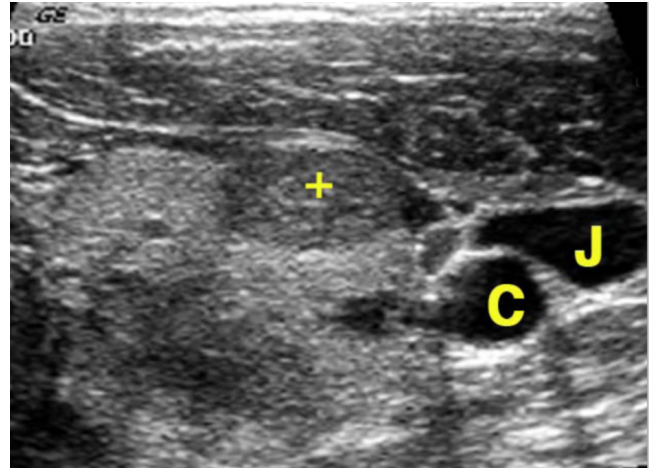


Figure 1C. 32-year-old male with multifocal renal carcinoid and thyroid metastases. Ultrasound of thyroid demonstrates a nodule (cross) adjacent to the jugular vein (J) and carotid artery (C).

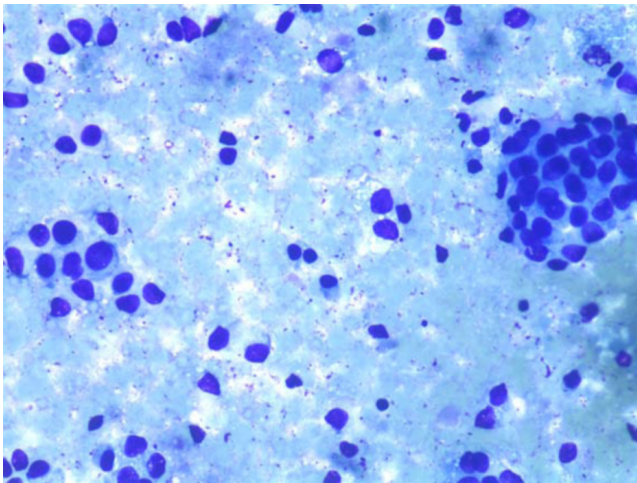


Figure 1D. 32-year-old male with multifocal renal carcinoid and thyroid metastases. Photomicrograph of Diff-Quick stain of FNA of right renal mass (400x) showing clusters of monotonous cells with round to oval nuclei and granular cytoplasm.

A CT guided fine needle aspiration (FNA) of the right kidney mass showed numerous single cells and small tissue fragments composed of a monotonous population of cells with oval to round nuclei, fine chromatin and a moderate amount of granular eosinophilic cytoplasm (Fig 1D). Areas of necrosis were also seen. Virtually all cells were strongly positive by immunohistochemistry for synaptophysin (Fig 1E), a neuroendocrine marker, and pancytokeratin (AE1,3), but negative for renal cell carcinoma (RCC) antigen and thyroid transcription factor (TTF-1). An immunostain for calcitonin was negative and serum calcitonin was also negative, thus excluding metastatic medullary carcinoma of the thyroid. An FNA of the thyroid lesion showed identical morphological and immunohistochemical findings (Fig 1F). These findings were interpreted as renal carcinoid with metastasis to the thyroid.

After the diagnosis of renal carcinoid was made, the patient underwent a somatostatin receptor scintigraphy (OctreoScan) to look for additional tumor foci. Octreotide, a somatostatin analogue, binds to somatostatin receptors which are expressed in more than 80% of carcinoid tumors and whose sensitivity for detecting carcinoid tumors is greater than 85% [3, 4]. There was increased activity in both kidneys and the thyroid gland; however the specificity of these findings was limited because octreotide is renally excreted and may have normal activity within the thyroid gland. More importantly, there was increased activity within the pleural based lesion and within the left adrenal lesion consistent with octreotide avid metastatic foci. There was no abnormal activity within the liver.

Therapeutic planning was complicated and involved a multidisciplinary team. This gentleman was healthy and a

Multifocal Renal Carcinoid Tumor Arising in Horseshoe Kidney with Metastases to the Thyroid

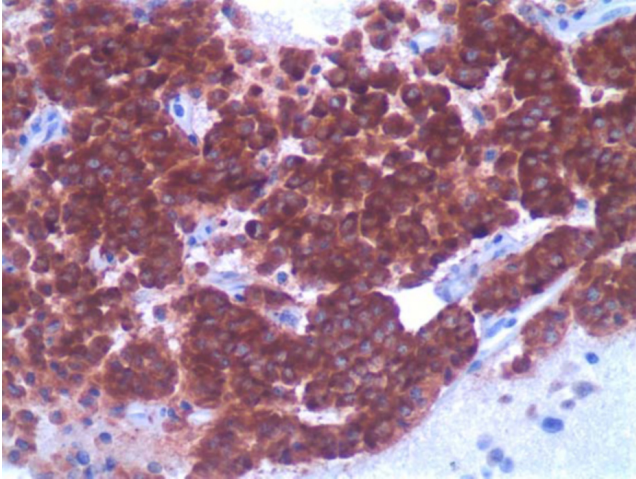


Figure 1E. 32-year-old male with multifocal renal carcinoid and thyroid metastases. Photomicrograph of synaptophysin immunohistochemical stain of cell block preparation (200x) from FNA of right renal mass showing strong staining in all cells consistent with neuroendocrine differentiation.

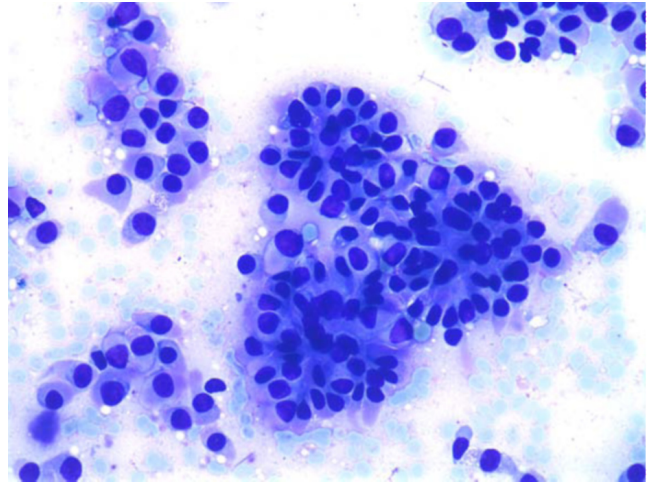


Figure 1F. 32-year-old male with multifocal renal carcinoid and thyroid metastases. Photomicrograph of Diff-Quick stain of FNA of thyroid (400x) showing clusters and single cells with round to oval nuclei and granular cytoplasm, identical to those seen in the right renal FNA (Fig 1D).

total nephrectomy would place him on dialysis. Moreover, any surgical intervention would be very difficult because of the size, location, and the nature of the blood supply to horseshoe kidneys. Renal function at the time of diagnosis was only mildly decreased with a creatinine of 1.6. He is being empirically treated with Sandostatin on a monthly basis, despite the lack of any carcinoid symptoms and will be rescanned for response.

Discussion

Carcinoid tumor cells arise from enterochromaffin or amine precursor uptake and decarboxylation cells. Carcinoid tumors can arise anywhere in the body but most frequently develop in the gastrointestinal tract and bronchial system of the lungs [5]. Enterochromaffin cells are not found in normal renal parenchyma making renal carcinoids extremely rare with less than forty cases in the English literature. Both primary and metastatic renal carcinoids have been reported. Even though some carcinoid tumors show a gender predilection, renal carcinoid tumors occur without any gender predominance [6].

Several groups have noted an association between primary renal carcinoid tumors and horseshoe kidneys with a relative risk ranging from 62 to 82 compared with normal kidneys [1, 2]. The pathogenesis of renal carcinoid tumor is subject to debate and may be different for horseshoe and non-horseshoe variants. Any hypothesis must account for the fact that neuroendocrine cells have not been identified in the normal kidney. Krishnan et al. have postulated that primary renal carcinoid tumors may be more frequently encountered in horseshoe kidneys because of the increased incidence of aberrant epithelium or teratomatous elements within these kidneys [1].

Renal carcinoids are often detected incidentally or because of abdominal pain or hematuria. However, they are usually very large at detection with an average size of 10.5 cm (range 1.2 to 30 cm). This is much larger than the typical non renal carcinoid tumors of which almost fifty percent measure less than 1 cm [6]. Unfortunately, imaging characteristics for renal carcinoids are nonspecific and overlap with those of renal cell carcinomas—that of a cystic and or solid enhancing mass. They have been noted to contain areas of necrosis, hemorrhage and calcification; however, there are no specific imaging findings on CT or MRI. Renal carcinoid is a histopathological diagnosis which employs immunohistochemical stains to confirm the neuroendocrine nature of the tumor [7].

Predicting the clinical course and prognosis of renal carcinoid tumor is difficult because of the paucity of cases. Carcinoid syndrome is rarely associated with renal carcinoids even in instances of metastases to liver [2]. The majority of cases is unifocal and is amenable to resection even in the presence of distant metastases. A recent review by Kawajiri et al. reported a 25.7% incidence of metastases with renal carcinoid. The most frequent sites of metastases were to lymph nodes, liver, and bones which reflects the pattern of spread from carcinoid tumor arising in other organs [6]. The review by Krishnan et al. of 32 cases of renal carcinoid suggested a more benign course for patients with the horseshoe subtype. In fact, a more recent review of the literature reveals only two cases of metastases related to a horseshoe kidney, and the authors at the time of publication suggested an optimistic outlook [2, 8].

Our case is unique because of its multifocal, bilateral involvement with over twenty foci identified, pathologically proven metastases to the thyroid, and presumed metastases to the pleura and left adrenal gland.

References

1. Krishnan B, Truong LD, Saleh G, Sirbasku DM, Slawin KM. Horseshoe kidney is associated with an increased relative risk of primary renal carcinoid tumor. *J Urol*. 1997 Jun;157(6):2059-2066. [[PubMed](#)]
2. Begin LR, Guy L, Jacobson SA, Aprikian AG. Renal carcinoid and horseshoe kidney: a frequent association of two rare entities--a case report and review of the literature. *J Surg Oncol*. 1998 July;68(2):113-119. [[PubMed](#)]
3. Mufarrij P, Varkarakis IM, Studeman KD, Jarrett TW. Primary renal carcinoid tumor with liver metastases detected with somatostatin receptor imaging. *Urology*. 2005 May;65(5):1002. [[PubMed](#)]
4. Tal R, Lask DM, Livne PM. Metastatic renal carcinoid: case report and review of the literature. *Urology*. 2003 Apr;61(4):838. [[PubMed](#)]
5. Kulke MH, Mayer RJ. Carcinoid tumors. *N Engl J Med*. 1999 Mar 18;340(11):858-868. [[PubMed](#)]
6. Kawajiri H, Onoda N, Ohira M, et al. Carcinoid tumor of the kidney presenting as a large abdominal mass: report of a case. *Surg Today*. 2004;34(1):86-89. [[PubMed](#)]
7. Kurzer E, Leveillee RJ, Morillo G. Rare case of carcinoid tumor arising within teratoma in kidney. *Urology*. 2005 Sep;66(3):658. [[PubMed](#)]
8. McVey RJ, Banerjee SS, Eyden BP, Reeve RS, Harris M. Carcinoid tumor originating in a horseshoe kidney. *In Vivo*. 2002 May-Jun;16(3):197-199. [[PubMed](#)]