

Received: 2019.03.12
Accepted: 2019.05.06
Published: 2019.07.25

Antisynthetase Syndrome and Autoantibodies: A Literature Review and Report of 4 Cases

Authors' Contribution:
Study Design A
Data Collection B
Statistical Analysis C
Data Interpretation D
Manuscript Preparation E
Literature Search F
Funds Collection G

ABCDEF 1 **Flávia Luiza Marin***
ABCDEF 2 **Henrique Pereira Sampaio***

1 Postgraduate Program in Pathophysiology in Medical Clinic, São Paulo State University (UNESP), Botucatu, São Paulo, Brazil
2 Department of Rheumatology, Division of Medical Clinic, Section of Medicine, São Paulo State University (UNESP), Botucatu, São Paulo, Brazil

Corresponding Author:
Conflict of interest:

* Flávia Luiza Marin and Henrique Pereira Sampaio contributed equally to this work
Flávia Luiza Marin, e-mail: flavialuizamarin@gmail.com
None declared

Case series

Patient: Female, 25 • Female, 39 • Male, 27 • Female, 42
Final Diagnosis: Antisynthetase syndrome
Symptoms: Arthralgia • dyspnea • muscle weakness
Medication: —
Clinical Procedure: Immunosuppressive therapy
Specialty: Rheumatology

Objective: Rare disease





Background: With the advent and advancement of autoantibodies, there has been progress in the diagnosis, prognosis, and treatment of rheumatologic diseases. Antisynthetase syndrome (ASS) is a great example of a disease that initially was described as arthritis, myositis, interstitial lung disease, mechanic's hands, Raynaud's phenomenon, and fever in the presence of the anti-JO-1 antibody, but nowadays it presents with a different spectrum related to new antibodies.

Case Report: We describe 4 patients with antisynthetase syndrome who were diagnosed with antibodies specific for myositis associated with different clinical findings. All patients responded to immunosuppressive therapy, and rituximab was the most used.

Conclusions: It is necessary to search for specific autoantibodies related to the syndrome in suspected clinical cases and in other rheumatological diseases refractory to the usual treatment.

MeSH Keywords: Amino Acyl-tRNA Synthetases • Autoantibodies • Myositis

Full-text PDF: <https://www.amjcaserep.com/abstract/index/idArt/916178>

 3542  1  6  25



Background

Antisynthetase syndrome (ASS) is a rheumatic disease of idiopathic autoimmune connective tissue. It is characterized by the presence of antibodies against the aminoacyl-RNAt (anti-ARS) complex and the clinical manifestations of inflammatory myopathy, interstitial lung disease (ILD), arthritis, cutaneous hyperkeratosis/mechanic's hands, fever and Raynaud's phenomenon [1–6]. The first case of ASS was described in 1990 by Margurie et al., who studied 29 patients with antisynthetase antibodies, inflammatory myopathy (mostly), ILD, inflammatory arthritis, sclerodactyly, Raynaud's phenomenon, and sicca syndrome [2,7]. However, to date, there are no well-defined diagnostic criteria due to the small number of cases. The similar phenotypes are associated with the specific antibodies of this group, which can be subdivided into diseases of different clinical manifestations and prognoses [2,5]. The disease initially characterized by arthritis, inflammatory myositis, mechanic's hands, Raynaud's phenomenon, fever, and pulmonary involvement was gradually divided into different subgroups better defined according to the associated antibody. For this reason, it is currently described through the classical triad: arthritis, myositis, and interstitial lung disease (ILD). Raynaud's phenomenon, mechanic's hands, and fever are other relevant but less prevalent factors [1,8]. The present descriptive study was developed through research on the PubMed/Medline and RIMA.org platform for original articles, review articles, case reports, and case series focused on antisynthetase syndrome. We used for these keywords: myositis, antisynthetase syndrome, autoantibodies, necrotizing myositis, inclusion corpuscle myositis, and their combinations. The inclusion criteria were: international and complete texts, published between May 2006 and February 2018, presenting basic concepts: pathophysiology, diagnosis, causes, signs, symptoms, related antibodies and treatments for the syndrome. The results were organized into 5 groups of information: epidemiology, pathogenesis, clinical findings, antibodies, and prognosis. We present these 4 cases to illustrate the different spectrum of this rare disease and its relation to new antibodies, and thus draw attention to the differential diagnosis of the most prevalent rheumatic diseases that evolve in an unexpected way and require more aggressive treatment.

Epidemiology

Because ASS is a rare disease, there is no scientific data on its epidemiology. However, it is known that 30% of patients with a myopathic inflammatory disease can be diagnosed with ASS by the presence of specific antibodies [5]. The incidence of inflammatory myopathy is approximately 2 per 100 000 individuals in the general population, so the annual incidence of ASS can be considered to be around 0.6 per 100 000 individuals.

It affects women and men in an approximate ratio of 2: 1, ages 22–74 years [2], and the mean age at diagnosis is 50 years [9].

Pathogenesis

It remains an idiopathic disease with unclear pathogenesis. Myopathies are believed to be mediated by innate immunity through interferon-alpha (INF- α) and cytokines (IL-6/IL-8/anti-TNF- α) [2,10], mainly produced by T and B lymphocytes (detected high levels of B-cell activation factor [BAFF]), macrophages, and dendritic cells. Complexes containing antibodies-specific myositis and associated myositis increase the activity of INF- α . However, anti-IFN- α therapy is associated with a higher risk of development of inflammatory myopathies, being a paradox in relation to its pathogenesis [2]. It is known that muscle regeneration has high expression of aminoacyl-RNAt-synthetase, which may be a target of the immune system. Therefore, it is possible that muscle damage triggers even more activation of the immune system. Thickett and Millar described a case of SAS induced by the drug Valsartan, and Ishikawa described a positive ASS-JO-1 case report associated with the use of Etanercept, which is an anti-TNF- α immunobiological. Smoking was associated with higher HLA-DRB1*03 expression [2], which is related to myositis in white American patients and detected in 73% of ASS [11], especially anti-JO-1 [2]. In addition, viral infections are also described as potential triggering factors, as well as African American ethnicity for increased risk of ILD (this still need studies for substantiation) [2].

Clinical findings

The largest study was performed among 24 rheumatology centers in Italy, Spain, Germany, and the United States, with the largest cohort of 225 patients with anti-Jo-1 positivity and one of the longest follow-ups ever reported (82 median months); it describes the standard clinical symptoms found. The initial symptoms may not suggest ASS, and even the incomplete form may become complete. It is necessary to pay attention to the diagnosis of ASS even in cases with isolated manifestations of ILD, arthritis, or myositis. Among 113 completed cases, 69 cases (61%) initially had developed incompletely (Figure1). Joint involvement can be subdivided in polyarthralgia and arthritis, which was present in 76.5% (66% symmetric polyarthrititis, 34% asymmetric oligoarthrititis, and 21.5% erosive arthrititis). The prevalence of rheumatoid factor is described in 29% and anti-cyclic citrullinated peptide (anti-CCP) in 12.5%; also, it was found to be anti-CCP, even in the absence of arthritis in some cases. Myositis was prevalent at the end the follow-up in 79% and ILD in 84% of the patients, and also can be subdivided into 3 forms: 26% asymptomatic, 34% subacute/acute, and 40% chronic. Raynaud's phenomenon was present in 17% of cases preceding other manifestations by an average

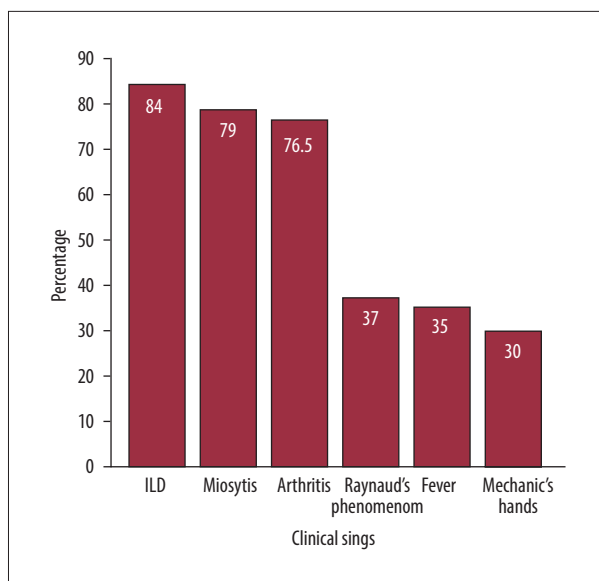


Figure 1. Signs and symptoms prevalent in AAS.

of 13 months. In 20% of cases, pulmonary arterial hypertension was found both in the complete and incomplete form of the disease, diagnosed by right cardiac catheterization [1].

Antibodies

Serum autoantibodies are commonly found in Idiopathic Inflammatory Myopathies or Autoimmune Inflammatory Myopathies, with a prevalence above 90%, which can define clinically homogeneous subgroups of patients and estimate prognoses [4,9]. Such antibodies are anti-nuclear or anti-cytoplasmic. They are divided into myositis-specific antibodies and myositis-associated antibodies, when related to other diseases of connective tissue. For this reason, a negative anti-nuclear antibody test does not rule out the presence of myositis-specific antibodies because the antigenic targets are cytoplasmic in the localization of subtle patterns of immunofluorescence staining [12]. Although some patients have more than one serum autoantibody, myositis-specific antibodies are rarely detected in the same patient. Anti-RNA synthetase antibodies are directed against to cytoplasmic reactivity products; that is, specific amino acids related to RNA synthetase [2,12]. This is a step towards protein synthesis [2] and is represented by cytoplasmic ANA [13]. The medical literature describes 16 myositis-specific antibodies, 8 of which comprise the group of antisynthetase antibodies [2,14] and the remaining 8 are not related to ASS. There is also a group of non-specific myositis-associated antibodies that do not make up the group of 16 myositis-specific antibodies (Figure 2). The direct role in the pathogenesis of the disease by these antibodies is unknown, but it is important to characterize groups of specific phenotypes and prognoses (Table 1) [2]. In summary, in the group of 8 antibodies to ASS,

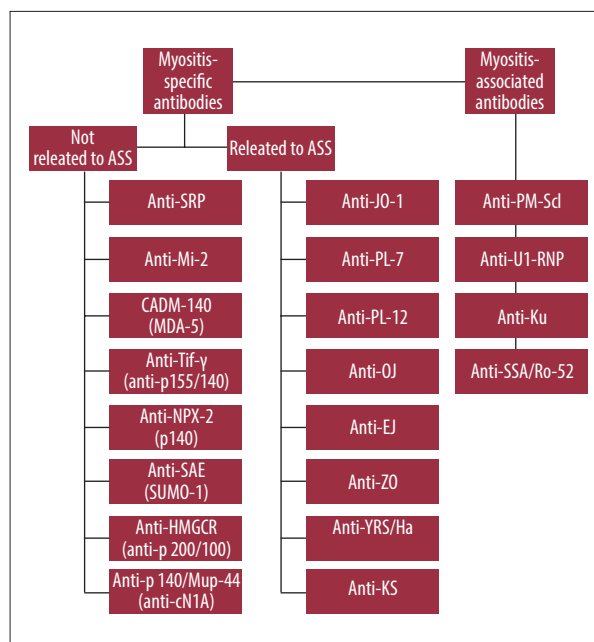


Figure 2. Division of autoantibodies in idiopathic inflammatory myopathies.

the anti-JO-1, anti-OJ, anti-EJ, anti-ZO, and anti-YRS/Ha [11] antibodies are most prone to classical ASS form (Figure 3) [2,5,15].

Prognosis

It appears that patients with ASS have a worse prognosis compared to patients with isolated DM or PM, which can be explained mainly by frequent lung involvement and possible increased risk for malignancy [3,10]. Another situation that causes considerable morbidity and mortality of these patients is pulmonary hypertension associated with ILD, which is present in 7.9% of cases (possibly underestimated due to the screening methodology) [7]. Among serum autoantibodies, anti-SRP is a marker for poor prognosis, followed by the antisynthetase group, specially anti-MDA-5 [14]. The best survival occurs in patients positive for anti-PM-Scl and anti-Mi-2 autoantibodies [9].

Case Report

From January 2006 to December 2018, 5 patients with antisynthetase syndrome were treated at the Connective Diseases Clinic of São Paulo State University (UNESP), Botucatu. However, only 4 patients agreed to participate in the study. Their data were collected based on the electronic medical records analysis of the MVPEP platform (version SMA-PEP.02.072.4). The study was evaluated by protocol number 3.010.725, accepted by the Research Ethics Committee of Botucatu Medical School (FMB)/UNESP, and all participants read and signed the consent form.

Table 1. Myositis antibodies.

Antibodies	Target	Prevalence	Clinical features	References
Myositis-specific antibodies not related to ass				
Anti-Tif 1γ or Anti-p155/140	Transcription intermediary factor 1γ	13–31% in DM and 22–29% in JDM	Absence of ILD. Presence of HLA-DQA1*0301. It is highly specific and moderately sensitive to predict myositis associated with malignancy in adults	[9,12,14]
Anti-CADM-140 or Anti-MDA-5	Melanoma differentiation-associated protein 5	19% in DM	Sensitivity of 77% and specificity of 86% to predict ILD in a rapidly progressive form and reserved prognosis. Cutaneous lesions with or without mild myositis and skin vasculopathy	[10,12,14,15]
Anti-Mi-2	Helicase	4–18% of IIM: 7% of Caucasians and 30% of Hispanics. 4–10% of JDM	Good therapeutic response. Rash can be severe in JDM	[9,14]
Anti-SAE or Anti-SUMO-1	Small ubiquitin-like modifier	11% in IIM and 8% in DM (less common in Asians)	Potential to serious cutaneous lesions that precede the myositis. Myositis can be moderate. Associated with HLA-DRB1*04-DQA1*03-DQB1 *	[12,14,15]
Anti-SRP	RNP involved in translocation	5% in IIM (more in Asian and African American) and 17% in necrotizing myopathy	Cardiac and lung involvement is contradictory. Increased dysphagia.	[14,16,17,18]
Anti-HMGCR or Anti-p200/100	3-hydroxy-3-methylglutaryl-coenzyme A reductase	6% in IIM	Statin-related immune-mediated necrotizing myopathy. Myositis can occur at the same time or even after the use of the statin has stopped.	14, 19,20
Anti-NXP-2 or Anti-p140 or Anti-MJ	Nuclear matrix protein-2	<5% in DM in adults and 20–23% in JDM	JDM with calcinosis and HLA-DRB1*08. Good therapeutic response and no association with neoplasia and ILD	9,12,14,15
Anti-Mup-44 or Anti-cN1A or Anti-NT5c1A	Cytosolic 5'-nucleotidase 1A	33-37% in inclusion body myositis	It does not correlate with other antibodies	[14,21]
Myositis-specific antibodies related to ASS				
Anti-JO-1	Histidyl	20–30% in IIMs and 75% in ASS	Develops as the classical form. Strong predictor for ILD (70–90%), but also strong predictor of clinical response to immunobiological drug	[2,3,4,14,16]
Anti-PL-7	Threonyl	5% in ASS	Increased involvement of the gastrointestinal tract, Raynaud's phenomenon, and ILD. Isolated ILD is typical, but milder compared to anti-PL-12. This happens in myositis as well	[2–5]
Anti-PL-12	Alanyl	5% in ASS	Increased involvement of the gastrointestinal tract, Raynaud's phenomenon, and ILD. ILD isolated is typical, but has a greater burden of ILD and esophageal involvement and a lower chance of developing arthritis and myositis compared to anti-PL-7	[2–5]
Anti-OJ	Isoleucyl	1-5% in AAS.	ILD is commonly, but responds very well to glucocorticosteroids. Strong association with neoplasia, but without statistical evidence.	2,3,4,5

Table 1 continued. Myositis antibodies.

Antibodies	Target	Prevalence	Clinical features	References
Anti-EJ	Glycyl	1.5% in ASS	It develops the classic form with myopathy and ILD, and is possibly the one with the lowest association with malignancy	[2]
Anti-KS	Asparaginyl	1% in ASS	DPI is frequent, but Raynaud's phenomenon and arthritis are not. Myositis was not evidenced	[2]
Anti-ZO	Phenylalanyl	<1% in ASS	Develops as the classical form.	[2]
Anti-YRS or Anti-TyR or anti-Ha	Tyrosyl	<1% in ASS	Develops as the classical form.	[2]
Myositis associated antibodies				
Anti-PM-Scl	Degraded ribosomal proteins	5–25% in IIM and 43–88% are scleromyositis or sclerodermatomyositis. It increases using the subunit PM-Scl-75 in addition to the PM-Scl-100 epitope in ELISA test	There is a possible risk for neoplasia and is represented by homogeneous nucleolar ANA	[9,12,14]
Anti-U1-RNP	U1 ribonucleoprotein	3–8% in PM or DM. 25–40% as an overlap syndrome with myositis and/or systemic sclerosis	It is part of Mixed connective tissue disease and it is represented by thick-stranded nuclear ANA. Associated with anti-PM-Scl and anti-KU	[2,13]
Anti-Ku	Protein-chromatin subunit	1-5% in DM and PM.	Associated with myositis and systemic sclerosis overlapping syndrome. Risk for neoplasia	[2,12,14]
Anti-RO-52 or anti-TRIM-21	Ro52 within the family of tripartite motif proteins	24% in IIM. 56% is found in association with anti-JO-1	Severe ILD and lower response to treatment.	[1,5,9,14,22,23]

ASS – antisynthetase syndrome; DM – dermatomyositis; JDM – juvenile dermatomyositis; ILD – interstitial lung disease; IIM – idiopathic inflammatory myopathies; PM – polymyositis.

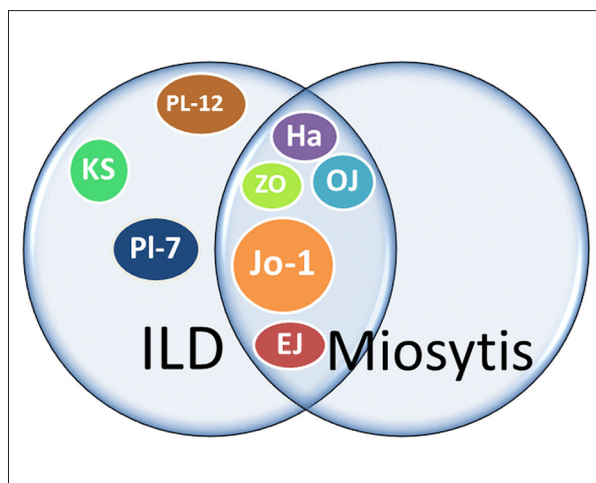


Figure 3. Relation of myositis-specific antibodies with myositis and interstitial lung disease.

Case 1

Case 1 was a 25-year-old woman with a proximal weakness of the scapular and pelvic girdle (muscular strength in scapular girdle grade III and pelvic IV), fatigue, dyspnea on exertion, high dysphagia for solids, fine-tuned pulmonary crackling on bilateral bases, and overlying erythematous and hyperkeratotic areas on the back of the metacarpophalangeal and interphalangeal joints on the both hands (Gottron's papules). Testing revealed creatine phosphokinase (CPK) 3249 IU/L, lactate dehydrogenase (LDH) 1240, aspartate aminotransferase (AST) 102 IU/L, alanine aminotransferase (ALT) 90 IU/L, ANA 1/320 cytoplasmic dotted isolated dots pattern, and anti-JO-1 positive=67 IU/ml. Electromyoneurography was compatible with a myopathic inflammatory pattern. High-resolution computed tomography showed signs of incipient non-specific interstitial pneumopathy. Antisynthetase syndrome was identified by cutaneous hyperkeratosis, myositis, non-specific interstitial pneumopathy, and presence of the anti-JO-1, and then she

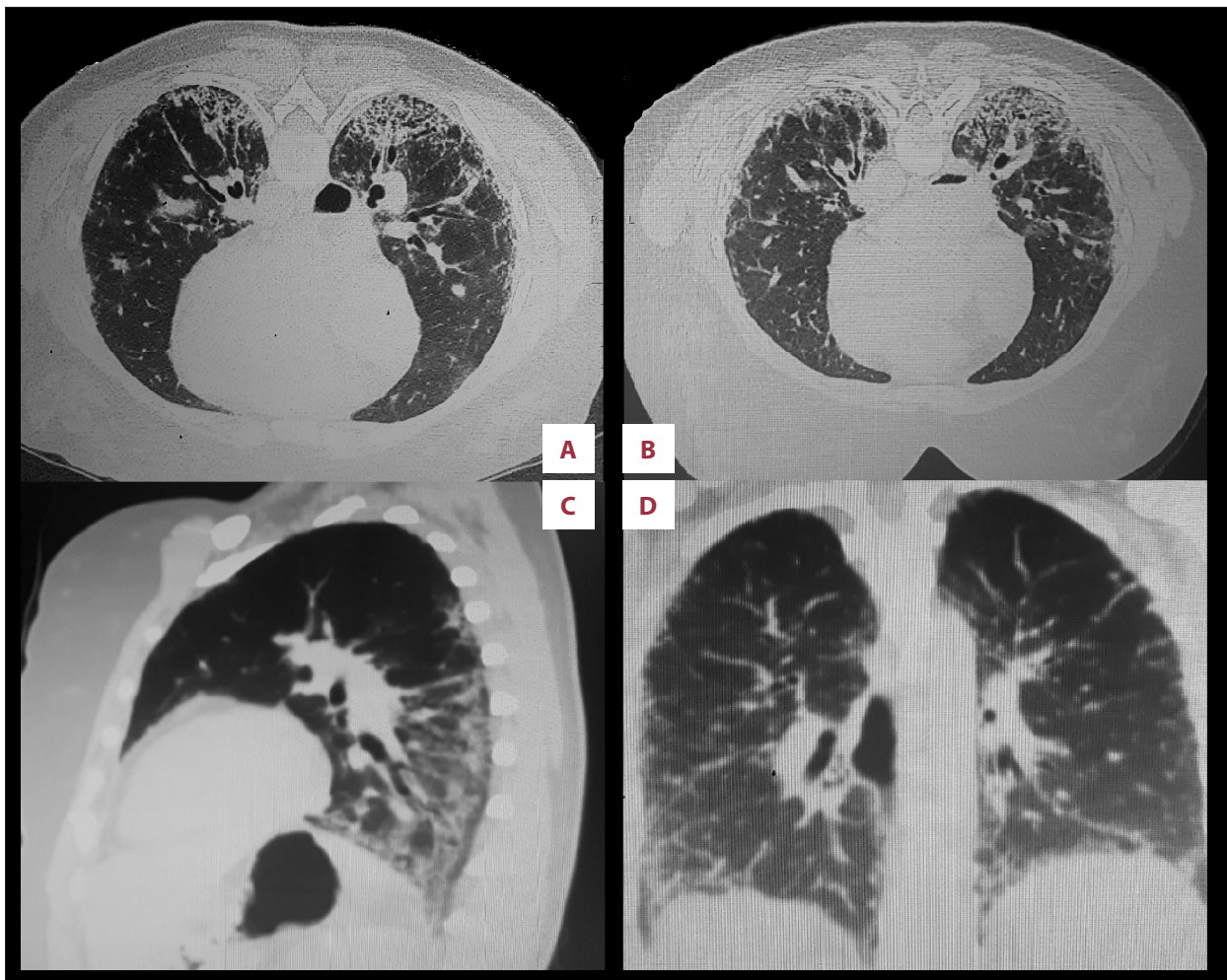


Figure 4. HRCT of the chest compatible with NSIP. Pulmonary fibrosis by peripheral and peribronchovascular reticular infiltrates, preserving the subpleural regions, with architectural distortion, associated with areas of ground-glass, bronchiectasis, and some honeycombing cysts. (A, B) Transverse incidence of the mid-lower chest with a 1-year difference between them. (C) Sagittal incidence. (D) Coronal incidence of the posterior chest.

was prescribed prednisone 1 mg/kg/day. Due to the refractoriness of slow monthly regression, the prednisone dose was again increased to 1 mg/kg/day and methotrexate 15 mg/week was added. The patient had a good response and control of the disease was achieved, so we suspended prednisone and maintained immunosuppressive for 5 years, without relapse.

Case 2

Case 2 was a 39-year-old woman who during the past 18 months had developed pruritus and scaling on the medial face of the hands (mechanic's hands), polyarthralgia of small and large joints of the inflammatory type, dry cough, dyspnea on exertion, weight loss of 5 kg/1 year, adynamia, Raynaud's phenomenon, telangiectasia on the cervix, clock-glass nails, unguis microangiopathy, and Velcro-type pulmonary crackling on bases. Complementary examinations showed the following:

high-resolution computed tomography of the chest was compatible with non-specific interstitial pneumopathy (Figure 4), spirometry with moderate restrictive ventilatory disorder without bronchodilator response, forced vital capacity=44%; nail-fold capillaroscopy presenting SD pattern (Figure 5); electromyoneurography performed during the period of corticoid therapy presented myopathic pattern and rare spontaneous activities in the right biceps brachial muscles and left lumbar paravertebral; muscle biopsy during the treatment period was normal; and anti-PL-7 was positive. Pulse therapy with cyclophosphamide 0.6 g/m²/monthly for 6 months and prednisone 1 mg/kg/day with slow monthly regression was performed in an irregular manner because of a pause for investigation of tuberculosis, which was negative. The patient evolved with pain in the right hypochondrium and elevation of liver enzymes with resolution after suspension of cyclophosphamide, confirming drug hepatitis. Due to progressive

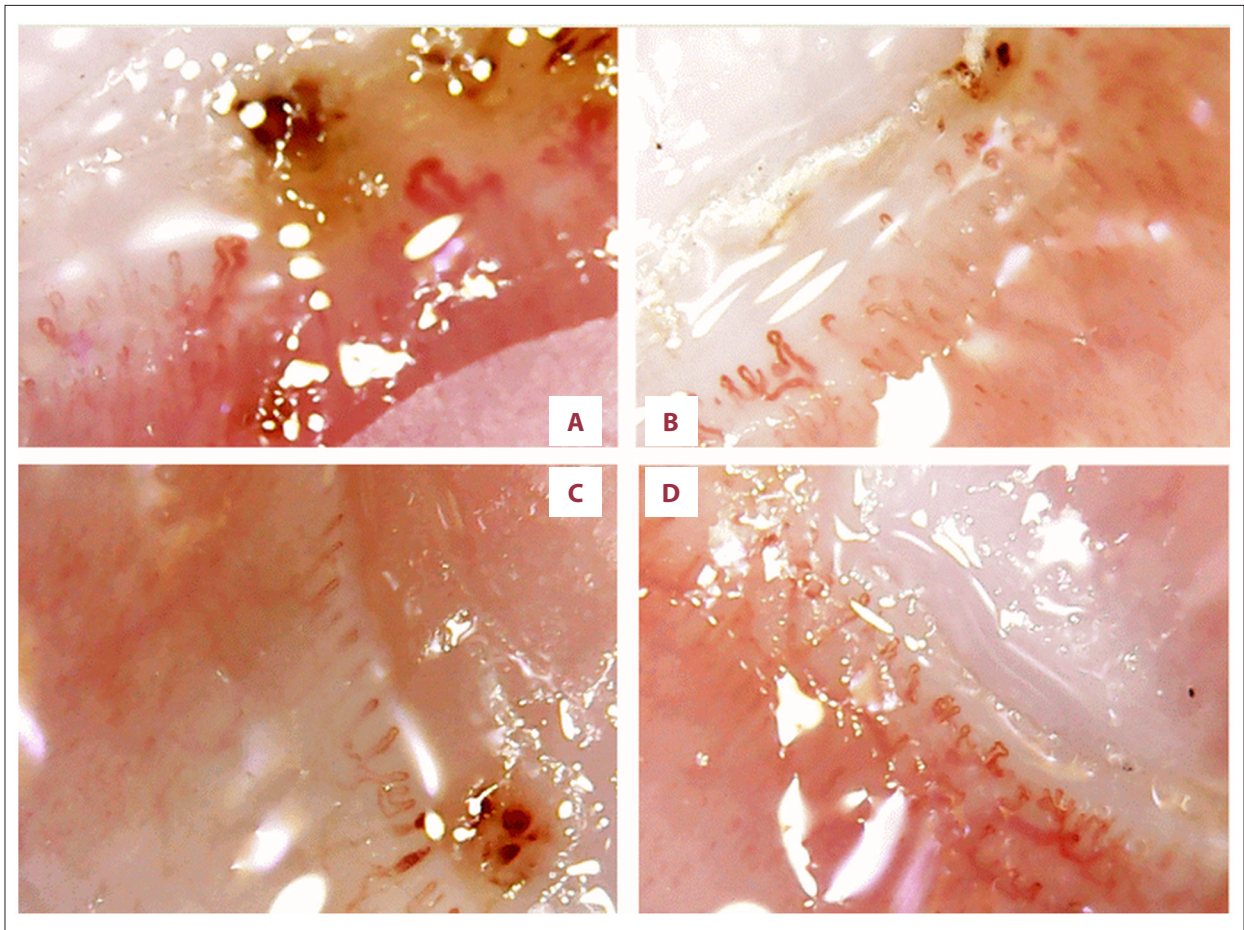


Figure 5. Nailfold capillaroscopy with SD pattern. (A, D) Tortuous or branched capillaries, dilated capillaries, megacapillaries, and microhemorrhages (in upper region). (B, C) Avascular areas.

worsening of the clinical and radiological pattern, mycophenolate mofetil was initially recommended at 2 g/day and increased to 3 g/day due to worsening pulmonary function after 1 year of use. Without resolution of it and requiring home oxygen therapy, the emergence of symmetric and additive erosive arthritis and lower limb vasculitis (biopsy was compatible with leukocytoclastic vasculitis), mycophenolate mofetil was suspended. We then prescribed prednisone 1 mg/kg/day plus a course of rituximab consisting of two 1-g doses given 15 days apart, every 6 months. The patient had already completed 7 courses. Home oxygen therapy was no longer required due to evolution with dyspnea improvement. Due to refractory arthritis, we subcutaneously administered methotrexate up to a dose of 25 mg/week, with a gradual reduction after control and currently at 15 mg/week orally. In this case, antisynthetase syndrome could be identified by mechanic's hands, Raynaud's phenomenon, non-specific interstitial pneumopathy, myositis, arthritis, and presence of the anti-PL-7.

Case 3

Case 3 was a 27-year-old man with 4 months of progressive myalgia and muscular weakness (muscle strength grade IV in pelvic girdle), asymmetrical oligoarthritis, mechanic's hands, and Gottron's papules in the 2nd and 3rd metacarpophalangeal joints bilaterally. Complementary exams showed: CPK 12.527 IU/L, AST 287 IU/L, ALT 371 IU/L, aldolase 86 IU/L, DHL 1264 IU/L, ANA 1/320 cytoplasmic dotted isolated dots pattern, and anti-JO-1 positive >200 IU/ml. Electromyoneurography of the right vastus lateralis and left anterior tibialis muscles showed a myopathic pattern with spontaneous activities; right biceps and paravertebral muscles with a myopathic pattern, without spontaneous activities. This was suggestive of polymyositis or myopathy associated with other rheumatologic diseases. Initially, he received treatment with prednisone 1 mg/kg/day and methotrexate 10 mg/week. The patient was lost to outpatient follow-up and stopped using medication on his own. He returned to our center 1 year later; during this time, he had been taking methotrexate 15 mg/week orally and prednisone 1 mg/kg/day prescribed by another rheumatologist.

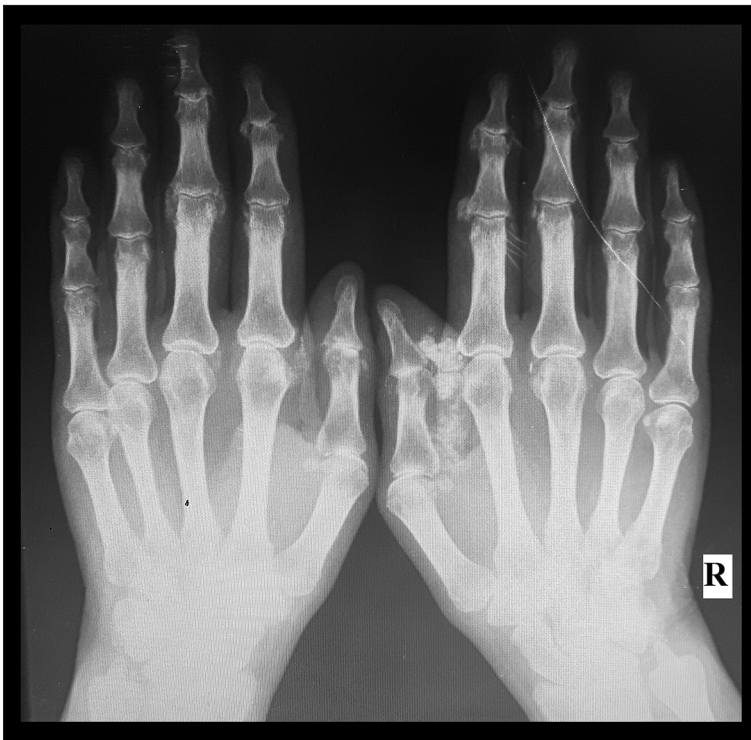


Figure 6. X-ray of hands with erosive arthritis and periarticular calcification.

The evaluation had high dysphagia for solids. Spirometry was suggestive of mixed ventilatory disorder, without bronchodilator response (forced vital capacity=76%, forced expiratory volume in 1 second (FEV1)=78%, FEV1/forced vital capacity 103%). High-resolution computed tomography of the chest showed faint ground-glass opacities, subpleural reticular areas bilaterally, and micronodular opacities in the apical segment of the right upper lobe, suggestive of non-specific interstitial pneumopathy. Then, methotrexate was changed to azathioprine 2 mg/kg/day and prednisone was maintained at 1 mg/kg/day. After 3 months, there was an important worsening of muscular weakness, and he was admitted to the hospital and received pulse therapy with methylprednisolone 1 g/IV/day for 3 days. At the quarterly outpatient return visit, due to persistence and worsening of clinical and laboratory activity indicators of muscular weakness (absence of ambulation), Pompe's disease was investigated, which was negative. A muscle biopsy was performed, showing a non-specific myopathic pattern, without signs of dystrophy or inflammation, without the result of immunohistochemistry. From this, antisynthetase syndrome was diagnosed by mechanic's hands, arthritis, non-specific interstitial pneumopathy, myositis, and presence of anti-JO-1. New pulse therapy was administered for 5 days with methylprednisolone 1 g/IV/day, followed by pulse therapy with cyclophosphamide 0.6 g/m²/IV and prednisone 0.75 mg/kg/day. In the following 6 months, a monthly pulse of cyclophosphamide with increasing dose up to 1 g/m² plus a pulse of methylprednisolone 1 g/IV and prednisone 0.75 mg/kg/day with very slow monthly regression were maintained. After that,

due to the slight maintenance of muscle weakness and high dysphagia associated with high CPK rates (10.104 IU/L and DHL 3280 IU/L) we prescribed a cycle of rituximab consisting of two 1-g doses given 15 days apart. The patient had excellent clinical and laboratory response, with muscular strength V degree and CPK and DHL within normal limits. To date, he has already completed 4 cycles of rituximab.

Case 4

Case 4 was a 42-year-old woman with a diagnosis of overlap syndrome of rheumatoid arthritis and polymyositis, with a non-specific interstitial pneumopathy and family history of a mother with rheumatoid arthritis and interstitial lung disease. There was symmetric and additive erosive polyarthritis and small and large joint involvement (Figure 6), despite treatment with hydroxychloroquine 400 mg/day, azathioprine 2 mg/kg/day, and prednisone 5 mg/day. She also had Raynaud's phenomenon, dyspnea upon rest, dry cough, high dysphagia for liquids, odynophagia, dry mouth, weight loss of 8 kg/8 months, fever of 38°C with night sweats 3 times a week, and weakness of pelvic and scapular waists. We changed azathioprine to methotrexate 15 mg/week/orally. A physical examination revealed lymphadenopathy in the bilateral cervical region, mobile and painless, fine crackling at the lung bases, diffuse synovial thickening in interphalangeal and metacarpophalangeal on both hands, limitation of hips, and muscular strength in scapular and pelvic girdle grade IV and preserved in the others groups. Complementary exams showed: normocytic and

normochromic mild anemia; AST 16 IU/L; ALT 30 IU/L; erythrocyte sedimentation rate 58 IU/L; CPK 513 IU/L; positive rheumatoid factor; positive ANA in fine dotted nuclear pattern; anti-SSA/RO >200 IU/ml; anti-JO-1 >200 IU/ml; spirometry (forced vital capacity 55%, FEV1 53% and FEV1/forced vital capacity 81%); CO₂ diffusion of 33%; chest high-resolution computed tomography with predominant ground-glass pattern in lower pulmonary lobes, diffuse reticular opacity with thickening of septal, micronodules, thin fibrotic beams; nailfold capillaroscopy without change; electromyoneurography with myopathic pattern in right anterior tibial, left lateral vastus, left paravertebral and left brachial biceps muscles; muscle biopsy in external service compatible with inflammatory myopathy; and minor salivary gland biopsy without alteration. There was posterior-anterior incidence of hand with reduction of the bone mineral density periarticular in proximal interphalangeal and metacarpophalangeal joints and reduction of intercarpal space, radiocarpal, and metacarpophalangeal, as well as microcysts and periarticular bone neoformation in proximal interphalangeal and distal interphalangeal of varying degrees. We administered pulse therapy with methylprednisolone 1 g/IV/day for 3 days, followed by cyclophosphamide 0.6 g/m²/monthly for 18 months and prednisone 1 mg/kg/day with slow monthly regression. In neoplastic screening, 3 hypochoic nodular images were detected with a hypochoic halo around them, without calcification. Doppler imaging of the peripheral vascular flow showed that only 1 of them larger than 1 cm. Puncture biopsy showed papillary carcinoma of the thyroid category IV (Bethesda 2010) and was followed with surgical resection with T1NxMx staging and radioactive iodine therapy. During this entire period, cyclophosphamide pulse therapy was maintained monthly. Despite this therapy, there was a significant evolution of arthritis and non-specific interstitial pneumopathy, so we reintroduced methotrexate 15 mg/week/orally while awaiting the judicial release of rituximab. We prescribed a course of rituximab consisting of two 1-g doses given 15 days apart every 6 months. To date, the patient has already completed 4 courses, with dramatic improvement and no progression of high-resolution computed tomography patterns and spirometry. This was a case of antisynthetase syndrome associated with neoplasia and was diagnosed by arthritis, non-specific interstitial pneumopathy, myositis, Raynaud's phenomenon, and presence of anti-JO-1.

Discussion

ASS can present in many ways, often incompletely at the outset, without the classic triad of myositis, interstitial lung disease, and arthritis associated with other characteristic findings such as Raynaud's phenomenon, mechanic's hands, and fever. Therefore, we should be aware of cases that begin only with isolated muscular, articular, or pulmonary involvement [1,16,23].

In up to 27% of the ASS frames, isolated polyarthritis may be the only symptom, delaying the diagnosis by a mean of 27 months, in contrast to the 18 months of delay in those patients who present with polyarthritis, ILD, and/or myositis [23]. In symmetric polyarthritis, anti-JO-1 investigation is suggested, even when rheumatoid and anti-CCP factors are positive, especially when there are associated systemic symptoms [1,3,8,24]. In some of the reported cases, the joint condition was similar to rheumatoid arthritis with erosive pattern and the rheumatoid factor positive, making an early diagnosis of ASS difficult. Anti-JO-1 is the antibody related to ASS that is most associated with arthritis, and when present clearly defines ASS, as all others 7 autoantibodies are related to ASS. This is also true for myositis-specific antibodies not related to ASS; because of the high specificity, they define their specific syndromes reported in Table 1. Thus, it can be speculated that cases of rheumatoid arthritis treated with anti-TNF- α that had developed myositis may actually be pictures of the natural evolution of ASS [1,3,24]. Likewise, isolated ILD should have anti-JO-1 investigation, and if available, the others antibodies associated with ILD described in Table 1. This is because ILD associated with various myositis-specific antibodies has different evolutions and prognosis among themselves and compared to rheumatoid arthritis and other rheumatic diseases. When myositis-specific antibodies are detected, pulmonary control should be performed regularly, since they have high prevalence rates in the course of the disease (68% specifically in ASS) [1]. In all 4 cases presented here, there was pulmonary involvement at the end of follow-up, 3 of which were anti-JO-1 positives, which is in accordance with the literature. The case with worst lung morbidity was related to anti-PL-7, confirming that negative anti-JO-1 ASS patients have a worse prognosis than those with positive JO-1 ASS [3,14]. Raynaud's phenomenon associated with polyarthritis in ASS was found in 50% of our cases and in the literature it is found in 32–43% [8,23]. However, Raynaud's phenomenon associated with polyarthritis in rheumatoid arthritis is an uncommon finding, reported in only 10% of such patients. Thus, these 2 isolated findings (symmetric polyarthritis and DPI) and the combination of Raynaud's phenomenon associated with polyarthritis serve as a warning in patients with rheumatoid factor and anti-CCP negative [23]. There is an important association of anti-RO-52 with anti-JO-1, which may be initially confused with Sjogren's syndrome, since autoantibodies targeting RO-52 and RO-60 antigens are historically reported only as anti-SSA/RO. At present, minor salivary gland biopsy helps differentiate Sjogren from other rheumatologic diseases with similar symptoms, and the presence of anti-JO-1 specifies that it is ASS. In cases refractory to corticosteroids and immunosuppressive drugs, rituximab can be beneficial, but there is no established duration of treatment [2,10,24,25]. It is a good option in cases of ASS anti-JO-1 positive [6,14] and cases of ASS associated with rheumatoid arthritis anti-CCP positive [2,25]. Ultimately, immunoglobulin/IV may be

needed [2,25]. In 3 of the cases presented here, it was necessary to prescribe rituximab, with different clinical indications, and 2 of them were anti-JO-1-positive. However, no patients used immunoglobulin. Detection of other specific antibodies to ASS, in addition to anti-JO-1, is difficult. Which reduces the reported prevalence of this syndrome in our rheumatology clinics, making it appear to be a rarer disease than it really is. The existing difference in the prevalence of some symptoms is increased by the fact that the largest sample is anti-JO-1.

Conclusions

The clinical manifestations of antisynthetase syndrome may have a varied combination and are not always present at the onset of disease. It may arise over time, even when treatment has already been instituted. Myositis, arthritis (sometimes only

inflammatory arthralgia), and interstitial pneumopathy are common to all, at a higher frequency. The poor prognosis and difficult disease control in most case reports are striking. Thus, it is necessary to search for specific autoantibodies related to the syndrome in clinical cases suggestive of other rheumatological diseases, especially rheumatoid arthritis refractory to the usual treatment, given the similar articular presentation and interstitial pneumopathy without a defined cause.

Acknowledgments

The authors would like to thank Caio Laguna Reis de Carvalho for supplying the nailfold capillaroscopy photographs.

Conflict of interest

None.

References:

1. Cavagna L, Nuño L, Scirè CA et al., AENEAS (American, European Network of Antisynthetase Syndrome) collaborative group: Clinical spectrum time course in anti Jo-1 positive antisynthetase syndrome: Results from an international retrospective multicenter study. *Medicine (Baltimore)*, 2015; 94(32): e1144
2. Mirrakhimov AE: Antisynthetase syndrome: A review of etiopathogenesis, diagnosis and management. *Curr Med Chem*, 2015; 22(16): 1963–75
3. Rojas-Serrano J, Herrera-Bringas D, Mejía M et al: Prognostic factors in a cohort of antisynthetase syndrome (ASS): Serologic profile is associated with mortality in patients with interstitial lung disease (ILD). *Clin Rheumatol*, 2015; 34: 1563–69
4. Hervier B, Devilliers H, Stanciu R et al: Hierarchical cluster and survival analyses of antisynthetase syndrome: Phenotype and outcome are correlated with anti-tRNA synthetase antibody specificity. *Autoimmun Rev*, 2012; (12): 210–17
5. Shi J, Li S, Yang H et al: Clinical profiles and prognosis of patients with distinct antisynthetase autoantibodies. *J Rheumatol*, 2017; 47(7): 1051–57
6. Wernham M, Montague SJ: Mechanic's hands and hiker's feet in antisynthetase syndrome. *CMAJ*, 2017; 189(44): E1365
7. Hervier B, Meyer A, Dieval C et al: Pulmonary hypertension in antisynthetase syndrome: Prevalence, aetiology and survival. *Eur Respir J*, 2013; 42: 1271–82
8. González-Gay MA, Montecucco C, Selva-O'Callaghan A et al: Timing of onset affects arthritis presentation pattern in antisynthetase syndrome. *Clin Exp Rheumatol*, 2018; 36(1): 44–49
9. Hochberg MC, Silman AJ, Smolen JS et al: *Connective tissue disorders*. In: *Rheumatology* 6th ed. Philadelphia, Elsevier, 2015; 1224–54
10. Hallowell RW, Danoff SK: Interstitial lung disease associated with the idiopathic inflammatory myopathies and the antisynthetase syndrome: Recent advances. *Curr Opin Rheumatol*, 2014; 26(6): 684–89
11. Noguchi E, Uruha A, Suzuki S et al: Skeletal muscle involvement in antisynthetase syndrome. *JAMA Neurol*, 2017; 74(8): 992–99
12. Sibilia J, Chatelus E, Meyer A et al: Comment faire le diagnostic et mieux comprendre les myopathies inflammatoires? L'utilité des auto-anticorps. *Presse Med*, Elsevier, 2010; 39: 1010–25 [in French]
13. Dellavance A, Júnior AG, Nuccitelli B et al: 3º Consenso Brasileiro para pesquisa de autoanticorpos em células HEP-2 (FAN). *Recomendações para padronização do ensaio de pesquisa de autoanticorpos em células HEP-2, controle de qualidade e associações clínicas*. *Rev Bras Reumatol*, 2009; 49(2): 89–109 [in Portuguese]
14. Souza FHC: Autoanticorpos em miopatias autoimunes. *Rev Paul Reumatol*, 2017; 16(4): 12–16
15. Satoh M, Tanaka S, Ceribelli A et al: A comprehensive overview on myositis-specific antibodies: New and old biomarkers in idiopathic inflammatory myopathy. *Clin Rev Allergy Immunol*, 2017; 52(1): 1–19
16. Marie I, Josse S, Hatron PY et al: Interstitial lung disease in anti-jo-1 patients with antisynthetase syndrome. *Arthritis Care Res (Hoboken)*, 2013; 65(5): 800–8
17. Hengstman GJD, Ter Laak HJ, Vree Egberts WTM et al: Antisignal recognition particle autoantibodies: Marker of a necrotizing myopathy. *Ann Rheum Dis*, 2006; 65: 1635–38
18. Picard C, Thierry Vincent T, Lega JC et al: Heterogeneous clinical spectrum of anti-SRP myositis and importance of the methods of detection of anti-SRP autoantibodies: A multicentric study. *Immunol Res New York, Springer*, 2016
19. Musset L, Allenbach Y, Benveniste O et al: Anti-HMGCR antibodies as a biomarker for immune-mediated necrotizing myopathies: A history of statins and experience from a large international multi-center study. *Autoimmun Rev*, 2016; 15(10): 983–93
20. Albayda J, Christopher-Stine L: Identifying statin-associated autoimmune necrotizing myopathy. *Cleve Clin J Med*, 2014; 81(12): 736–41
21. Herbert MK, Stammen-Vogelzangs J, Verbeek MM et al: Disease-specificity of autoantibodies to cytosolic 5'-nucleotidase 1A in sporadic inclusion body myositis versus known autoimmune diseases. *Ann Rheum Dis*, 2016; 75(4): 696–701
22. Ghillani P, André C, Toly C et al: Clinical significance of anti-Ro52 (TRIM21) antibodies non-associated with anti-SSA 60 kDa antibodies: Results of a multicentric study. *Autoimmun Rev*, 2011; (10): 509–13
23. Lefèvre G, Meyer A, Launay D et al: Seronegative polyarthritis revealing antisynthetase syndrome: a multicentre study of 40 patients. *Rheumatology (Oxford)*, 2015; 54: 927–32
24. Meyer A, Lefevre G, Biery G et al: Antisynthetase syndrome, ACPA are associated with severe and erosive arthritis – An overlapping rheumatoid arthritis and antisynthetase syndrome. *Medicine (Baltimore)*, 2015; 94(20): e523
25. Morrisset J, Johnson C, Rich E et al: Management of myositis-related interstitial lung disease. *Chest*, 2016; 150(5): 1118–28