


## Case Report

# Adrenocortical carcinoma with inferior vena cava tumor thrombus found during surgery

Yuta Nabeshima,<sup>1</sup> Shimpei Yamashita,<sup>1</sup>  Ryusuke Deguchi,<sup>1</sup> Ryuta Iwamoto,<sup>2</sup> Kenji Warigaya,<sup>2</sup> Hiroyuki Koike,<sup>1</sup> Kazuro Kikkawa,<sup>1</sup> Yasuo Kohjimoto,<sup>1</sup> Shinichi Murata<sup>2</sup> and Isao Hara<sup>1</sup>

Department of <sup>1</sup>Urology and <sup>2</sup>Diagnostic Pathology, Wakayama Medical University, Wakayama, Japan

### Abbreviations & Acronyms

ACC = adrenocortical carcinoma  
CT = computed tomography  
IVC = inferior vena cava  
MRI = magnetic resonance imaging

**Correspondence:** Shimpei Yamashita M.D., Ph.D., Department of Urology, Wakayama Medical University, 811-1 Kimiidera, Wakayama 641-0012, Japan. Email: keito608@wakayama-med.ac.jp

### How to cite this article:

Nabeshima Y, Yamashita S, Deguchi R *et al.* Adrenocortical carcinoma with inferior vena cava tumor thrombus found during surgery. *IJU Case Rep.* 2022; 5: 362–365.

This is an open access article under the terms of the Creative Commons Attribution-NonCommercial-NoDerivs License, which permits use and distribution in any medium, provided the original work is properly cited, the use is non-commercial and no modifications or adaptations are made.

Received 3 February 2022;  
accepted 15 May 2022.  
Online publication 3 June 2022

**Introduction:** The safety and efficacy of minimally invasive approaches for adrenocortical carcinoma with inferior vena cava tumor thrombus have not yet been established. We report a case of large adrenocortical carcinoma with inferior vena cava tumor thrombus found perioperatively which required conversion from a laparoscopic to an open procedure.

**Case presentation:** A 71-year-old woman with right-side 10-cm diameter adrenocortical carcinoma was scheduled for laparoscopic adrenalectomy. The operation was converted to open surgery, however, because inferior vena cava tumor thrombus, which was not detected by preoperative imaging modalities, was found during surgery.

**Conclusion:** In patients with large adrenocortical carcinoma, the possible presence of inferior vena cava thrombus should be considered when selecting surgical procedures.

**Key words:** adrenocortical carcinoma, inferior vena cava, laparoscopic surgery, open conversion, tumor thrombus.

## Keynote message

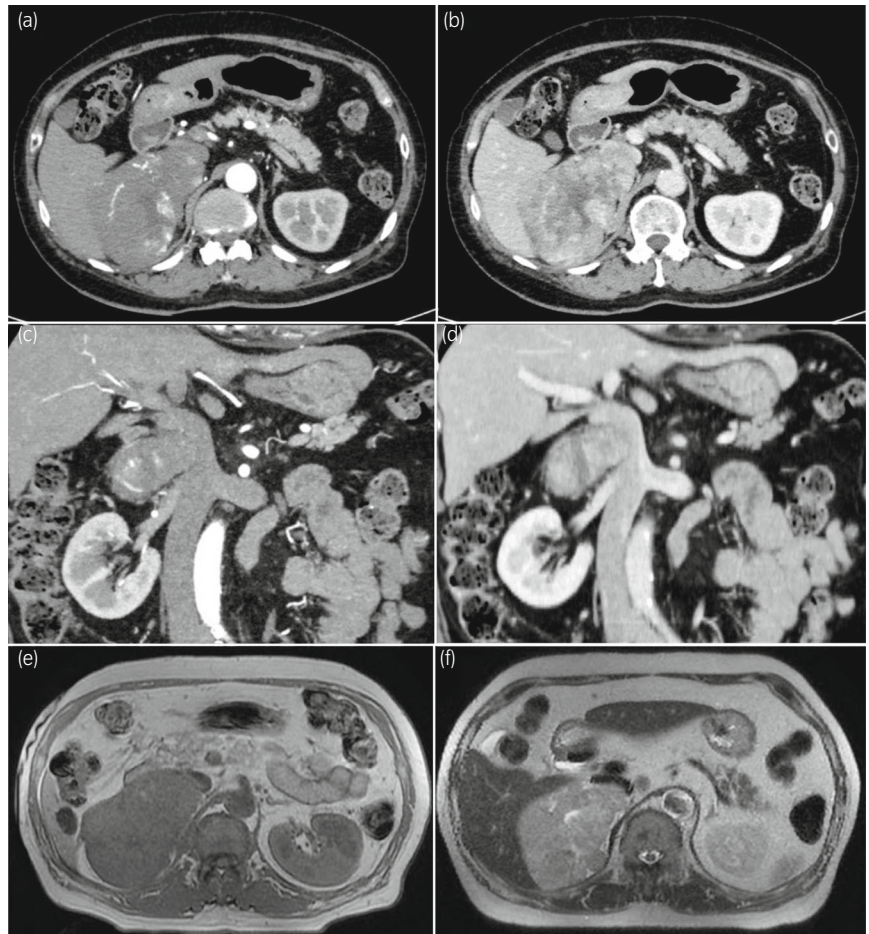
Laparoscopic surgery was initially planned for a 71-year-old woman with adrenocortical carcinoma. Inferior vena cava tumor thrombus was found perioperatively, so the operation was converted to open surgery. In patients with large adrenocortical carcinoma, the presence of inferior vena cava tumor thrombus should be considered.

## Introduction

ACC is a rare neoplasm associated with poor prognosis.<sup>1,2</sup> IVC tumor thrombus has reported incidence of 10% in patients with ACC.<sup>3</sup> Open adrenalectomy has traditionally been recommended as the standard surgical procedure for ACC, but there is recent increase in the frequency of minimally-invasive approaches, such as laparoscopic and robotic surgery.<sup>4</sup> However, the safety and efficacy of these minimally invasive approaches for ACC with IVC tumor thrombus have not yet been established. We report a case of ACC that required conversion from laparoscopic to open procedure due to perioperatively detected IVC tumor thrombus, with discussion of the optimal choice of surgical methods for ACC.

## Case presentation

A 71-year-old woman was presented with pollakiuria. Physical examination revealed increased density of eyebrows and pubic hair, and pitting edema in her legs. In laboratory analysis, serum cortisol was 18.3 µg/dL, plasma adrenocorticotrophic hormone was 1.0 pg/mL, and plasma dehydroepiandrosterone sulfate was 4452 µg/dL. Endocrinologic investigation revealed disappearance of circadian change of serum cortisol and the loss of suppressibility of serum cortisol by dexamethasone, suggesting Cushing's syndrome. Enhanced abdominal CT scan showed a 10-cm right-side adrenal mass with heterogeneous enhancement (Fig. 1a–d). Although the mass compressed the IVC, CT images did not detect IVC tumor thrombus. MRI showed the mass was a hypointense lesion on T1-weighted image and



**Fig. 1** Preoperative enhanced CT images (a: axial/early phase, b: axial/late phase, c: coronal/early phase, and d: coronal/late phase) and MRI images (e: T1-weighted image and f: T2-weighted image).

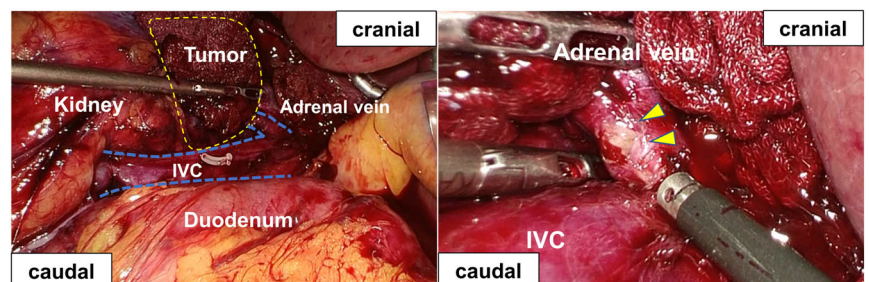
hyperintense lesion on T2-weighted image (Fig. 1e,f). MRI images also failed to show the IVC tumor thrombus. On  $^{131}\text{I}$ -adosterol scintigraphy, the right adrenal gland was associated with low uptake. From these observations, there was preoperative suspicion of ACC with Cushing's syndrome and the clinical stage was determined as cT2N0M0.

Laparoscopic adrenalectomy was initially attempted, although after soft tissues around right adrenal vein was removed, tumor thrombus was found in the vein (Fig. 2). Ultrasonography revealed that tumor thrombus slightly extended to the IVC. The operation was therefore converted from laparoscopic to open approach by making an inverted L-shaped skin incision which connected three laparoscopic ports on the right upper abdomen. After clamping the IVC at the head side and the tail side of the right adrenal vein, we performed open adrenalectomy and removal of IVC

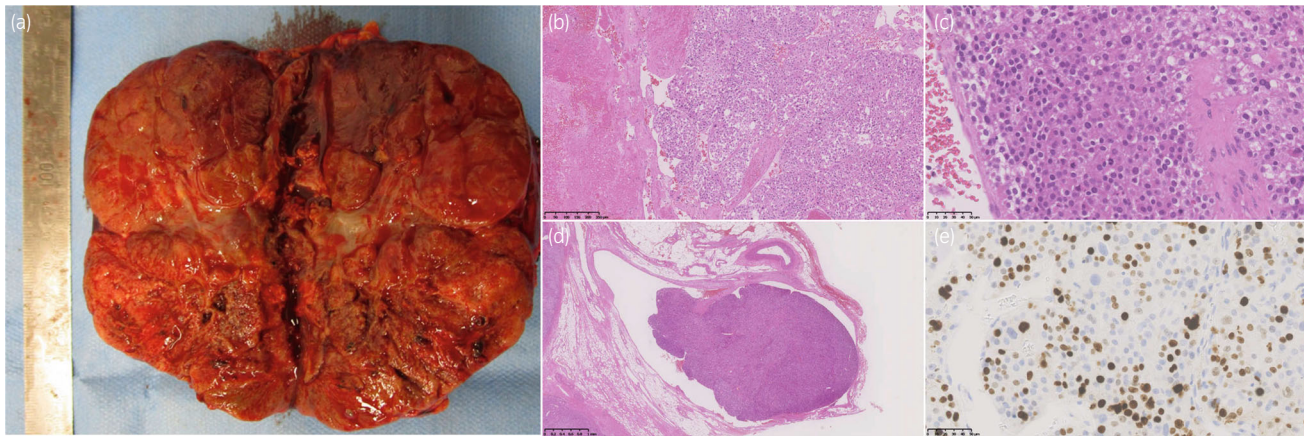
tumor thrombus. The defect of IVC was continuously sutured using 5-0 prolene (Ethicon, Somerville, NJ, USA). Histological examination revealed that the mass was an adrenal cortical neoplasm with extension to the IVC, the Weiss score was 7 and the Ki-67 proliferation index was high, more than 60% (Fig. 3). The patient was therefore diagnosed with ACC with the pathological stage pT4N0M0. Although she underwent adjuvant mitotane treatment, positron emission tomography scan showed recurrence in the liver 4 months postoperatively.

## Discussion

ACC is associated with poor prognosis, and the 5-year survival rate in patients with ACC is reported to be 16–35%.<sup>5,6</sup> Laan *et al.* reported that the 5-year survival rate in patients



**Fig. 2** IVC tumor thrombus found during surgery. The arrowheads indicate tumor thrombus.



**Fig. 3** Macroscopic image (a) and histologic findings of the tumor (b–e). H&E stain, original magnification:  $\times 200$  (b),  $\times 400$  (c), and  $\times 20$  (d). The immunohistochemical staining of cancer cells was positive for MIB1 (e).

**Table 1** Summary of reported cases in Japan and the present case

	Reported cases in Japan ( $n = 14$ )	Present case
Age	Median 40 years (range: 26–74 years)	71 years
Gender	Male: 6 cases, female 8 cases	Female
Tumor side	Right 11 cases, left 3 cases	Right
Tumor size	Median 11 cm (range: 8–18 cm)	11 cm
Initial surgical method	Open	Laparoscopic
Level of tumor thrombus	Infrahepatic: 5 cases Suprahepatic Infra-right atrium: 3 cases Supra-right atrium: 5 cases Unknown: 1 case	Infrahepatic

with ACC involving IVC tumors was 0%.<sup>7</sup> To our knowledge, 14 patients with ACC and IVC tumor thrombus have been reported in Japan (Table 1). The median tumor size was 11 cm (range: 8–11 cm). Most patients were affected on the right side (79%) due to the anatomy of the adrenal vein. All patients underwent open radical adrenalectomy with resection of IVC thrombus. In the present case, laparoscopic procedures were initially attempted, but a switch to open surgery was required due to IVC tumor thrombus being found during surgery.

European Network for the Study of Adrenal Tumor guidelines recommend open surgery for patients with ACC with local invasion.<sup>8</sup> For ACC without local invasion, the surgical method is determined according to the size of the tumor. Laparoscopic adrenalectomy is recommended for tumors  $\leq 6$  cm, but there are no definitely established guidelines for the choice of laparoscopic surgery or open surgery for tumors  $> 6$  cm. Meanwhile, Sgourakis *et al.* recently compared surgical outcomes between open and laparoscopic surgery in patients with ACC  $< 10$  cm without local invasion; perioperative outcomes in the laparoscopic group were better than those in open surgery group without difference between the groups in oncological outcomes.<sup>9</sup> However, the efficacy and safety of laparoscopic surgery for ACC  $\geq 10$  cm have not been specifically reported. Moreover, ACC with

IVC thrombus tend to be large in size, as shown in Table 1. The presence of IVC thrombus is an important factor when selecting surgical methods, so IVC thrombus should ideally be detected preoperatively, especially in patients with large right-sided ACC. However, preoperative diagnosis of the presence of IVC tumor thrombus is difficult by using conventional imaging techniques including abdominal CT scan because the IVC can be compressed by large tumors, like in the present case.<sup>10</sup> The usefulness of intracaval endovascular ultrasonography or enhanced MRI for preoperative detection of IVC thrombus has been previously reported,<sup>10,11</sup> but further investigation is required owing to limited evidence.

The efficacy and safety of laparoscopic or robot assisted surgery have been recently reported for advanced renal cell carcinoma with IVC tumor thrombus.<sup>12,13</sup> To our knowledge, however, there are no reports about the outcomes of these minimally-invasive surgical techniques for ACC with IVC thrombus. The wall of the adrenal vein is thinner and weaker than that of the renal vein. Tumor thrombus of the ACC has been reported to have higher risk of pulmonary infarction than that of renal cell carcinoma because it is gelatinous and vulnerable.<sup>14</sup> Considering these backgrounds, there must be careful consideration of the application of laparoscopic or robotic surgery to the ACC with IVC thrombus.

We therefore propose the following surgical methods for ACC: when local invasion of tumors is suspected from preoperative CT images, open procedure should be selected. When local invasion is not suspected, although laparoscopic surgery should be initially selected for tumors  $< 10$  cm, IVC thrombus should be re-evaluated using intraoperative ultrasonography. If thrombus is detected during surgery, the surgical procedure should be converted to open procedure. For tumors  $\geq 10$  cm, preoperative intracaval endovascular ultrasonography or enhanced MRI should be used to evaluate the presence of tumor thrombus. If IVC tumor thrombus is observed, open procedure should be selected. If IVC tumor thrombus is not detected, we recommend performing laparoscopic procedure and reevaluating the presence of tumor thrombus during surgery with intraoperative ultrasonography in the same way as for tumors  $< 10$  cm.

## Conclusion

In patients with large ACC, especially >10 cm, surgical procedures should be performed with consideration of potential for IVC thrombus.

## Acknowledgments

This document was proof-read and edited by Benjamin Phillis at the Clinical Study Support Center at Wakayama Medical University.

## Author contributions

Yuta Nabeshima: Conceptualization; data curation; writing – original draft. Shimpei Yamashita: Software; visualization; writing – original draft. Ryusuke Deguchi: Conceptualization; data curation. Ryuta Iwamoto: Data curation. Kenji Wari-gaya: Data curation. Hiroyuki Koike: Data curation. Kazuro Kikkawa: Supervision. Yasuo Kohjimoto: Supervision. Shini-chi Murata: Supervision. Isao Hara: Supervision; writing – review and editing.

## Conflict of interest

The authors declare no conflict of interest.

## Approval of the research protocol by an Institutional Reviewer Board

N/A.

## Informed consent

N/A.

## Registry and the Registration No. of the study/trial

N/A.

## References

- 1 Allolio B, Fassnacht M. Clinical review: adrenocortical carcinoma: clinical update. *J. Clin. Endocrinol. Metab.* 2006; **91**: 2027–37.
- 2 Else T, Kim AC, Sabolch A *et al.* Adrenocortical carcinoma. *Endocr. Rev.* 2014; **35**: 282–326.
- 3 Nader S, Hickey RC, Sellin RV, Samaan NA. Adrenal cortical carcinoma. A study of 77 cases. *Cancer* 1983; **52**: 707–11.
- 4 Calcaterra NA, Hsiung-Wang C, Suss NR, Winchester DJ, Moo-Young TA, Prinz RA. Minimally invasive adrenalectomy for adrenocortical carcinoma: five-year trends and predictors of conversion. *World J. Surg.* 2018; **42**: 473–81.
- 5 Ng L, Libertino JM. Adrenocortical carcinoma: diagnosis, evaluation and treatment. *J. Urol.* 2003; **169**: 5–11.
- 6 Schulick RD, Brennan MF. Adrenocortical carcinoma. *World J. Urol.* 1999; **17**: 26–34.
- 7 Laan DV, Thiels CA, Glasgow A *et al.* Adrenocortical carcinoma with inferior vena cava tumor thrombus. *Surgery* 2017; **161**: 240–8.
- 8 Gaujoux S, Mihai R. European Society of Endocrine Surgeons (ESES) and European network for the study of adrenal Tumours (ENSAT) recommendations for the surgical management of adrenocortical carcinoma. *Br. J. Surg.* 2017; **104**: 358–76.
- 9 Sgourakis G, Lanitis S, Kouloura A *et al.* Laparoscopic versus open adrenalectomy for stage I/II adrenocortical carcinoma: meta-analysis of outcomes. *J. Invest. Surg.* 2015; **28**: 145–52.
- 10 Kikumori T, Imai T, Kaneko T *et al.* Intracaval endovascular ultrasonography for large adrenal and retroperitoneal tumors. *Surgery* 2003; **134**: 989–93. discussion 93–4.
- 11 Zini L, Porpiglia F, Fassnacht M. Contemporary management of adrenocortical carcinoma. *Eur. Urol.* 2011; **60**: 1055–65.
- 12 Shao P, Li J, Qin C *et al.* Laparoscopic radical nephrectomy and inferior vena cava thrombectomy in the treatment of renal cell carcinoma. *Eur. Urol.* 2015; **68**: 115–22.
- 13 Masic S, Smaldone MC. Robotic renal surgery for renal cell carcinoma with inferior vena cava thrombus. *Transl. Androl. Urol.* 2021; **10**: 2195–8.
- 14 Moul JW, Hardy MR, McLeod DG. Adrenal cortical carcinoma with vena cava tumor thrombus requiring cardiopulmonary bypass for resection. *Urology* 1991; **38**: 179–83.