

# “Dancing Coins?” Unexpected Finding During microsurgery and Potential Risk of Sperm Damage: Intrascrotal Calculi: A Retrospective Analysis

Huang Liu<sup>1,\*</sup>, Zhixing Zhang<sup>2,\*</sup>, Wei Lv<sup>3</sup>, Qianyi Li<sup>1</sup>, Zhaohui Qing<sup>3</sup>, Xiaolin Zhong<sup>4</sup>, Shaoqin Peng<sup>3</sup>, Hai Lin<sup>1</sup>, Houbin Zheng<sup>1</sup>

<sup>1</sup>Department of Andrology, NHC Key Laboratory of Male Reproduction and Genetics, Guangdong Provincial Reproductive Science Institute (Guangdong Provincial Fertility Hospital), Human Sperm Bank of Guangdong Province, Guangzhou, People's Republic of China; <sup>2</sup>Department of Ultrasonography, NHC Key Laboratory of Male Reproduction and Genetics, Guangdong Provincial Reproductive Science Institute (Guangdong Provincial Fertility Hospital), Human Sperm Bank of Guangdong Province, Guangzhou, People's Republic of China; <sup>3</sup>Department of Anesthesiology, NHC Key Laboratory of Male Reproduction and Genetics, Guangdong Provincial Reproductive Science Institute (Guangdong Provincial Fertility Hospital), Human Sperm Bank of Guangdong Province, Guangzhou, People's Republic of China; <sup>4</sup>Inpatient Department, NHC Key Laboratory of Male Reproduction and Genetics, Guangdong Provincial Reproductive Science Institute (Guangdong Provincial Fertility Hospital), Human Sperm Bank of Guangdong Province, Guangzhou, People's Republic of China

\*These authors contributed equally to this work

Correspondence: Houbin Zheng, Email zhenghoubin@126.com

**Objective:** Microsurgery of andrology always brings unexpected findings. Scrotal calculi are rare and unique, which are easily confused with tumor. To understand its etiology and harm, our study retrospectively analyzed the clinical characteristics of men with scrotal calculi to provide a reference for clinical practice.

**Methods:** The clinical data of patients who underwent microscopic testicular sperm extraction (MTESE) and microscopic epididymal sperm aspiration (MESA) from January 1, 2018 to December 31, 2021 were retrospectively analyzed. Data screening was performed on cases in which calculi were found or not, and the relationship between calculi and spermatogenesis was analyzed.

**Results:** A total of 405 patients were recruited. After screening, 218 nonobstructive azoospermia (NOA), 83 obstructive azoospermia (OA), and 13 cryptozoospermia (CZ) patients were included in the study. Calculi were found in 3 patients [incidence was 0.74% (3/405)], in which 2 patients had obstructive azoospermia (1 was epididymal calculi, 1 was intrascrotal calculi) and 1 patient had cryptozoospermia (intrascrotal calculi). Pathological results showed that chronic granuloma with abscess infiltration appeared in epididymal tissue, basement membrane thickening and fibrosis appeared in seminiferous tubules, and fibrous hyperplasia with calcium deposition was found in scrotal calculus. White blood cells, lymphocytes, red blood cells, abstinence time and urethritis were closely related to the occurrence of calculi. While abstinence time might be a potential predictor, which increased the risk by approximately 1.2 times.

**Conclusion:** Disturbance of the testicular microenvironment caused by lymphocyte infiltration may be the main reason for scrotal calculi and ultimately cause spermatogenesis disorders. Prolonged sexual abstinence was a potential risk.

**Keywords:** intrascrotal calculi, azoospermia, cryptozoospermia, testicular microenvironment, lymphocyte infiltration, prolonged sexual abstinence, tumour

## Introduction

The application of microsurgery has promoted the development of andrology. Many abnormal phenomena found on imaging have been verified and confirmed in microsurgery. Scrotal calculi are known as “pearls” in the scrotum, with an

incidence of 2.65% in 868 patients.<sup>1,5</sup> They have large morphological differences, are rarely diagnosed in vitro and are easily misdiagnosed as tumors.<sup>2-4</sup> Scrotal microsurgery is a good method for differentiation and diagnosis.

Intrascrotal calculi are considered to originate from fibrin, meconium or inflammatory crystal deposits, which are similar to urolithiasis but with an uncertain relationship.<sup>1</sup> Some have reported that intrascrotal calculi are small yellow particles, small chips or larger shapes.<sup>2-4</sup> Most of them were irregular, and only some were round pearls.<sup>5</sup> Their main components are carbonate or phosphate.<sup>6</sup> Some studies have found that these intrascrotal calculi lead to a decline in sperm parameters.<sup>7,8</sup> Other studies also revealed that these interesting things were closely related to testicular tumors.<sup>9</sup> However, due to the low incidence of intrascrotal calculi and the lack of relevant literature, the impact of intrascrotal calculi on sperm is unclear.

In the past 3 years, from 2018 to 2021, several cases of intrascrotal calculi with unique features and similar to “Dancing coins” or ‘Jade gourd’ were found. The patients also had abnormal spermatogenesis in reproduction, which aroused our interest. Therefore, to clarify and explore its mechanism and analyze the correlation with spermatogenesis, we conducted a retrospective analysis of patients with scrotal calculi found undergoing microsurgery in andrology and found new evidence to support scrotal calculi affecting spermatogenesis, which may provide a reference for clinical practice.

## Patients and Methods

### Patients

We retrospectively analyzed the clinical data of all patients who underwent 3D microscopic testicular sperm extraction (MTESE) and microscopic epididymal sperm aspiration (MESA) at Guangdong Provincial Fertility Hospital from January 1, 2018, to December 31, 2021. The inclusion criteria were as follows: (1) at least two complete examinations [including physical examination, routine semen analysis, seminal plasma biochemical analysis, blood cell analysis, reproductive hormones, chromosome, Azoospermia factor (AZF) gene and scrotal ultrasound] were performed before surgery. (2) Complete surgical records, intraoperative images or videos should be provided during the operation. (3) Postoperative histopathological examination. The exclusion criteria were as follows: (1) varicocele. (2) Deletion of AZF gene. (3) Chromosomal abnormalities, such as 47, XXY, etc. (4) Cryptorchidism. (5). Absence of vas deferens.

### Methods

All cases were classified and screened according to relevant criteria to determine the final inclusion of the case. According to clinical diagnosis, all patients were divided into three categories: obstructive azoospermia, nonobstructive azoospermia and cryptozoospermia. According to the corresponding inclusion criteria and exclusion criteria, screening was carried out one by one, such as congenital absence of vas deferens, iatrogenic injury, varicocele, AZF gene deletion, chromosome abnormality (47, XXY, etc.), cryptorchidism, etc. For all included cases, age, infertility time, lifestyle, medical history, examination and test results, surgical images or video, and pathological results were compared. This study was approved by the ethics committee of Guangdong Provincial Reproductive Science Institute (Guangdong Provincial Fertility Hospital) (Approval number: 2021 [05]). All patients signed informed consent before the surgery.

### Microsurgery

Under general anesthesia with endotracheal intubation, the scrotal midline was selected as a longitudinal incision to cut the skin. The subcutaneous fascia and testicular sheath were separated to expose the testis and epididymis. Microscopic testicular sperm extraction (MTESE) and microscopic epididymal sperm aspiration (MESA) were performed by using an ultrahigh-definition operating microscope (Vario/S88, Zeiss, Germany). The full seminiferous tubules or epididymis fluid were collected to observe the sperm parameters under an inverted microscope (Nikon, Japan, TI-U/B).

### Statistical Analysis

SPSS 19.0 (IBM, Version 19.0, USA) was used for the data. Descriptive statistics were performed. The counting data were expressed as the adoption rate or percentage (%), and the measurement data were expressed in the form of the mean

( $\bar{x}$ )  $\pm$  standard deviation (s.d.). The Mantel test was used for correlation studies. Univariate logistic regression analysis was used to explore the risk factors.

## Results

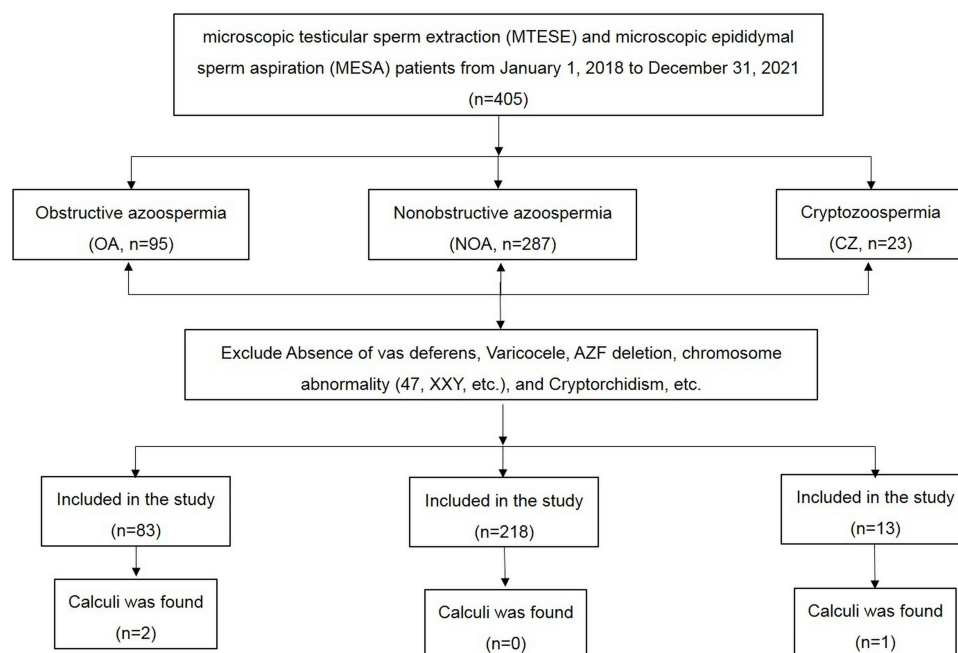
### Patient Screening Process in the Study

A total of 405 patients were collected, aged from 19 to 52 years, with an average of  $32.93 \pm 5.62$  years, and the infertility time was 1 to 6 years, with an average of  $2.79 \pm 1.18$  years, including 95 cases of obstructive azoospermia, 287 cases of nonobstructive azoospermia and 23 cases of cryptozoospermia. After screening according to the exclusion criteria, 83 cases of obstructive azoospermia, 218 cases of nonobstructive azoospermia and 13 cases of cryptozoospermia were included. Stones were found in 2 patients with obstructive azoospermia (1 was epididymal calculi with the shape “golden coins”, 1 was intrascrotal calculi with the shape ‘jade gourd’) and 1 patient with cryptozoospermia (with the shape “jade gourd” of tooth marks) (Figure 1).

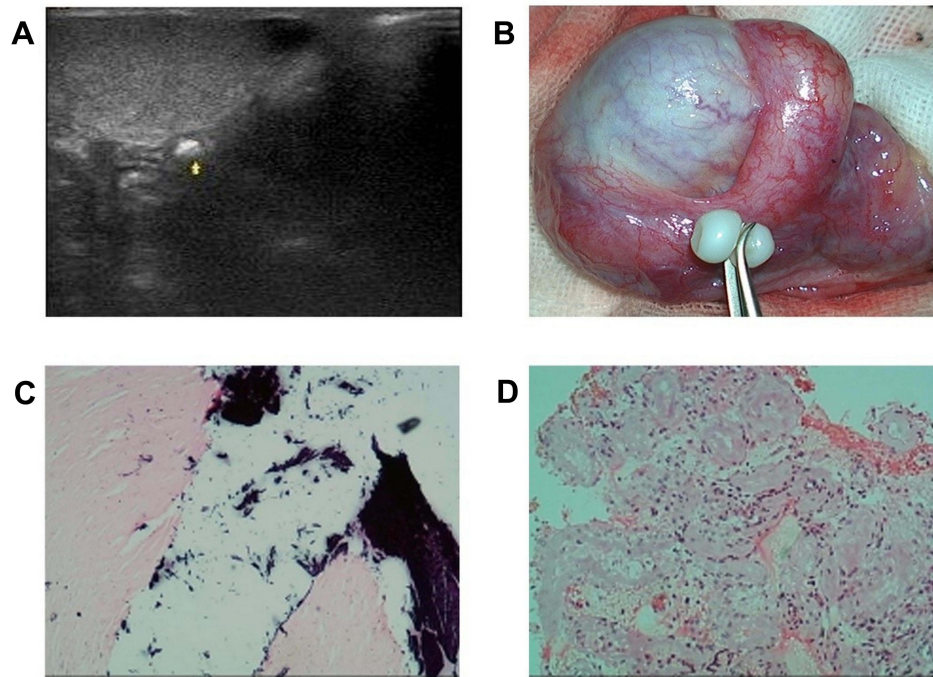
### Characteristics of Patients with Calculi

#### Case 1

“Jade gourd” was found in a 37-year-old patient who was admitted to the hospital from August 3, 2018, to August 8, 2018, due to fertility difficulties after 3 years of marriage with a normal sexual life. The man had a normal past history, without a special family history or bad habits and hobbies, and had an abnormal personal history, and no definite cause of infertility was found in his wife. Physical examination showed that a nodule could be touched in the left epididymis tail without tenderness and poor mobility and with a clear boundary and hard texture. 3D ultrasonic examination showed a strong echo mass of approximately  $8 \times 7$  mm in the epididymal head (Figure 2A). His clinical diagnosis was cryptozoospermia. To cooperate with his wife for intracytoplasmic sperm injection (ICSI), he was hospitalized for microscopic testicular sperm extraction to find more and better sperm. During the operation, a  $5 \text{ mm} \times 5 \text{ mm} \times 5 \text{ mm}$  small white interesting stone with a smooth surface and “jade gourd” shape in the recess of the connecting part between the left epididymal tail and the vas deferens was found (Figure 2B). Pathological findings: ① Stone: Calcareous deposits could be seen in the mechanically denatured fibrous tissue, which was consistent with idiopathic calcinosis (Figure 2C). ② Testicular tissue: Approximately 150 seminiferous tubules were found, the basement membrane of seminiferous



**Figure 1** Patient screening process.



**Figure 2** Clinical image of case 1, (A), 3D ultrasound image; (B), The “jade gourd”-shaped stone during the surgery. (C), Calculus pathology; (D), Testicular histopathology.

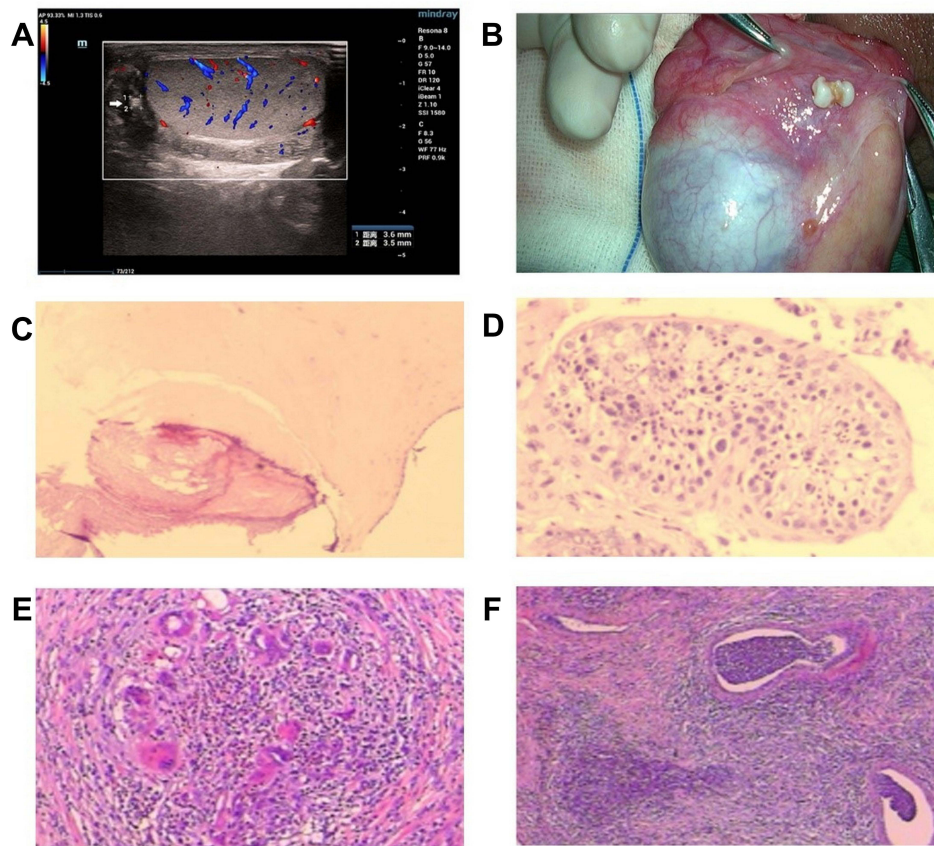
tubules was thickened, transparent and degenerative, and interstitial fibrosis was observed. Only a small number of proliferating Sertoli cells in the seminiferous tubules were lodged, without spermatogenic cells, sperm cells or sperm. This was considered a Sertoli cell-only syndrome, with a Johnson score of 1–2<sup>10</sup> (Figure 2D).

### Case 2

“Dancing coins” were found in a 26-year-old man who was admitted to the hospital from March 6, 2019, to March 12, 2019, due to fertility difficulties after 1 year of marriage with a normal sexual life. He had an unexplained history of scrotal swelling and pain in adulthood, but that returned naturally without treatment. He had no history of trauma or surgery or no special family history, he had masturbation habits, but he had no habit of smoking, drinking or drug addiction, and his wife was healthy. Physical examination showed that the epididymis was thickened. 3D ultrasonic examination showed that both sides of the epididymis were thickened, approximately 6 mm, and the epididymis canal was tortuously shaped, with a thickness of approximately 1 mm. There were strong echoes of light and shadow with varying sizes flowing along the epididymis canal. (Video 1). The clinical diagnosis was obstructive azoospermia. To obtain sperm and recanalize the sperm output path, vasoepididymostomy and microscopic epididymal sperm aspiration (MESA) were performed. Numerous small “golden coin” shape calculi were found in the epididymis (Video 2). Microscopic examination revealed the following: ① Stone: Granular calcium was found in the samples. ② Epididymis liquid: A large number of motile sperm were found in epididymal fluid under the microscope.

### Case 3

A “Jade gourd” with tooth marks was found in a 38-year-old man who was admitted to the hospital from May 15, 2021, to June 7, 2021, due to repeated scrotal swelling and pain for approximately 60 days. Since the middle of March, he had dull pain on one side of the scrotum without obvious inducement, which occurred repeatedly and did not improve after taking drugs irregularly. He was hospitalized in the hospital on April 10, 2021, and improved after conservative treatment. However, another serious attack occurred on May 12, so he was hospitalized. He had married for 4 years, and no definite cause of infertility was found in his wife, but it was difficult to have a baby. Past history, personal history and family history were not unique. Physical examination showed that the epididymis was thickened, and a thumb-sized hard nodule could be touched in the head of the right epididymis without tenderness and poor mobility. 3D ultrasonic examination showed that the bilateral testes were



**Figure 3** Clinical image of case 3, (A), 3D ultrasound image; (B), The “Jade gourd” shape with tooth marks stone during the surgery. (C), Calculus pathology; (D), Testicular histopathology. (E), Inflammatory cells in epididymis tissue, (F), Inflammatory abscess in epididymis tissue.

approximately 42×25 x 30 mm. A small effusion was observed in the right scrotum. The epididymis head was approximately 11 mm, and the body was approximately 7 mm. A hyperechoic nodule shadow could be seen at the head of the right epididymis, approximately 3.6×3.5 mm (Figure 3A) (Video 3). The clinical diagnosis was as follows: “1. Epididymitis, 2. Obstructive azoospermia”. After admission to control inflammation, testicular accessory exploration and microscopic epididymal sperm aspiration (MESA) were performed to obtain sperm and recover the sperm transfusion. A special white yellow “Jade gourd” with tooth mark-shaped stones could be seen in the depression at the connection between the left epididymal tail and the vas deferens during the surgery (Figure 3B) (Video 4). Pathological findings: ① Stone: Fibrous tissue hyperplasia and local calcification were found. Pathological diagnosis: Fibrous tissue hyperplasia and local calcification (Figure 3C). ② Testicular tissue: 30 seminiferous tubules were found, the basement membrane of seminiferous tubules was slightly thickened, and primary spermatocytes, secondary spermatocytes, sperm cells and sperm were found in the lumen (10 < number of sperm < 20/cross-section of seminiferous tubules). This was considered low testicular spermatogenic function (mild) and a Johnsen score of 8–9 (Figure 3D). ③ Epididymis tail mass: The tissue was infiltrated with acute and chronic inflammatory cells (Figure 3E), multinucleated giant cells were seen locally, presenting chronic granulomatous inflammatory changes, and some abscesses were formed (Figure 3F).

## Comparison of Clinical Characteristics

Detailed clinical data (including physical examination, genetic analysis, routine blood analysis, reproductive hormones, routine urine analysis, semen analysis, seminal plasma biochemical analysis, microbial culture, ultrasound and pathology results) of the patients with calculi and without calculi in the study were compared (Table 1).

**Table 1** Comparison of Clinical Characteristics

Indicators	Obstructive Azoospermia		Cryptozoospermia	
	Calculi (n=2)	Normal (n=81)	Calculi (n=1)	Normal (n=12)
General characteristics				
Age (years)	31.50±6.50	32.96±5.68	37	32.33±4.97
Infertility time (years)	2.50±1.50	2.74±1.16	3	3.17±1.21
Medical history				
Mumps (n)	0	0	0	5
Orchitis (n)	1	42	0	0
Urethritis (n)	2*	12*	0	2
Habit				
Masturbation (n)	1	19	0	7
Stay up late (n)	2	33	1	9
Physical examination				
Testicular volume (mL)	15.00	14.16±2.31	10	8.83±2.64
Redundant prepuce (n)	1	27	1	4
Genetic				
Chromosome	46, XY	46, XY	46, XY	46, XY
AZF deletion (Y/N)	N	N	N	N
Blood Rt				
WBC ( $\times 10^9/L$ )	10.20±1.40*	7.28±1.68*	5.9	7.41±1.67
Neutrophils ( $\times 10^9/L$ )	6.00±1.50	4.30±1.35	2.95	4.54±1.37
Neutrophils (%)	57.60±6.90	57.75±9.79	49.9	55.97±12.94
Lymphocyte ( $\times 10^9/L$ )	3.25±0.05*	2.19±0.70*	2.37	2.23±0.53
Lymphocyte (%)	32.25±5.05	30.69±8.28	40	30.88±6.68
RBC ( $\times 10^9/L$ )	4.62±0.36	5.28±0.46	5.29	4.97±0.24
Hemoglobin	151.00±12.00	156.06±11.37	143	151.67±6.25
Platelet	184.50±42.50	244.90±49.06	320	271.08±52.46
Hormones				
FSH (mIU/mL)	5.94±2.15	7.53±7.48	56.08	23.28±15.05
LH (mIU/mL)	4.01±1.11	5.64±3.46	23.57	10.51±7.06
P (pmol/L)	0.66±0.31	0.71±0.43	0.87	0.59±0.36
E <sub>2</sub> (pmol/L)	106.80±3.80	98.88±54.56	104	78.53±24.78
PRL (mIU/mL)	220.98±102.03	281.40±138.54	327.27	275.03±168.00
T (nmol/L)	16.98±1.16	16.05±7.05	12.4	12.24±4.29
Urine Rt				
LEU (n/uL)	8.00±8.00	9.99±49.55	0	1.17±2.73
BLD (n/uL)	1.00±1.00	1.93±4.72	0	0.42±0.76
KET (±)	-	±	0	0
Semen Rt				
AT (day)	17.50±12.50 <sup>Δ</sup>	5.05±3.99 <sup>Δ</sup>	7 <sup>Δ</sup>	3.67±0.94 <sup>Δ</sup>
SV (mL)	2.30±0.10	3.16±2.26	1.9	2.6±1.04
pH	8.05±0.15	7.87±0.52	8.4	7.93±0.31
SC (n/HP/mL)	0	0	2	2.58±1.11
MS (n/HP/mL)	0	0	1	0.42±0.49
Seminal P.				
α-glycosidase (U/L)	9.37±0.82	9.11±5.81	31.9	11.59±9.81
Citric acid (mmol/L)	17.62±4.42	31.03±34.92	21.78	26.97±33.12
Zinc (mmol/L)	2.55±1.03	3.61±2.29	2.76	3.82±2.53
Microbial				
NG positive (n)	0	0	0	0
UU positive (n)	1	17	0	5
CT positive (n)	0	0	0	0
MH positive (n)	0	2	0	0

**Note:** Comparison of calculi patients and normal patients \*P<0.05, <sup>Δ</sup>P<0.01.

**Abbreviations:** AZF, Azoospermia gene; WBC, White blood cells; RBC, Red blood cells; FSH, Follicular estrogen hormone; LH, Luteinizing hormone; PRL, Prolactin; P, Progesterone; E<sub>2</sub>, Estradiol; T, Testosterone; LEU, Urine leukocyte; BLD, Urine red blood cells; KET, Urine ketone body; AT, Sexual abstinence time; SV, Semen volume; pH, Semen pH value; SC, Sperm count; MS, Motile sperm; NG, Neisseria gonorrhoeae; UU, Ureaplasma urealyticum; CT, Chlamydia; MH, Mycoplasma hominis.

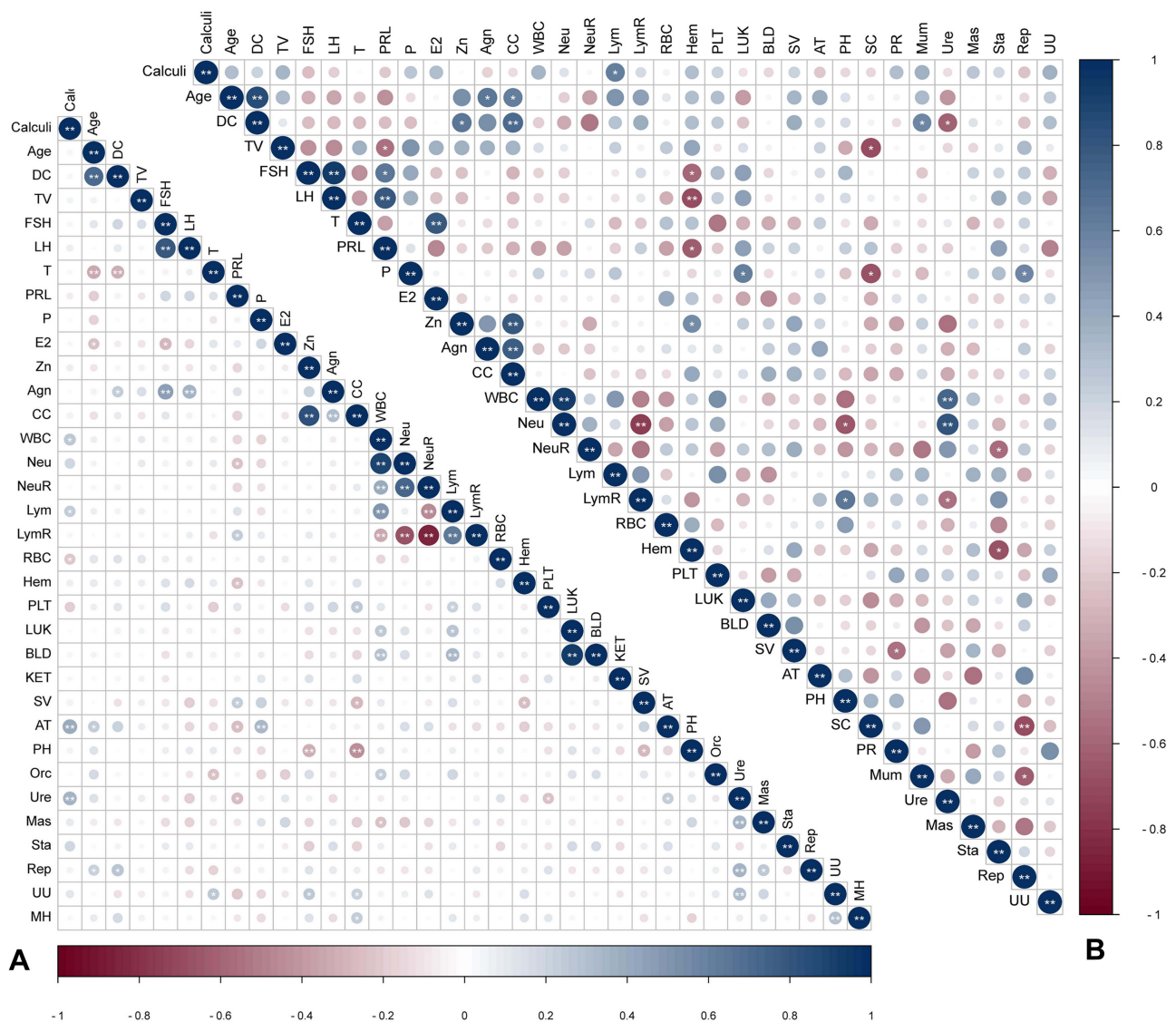
## Correlation Analysis

Pearson correlation analysis showed that the occurrence of calculi was closely related to white blood cell count ( $r=0.259$ ,  $p=0.018$ ), lymphocyte count ( $r=0.229$ ,  $p=0.037$ ), red blood cells ( $r=-0.216$ ,  $p=0.050$ ), urethritis ( $r=0.349$ ,  $p=0.001$ ) and abstinence time ( $r=0.3999$ ,  $p<0.001$ ) in the obstructive azoospermia group (Figure 4A), and the occurrence of calculi was also closely related to lymphocyte count ( $r=0.700$ ,  $p=0.008$ ) in the cryptozoospermia group (Figure 4B).

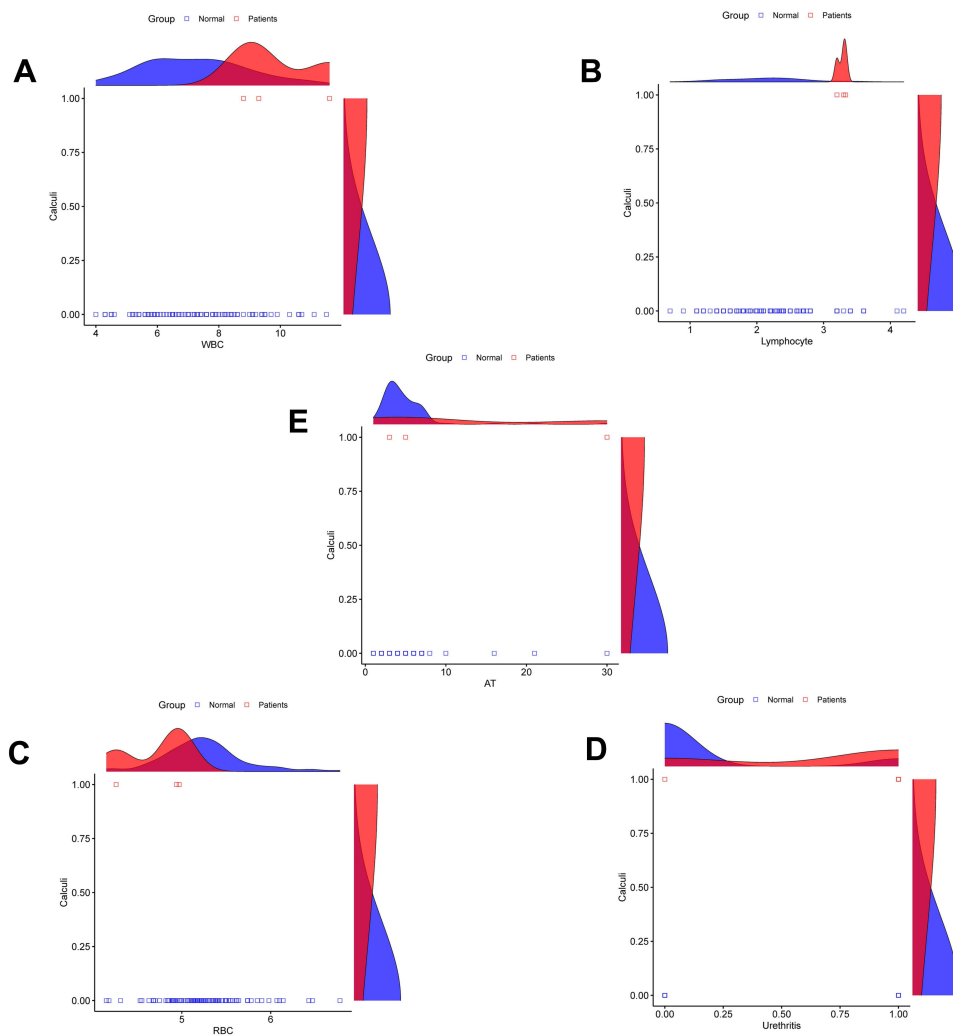
Univariate logistic regression analysis revealed that white blood cell count (Figure 5A), lymphocyte count (Figure 5B), red blood cells (Figure 5C) and urethritis (Figure 5D) did not significantly predict the risk of calculi, while sexual abstinence time was a potential factor for predicting the incidence of calculi (Figure 5E). Prolonged sexual abstinence increases the risk of stones by approximately 1.2 times (Table 2).

## Discussion

Intrascrotal calculi can occur at any age and have been found in 4-month-old infants and 75-year-old people.<sup>2</sup> The incidence of sphincter calculi is approximately 1.9%~9.6%,<sup>3,11,12</sup> However, in some specific populations, the incidence rate has significantly increased. In china, Zhang HM et al<sup>28</sup> found that the incidence rate would significantly increase in



**Figure 4** Pearson correlation analysis, (A), Correlation between calculi and other indicators in the obstructive azoospermia group. (B), Correlation between calculi and other indicators in the cryptozoospermia group. \*,  $p<0.05$ ; \*\*,  $p<0.01$ .



**Figure 5** Results of univariate logistic regression analysis.

**Note:** (A), Analysis results for WBC, (B), Analysis results for lymphocyte, (C), Analysis results for RBC, (D), Analysis results for Urethritis, (E), Analysis results for AT. **Abbreviations:** WBC, White blood cells; RBC, Red blood cells; AT, Abstinence time; 1, Calculi positive; 0, Calculi negative.

specific male populations such as repeated chronic trauma, scrotal diseases, primary infertility or exposure history of sexually transmitted diseases. In our study, the incidence was 0.74%, and the main reason was the characteristics of the population that we observed. According to the present literature, most scrotum calculi occur in infants and young children or elderly people,<sup>2</sup> but our observation group was mainly men of childbearing age, who were in the period of the

**Table 2** Univariate Logistic Regression Analysis

Indicators	B	S.E,	Wals	df	Sig.	Exp (B)	95% C.I. of EXP (B)	
							Upper Limit	Lower Limit
WBC	0.471	0.339	1.936	1	0.164	1.602	0.825	3.112
Lym	1.429	0.805	3.154	1	0.076	4.175	0.862	20.210
RBC	-2.199	1.438	2.339	1	0.126	0.111	0.007	1.857
Ure	2.424	1.259	3.708	1	0.054	11.286	0.958	133.001
AT	0.149	0.061	5.987	1	0.014*	1.160	1.030	1.307

**Note:** \*, P<0.05.

**Abbreviations:** WBC, White blood cells; RBC, Red blood cells; Lym, Lymphocyte; AT, Sexual abstinence time; Ure, Urethritis.



most powerful vitality, and calculi were often caused by secondary factors. Therefore, we retraced the patients' past medical history, personal history and lifestyle habits in detail. We found that urethritis was closely associated with the calculi; therefore, it should be taken seriously by males of childbearing age. Second, the small sample size may also be a major factor causing our low positive rate.

The clinical manifestations of calculus of the tunica vaginalis are different; most of them are asymptomatic, and some might show scrotal pain or mass,<sup>13</sup> especially with large stones. In 2005, a 93 year old man with 420g scrotal calculus had been reported in China.<sup>4</sup> Under ultrasound, most of them were hyperechoic masses. When there was a large amount of hydrocele, some could change with the change in body position. When the stones were small, they were not typical under ultrasound, and some could be seen with uneven echo. At this time, it needs to be distinguished from the tumors.<sup>14</sup> Most were found in physical examinations because of the need for childbearing. Our patients were both in the peak period of childbearing and in the concentrated age for finding stones. Therefore, when finding masses or nodules in the scrotum, the patient should be aware of the existence of stones and should be distinguished from other diseases to avoid misdiagnosis.

Previous studies found that most stones were small yellow crystals; thus far, there have been few cases with special shapes. Recently, Malouf et al discovered round pearl scrotal calculi through B-ultrasound.<sup>5</sup> These phenomena indicated that under the action of hydrocele, the stones might have special shapes, which made the men feel confused and adored. For our patient, the shape of the stones was more special. It might be one of the rarest in the world and look like a gourd baby with white and gelatinous. It was composed of two small spheres: the upper sphere was smaller, the lower sphere was larger, there were obvious concave marks at the middle junction, and the surface was smooth and reflective. According to the location of the stone, we speculated that its formation might be closely related to the flow of fluid in the tunica vaginalis. During the operation, we found that it was located in the depression of the right epididymis tail, which was close to the testis. When the hydrocele of the tunica vaginalis flowed here, the velocity slowed down and easily formed a whirling vortex, which caused the stress effect of the rotation of the effusion after the deposition of stones and played a similar role in polishing and forming an interesting shape of *Cucurbita pepo*. Therefore, we had to sigh the greatness and cleverness of human body fluid.

The pathogenesis and the cause of the formation of calculus were considered to be related to congenital and acquired factors. The congenital factor was that the remnants of the embryonic stage were calcified after being wrapped by testicular sheath fiber tissue. The acquired factor was inflammatory exudation of the testicular sheath caused by trauma and infection, which promoted the deposition of calcium, phosphorus, uric acid and other substances in the effusion.<sup>1,15,16</sup> In our cases, the patients denied a history of trauma or infection and ruled out the induction of inflammatory effusion; moreover, the pathological reports showed that the tissue was composed of organic fibrous tissue and calcium deposits. Therefore, we believe that these two cases were most likely caused by congenital factors combined with aseptic infection, which was mainly manifested in the following two aspects. First, the fibrous tissue wrapped the deposited calcium, stimulated the occurrence of aseptic inflammation, and promoted the stress response of the immune system, so typical effusion could be found in the sheath. Second, the bacterial culture results of the two cases showed no obvious infection process, but the infection symptoms of case 3 were typical. The source of this infection was probably aseptic inflammation. The inflammatory symptoms caused by autoimmune reactions led to obvious exudation, especially in the epididymis. The lymphocytes and leukocytes of patients with calculi were closely related to the occurrence of calculi, which also proved our judgment.

Do intrascrotal calculi cause risks other than pain? It was reported that testicular microlithiasis was related to a decrease in sperm parameters and led to unexplained infertility,<sup>17</sup> which was also reported in China.<sup>18</sup> However, whether intrascrotal calculi cause sperm abnormalities has not yet been confirmed. From our cases, spermatogenesis decreased to varying degrees. One was obstructive azoospermia, with slightly lower spermatogenic function, and the other was cryptozoospermia with serious spermatogenic damage. Combined with the changes in the epididymis, we highly suspected that intrascrotal calculi might cause aseptic inflammation in the scrotum, resulting in increased exudative secretion and pressure in the epididymal canal, causing epididymal obstruction, inducing an autoimmune response, and then causing a decline in spermatogenesis or even serious damage. Therefore, we examined the epididymis tissue and found that the thickened and fibrotic epididymis tissue was infiltrated with acute and chronic inflammatory

cells, multinucleated giant cells were seen locally, presenting chronic granulomatous inflammatory changes, and some abscesses were formed. Why did this unexplained inflammation occur? With two of our patients with obstructive azoospermia, we seem to have found the answer. We found that prolonged abstinence was an increased risk factor for stones, increasing the risk by 1.2 times. This is a good explanation for both of our cases, both of whom had prolonged abstinence.

The effect of testicular stones on sperm is controversial. Some studies have shown that testicular stones could cause an increase in FSH and LH in men and reduce sperm concentrations.<sup>8</sup> Another study showed that testicular stones could cause a slight decrease in sperm parameters but did not affect sex hormones.<sup>19</sup> There was also a view that testicular stones did not affect sperm parameters.<sup>20</sup> We did not find large sample studies or data on the correlation between scrotal stones and sperm parameters. According to the case data mentioned above, whether scrotal stones have an impact on sperm is worth further discussion. In our case, all the patients showed decreased spermatogenic function, with different degrees of decline. The spermatogenic function of cases 2 and 3 was slightly decreased, but epididymis function was impaired, and the spermatogenic function of case 1 was severely decreased. We considered this to be the two stages of impaired sperm production because the existence of scrotum stones stimulates local immune protection and noninfectious inflammation, causing the testis and epididymis to be in an immunological stress state. Thus, the epididymis small tube secretion and pressure increased, and the output of the sperm was blocked, which in turn affected the function of endogenous testicular seminiferous tubules and led to obstructive azoospermia or cryptozoospermia. This idea has also been tested in animal experiments: a study in 2004 showed that osmotic pressure in the tail of the epididymis affects the function of the epididymal flagellum and thus regulates sperm count.<sup>21</sup> Another study in a rat model in 2016 showed that the increase in epididymal pressure after vasectomy could lead to spermatogenic injury, and the change in injury depended on the postoperative development of sperm granuloma.<sup>22</sup> Therefore, we considered that intrascrotal calculi might be an invisible killer of sperm and the cause of obstructive azoospermia and cryptozoospermia.

To identify the main factors causing these differences, we compared the characteristics of the three cases and groups and found that abstinence time may be a potential risk factor. Cases 1 and 2 with scrotal calculi in obstructive azoospermia had abstinence for more than 15 days, while case 3 with calculi in occult spermatozoa had abstinence days significantly higher than those in normal subjects. Research has shown that abstinence for more than 10 days leads to a decrease in sperm acrosin.<sup>23</sup> After long-term abstinence, the oxidative stress reaction in semen is strengthened, and the fertilization ability of sperm is decreased.<sup>24</sup> From the perspective of environmental factors, a study revealed that long-term sexual abstinence leads to hemospermia<sup>25</sup> and the occurrence of male idiopathic infertility.<sup>26</sup> There were also cases of Penile Mondor's disease reported after long-term sexual abstinence.<sup>27</sup> Based on the common characteristics of our three cases, we confirmed that long-term sexual abstinence might be the root cause of the series of injuries, which should be given more attention.

## Conclusion

In summary, when a mass or nodule is found in the scrotum, the possibility of calculus of the tunica vaginalis should be fully considered or excluded. This stone might cause aseptic inflammation, which would cause serious damage to sperm production. Prolonged abstinence may be a potential risk factor.

Although we highly suspected that intrathecal stones were related to aseptic inflammation of the scrotum and would cause serious damage to the epididymis and spermatogenesis, our study still had certain limitations due to the small number of cases and limited observed indicators. Therefore, we will conduct detailed molecular mechanism analysis and observation to obtain more reliable evidence. However, we thought our findings were still meaningful, which laid a foundation for future research.

## Abbreviations

3D, Three-dimensional; MTESE, Microscopic testicular sperm extraction; MESA, Microscopic epididymal sperm aspiration; NOA, Nonobstructive azoospermia; OA, obstructive azoospermia; CZ, Cryptozoospermia; AZF, Azoospermia factor; ICSI, Intracytoplasmic sperm injection; WBC, White blood cells; RBC, Red blood cells; FSH,

Follicular estrogen hormone; LH, luteinizing hormone; PRL, Prolactin; P, progesterone; E<sub>2</sub>, Estradiol; T, Testosterone; LEU, Urine leukocyte; BLD, Urine red blood cells; KET, Urine ketone body; AT, Sexual abstinence time; SV, Semen volume; pH, Semen pH value; SC, Sperm count; MS, motile sperm; NG, Neisseria gonorrhoeae; UU, Ureaplasma urealyticum; CT, Chlamydia; MH, Mycoplasma hominis.

## Data Sharing Statement

The original contributions presented in the study are included in the article, and further inquiries can be directed to the corresponding author.

## Ethics Approval

This study was approved by the ethics committee of Guangdong Provincial Reproductive Science Institute (Guangdong Provincial Fertility Hospital) (Approval number, 2021 [05]). Our study complies with the Declaration of Helsinki. All patients signed informed consent before the surgery, and their names, addresses and other personal data will be replaced by codes or numbers, and their privacy will be well protected. Only relevant doctors know their data.

## Consent for Publication

Written informed consent and permission of any clinical images or the data for publication were obtained from the patients.

## Acknowledgments

We thank the patients for analyzing their medical records and the reviewers for their recommendations.

## Funding

There is no funding to report.

## Disclosure

The authors declare that they have no competing interests.

## References

1. Linkowski GD, Avellone A, Gooding GA. Scrotal calculi, sonographic detection. *Radiology*. 1985;156(2):484. doi:10.1148/radiology.156.2.2989975
2. Sánchez Merino JM, Lancina Martín A, Grases Freixedas F, Parra Muntaner L, Gómez Cisneros SC, García Alonso J. Litisias intraescrotal. Análisis cristalográfico [Intraescrotal lithiasis. Crystallographic analysis]. *Arch Esp Urol*. 2002;55(5):523–526.
3. Artas H, Orhan I. Scrotal calculi. *J Ultrasound Med*. 2007;26(12):1775–1779. doi:10.7863/jum.2007.26.12.1775
4. Li GH, Li XD, Cheng S, Chen ZD. A large intrascrotal calculus. *Asian J Androl*. 2005;7(1):103–105. doi:10.1111/j.1745-7262.2005.00013.x
5. Malouf WT, Dyer RB, Carter SC. Classics in abdominal radiology, a “scrotal pearl”. *Abdom Radiol*. 2019;44(9):3205–3206. doi:10.1007/s00261-019-02088-y
6. Vahlensieck W, Hesse A. Calculi in hydrocele, incidence and results of infrared spectroscopy analysis. *Korean J Urol*. 2010;51(5):362–364. doi:10.4111/kju.2010.51.5.362
7. Mahafza WS, Alarini MY, Awadghanem AF, Odwan G, Juweid ME. Testicular microlithiasis, correlation with Doppler sonography of testicular arteries and sperm function. *J Clin Ultrasound*. 2016;44(8):474–479. doi:10.1002/jcu.22363
8. Hiramatsu I, Tsujimura A, Miyoshi M, et al. Prevalence of testicular microlithiasis in healthy newlywed men trying for first-time pregnancy. *Int J Urol*. 2020;27(11):990–995. doi:10.1111/iju.14342
9. Trout AT, Chow J, McNamara ER, et al. Association between testicular microlithiasis and testicular neoplasia, large multicenter study in a pediatric population. *Radiology*. 2017;285(2):576–583. doi:10.1148/radiol.2017162625
10. Johnsen SG. Testicular biopsy score count--a method for registration of spermatogenesis in human testes, normal values and results in 335 hypogonadal males. *Hormones*. 1970;1(1):2–25. doi:10.1159/000178170
11. Tan S, Özcan MF, Karaoğlanoğlu M, Ipek A, Özcan AS, Arslan H. Prevalence of scrotal calculi and their relationship with pain. *Diagn Interv Radiol*. 2012;18(3):303–306. doi:10.4261/1305-3825.DIR.4808-11.1
12. Deganello A, Svasti-Salee D, Allen P, Clarke JL, Sellars ME, Sidhu PS. Scrotal calcification in a symptomatic pediatric population, prevalence, location, and appearance in a cohort of 516 patients. *Clin Radiol*. 2012;67(9):862–867. doi:10.1016/j.crad.2012.01.019
13. Aslan A, Tan S, Yıldırım H, et al. Scrotal calculi in clinical practice and their role in scrotal pain, A prospective study. *J Clin Ultrasound*. 2015;43(7):406–411. doi:10.1002/jcu.22247

14. Vijayanathan A, Kumar G, Rajendram NK. Intrascrotal calculi, A rare benign entit. *Eur J Radiol Extra*. 2008;66(3):105–107. doi:10.1016/j.ejrex.2008.04.002
15. Patoulas I, Koutsogiannis E, Panopoulos I, Michou P, Feidantsis T, Patoulas D. Hydrocele in Pediatric Population. *Acta Med*. 2020;63(2):57–62. doi:10.14712/18059694.2020.17
16. Khanna S, Ticckoo S. Calculous disease in hydrocele. A report of 2 cases. *Eur Urol*. 1989;16(3):235–236. doi:10.1159/000471578
17. Rassam Y, Gromoll J, Kliesch S, Schubert M. Testicular microlithiasis is associated with impaired spermatogenesis in patients with unexplained infertility. *Urol Int*. 2020;104(7–8):610–616. doi:10.1159/000508584
18. Xu C, Liu M, Zhang FF, et al. The association between testicular microlithiasis and semen parameters in Chinese adult men with fertility intention, experience of 226 cases. *Urology*. 2014;84(4):815–820. doi:10.1016/j.urology.2014.03.021
19. Anvari Aria S, Nordström Joensen U, Bang AK, et al. Testicular microlithiasis on scrotal ultrasound in 4850 young men from the general population, associations with semen quality. *Andrology*. 2020;8(6):1736–1743. doi:10.1111/andr.12854
20. D’Andrea S, Martorella A, Castellini C, et al. Clinical and seminal parameters associated with testicular microlithiasis and its severity in males from infertile couples. *Hum Reprod*. 2021;36(4):891–898. doi:10.1093/humrep/deaa354
21. Cooper TG, Yeung CH, Wagenfeld A, et al. Mouse models of infertility due to swollen spermatozoa. *Mol Cell Endocrinol*. 2004;216(1–2):55–63. doi:10.1016/j.mce.2003.10.076
22. Ma L, Guo Y, Yuan Y, Li YG, Deng XZ, Yang ZW. Morphometric study of the testis and reproductive tract (including sperm granuloma) after vasectomy in mature rats. *Asian J Androl*. 2016;18(1):66–73. doi:10.4103/1008-682X.150038
23. Blackwell JM, Zaneveld LJ. Effect of abstinence on sperm acrosin, hypoosmotic swelling, and other semen variables. *Fertil Steril*. 1992;58(4):798–802. doi:10.1016/s0015-0282(16)55330-8
24. Degirmenci Y, Demirdag E, Guler I, Yildiz S, Erdem M, Erdem A. Impact of the sexual abstinence period on the production of seminal reactive oxygen species in patients undergoing intrauterine insemination, A randomized trial. *J Obstet Gynaecol Res*. 2020;46(7):1133–1139. doi:10.1111/jog.14308
25. Klevecka V, Jatulis A, Kraniauskas V, Salkauskas V, Uksas A, Zeromskas P. Hemospermija [Hemospermia]. *Medicina*. 2005;41(4):359–364.
26. de Morais MP, Curado RF, Silva E, Moura KS, Arruda JT. Male idiopathic infertility and the TP53 polymorphism in codon 72. *GMR*. 2016;15(4). doi:10.4238/gmr15048882
27. Sheikh MM, Jeelani HM, Farooqi A, Riaz A. Penile Mondor’s disease, rare association with excessive masturbation. *Cureus*. 2020;12(5):e8317. doi:10.7759/cureus.8317
28. Zhang HM, Li GZ, Zhu CY. 阴囊结石的临床研究进展[J] [Scrotal calculi, advances in clinical research]. *Zhonghua Nan Ke Xue*. 2014;20(11):1047–1050. Chinese.

International Journal of General Medicine

Dovepress

## Publish your work in this journal

The International Journal of General Medicine is an international, peer-reviewed open-access journal that focuses on general and internal medicine, pathogenesis, epidemiology, diagnosis, monitoring and treatment protocols. The journal is characterized by the rapid reporting of reviews, original research and clinical studies across all disease areas. The manuscript management system is completely online and includes a very quick and fair peer-review system, which is all easy to use. Visit <http://www.dovepress.com/testimonials.php> to read real quotes from published authors.

Submit your manuscript here: <https://www.dovepress.com/international-journal-of-general-medicine-journal>