








SHORT COMMUNICATION

Endometrial area of the blood flow as a marker of endometritis in equine

Eva Da Silva-Álvarez¹  | Vanessa Gómez-Arrones² | Francisco Eduardo Martín-Cano¹  | Gemma Gaitskell-Phillips¹  | Jose Manuel Ortiz-Rodríguez¹  | Juan Jesús Carrasco² | Maria Cruz Gil¹  | Fernando J. Peña Vega¹  | Cristina Ortega Ferrusola¹ 

¹Laboratory of Equine Reproduction and Equine Spermatology, Veterinary Teaching Hospital, University of Extremadura, Cáceres, Spain

²CENSYRA, Centro de Selección y Reproducción Animal de Extremadura, Badajoz, Spain

Correspondence

Cristina Ortega Ferrusola, Laboratory of Equine Reproduction and Equine Spermatology, Veterinary Teaching Hospital, University of Extremadura, Cáceres 10071, Spain.
Email: cristinaof@unex.es

Abstract

In this study, uterine blood flow area (BFA) has been evaluated for the first time using power Doppler ultrasound (PD) as a marker of endometritis in mares and jennies. The uterine BFA in healthy mares was greater in oestrus than in diestrus ($p < .001$). However, differences in endometrial blood flow between oestrus and diestrus were not observed in mares with endometritis. The uterine blood flow in healthy jennies is not affected by the oestrus cycle. Both species showed an increase in endometrial BFA in pathological uterine conditions compared to controls. BFA was a good marker of endometritis with an area under curve (AUC) (estrus:0.94 ($p < .001$) diestrus:0.98 ($p < .001$) in mares and AUC (0.91 ($p < .0001$) in jennies. The results of this preliminary study suggest that PD ultrasound in combination with computerized image analysis has the potential to be a very useful tool in the diagnosis of endometritis.

KEYWORDS

blood flow and equine, doppler, endometritis

1 | INTRODUCTION

Endometritis is a common disease in equines that can lead to multiple reproductive problems with conception failure, shortening of the cycle and embryonic mortality being the main consequences (Leblanc and Causey, 2009).

Some clinical signs of endometritis such as intrauterine fluid or hyperoedema can be diagnosed using B-mode ultrasound; however, these signs are not always present. Recent advances in Doppler ultrasound enable monitoring of uterine blood flow during early pregnancy and in cycling mares (Bollwein et al., 2004). Current research has evaluated the use of pulse and colour Doppler ultrasound in the evaluation of uterine perfusion in mares with endometritis (Abdelnaby et al., 2020; Lüttgenau et al., 2021). However, this is

a time-consuming technique and requires operator experience. PD ultrasound is a more sensitive technique for the detection of blood flow changes in smaller-sized vessels, in addition for being easier to use. This Doppler modality combined with computer-assisted analysis of images was already used in a previous study of our group to detect uterine blood flow differences between pregnant and non-pregnant mares prior to flushing in an embryo transfer program (Nieto-Olmedo et al., 2020). This is the first time that PD ultrasound has been used to evaluate uterine perfusion in the diagnosis of endometritis in equines.

Considering all the above, we hypothesize that PD ultrasound could detect vascular changes associated with endometritis in equines, so this study aimed to determine if the endometrial blood flow area is a good marker of endometritis in equines.

This is an open access article under the terms of the [Creative Commons Attribution-NonCommercial](https://creativecommons.org/licenses/by-nc/4.0/) License, which permits use, distribution and reproduction in any medium, provided the original work is properly cited and is not used for commercial purposes.

© 2022 The Authors. *Reproduction in Domestic Animals* published by Wiley-VCH GmbH.

2 | MATERIALS AND METHODS

2.1 | Animals and experimental design

Fifteen pure Spanish horse mares, with an age range between 5–17 years old and thirteen Andalusian donkeys aged between 5–16 years old were used in this study. The uterine BFA of the mares (8 healthy and 7 pathological) and jennies (4 healthy and 9 pathological) was evaluated in oestrus and diestrus using PD ultrasound. The females were classified into healthy and endometritis groups based on cytology and culture. Six uterine images (three from each uterine horn) were taken per animal and image processing was performed using blind computer-assisted image analysis (ImageJ, v1.5.3 software) (Figure 1). Images were taken at two points during the oestrus cycle: oestrus (follicle diameters $>35 \times 35$ mm, uterine oedema $\geq 3/5$, relaxed cervix and receptive to a teaser stallion) and diestrus (on day 8 post-ovulation).

2.2 | Ultrasound examination

The ultrasound equipment used was a MyLabFive Vet ultrasound machine (Esaote SpA) with a 5-7.5 MHz linear probe. Three cross-sectional images of the middle-third of each uterine horn were then captured using PD ultrasound. A total of 12 images were obtained for each animal: 6 in oestrus and 6 in diestrus.

2.3 | Ultrasound image analysis

Post-acquisition analysis of PD ultrasound images was carried out using ImageJ v1.5.3 software (U.S. National Institutes of Health). Using a colour threshold, the number of pixels corresponding to blood vessels was counted. A total of 672 images were evaluated.

2.4 | Statistical analysis

To normalize the magnitude of uterine vascularization according to the size of the uterus and enable its comparison between species,

the cross-sectional area of the uterus in each image was used to carry out said normalization obtaining the percentage of uterine vascularization:

$$\frac{\text{Vascularization area}}{\text{Cross sectional area uterus}} \times 100$$

All statistical analysis and graphical representations were carried out using GraphPad Prism 8 software (GraphPad Software Inc. V8.2.1). Performing diagnostic curves were used to investigate the predictive value of the proposed variable. Youden's test allowed cut-off values to be established for the variables with good prognostic values. AUC was calculated with a confidence interval (CI) of 95% and a significance test for each variable studied.

3 | RESULTS

3.1 | Effect of the oestrus cycle on uterine vascularization in healthy mares and jennies

Healthy mares showed a greater uterine BFA in oestrus than diestrus (1.44 ± 0.44 vs. 0.67 ± 0.24 , $p < .001$). However, in healthy jennies, no significant differences in BFA were observed between both phases (1.65 ± 0.96 vs. 1.94 ± 1.41). The uterine BFA of jennies in diestrus was greater than in mares ($p < .01$) (Figure 2).

3.2 | Effect of the oestrus cycle on uterine vascularization in mares and jennies with endometritis

Mares and jennies with endometritis did not show significant differences throughout the oestrus cycle. Once more, jennies showed a greater uterine BFA than mares in diestrus ($p < .001$) (Figure 3).

3.3 | Effect of endometritis on uterine vascularization in mares and jennies

Mares with endometritis presented a greater uterine BFA than healthy mares in both oestrus phases (oestrus: 2.42 ± 0.46 vs.

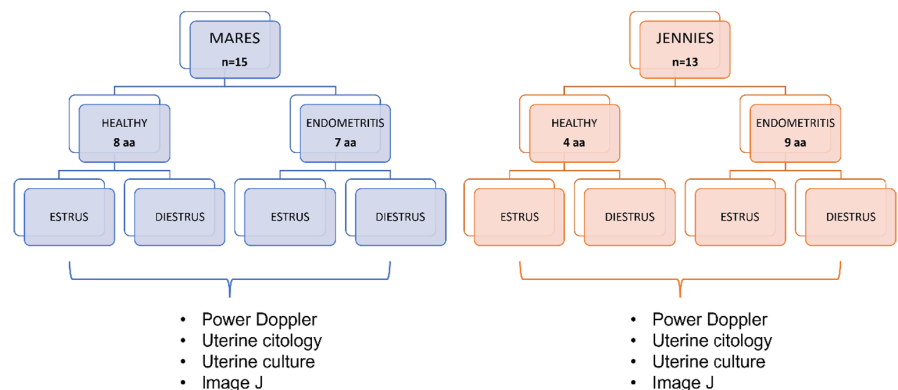


FIGURE 1 Diagram showing experimental design (n: sample size, aa: animals)

1.44 ± 0.44 ($p < .0001$); diestrus (2.29 ± 0.69 vs. 0.67 ± 0.24 , $p < .00001$). In jennies, an increase in BFA was observed in pathological individuals compared to healthy animals in oestrus (3.51 ± 0.69 vs. 1.65 ± 0.96 , $p < .01$). This increase of vascularity was more evident in diestrus (4.68 ± 1.90 vs. 1.94 ± 1.41 , $p < .0001$) (Figure 4).

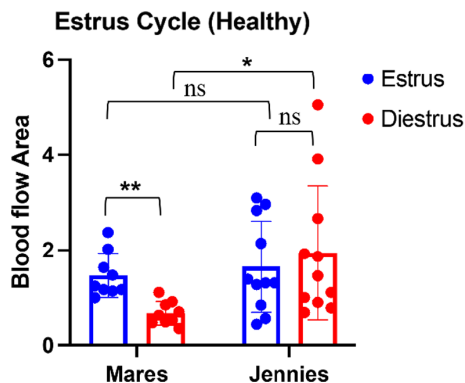


FIGURE 2 Mean values of the BFA in oestrus measured by power Doppler in healthy mares and jennies (ns: no significance)

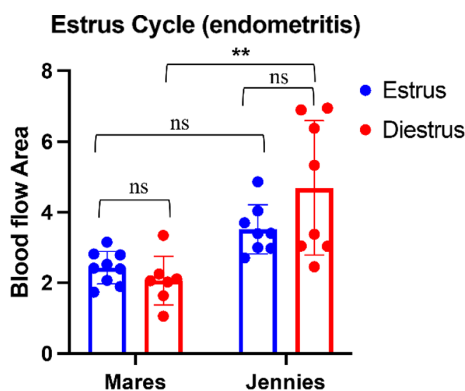


FIGURE 3 Mean values of the BFA in oestrus measured by power Doppler in mares and jennies with endometritis (ns: no significance)

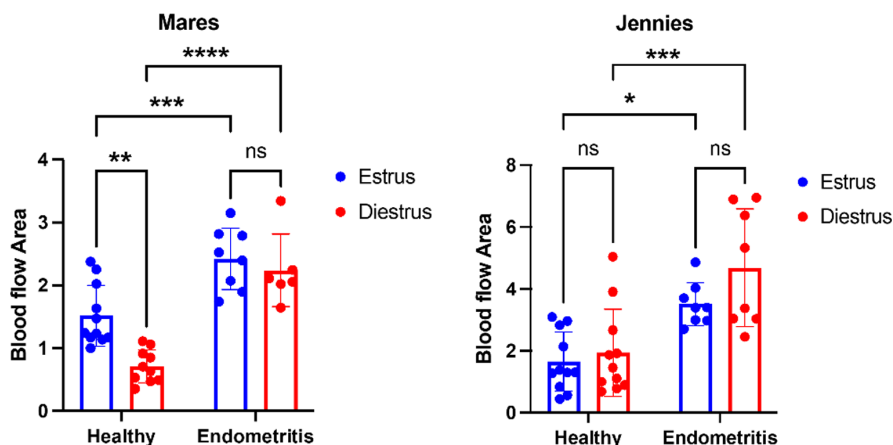


FIGURE 4 Mean values of the blood flow area in each phase of the oestrus cycle measured by power Doppler in mares and jennies (healthy and with endometritis). (ns: no significance)

3.4 | Predictive value of the parameters studied using ROC curves

The BFA was evaluated using a diagnostic performance curve (ROC curve: Receiver Operating Characteristic) in mares in oestrus and diestrus. This parameter showed a good prognostic value, presenting an AUC of 0.94 (oestrus) and 0.98 (diestrus). Using Youden's index, the cut-off value for this parameter was also determined (Figure 5). In the case of jennies, the measurements were unified obtaining an AUC of 0.91 and a single cut-off value (Figure 6).

4 | DISCUSSION

In this study, we evaluated endometrial BFA (percentage of vascularization) for the first time using PD ultrasound with subsequent analysis of images, to diagnose endometritis in equines (mares and jennies). We observed an increase of uterine BFA in females with endometritis. These findings agree with those observed by EA. Abdelnaby et al., 2020, where a hyperaemic process was evident with a decrease of Doppler indices and an increase in Doppler velocity parameters assessed with pulse and colour Doppler ultrasound (Abdelnaby et al., 2020). Using colour Doppler J. Lüttgenau et al., 2021, diagnosed mares with persistent post-breeding endometritis before artificial insemination, observing greater uterine perfusion in mares with endometritis (Lüttgenau et al., 2021). In our study, we also observed how the hormonal status can influence uterine vascularization in healthy mares, increasing the uterine BFA in oestrus. In agreement with our findings, Bollwein et al., 2002, suggest that this increase in uterine blood flow could be due to the greater oestrogen levels in oestrus (Bollwein et al., 2002). In contrast, in jennies, hormonal levels did not seem to affect uterine vascularization, showing even a greater BFA in diestrus than in healthy mares. This result could be due to the larger uterine size of this species (Wissdorf et al., 2021) but as the Doppler measurements were normalized by the cross-sectional area, the difference observed is likely to be linked to an increase in blood flow.

FIGURE 5 Representation of the different predictive values obtained by ROC curves for the BFA parameter in both phases of the oestrus cycle in mares. Each of them represents oestrus (AUC: 0.94 ($p < .001$) cut-off value: 1.685), diestrus (AUC: 0.98 ($p < .001$), cut-off value: 0.983). AUC (area under the curve)

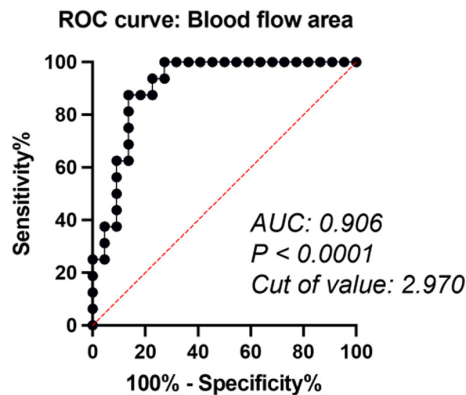
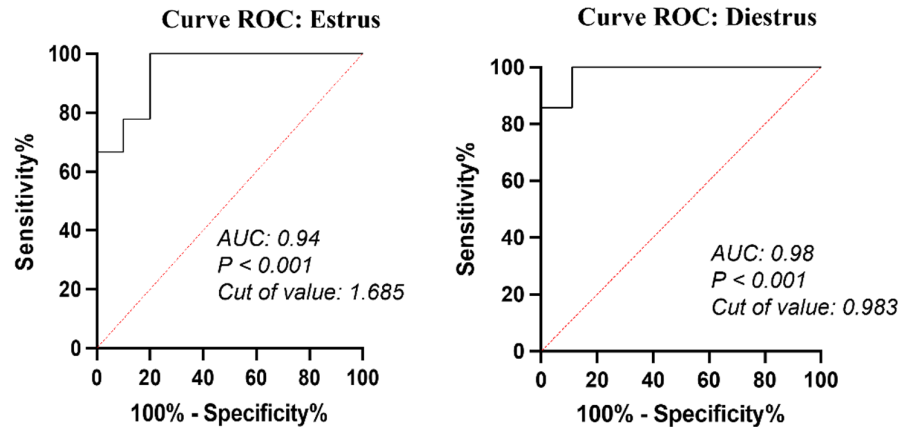


FIGURE 6 Representation of the predictive value obtained by ROC curve in jennies (AUC: 0.90, cut-off value: 2.970). ($p < .0001$). AUC (area under the curve)

The study revealed that PD ultrasound is a sensible and helpful technique for the detection of increases in blood flow associated with endometritis in equines. The endometritis caused a significant increase in uterine vascularization both in oestrus and diestrus in mares and jennies but abolished the hormonal effect over the endometrial blood flow. A previous study did not find any differences in mares due to the oestrus cycle or between mares with abnormal uterine secretion (El-Shahat et al., 2020). Probably, this absence of effect could be due to the fact that in this study, the data were not normalized by the uterine size.

The endometrial BFA was evaluated by a ROC curve, with a good prognostic value for differentiation of healthy and pathological mares in both phases of the oestrus cycle and cut-off values were established. Thus, this parameter seems to be a good marker of endometritis in equines.

Although preliminary, these results could serve as a starting point for future implementation of PD ultrasound as a complementary tool in the diagnosis of endometritis in equines. This tool could be applicable in equines with subclinical endometritis, where no obvious signs would be found with B-mode ultrasound, but alterations in uterine perfusion with PD ultrasound could be detected. In our opinion, the data from this study could open new lines of research in the early diagnosis of subfertility in equines.

CONFLICTS OF INTEREST

The authors declared no potential conflicts of interest.

DATA AVAILABILITY

The data that support the findings of this study are available on request from the corresponding author. The data are not publicly available due to privacy or ethical restrictions.

ORCID

Eva Da Silva-Álvarez  <https://orcid.org/0000-0003-3746-8937>

Francisco Eduardo Martín-Cano  <https://orcid.org/0000-0003-4971-4883>

Gemma Gaitskell-Phillips  <https://orcid.org/0000-0003-4308-7903>

Jose Manuel Ortiz-Rodríguez  <https://orcid.org/0000-0002-3248-6493>

Maria Cruz Gil  <https://orcid.org/0000-0001-7041-9673>

Fernando J. Peña Vega  <https://orcid.org/0000-0002-1311-2947>

Cristina Ortega Ferrusola  <https://orcid.org/0000-0002-7698-8735>

Fernando J. Peña Vega  <https://orcid.org/0000-0002-1311-2947>

Cristina Ortega Ferrusola  <https://orcid.org/0000-0002-7698-8735>

Cristina Ortega Ferrusola  <https://orcid.org/0000-0002-7698-8735>

Cristina Ortega Ferrusola  <https://orcid.org/0000-0002-7698-8735>

REFERENCES

- Abdelnaby, E. A., Emam, I. A., Salem, N. Y., Ramadan, E. S., Khattab, M. S., Farghali, H. A., & Abd El Kader, N. A. (2020). Uterine hemodynamic patterns, oxidative stress, and chromoendoscopy in mares with endometritis. *Theriogenology*, 158, 112–120. <https://doi.org/10.1016/J.THERIOGENOLOGY.2020.09.012>
- Bollwein, H., Weber, F., Kolberg, B., & Stolla, R. (2002). Uterine and ovarian blood flow during the estrous cycle in mares. *Theriogenology*, 57(8), 2129–2138. [https://doi.org/10.1016/S0093-691X\(02\)00703-3](https://doi.org/10.1016/S0093-691X(02)00703-3)
- Bollwein, H., Weber, F., Woschée, I., & Stolla, R. (2004). Transrectal Doppler sonography of uterine and umbilical blood flow during pregnancy in mares. *Theriogenology*, 61(2–3), 499–509. [https://doi.org/10.1016/S0093-691X\(03\)00225-5](https://doi.org/10.1016/S0093-691X(03)00225-5)
- El-Shahat, K., Abo El-Maaty, A., Helmy, M., & el Baghdady, Y. (2020). Power and color Doppler ultrasonography for evaluation of the ovarian and uterine haemodynamics of infertile mares. *Bulgarian Journal of Veterinary Medicine*, 23(3), 338–349. <https://doi.org/10.15547/bjvm.2019-0004>
- Leblanc, M., & Causey, R. (2009). Clinical and subclinical endometritis in the mare: Both threats to fertility. *Reproduction in Domestic Animals*, 44(SUPPL. 3), 10–22. <https://doi.org/10.1111/J.1439-0531.2009.01485.X>

- Lüttgenau, J., Imboden, I., Wellnitz, O., Romer, R., Scaravaggi, I., Neves, A. P., Borel, N., Bruckmaier, R. M., Janett, F., & Bollwein, H. (2021). Intrauterine infusion of killed semen adversely affects uterine blood flow and endometrial gene expression of inflammatory cytokines in mares susceptible to persistent breeding-induced endometritis. *Theriogenology*, *163*, 18–30. <https://doi.org/10.1016/J.THERIOGENOLOGY.2020.12.029>
- Nieto-Olmedo, P., Martín-Cano, F. E., Gaitskell-Phillips, G., Ortiz-Rodríguez, J. M., Peña, F. J., & Ortega-Ferrusola, C. (2020). Power Doppler can detect the presence of 7–8 day conceptuses prior to flushing in an equine embryo transfer program. *Theriogenology*, *145*, 1–9. <https://doi.org/10.1016/J.THERIOGENOLOGY.2020.01.015>
- Wissdorf, H., Jerbi, H., & Meier-Schellersheim, M. (2021). *Anatomical differences of the donkey, mule, and horse*. Utzverlag GmbH.

How to cite this article: Da Silva-Álvarez, E., Gómez-Arrones, V., Martín-Cano, F. E., Gaitskell-Phillips, G., Ortiz-Rodríguez, J. M., Carrasco, J. J., Gil, M. C., Peña Vega, F. J., & Ortega Ferrusola, C. (2022). Endometrial area of the blood flow as a marker of endometritis in equine. *Reproduction in Domestic Animals*, *57*(Suppl. 5), 98–102. <https://doi.org/10.1111/rda.14132>