


Combinational elastography for assessment of liver fibrosis in patients with liver injury

Tomotaka Yazaki^{1,2}, Hiroshi Tobita^{1,2} ,
Shuichi Sato³, Tatsuya Miyake⁴,
Masatoshi Kataoka^{1,2} and Shunji Ishihara²

Abstract

Objective: We investigated the utility of combinational elastography with point shear wave elastography (pSWE) and real-time tissue elastography (RTE) for evaluating liver fibrosis in patients with liver injury.

Methods: In this prospective single-institution study, patients scheduled for a liver biopsy to determine the presence of liver disease were enrolled. Liver fibrosis in each patient was evaluated using both shear wave velocity (Vs) shown by pSWE and the liver fibrosis index (LFI) shown by RTE, while a liver biopsy sample was obtained from the same area that was subjected to an elastography examination. Results of the latter were compared with those obtained in a histological examination.

Results: Multivariate analysis showed that Vs and LFI were significantly correlated with the liver fibrosis stage in all of the enrolled patients. Sub-analysis findings compared patients with and without non-alcoholic fatty liver disease (NAFLD) and demonstrated that Vs was significantly correlated with the liver fibrosis stage in both groups, whereas LFI was correlated with that only in the non-NAFLD patients. However, a multivariate analysis demonstrated a significant correlation between steatosis grade and LFI in the NAFLD patients.

Conclusions: RTE is less useful than pSWE for assessing liver fibrosis in patients with NAFLD.

⁴Division of Hepatology, Shimane Prefectural Central Hospital, Izumo, Japan

Corresponding author:

Hiroshi Tobita, Division of Hepatology, Shimane University Hospital, Izumo, Japan, Department of Internal Medicine II, Shimane University School of Medicine, Enya-cho, 89-1, Izumo 693-8501, Japan.
Email: ht1020@med.shimane-u.ac.jp

¹Division of Hepatology, Shimane University Hospital, Izumo, Japan

²Department of Internal Medicine II, Shimane University School of Medicine, Izumo, Japan

³Izumo City General Medical Center, Izumo, Japan



Keywords

Combinational elastography, point shear wave elastography, real-time tissue elastography, liver injury, non-alcoholic fatty liver disease, shear wave velocity, liver fibrosis index

Date received: 26 November 2021; accepted: 25 April 2022

Introduction

Liver fibrosis is closely associated with the prognosis of patients with chronic liver disease, and its evaluation is important for determining the risk of developing hepatocellular carcinoma.^{1–5} Although an ultrasound-guided liver biopsy procedure is widely accepted as the gold standard method for a liver injury diagnosis, it is invasive and can cause fatal complications such as bleeding.^{6,7} Additionally, fibrosis can occur unevenly in the liver, which may lead to sampling errors, thus affecting the histological assessment of biopsy samples.^{8,9} Therefore, it is important to establish an effective non-invasive method for evaluating liver fibrosis that does not include an ultrasound-guided liver biopsy procedure.

Elastography was initially developed in 1992 as a non-invasive method for determining liver fibrosis. Two modes are currently available, shear wave imaging and strain imaging, each of which has different characteristics. Point shear wave elastography (pSWE), a type of shear wave imaging, is integrated into conventional ultrasound devices as an acoustic radiation force for quantification of imaging elastography,¹⁰ while shear wave velocity (Vs) is determined by pSWE increases in parallel with the progress of liver fibrosis, which is a useful factor for assessing liver fibrosis in patients with chronic viral hepatitis (CVH)^{11,12} and non-alcoholic fatty liver disease (NAFLD).¹³ However, results obtained using SWE are affected by inflammation, jaundice, and congestion in the liver.¹⁴ Another imaging method is real-time

strain elastography (RTE), which is a non-invasive sonography-based technique, and it provides two-dimensional visualization of strain induced by internal heartbeat and vibration of the inferior vena cava. RTE can be used instead of manual probe compression, and it is also useful for assessing liver fibrosis in patients with primary biliary cholangitis (PBC)¹⁴ and CVH.¹⁵ Furthermore, this imaging method is minimally affected by inflammation, jaundice, and/or congestion in the liver,¹⁴ although its accuracy is largely dependent on the measurement technique used, and special training is required.

Combinational elastography, which uses the characteristics of both SWE and RTE, is considered to be useful for evaluating the degree of liver fibrosis and that of liver inflammation in patients with autoimmune hepatitis.¹⁶ However, little is known about its usefulness for evaluating liver fibrosis in NAFLD patients.¹⁷

The purpose of this prospective study was to investigate combinational elastography and its usefulness for pSWE and RTE in patients with liver injury, including NAFLD. Furthermore, to increase the evaluation accuracy, a liver biopsy was performed in the same area at the same time as combinational elastography.

Materials and methods

Study design and patients

This prospective single-institution study was performed at Shimane University Hospital (Shimane-Izumo, Japan) after

receiving approval from the local ethics committee (approval no. 20170619-1). From April 2017 to March 2020, consecutive patients who were scheduled for an ultrasound-guided liver biopsy examination as part of routine clinical care and who were able to undergo an ultrasound combination elastography examination at the same time were included. When Vs and/or the liver fibrosis index (LFI) could not be adequately measured on the day of liver biopsy, that patient was excluded. The study protocol conformed to the principles of the Declaration of Helsinki, and each patient provided informed consent to participate. The findings for this study were reported in accordance with the STROBE guidelines.¹⁸

Clinical and laboratory assessments

Clinical data were collected at the time of the elastography examination, including age, sex, weight, height, and cause of chronic liver disease. Body mass index (BMI) was calculated as weight (in kg) divided by height (in m) squared. Blood samples were taken after an overnight fast on the same day as the liver biopsy. The FIB4 index and type IV collagen 7S serum level were determined as markers for assessing fibrosis.^{19–21}

Vs (pSWE) and LFI (RTE) calculation procedures

pSWE and RTE were performed after an overnight fast using an ultrasound device (ARIETTA S70; Hitachi, Tokyo, Japan) with an EUP-C251 convex type probe (1–5 MHz, 50-mm radius scan width, 75° field of view scan angle) (Hitachi, Tokyo, Japan), as previously reported.^{22,23} Using this device, Vs and LFI can be determined with a single probe, which is a significant advantage. First, two sonographers with varying ultrasound experience and training in elastography image acquisition

performed pSWE and RTE immediately before the liver biopsy procedure. During shallow expiration, five sequential Vs measurements were obtained via an intercostal approach in the upper portion of the right lobe. The measurement sites were at least 2 cm below the liver capsule and at a depth of less than 6 cm below the skin surface. One of the sonographers determined the region of interest (ROI) in the liver tissue using liver anatomic structures such as large blood vessels avoided. Using the reliability index, the percentage of the net amount of effective Vs (VsN) was determined to confirm whether pSWE was appropriate for the measurements.²⁴ When VsN was 60% or greater, measurements were performed five times and the median value was determined. Next, a ROI was set in the same location as the area where pSWE was measured, and RTE was performed five times to evaluate LFI. Because the RTE displays the relative amount of distortion, the entire RTE area was established as the area of analysis. Finally, in the same area where Vs and LFI were measured, a liver biopsy was performed using a 16-gauge cutting biopsy needle (Figure 1).

Histological analysis

Liver biopsy specimens were obtained, fixed in formalin, and embedded in paraffin, and they were then stained with hematoxylin-eosin and Masson's trichrome. All specimens were examined by pathologists who were blinded to individual patient characteristics. Only samples with a sufficient amount of tissue collected for pathological diagnosis were analyzed. NAFLD was diagnosed using the Matteoni classification. In the NAFLD patients, liver histology findings (fibrosis stage [0–4], hepatitis grade [0–3], steatosis grade [0–3], and ballooning grade [0–2]) were examined in accordance with the Brunt classification²⁵

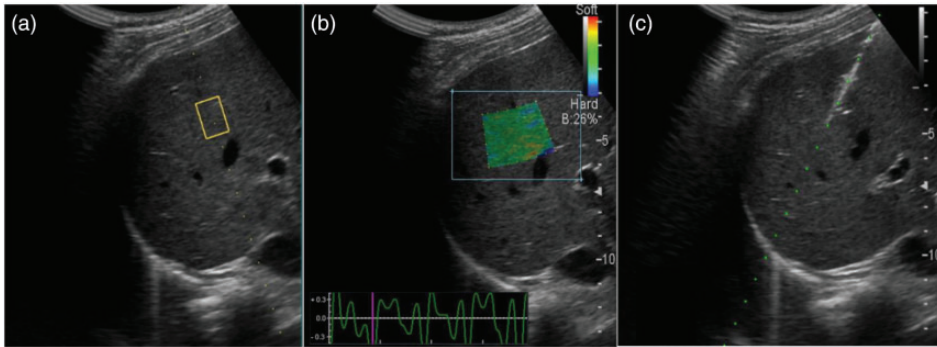


Figure 1. (a) Image showing the pSWE procedure. The measurement sites were at least 2 cm below the liver capsule and at a depth of less than 6 cm below the skin surface. The ROI was determined and anatomic structures such as large blood vessels were avoided. The V_s value for the area in the rectangle was calculated using pSWE. (b) Image showing the RTE procedure. An ROI was established in the same area where pSWE was measured. The LFI value for the area in the trapezium was calculated using RTE and (c) Liver biopsy sample obtained from same area that was examined using pSWE and RTE.

pSWE, point shear wave elastography; ROI, region of interest; V_s , shear wave velocity; RTE, real-time tissue elastography; LFI, liver fibrosis index.

and NAFLD activity (NAS) scoring.²⁶ In the non-NAFLD patients, fibrosis stage (0–4) and hepatitis grade (0–3) were assessed using the Metavir scoring system,²⁷ while steatosis (0–3) and ballooning (0–2) grades were assessed using the NAS score.

Statistical analysis

Values are shown as the median (range) or percentage, as appropriate. The Mann–Whitney U test was performed to test for differences between two groups. Any correlation between data was tested using the nonparametric Spearman’s rank correlation analysis. Correlations of histological parameters with V_s and LFI were evaluated using multivariate analysis. P values <0.05 were considered to indicate statistical significance. All statistical analyses were performed using the Bell Curve for Excel statistical analysis software package, ver.2.14 (Social Survey Research Information Co., Ltd., Tokyo, Japan).

Results

Patients

One hundred thirteen patients with liver injury underwent routine laboratory tests and a liver biopsy between April 2017 and March 2020. After excluding 17 patients with poor quality V_s or LFI results, 96 patients were included in this study. Table 1 shows the etiologies of liver disease in the present patients, which included NAFLD, drug-induced liver disease, PBC, alcoholic liver injury, autoimmune hepatitis, hepatitis B virus, hepatitis C virus, primary sclerosing cholangitis, and idiopathic portal hypertension. No specific cause of liver dysfunction was found in 16.7% (21/96) of the cohort, even after laboratory and histological assessments. Table 2 presents characteristics of the study population. The median age was 65 years (range, 23–86 years), and there were 52 women and 44 men enrolled into the study.

Table 1. Etiology of liver disease in all patients on the basis of liver biopsy results.

Liver disease	No.
NAFLD	33
DILI	15
PBC	10
ALD	7
AIH	5
HCV	2
HBV	1
PBC	1
IPH	1
Nonspecific liver injury ♦	21

♦The specific cause of liver dysfunction was not found upon laboratory or histological examination.

NAFLD, nonalcoholic fatty liver disease; DILI, drug-induced liver disease; PBC, primary biliary cholangitis; ALD, alcoholic liver disease; AIH, autoimmune hepatitis; HCV, hepatitis C virus; HBV, hepatitis B virus; PBC, primary sclerosing cholangitis; IPH, idiopathic portal hypertension.

Correlations between elastography type and histological parameters in patients with chronic liver disease

Results of the univariate and multivariate analyses showing correlations between the elastography type and histological parameters are presented in Table 3. Multivariate analysis results revealed that Vs was positively correlated with fibrosis stage ($p < 0.01$) and hepatitis grade ($p < 0.01$), while LFI showed a positive correlation with fibrosis stage ($p < 0.01$) and steatosis grade ($p < 0.05$).

Correlations between elastography type and histological parameters in NAFLD and non-NAFLD patients

Few reports have presented results of combinational elastography that was performed to examine patients with liver injury, and it remains unknown whether this method is appropriate for assessing liver fibrosis in

Table 2. Baseline characteristics and clinical parameters for all patients ($n = 96$).

Variable	
Age (years)	65 (23–86)
Women/men	52/44
Body mass index (kg/m^2)	24.0 (16.1–40.6)
Total bilirubin (mg/dL)	0.7 (0.4–6.2)
AST (U/L)	53 (10–816)
ALT (U/L)	63 (10–933)
Platelet count ($\times 10^9/\text{L}$)	20.8 (6.6–36.3)
Serum albumin (g/dL)	4.0 (2.1–5.4)
Prothrombin time (%)	104.0 (21.0–145.0)
hs-CRP (mg/dL)	0.1 (0.01–25.8)
FIB4 index	2.3 (0.4–31.3)
Type 4 collagen 7s (ng/mL)	5.3 (2.0–15.0)
Vs (m/s)	1.6 (1.0–3.1)
LFI	2.4 (0.6–4.6)

Values are presented as the number or median (minimum–maximum).

AST, aspartate aminotransferase; ALT, alanine aminotransferase; hs-CRP, high-sensitive C-reactive protein; FIB4 index, fibrosis-4 index; LFI, liver fibrosis index; Vs, shear wave velocity.

those with NAFLD. Thus, analyses using data obtained from the present study were performed to determine its usefulness. Characteristics of the NAFLD and non-NAFLD patients are presented in Table 4. BMI and serum albumin were significantly higher in NAFLD patients compared with those of the non-NAFLD patients. The average score for each histological factor was also compared between the groups (Figure 2). Scores for steatosis and ballooning were significantly higher in the NAFLD patients, while there were no differences for hepatitis or fibrosis stage between the groups.

Next, correlations between the elastography type and histological parameters in NAFLD and non-NAFLD patients were examined (Table 5). Multivariate analysis revealed that the fibrosis stage was significantly correlated with Vs in both

Table 3. Correlation of each histopathologic parameter with Vs and LFI in all patients.

Explanatory variable	Vs*				LFI#			
	β	p value	r	p value	β	p value	r	p value
All								
Fibrosis stage (0/1/2/3/4) = (22/34/15/13/12)	0.42	<0.01	0.49	<0.01	0.27	<0.01	0.38	<0.01
Hepatitis grade (0/1/2/3/) = (3/43/44/6)	0.25	<0.01	0.31	<0.01	0.19	0.06	0.26	<0.05
Steatosis grade [‡] (0/1/2/3/) = (52/23/17/4)	NE	NE	0.29	0.36	0.29	<0.05	0.32	<0.01
Ballooning grade (0/1/2/) = (61/10/25)	NE	NE	0.02	0.96	0.04	0.73	0.31	<0.01

*Vs was determined using pSWE.

#LFI was calculated using RTE.

Vs, shear wave velocity; LFI, liver fibrosis index; RTE, real-time tissue elastography; pSWE, point shear wave elastography; r, coefficient of correlation in univariate analysis; β , standard partial regression coefficient in multivariate analysis; †, steatosis grade was significantly higher in NAFLD as compared with non-NAFLD patients; NAFLD, nonalcoholic fatty liver disease; NE, not examined.

Table 4. Baseline demographic characteristics and clinical parameters of NAFLD and non-NAFLD patients.

Variable	NAFLD (n = 33)	Non-NAFLD (n = 63)
Age (years)	64 (24–79)	65 (23–86)
Women/men	18/15	34/29
Body mass index (kg/m ²)	27.8 (18.3–40.6)	22.2 (16.1–31.2)*
Total bilirubin (mg/dL)	0.7 (0.4–2.1)	0.7 (0.4–6.2)
AST (U/L)	53 (22–186)	53 (10–816)
ALT (U/L)	69 (20–213)	52 (10–933)
Platelet count ($\times 10^9$ /L)	22.5 (8.3–29.3)	20.0 (6.6–36.3)
Serum albumin (g/dL)	4.4 (3.3–5.4)	3.7 (2.1–5.0)*
Prothrombin time (%)	108.7 (74.2–136.9)	99.6 (21.0–145.0)
hs-CRP (mg/dL)	0.09 (0.01–1.02)	0.1 (0.01–25.8)
FIB4 index	1.8 (0.4–9.0)	2.5 (0.5–31.3)
Type 4 collagen 7s (ng/mL)	5.4 (2.0–12.0)	5.2 (2.4–15.0)
Vs (m/s)	1.5 (1.1–2.46)	1.9 (1.0–3.1)
LFI	2.8 (0.9–4.6)	2.3 (0.6–3.9)*

*Significant difference between NAFLD and non-NAFLD groups; $p < 0.05$.

Values are presented as number or median (minimum–maximum).

NAFLD, nonalcoholic fatty liver disease; AST, aspartate aminotransferase; ALT, alanine aminotransferase; hs-CRP, high-sensitive C-reactive protein; FIB4 index, fibrosis-4 index; LFI, liver fibrosis index; Vs, shear wave velocity.

groups (NAFLD, $p < 0.05$; non-NAFLD, $p < 0.01$). However, the fibrosis stage was correlated with LFI only in non-NAFLD patients ($p < 0.05$). Furthermore, the hepatitis grade was correlated with Vs in the non-NAFLD patients ($p < 0.01$), while the steatosis grade was correlated with LFI in the NAFLD patients ($p < 0.05$).

Influence of distance from the body surface to the liver surface on elastography results

Because thick subcutaneous fat deposition might affect elastography results by blocking ultrasound signals, the distance from the body surface to the liver surface was

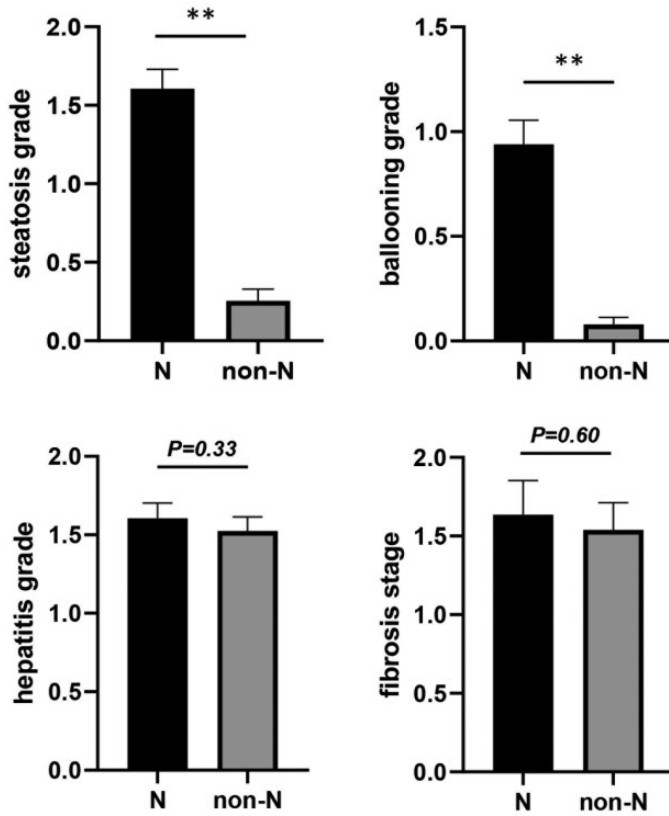


Figure 2. Histological grades for steatosis, ballooning, hepatitis, and fibrosis in NAFLD and non-NAFLD patients. The average score for each histological factor was also compared between the groups, and that of steatosis and ballooning were significantly higher in the NAFLD patients (** $p < 0.01$). NAFLD, non-alcoholic fatty liver disease; N, NAFLD group; n-N, non-NAFLD group.

analyzed with respect to its influence on Vs and LFI. The results indicated that the distance from the body surface to the liver (2.0 [1.0–3.0] cm, median [range]) was significantly correlated with the Vs value (Spearman's rank correlation analysis; $r = -0.25$, $p < 0.05$) but not with that of LFI (Spearman's rank correlation analysis; $r = 0.13$; Table 6).

Discussion

To the best of our knowledge, this is the first study to investigate the usefulness of combinational elastography for evaluating

liver fibrosis in NAFLD patients. The results revealed its usefulness for assessing liver fibrosis in patients with liver injury using Vs, as shown by pSWE results, and LFI, as shown by RTE results. When NAFLD and non-NAFLD patients were compared, there was no correlation between LFI and the liver fibrosis stage in the NAFLD patients. This indicates that the usefulness of RTE was relatively low in these cases.

To prevent hepatocellular carcinoma development in NAFLD patients, it is important to monitor liver fibrosis in clinical settings.^{4–8} Although various types of

Table 5. Correlation of each histopathologic parameter with Vs and LFI in NAFLD and non-NAFLD patients.

Explanatory variables	Vs*				LFI#				
	β	p value	r	p value	β	p value	r	p value	
NAFLD									
Fibrosis stage (0/1/2/3/4) = (6/12/6/6/3)	0.38	<0.05	0.34	<0.05	NE	NE	0.29	0.1	
Hepatitis grade (0/1/2/3) = (1/11/21/0)	NE	NE	0.05	0.78	NE	NE	0.14	0.43	
Steatosis grade [‡] (0/1/2/3) = (1/14/15/3)	NE	NE	0.01	0.94	0.42	<0.05	0.38	<0.05	
Ballooning grade (0/1/2) = (4/4/25)	NE	NE	0.31	0.08	NE	NE	0.2	0.26	
Non-NAFLD									
Fibrosis stage (0/1/2/3/4) = (16/22/9/7/9)	0.46	<0.01	0.57	<0.01	0.31	<0.05	0.41	<0.01	
Hepatitis grade (0/1/2/3) = (2/32/23/6)	0.36	<0.01	0.44	<0.01	0.23	0.06	0.28	<0.05	
Steatosis grade [‡] (0/1/2/3) = (51/9/2/1)	NE	NE	0.06	0.64	NE	NE	0.17	0.19	
Ballooning grade (0/1/2) = (57/6/0)	NE	NE	0.11	0.39	NE	NE	0.18	0.16	

*Vs was determined using pSWE.

LFI was calculated using RTE.

‡, steatosis grade was significantly higher in NAFLD as compared with non-NAFLD patients.

Vs, shear wave velocity; LFI, liver fibrosis index; NAFLD, nonalcoholic fatty liver disease; r, coefficient of correlation in univariate analysis; β , standard partial regression coefficient in multivariate analysis; pSWE, point shear wave elastography; RTE, real-time strain elastography; NE, not examined.

Table 6. Correlation of the distance from the body surface to the liver with Vs and LFI in all patients.

Variable	Vs		LFI		
	Spearman r	p value	Spearman r	p value	
All patients	Distance	-0.25	<0.05	0.13	0.20

Distance, distance from body surface to liver surface; Vs, shear wave velocity; LFI, liver fibrosis index.

noninvasive elastography including pSWE and RTE are used to evaluate liver fibrosis, no reports regarding the diagnostic accuracy of combinational elastography for assessing liver fibrosis in NAFLD patients have been presented.

A recent meta-analysis that included nine studies that used pSWE and enrolled 982 NAFLD patients showed that pSWE was a feasible imaging technique that enabled non-invasive liver fibrosis staging in such patients, particularly those with advanced fibrosis and cirrhosis.¹³ Although the average liver fibrosis stage in the NAFLD patients enrolled into the present study was relatively low, pSWE

was shown to have significant utility for assessing liver fibrosis even in those cases. The distance from the body surface to the liver was correlated with the Vs (Table 6), suggesting that thick subcutaneous fat deposition might influence the pSWE results that are used to evaluate liver fibrosis in obese patients, including those with NAFLD.

The usefulness of RTE for evaluating liver fibrosis in NAFLD patients remains controversial. Ochi et al. conducted a prospective investigation of 181 patients with NAFLD and found RTE to be useful for evaluating hepatic fibrosis in them.²⁸ Conversely, Tomeno et al. reported that

LFI that was calculated on the basis of RTE was not a useful index for evaluating liver fibrosis in their NAFLD patients.²⁹

Combinational elastography is currently considered to be applicable for evaluation of chronic liver disease, although liver tissues in a region that is different from the region examined using elastography were evaluated in previous studies.^{16,17} Thus, the present prospective study was designed to confirm the utility of combinational elastography for staging liver fibrosis by evaluating a liver biopsy sample obtained from the same area examined by elastography. The findings showed a positive correlation between liver fibrosis stage and Vs ($p < 0.01$) and LFI ($p < 0.01$) in all of the enrolled patients, indicating the usefulness of combination elastography for evaluating liver fibrosis in those with liver injury, which are consistent with the results of a previous study.¹⁷ The present enrolled cohort was divided into the NAFLD and non-NAFLD patients, and a comparative analysis between the groups was performed to examine whether pSWE and RTE are useful in assessing liver fibrosis. The results indicated a significant correlation between Vs and liver fibrosis stage in both groups, while LFI was not correlated with the liver fibrosis stage in the NAFLD patients. These findings suggest that RTE may be less useful than pSWE for evaluating the liver fibrosis stage in NAFLD patients.

A previous study investigated the combined use of strain and shear wave imaging in 383 patients with liver disease, including 43 NAFLD patients, and reported that LFI was correlated with liver fibrosis stage, although the diagnostic ability of LFI was reduced with stage progression.¹⁷ The reason for such a decreased diagnostic ability with progressing fibrosis stage in patients with liver disease was unclear. In the present NAFLD patients, LFI did not show a correlation with liver fibrosis stage, while a multivariate analysis indicated that

steatosis grade was correlated with LFI (Table 5). Because RTE visualizes the strain induced by the internal heartbeat and vibration of the inferior vena cava, as shown in images of the liver, it is thought that the presence of steatosis may reduce liver deformation, which might explain why RTE was less useful than pSWE in the present patients with NAFLD.

This study has several limitations, including the small number of patients treated at a single facility. Furthermore, disease types assigned to liver injury patients were heterogeneous, and a definitive diagnosis was not obtained in many of them. Sub-analyses of the NAFLD patients indicated that some of them were affected by diseases for which the usefulness of elastography has not been reported, suggesting that a strict comparison with non-NAFLD patients might not have been possible. To investigate individual related diseases, the number of patients enrolled should be increased in a future study.

In conclusion, to the best of our knowledge, this is the first study to compare the clinical usefulness of combinational elastography as a non-invasive tool for assessing liver fibrosis using biopsy specimens obtained from the same area that was examined by elastography in patients with chronic liver disease. The results revealed that combinational elastography had significant utility for examinations in the enrolled cohort, although RTE was less useful than pSWE for evaluating liver fibrosis in patients with NAFLD. Additional research is needed to refine the statistical methods used for the assessments performed with combinational elastography in patients with liver injury, including NAFLD.

Declaration of conflicting interests

The authors declared the following potential conflicts of interest with respect to the research, authorship, and/or publication of this article: Shunji Ishihara received honoraria for lecture

fees from Takeda Pharmaceutical Company, Ltd. and Abbvie GK. Tomotaka Yazaki, Hiroshi Tobita, Syuuichi Sato, Tatsuya Miyake, and Masatoshi Kataoka have no conflicts of interest to declare.

Funding

This research received no specific grant from any funding agency in the public, commercial, or not-for-profit sectors.

ORCID iD

Hiroshi Tobita  <https://orcid.org/0000-0003-2408-2023>

References

1. Kudo M. Prediction of hepatocellular carcinoma incidence risk by ultrasound elastography. *Liver Cancer* 2014; 3: 1–5.
2. Kudo M. Surveillance, diagnosis, treatment, and outcome of liver cancer in Japan. *Liver Cancer* 2015; 4: 39–50.
3. Clinical Practice guidelines for hepatocellular carcinoma differ between Japan, United States, and Europe. *Liver Cancer* 2015; 4: 85–95.
4. Angulo P, Kleiner DE, Dam-Larsen S, et al. Liver fibrosis, but no other histologic features, is associated with long-term outcomes of patients with nonalcoholic fatty liver disease. *Gastroenterology* 2015; 149: 389–397.
5. Dulai PS, Singh S, Patel J, et al. Increased risk of mortality by fibrosis stage in nonalcoholic fatty liver disease: systematic review and meta-analysis. *Hepatology* 2017; 65: 1557–1565.
6. Bravo AA, Sheth SG and Chopra S. Liver biopsy. *N Engl J Med* 2001; 344: 495–500.
7. Van der Poorten D, Kwok A, Lam T, et al. Twenty-year audit of percutaneous liver biopsy in a major Australian teaching hospital. *Intern Med J* 2006; 36: 692–699.
8. Regev A, Berho M, Jeffers LJ, et al. Sampling error and intraobserver variation in liver biopsy in patients with chronic HCV infection. *Am J Gastroenterol* 2002; 97: 2614–2618.
9. Ratziu V, Bellentani S, Cortez-Pinto H, et al. A position statement on NAFLD/NASH based on the EASL 2009 special conference. *J Hepatol* 2010; 53: 372–384.
10. Dietrich CF, Bamber J, Berzigotti A, et al. EFSUMB guidelines and recommendations on the clinical use of liver ultrasound elastography, update 2017 (long version). *Ultraschall Med* 2017; 38: e16–e47.
11. Liu J, Ren W, Ai H, et al. Acoustic structure quantification versus point shear wave speed measurement for the assessment of liver fibrosis in viral hepatitis B. *Ultrasound Med Biol* 2018; 44: 1177–1186.
12. Herrmann E, De Lédinghen V, Cassinotto C, et al. Assessment of biopsy-proven liver fibrosis by two-dimensional shear wave elastography: an individual patient data-based meta-analysis. *Hepatology* 2018; 67: 260–272.
13. Jiang W, Huang S, Teng H, et al. Diagnostic accuracy of point shear wave elastography and transient elastography for staging hepatic fibrosis in patients with non-alcoholic fatty liver disease: a meta-analysis. *BMJ Open* 2018; 8: e021787.
14. Koizumi Y, Hirooka M, Abe M, et al. Comparison between real-time tissue elastography and vibration-controlled transient elastography for the assessment of liver fibrosis and disease progression in patients with primary biliary cholangitis. *Hepatol Res* 2017; 47: 1252–1259.
15. Jieanu CF, Ungureanu BS, Sandulescu DL, et al. Real time elastography assessment of fibrosis in chronic viral hepatitis. *Curr Health Sci J* 2015; 41: 317–324.
16. Yada N, Sakurai T, Minami T, et al. Influence of liver inflammation on liver stiffness measurement in patients with autoimmune hepatitis evaluation by combinational elastography. *Oncology* 2017; 92: 10–15.
17. Yada N, Tamaki N, Koizumi Y, et al. Diagnosis of fibrosis and activity by a combined use of strain and shear wave imaging in patients with liver disease. *Dig Dis* 2017; 35: 515–520.
18. Von Elm E, Altman DG, Egger M, et al. The Strengthening the Reporting of

- Observational Studies in Epidemiology (STROBE) statement: guidelines for reporting observational studies. *Ann Intern Med.* 2007; 147: 573–577.
19. Shah AG, Lydecker A, Murray K, et al. Nash Clinical Research Network. Comparison of noninvasive markers of fibrosis in patients with nonalcoholic fatty liver disease. *Clin Gastroenterol Hepatol* 2009; 7: 1104–1112.
 20. Sumida Y, Nakajima A and Itoh Y. Limitations of liver biopsy and non-invasive diagnostic tests for the diagnosis of nonalcoholic fatty liver disease/nonalcoholic steatohepatitis. *World J Gastroenterol* 2014; 20: 475–485.
 21. Okanoué T, Ebise H, Kai T, et al. A simple scoring system using type IV collagen 7S and aspartate aminotransferase for diagnosing nonalcoholic steatohepatitis and related fibrosis. *J Gastroenterol* 2018; 53: 129–139.
 22. Yada N, Kudo M, Morikawa H, et al. Assessment of liver fibrosis with real-time tissue elastography in chronic viral hepatitis. *Oncology* 2013; 84: 13–20.
 23. Yada N, Kudo M, Kawada N, et al. Noninvasive diagnosis of liver fibrosis: utility of data mining of both ultrasound elastography and serological findings to construct a decision tree. *Oncology* 2014; 87: 63–72.
 24. Yada N, Sakurai T, Minami T, et al. A newly developed shear wave elastography modality: with a Unique Reliability Index. *Oncology* 2015; 89: 53–59.
 25. Brunt EM, Janney CG, Di Bisceglie AM, et al. Nonalcoholic steatohepatitis: a proposal for grading and staging the histological lesions. *Am J Gastroenterol* 1999; 94: 2467–2474.
 26. Kleiner DE, Brunt EM, Van Natta M, et al. Nonalcoholic Steatohepatitis Clinical Research Network. Design and validation of a histological scoring system for nonalcoholic fatty liver disease. *Hepatology* 2005; 41: 1313–1321.
 27. Bedossa P and Poynard T. An algorithm for the grading of activity in chronic hepatitis C. The METAVIR Cooperative Study Group. *Hepatology* 1996; 24: 289–293.
 28. Ochi H, Hirooka M, Koizumi Y, et al. Real-time tissue elastography for evaluation of hepatic fibrosis and portal hypertension in nonalcoholic fatty liver diseases. *Hepatology* 2012; 56: 1271–1278.
 29. Tomeno W, Yoneda M, Imajo K, et al. Evaluation of the liver fibrosis index calculated by using real-time tissue elastography for the non-invasive assessment of liver fibrosis in chronic liver diseases. *Hepatol Res* 2013; 43: 735–742.