

Contents lists available at [ScienceDirect](http://www.sciencedirect.com)

International Journal of Surgery Case Reports

journal homepage: www.casereports.com

A rare cause of root-compression: Subaxial cervical synovial cyst in association with congenital fusion



Tabea Breckwoldt^a, Tunc Oktenoglu^{b,*}, Mehdi Sasani^b, Tuncer Suzer^c, Ali Fahir Ozer^c

^a University of Fribourg, Faculty of Sciences, Fribourg, Switzerland

^b American Hospital, Neurosurgery Department, Istanbul, Turkey

^c Koc University Medical School, Neurosurgery Department, Istanbul, Turkey

ARTICLE INFO

Article history:

Received 23 July 2015

Received in revised form 18 August 2015

Accepted 11 September 2015

Available online 18 September 2015

Keyword:

Cervical synovial cyst

ABSTRACT

INTRODUCTION: Synovial cyst in the cervical spine is a very rare pathology that develops from the facet joint. When a synovial cyst emerges into the surrounding space, it can compress the nervous tissue and cause neurological symptoms. In the cervical area there is additionally the risk of spinal cord compression comparing to the more common presentation of synovial cysts in the lumbar spine.

PRESENTATION OF CASE: Here, a cervical synovial cysts from the left facet joint grew into the spinal canal and compressed the C8 nerve root which led to root compressing symptoms. Interestingly we found this synovial cyst with congenital fusion. We identified only nine similar cases in the literature. The cyst was removed surgically and the patient discharged without complications.

DISCUSSION: Numerous theories have been established to explain the pathogenesis of synovial cyst. Biomechanical alterations of the spine play a significant role in the development of synovial cyst. However, the etiology is still unclear.

CONCLUSION: Surgical treatment should be considered in cervical synovial cysts with neurologic deficit or with cord compression or when the conservative treatment is ineffective.

© 2015 The Authors. Published by Elsevier Ltd. on behalf of Surgical Associates Ltd. This is an open access article under the CC BY-NC-ND license (<http://creativecommons.org/licenses/by-nc-nd/4.0/>).

1. Background

Synovial cysts are infrequent findings in the spine; when they appear, they are mostly located in the lumbar area. Even rarer is the occurrence of a synovial cyst in the cervical spine [1]. The pathology arises from the facet joint and may cause pain, radiculopathy or myelopathy [2,3]. On the background of the international literature, we report this uncommon case of a cervical synovial cyst associated with congenital fusion, including our therapeutic approach.

2. Case

2.1. History and clinical findings

This 57 year old female patient with neck and left arm pain. The symptoms started six weeks prior. There was no history of trauma. Initially, the patient was put in conservative treatment with painkillers and she also received physiotherapy for a short time period. Despite these therapies, the patient's pain continued. When presenting at our institution the patient complained of left arm pain beginning in the region of the scapula and shoulder, radiating to the forearm and the fingers IV and V.

Neurological examination revealed a slight motor weakness (1/5) of left triceps muscle. There was no loss of sensation.

2.2. Imaging and differential diagnosis

MRI-scans showed a cyst at C7–T1 level located dorsolaterally on the left side with connection to the left facet joint. Also, radiographic sign of congenital fusion was observed at C3–C4 level (Fig. 1a). The remaining cervical discs were highly degenerated, even C7–T1 level showing degenerative spondylolisthesis with the respective cyst (Fig. 1a). The cyst caused compression on left C8 nerve root (Fig. 1).

2.3. Operative procedure

The patient operated in the prone position under general anesthesia. After conformation of the correct level, posterior midline incision was performed and the cyst was totally removed following unilateral muscular dissection only on the left side, under the microscope. No complication occurred during surgery.

3. Outcome and follow-up

The post-operative period was uneventful. The patient was discharged in third postoperative day. The patient was followed in postoperative 3rd, 6th and 12th months. She showed only mild neck

* Corresponding author. Fax: +90 212 311 23 44.

E-mail address: tuncoktenoglu@gmail.com (T. Oktenoglu).

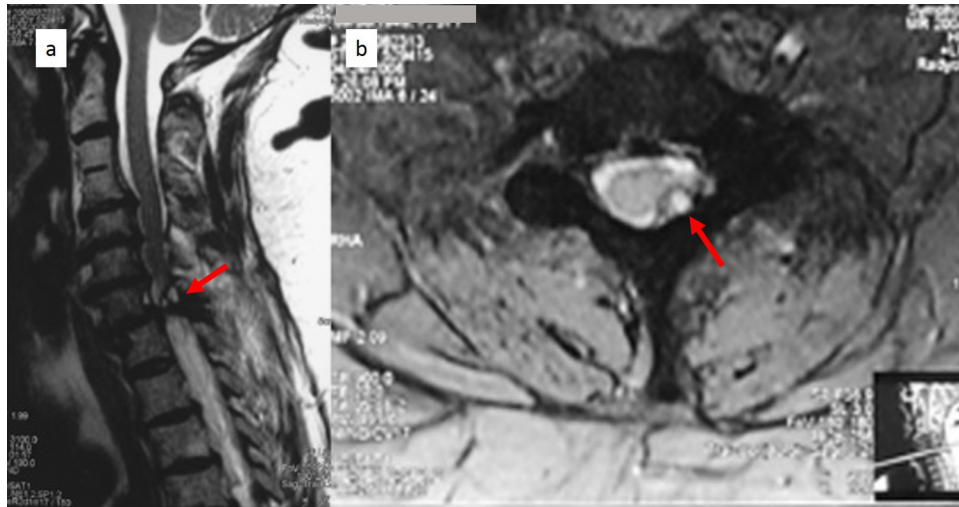


Fig. 1. (a) T2 weighted sagittal MRI shows C2–C3 congenital fusion, C7–T1 spondylolisthesis and C7–T1 synovial cyst (arrow) and (b) T2 weighted axial MRI shows C7–T1 left sided synovial cyst (arrow).

pain that relieved with painkillers. Slight motor weakness observed at triceps muscle improved within 3 months. She did not developed arm pain in control follow-ups.

Histopathological diagnosis was reported as synovial cyst.

4. Discussion

In the study presented here, a case of subaxial cervical synovial cyst with congenital fusion is described. Intraspinial cysts are unusual abnormalities [4], thus the occurrence of synovial cysts in the cervical region is especially a rarity.

4.1. Symptoms and epidemiology

Signs of a symptomatic cervical synovial cyst are mainly neck pain, pain in upper limbs, radiculopathy and myelopathy [2,3,5,6], all caused by nerve root and/or spinal cord-compression [7]. Brown-Séquard syndrome [8], acute myelopathie and spontaneous haemorrhage have been described in coherence with cervical synovial cysts [2,5]. The symptoms are similar to all other space-occupying processes, which can make diagnosis difficult [5]. The patient presented here showed only nerve root irritation findings. Triceps brachii is innervated mainly by C6, C7 and a minor contribution from C8 nerve roots [9]. The clinical findings observed in neurologic examination; pain distribution and slight motor weakness at triceps muscle was due to left C8 nerve root compression.

The mean age of patients with symptomatic subaxial cervical synovial cysts in numerous studies ranges from 62 to 79 years [3]. The youngest patient mentioned in the reviewed literature was 16 years and the oldest 86 years [3,10].

Most commonly, as all types of intraspinal, extradural cysts, [4] subaxial cervical synovial cysts are located at the level C7–T1 [1–3,11]. They appear most infrequently on level C2–C3 and C5–C6 [2,3]. The transitional joint is more affected than the middle levels. At the C7–T1 segment the elastic cervical spine interacts directly with the firm thoracic spine. So, there may be differently pronounced biomechanical forces and a risk for instability in particular [1,5].

Our patient fits well in epidemiological criteria.

We propose, that the possible mechanism of synovial cyst development in our patient could have been as follows: the partially fused vertebrae of the C3 and C4 levels enhance the load on spine

while, reducing the number of functional segments. Congenital fusion in spine cause hypermobility and increased loading on adjacent segments and this leads to degeneration of intervertebral discs. Altogether, this might have increased the existent biomechanical impact on the cervico–thoracic joint and has eventually led to the formation of the cyst. Spondylolisthesis of C7–T1 is also a sign of advanced degeneration as seen on our patient. To our knowledge, this is the tenth reported cervical synovial cyst in conjunction with congenital fusion [2,11].

4.2. Aetiology

A number of case reports and case series have accurately described the morphology of synovial cyst in the subaxial cervical area [11]. Connections to other processes like degenerative changes, rheumatoid arthritis, congenital factors and trauma have been drawn [2]. Coherent theories have been established about their pathogenesis of synovial cysts [11]. However, at the end of the day their aetiology remains unclear [3,12].

4.3. Clinical diagnostic and treatment

In respect to clinical diagnostics, MR-imaging is the best established technique for visualizing synovial cysts [5,12]. Moreover, MR-study helps to distinguish synovial cyst from other cysts located in spine. The synovial cyst differs histologically from the ganglion cyst concerning synovial lining, the containing fluid and existing connection to the facet joint; synovial cysts are defined as cystic dilatations of the synovium [13]. This differential diagnosis can be important for surgical treatment, because of the drift of synovial cysts adhering to the dura [7].

Furthermore, the incidence of synovial cysts is increasing because of the eased availability of MR- and CT-imaging [1,3].

In case of significant/intense symptoms further treatment of cervical synovial cysts is usually surgical decompression and extinction of the cyst [1,6,14]. But it remains controversial whether a fusion augmentation is indicated [3,5,11]. Only few reports describe minimalized surgery, like CT guided aspiration or a non-surgical approach [15,16]. These minimalized procedures can be acceptable for the lumbar region, however, in the cervical region higher safety is demanded due to the risk of spinal cord compression.

After surgery, patients usually recover well and show pain relief quickly [1,7]. We found no report regarding a synovial cyst recurrence in the cervical area [6,11].

Patient consent

Written informed consent was obtained from the patient for publication of this case report and accompanying images. A copy of the written consent is available for review by the Editor-in-Chief of this journal on request.

Conflicts of interest

No any conflicts of interest.

Funding

No any sources of funding.

Ethical approval

No need.

Authors contribution

Tabea Breckwoldt: writing the paper.
Tunc Oktenoglu: study concept and design, writing the paper.
Mehdi Sasani: data collection.
Tuncer Suzer: data analysis or interpretation.
Ali Fahir Ozer: data collection, study concept or design.

Guarantor

Tunc Oktenoglu.
American Hospital, Neurosurgery Department.

References

- [1] M.K. Lyons, B.D. Birch, W.E. Krauss, N.P. Patel, E.W. Nottmeier, O.K. Boucher, Subaxial cervical synovial cysts, report of 35 histologically confirmed surgically treated cases and review of the literature, *Spine* 36 (2011) 1285–1289.
- [2] L. Attwell, V.A. Elwell, A. Meir, Cervical synovial cyst, *Br. J. Neurosurg.* 28 (2014) 813–814.
- [3] S. Piskis, J.E. Cohen, Y. Barzilay, A. Hasharoni, L. Kaplan, E. Itshayek, Symptomatic facet cysts of the subaxial cervical spine, *J. Clin. Neurosci.* 20 (2013) 928–932.
- [4] M. Machino, Y. Yukawa, K. Ito, F. Kato, Cervical degenerative intraspinal cyst: a case report and literature review involving 132 cases, *BMJ Case Rep.* (2012), <http://dx.doi.org/10.1136/bcr-2012-007126>.
- [5] E.F. Bisson, J.C. Sauri-Barraza, T. Niazi, M.H. Schmidt, Synovial cysts of the cervicothoracic junction causing myelopathy: report of 3 cases and review of the literature, *Neurosurg. Focus* 35 (2013) 1–7.
- [6] F. Costa, C. Menghetti, A. Cardia, M. Fornari, A. Ortolina, Cervical synovial cyst: case report and review of literature, *Eur. Spine J.* 2 (2010) 100–102.
- [7] T. Hakan, F. Varder Aker, Cervical synovial cyst: case report, *Turk. Neurosurg.* 12 (2002) 55–58.
- [8] S.W. Kim, C.I. Ju, H.S. Kim, Y.S. Kim, Brown-Séquard syndrome caused by a cervical synovial cyst, *J. Kor. Neurosurg. Soc.* 55 (2014) 215–217.
- [9] R. Drake, A.W. Vogl, A.W.M. Mitchell, *Gray's Anatomy for Students*, 2nd ed., Churchill Livingstone, Philadelphia, 2010.
- [10] G. Overvliet, M.A. van Scherpenzeel-de Vries, M.P. Wattjes, R.J. Vermeulen, Cervical synovial cyst in a 16-year-old girl, *Pediatr. Neurol.* 0887–8994 (15) (2015) 113–117.
- [11] M. Bydon, J.A. Lin, R. de la Garza-Ramos, D.M. Sciubba, J.P. Wolinsky, T.F. Witham, et al., The role of spinal fusion in the treatment of cervical synovial cysts: a series of 17 cases and meta-analysis, *J. Neurosurg. Spine* 21 (2014) 919–928.
- [12] G. Kahilogullari, H. Tuna, A. Attar, Management of spinal synovial cysts, *Turk. Neurosurg.* 18 (2008) 211–214.
- [13] C.C. Kao, S. Winkler, J.H. Turner, Synovial cyst of spinal facet: case report, *J. Neurosurg.* 41 (1974) 372–376.
- [14] J.K. Song, W. Musleh, S.D. Christie, R.G. Fessler, Cervical juxtafacet cysts: case report and literature review, *Spine J.* 6 (2006) 279–281.
- [15] C.B. Colen, A. Rengachary, Spontaneous resolution of a cervical synovial cyst, *J. Neurosurg. Spine* 4 (2006) 186.
- [16] V.J. Konstanian, M.S. Mathews, CT guided aspiration of a cervical synovial cyst, case report and technical note, *Interv. Neuroradiol.* 13 (2007) 295–298.

Open Access

This article is published Open Access at sciedirect.com. It is distributed under the [IJSCR Supplemental terms and conditions](#), which permits unrestricted non commercial use, distribution, and reproduction in any medium, provided the original authors and source are credited.