

Received: 2020.06.05

Accepted: 2020.07.26

Available online: 2020.08.17

Published: 2020.09.21

# Natural Killer (NK)//T-Cell Lymphoma, Nasal Type, with Periorbital Involvement: A Case Report and Literature Review

## Authors' Contribution:

Study Design A  
Data Collection B  
Statistical Analysis C  
Data Interpretation D  
Manuscript Preparation E  
Literature Search F  
Funds Collection G

AB 1 **Grażyna Lisowska**  
EF 1 **Natalia Zięba**  
F 2 **Grażyna Stryjewska-Makuch**  
F 1 **Wojciech Ścierański**  
B 1 **Katarzyna Miśkiewicz-Orczyk**  
A 1 **Maciej Misiótek**

1 Department of Otorhinolaryngology and Laryngological Oncology in Zabrze, Medical University of Silesia in Katowice, Zabrze, Poland

2 Department of Laryngology and Laryngological Oncology, Independent Public Research Hospital No. 7 of The Silesian Medical University in Katowice, Upper Silesian Medical Centre, Katowice, Poland

**Corresponding Author:** Natalia Zięba, e-mail: [natalia.zieba.ent@gmail.com](mailto:natalia.zieba.ent@gmail.com)

**Conflict of interest:** None declared

**Patient:** Female, 36-year-old  
**Final Diagnosis:** NK/T-cell lymphoma  
**Symptoms:** Nasal congestion • rhinorrhea • sinus congestion  
**Medication:** —  
**Clinical Procedure:** —  
**Specialty:** Otolaryngology

**Objective:** Rare disease

**Background:** Extranodal natural killer (NK)/T-cell lymphomas are rare neoplasms that result in the destruction of mid-facial tissues. Infrequently seen in ear, nose, and throat clinical practice, they are often misdiagnosed and treated as chronic sinusitis, which delays proper diagnosis. This study aimed to describe the insidious course of NK/T-cell lymphomas, nasal type.

**Case Report:** A 36-year-old woman with a 2-year history of recurrent exacerbation of chronic sinusitis and allergies was admitted to our clinic. Multiple endoscopic sinus surgical procedures were performed. Repeated histopathological tissue examinations revealed extranodal NK/T-cell lymphoma, nasal type. Positron emission tomography combined with computed tomography (PET-CT) was performed to assess the extent of the disease. The patient was treated with antibiotics, steroids, and antifungal drugs for many months before the definitive diagnosis was made. The patient was eligible for modified SMILE chemotherapy; however, the patient died suddenly from septic shock several days before the beginning of treatment.

**Conclusions:** Chronic rhinosinusitis with progressive necrosis of sinonasal tissue that persists despite adequate antibacterial and antifungal treatment should prompt further investigation. In such cases, it is important to consider the diagnosis of NK/T-cell lymphomas, nasal type. Early diagnosis increases the opportunity for successful treatment.

**MeSH Keywords:** Lymphoma, Extranodal NK-T-Cell • Paranasal Sinus Diseases • Paranasal Sinus Neoplasms • Sinusitis

**Full-text PDF:** <https://www.amjcaserep.com/abstract/index/idArt/926599>




2762



—



3



29



## Background

In most Western countries, especially in North America and Europe, natural killer (NK)/T-cell lymphoma is a rare neoplasm seldom seen in clinical practice [1]. Most non-Hodgkin lymphomas of the head and neck are diffuse large B-cell lymphomas [2,3]. Extranodal NK/T-cell lymphomas can affect the nose and sinuses (the nasal type) or can involve other organs such as the testes, lungs, skin or gastrointestinal tract [1,4].

Extranodal NK/T-cell lymphomas, nasal type, are most prevalent in Asia, Mexico, and Central and South America [4–9] where the prevalence is estimated to account for 3% to 10% of all lymphomas [5]. However, nasal type extranodal NK/T-cell lymphomas account for less than 1% of all lymphomas in Western countries [2,5,6]. The disease is more prevalent in men and the mean age of onset is 50 years [2,4,10]. Its etiology is unknown; however, it is strongly associated with Epstein-Barr virus (EBV) infection [1,9–12]. Past exposure to pesticides is reported to be a probable causative factor for the disease [1].

NK/T-cell lymphomas, nasal type, were formerly known as mid-line lethal granulomas [4,5,13–15]. The disease results in the destruction of mid-facial tissues [5,16] and is most commonly found in the nasal cavity (80.5%), maxillary sinus (6.22%), and ethmoid sinus (3.7%) [4].

The onset of the NK/T-cell lymphoma, nasal type, is often insidious. The condition is frequently mistaken for chronic sinusitis with a different etiology, allergy, or autoimmune reaction [15–17]. Patients most often present with nasal obstruction, nasal purulent discharge, or epistaxis [1,2,10, 16], and these symptoms become more intense over time. Ulceration and destruction of mid-facial tissues including the nasal cavity, sinuses, and hard palate are observed [18]. Systemic symptoms such as weight loss, night sweats, or fever indicate the stage of the disease and are associated with a poor prognosis [2,9,19]. The diagnosis is established based on the histopathological and immunohistochemical findings of tissue samples collected from the affected area [1,15].

Cluster of differentiation (CD)2, CD3, CD7, CD43, and CD45 antigens are common in NK cells and T lymphocytes, and CD16, CD56, and CD57 antigens are characteristic of NK cells. They are characterized by the absence of the T-cell receptor and surface CD3(–) [7,20]. NK/T-cell lymphomas, nasal type, may express cytotoxic molecules such as T1A-1, granzyme B, and perforin and are most often characterized by the presence of cytoplasmic CD3(+) antigen and the absence of surface CD3(–) [1,7,10,13,21].

Because lymphomas are neoplasms which show increased fluorodeoxyglucose (FDG) uptake (they are FDG-avid lesions),

positron emission tomography combined with computed tomography (PET-CT) is the first-line modality in the assessment of the location and extent of a tumor [21–23].

The stage of NK/T-cell lymphoma, nasal type, is established using the Ann Arbor staging system, specifically as related to the presence of B symptoms, and the International Prognostic Index [1,12,16,19]. The prognosis in this group of lymphomas is usually poor and depends on the initial stage of the disease. Chemoradiotherapy is the preferred approach. Novel treatment regimens will hopefully contribute to a better prognosis for patients with this type of lymphoma.

## Case Report

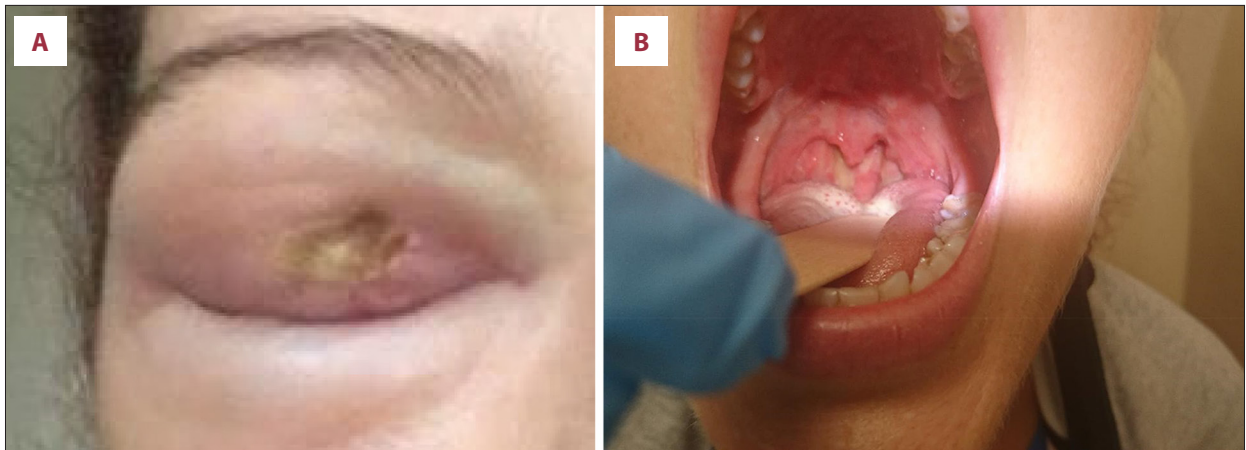
A 36-year-old woman with a 2-year history of chronic sinusitis and allergy was admitted to our clinic in June 2016. Her previous medical history was irrelevant, except for a diagnosis of chronic sinusitis in 2014. The patient presented with no history of other chronic diseases. However, edema and intense pruritus of the right eyelid were observed (Figure 1A). The patient associated the symptoms with an allergic reaction to a ferulic acid peel, and, as a result, systemic steroids were administered. However, the reoccurrence of edema was observed.

A sinus CT revealed bilateral sinusitis (Figure 2A), ethmoid sinus opacification, maxillary sinusitis, and peripheral edema of the frontal sinus. Endoscopic sinus surgery was performed and tissue samples were collected intraoperatively. Histopathological evaluation revealed inflammatory polyps of the respiratory tract with numerous eosinophils.

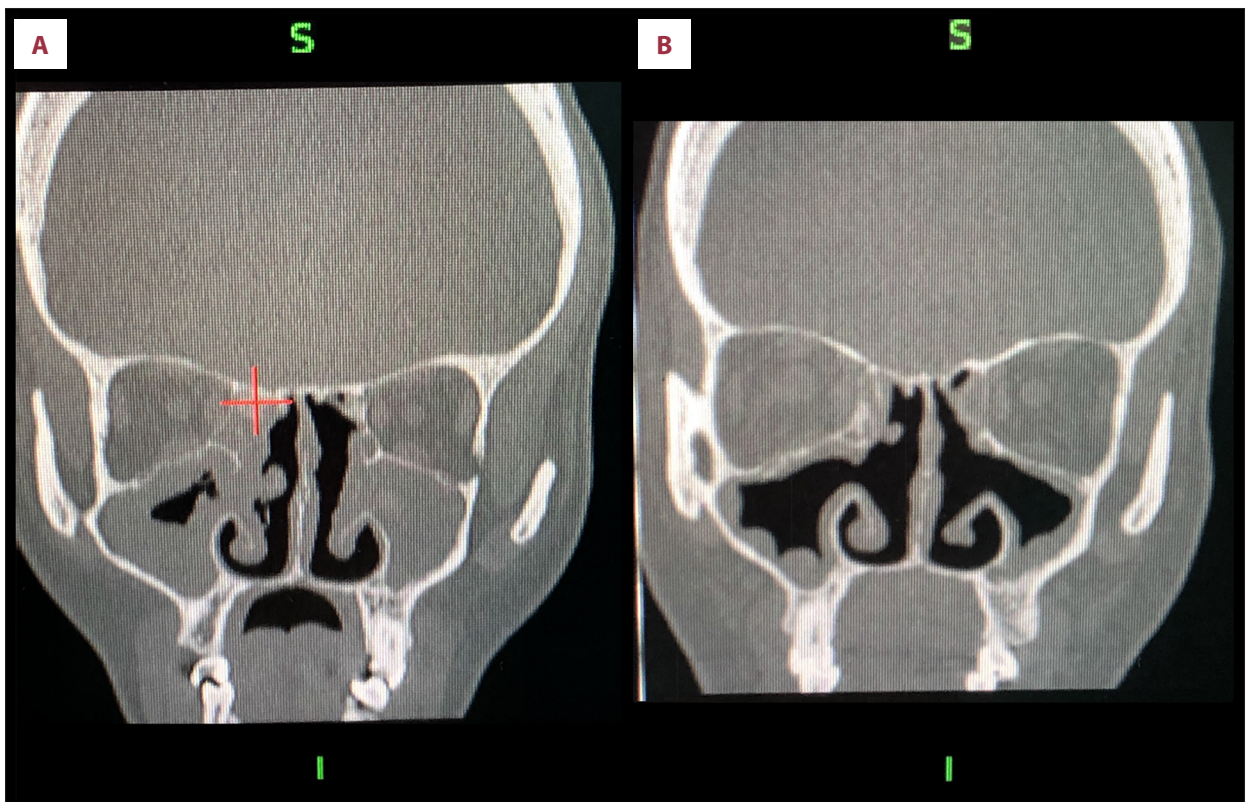
Because of persistent symptoms, the patient was referred for ophthalmological, neurological, and allergological assessment. Skin prick tests were performed, and the patient was evaluated for suspected Quincke's edema. However, no abnormalities were found.

In October 2016, the patient's symptoms recurred, and computer-assisted endoscopic sinus surgery was performed (Draf type IIa; right frontal sinus). Repeated tissue sample collection was performed. The samples were sent for histopathological examination, which revealed that a fragment of the airway mucous membrane had profuse chronic inflammatory infiltration, including single eosinophils.

At that stage the physical examination revealed ulceration of the nasal septum. Tissue samples were collected from the affected area. However, the histopathological finding "necrosis with bacterial colonies" was inconclusive. Periorbital cellulitis was suspected. Repeated ophthalmological assessment was performed. Magnetic resonance imaging (MRI) showed edema of the right orbital adipose tissue, with no other abnormalities.



**Figure 1.** (A) Edema and ulceration of the right eyelid. (B) Ulceration of the uvula, hard palate, and palatine tonsils.



**Figure 2.** (A) CT scan coronal view: recurrent bilateral sinusitis. (B) Subsequent CT scan, coronal view.

In November 2016, the patient was readmitted to our hospital because of the intensity of her symptoms, and amoxicillin with clavulanic acid and metronidazole were administered. The patient's condition improved following the treatment.

However, the recurrence of symptoms was observed in April 2017. The patient reported pruritus and edema of the right eyelid as well as anosmia and nasal dryness. Laryngological examination showed necrosis of the nasal mucosa involving the nasal septum, with perforation of the nasal cartilage.

The results of the repeated CT scan were similar to the previous CT findings.

Microbiological assessment of ocular secretion revealed the presence of *Demodex*, and the orbital symptoms were interpreted as *Demodex*-related infection. Nasal culture revealed *Klebsiella Pneumoniae* and *Pseudomonas aeruginosa*. Intravenous clarithromycin was given, which resulted in an excellent therapeutic effect. Consequently, a remission lasting several months was obtained.

In October 2017, repeated endoscopic sinus surgery was performed. Tissue samples were collected and histopathological examination revealed chronic sinusitis. Clindamycin and dexamethasone were administered intravenously because of persistent inflammatory symptoms and significant sinonasal edema, which resulted in improvement in the patient's general condition.

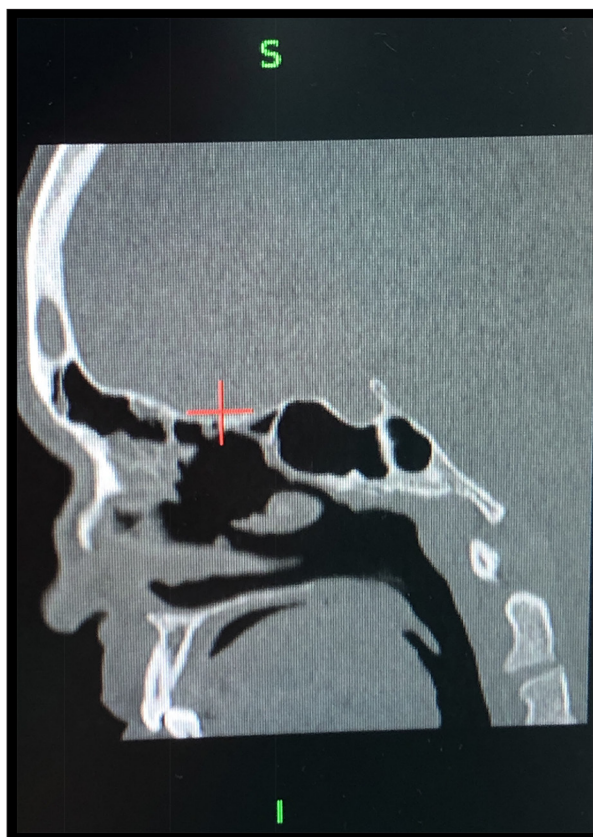
Symptoms of variable severity became persistent. The patient was readmitted to our hospital in April 2018. Physical examination identified nasal odor and anterior rhinoscopy showed nasal cavity crusting and a large amount of purulent content. In addition, the physical examination showed edema and redness of the right upper eyelid, inflammation and ulceration of the uvula, hard palate, and palatine tonsils (Figure 1B). The oral mucous membrane was swollen. Indirect laryngoscopy revealed no abnormalities. Endoscopic sinus surgery was performed for the fourth time (Figure 2B). However, histopathological examination did not reveal any new findings. Dexamethasone, ciprofloxacin, cefuroxime, and analgesics were administered. The patient was assessed by the immunology department. Flow cytometry revealed decreased B cells and a normal immunoglobulin level. In May 2018, the patient presented with high fever (40°C), night sweats, and weight loss.

Physical examination revealed an increasing perforation of the nasal septum and progressive necrosis of nasal and hard palate tissues (Figure 3). Furthermore, deep diffuse ulcerations of the soft palate and the mid-pharynx were noted. Fungal infection was diagnosed and nystatin and gentamycin were given intravenously. Examination for immunodeficiency and autoimmune diseases was negative, except for positive antinuclear antibodies.

A high-resolution CT revealed transient ground-glass opacification in the third segment of the right lung and the tree-in-bud sign at the base of both lungs. The abdominal ultrasound was unremarkable.

Wegener's granulomatosis was suspected because of the progressive necrosis that was unresponsive to previous treatment in June 2018; however, the histopathological examination did not confirm it. The patient was referred for ophthalmological, allergological, immunological, oncological, and hematological assessment and was also screened for infectious diseases.

The clinical picture was suggestive of extranodal NK/T-cell lymphoma, nasal type. The definitive diagnosis was established after repeated tissue samples from the sinuses were collected and assessed. The results of the histopathological examination obtained from the right ethmoid sinus showed a fragment of respiratory mucosa with extensive ulceration and areas of necrosis with abundant inflammatory infiltration with numerous



**Figure 3.** CT scan sagittal view: nasal septum perforation, nasal collapse, and deformation.

macrophages (CD68+), small B lymphocytes (CD20+) and CD 2+, CD 3+ (some of them with cytoplasmic staining), CD56+, granzyme B+, anaplastic lymphoma kinase (CD246)-, CD15-, CD25-, epithelial membrane antigen-, and paired box protein-5- and EBV-positive neoplastic cells. CD68+ and CD20+ cells were part of the reactive cells' background in this case. The proliferative activity of the Ki-67 antigen was about 50%. The results of immunohistochemistry excluded the diagnosis of anaplastic large-cell lymphoma. The histopathological specimen examination in conjunction with the clinical image confirmed the diagnosis of extranodal NK/T-cell lymphoma, nasal type.

The PET scan showed parietal lesions in the ethmoid region, and sphenoid and maxillary sinuses. Increased metabolic activity was observed in the 18F-FDG PET (SUVmax, 8.2) and was found in the nasal bridge, lower nasal septum, posterior wall of the nasopharynx, roof, and left parapharyngeal space.

Tissue masses that did not show metabolic activity were observed bilaterally in the frontal sinuses. In addition, increased metabolic activity was observed in the lymph node on the left side (Level 2; 9×11 mm; SUVmax, 3.9). Metabolic activity of the left medial pterygoid muscle (SUVmax, 5.0) was observed, which was suggestive of functional changes or infiltration. Pathological FDG

accumulation was not found in the chest or abdominal cavity. No clear focal lesions were found in the osteoarticular system. After PET analysis, the patient's tumor was classified as stage T3.

In the beginning of August 2018, increased C-reactive protein and lactic acid dehydrogenase (LDH) were observed (79.49 mg/L and 385 U/L, respectively). However, the general condition of the patient was good and she was eligible for modified SMILE chemotherapy, which includes IV methotrexate 2000 mg/m<sup>2</sup> (day 1), IV dexamethasone 40 mg with IV ifosfamide 1500 mg/m<sup>2</sup> and etoposide 100 mg/m<sup>2</sup> (days 2–4), and IV or IM PEG-L-asparaginase 1500–2500 IU/m<sup>2</sup> (day 8). Cycles of chemotherapy are repeated every 3 weeks with consecutive radiotherapy 45–50.4 Gy (2–4 cycles).

The patient died suddenly from septic shock several days before the beginning of the treatment.

## Discussion

Our case shows that the diagnosis of NK/T-cell lymphoma, nasal type, was delayed compared to the onset of the first symptoms, which agrees with the observations of other authors [16]. Our diagnostic procedures and approaches before establishing the definitive diagnosis were similar to those reported in the literature [1]. One reason for the delay in diagnosis is that NK/T-cell lymphoma is rare, especially at our latitude. Clinicians do not always consider this diagnosis, particularly in the early stage of the disease. First symptoms are often suggestive of chronic sinusitis. Furthermore, this suspicion is frequently confirmed by histopathological findings of tissues samples collected during endoscopic sinus surgery [1,16], which result in implementation of treatment for chronic sinusitis, which leads to periodic remissions. Therefore, the disease progresses and the definitive diagnosis is delayed [10].

The clinical course is characterized by progressive tissue necrosis with ulceration and extensive crusting. Such conditions favor secondary bacterial and fungal infections that can be misdiagnosed as the underlying disease. Consequently, patients are treated with antibiotics or antifungal drugs for many weeks or even months. Symptoms due to superinfection commonly decrease after pharmacological treatment and patients report improvement; however, this delays establishing the correct diagnosis.

Therefore, the determination of the attending physician during the diagnostic process is of crucial importance because multiple tissue collections are often necessary for histopathological examination [1,2,4,5,10,15,17,24].

The importance of collecting an adequate tissue sample for histopathological examination is significant [16]. The sample

should be forwarded to an experienced pathologist for assessment while fresh [1,24]. Establishing the diagnosis is difficult because NK/T-cell lymphoma displays extensive necrosis and a small number of cancer cells in the affected area [15,25].

Sanchez-Romero et al. [11] reported that a biopsy collected through the oral cavity from a pathologically altered tissue can have significant diagnostic value and concluded that oral tissue samples are more representative than nasal biopsies. Oral biopsies were characterized by less necrosis, superimposed inflammation, and infection [11]. In the present case, several nasal and sinus biopsies were taken because the disease process seemed to be the most extensive in these areas. However, it is worth remembering the above-cited report and performing oral biopsy if possible.

Miyake et al. analyzed patients diagnosed with NK/T-cell lymphoma, nasal type, in Sao Paulo, Brazil, from January 2005 to June 2013 and reported that the time from symptom onset to histopathological diagnosis ranged between 2 months and 1 year [15]. Sands et al. reported that the mean time to diagnosis was 21.5 months [26].

An infection caused by *P. Aeruginosa* can mimic NK/T-cell lymphoma [5], as was the case with our patient. Cases suggestive of periorbital cellulitis were also reported before establishing the definitive diagnosis of NK/T-cell lymphoma [5,18,25,27].

Termote et al. [8], in a series of cases with periorbital involvement, emphasized that painless periorbital cellulitis with chronic sinusitis not responding to conventional therapy raises suspicion of NK/T-cell lymphomas. Additionally, they reported that periorbital involvement is associated with poor prognosis and is a sign of advanced disease [8].

The clinical picture characterized by progressive tissue necrosis due to small-vessel occlusion could be suggestive of Wegener's granulomatosis, particularly because it is more prevalent than NK/T-cell lymphoma, nasal type [13,24]. In previously reported cases, autoimmune diseases were also suspected [1].

Other diseases that result in the destruction of mid-facial tissues which should be considered in the differential diagnosis include other types of lymphomas, tertiary syphilis, squamous cell carcinoma, fungal infections, leishmaniasis, and cocaine abuse [1,10,14,15].

In particular, diffuse large B-cell lymphomas should be considered in the differential diagnosis of NK/T-cell lymphomas, nasal type. The disease process in this type of lymphoma affects mostly the paranasal sinuses, whereas the nasal cavity is usually not involved [20].

Persistent or recurrent fever of unknown origin should always prompt further investigation. Soon et al. reported that lymphoma should be suspected in all patients with sinonasal symptoms and persistent or recurrent fever that is unresponsive to treatment [16]. Similarly, weight loss or night sweats should prompt further assessment [10].

Harabuchi et al. described the most common symptoms among their patients with NK/T-cell lymphomas and reported that nasal obstruction was present in 70–80% of patients, bloody rhinorrhea in 44–47%, B symptoms in 31–53%, and high LDH in 20–40% [9]. In their cohort study, Lee et al. reported that several factors are related with poor survival such as elevated LDH, the presence of B symptoms, regional lymphadenopathies, and bone marrow involvement [28]. Group B symptoms are generally considered to be a negative prognostic factor for the disease and occur more frequently in the advanced stage [2,13]. Vazquez et al. compared sinonasal NK/T-cell lymphomas and extranasal NK/T-cell lymphomas and reported that B symptoms were related to worse survival only in extranasal disease [4].

Chemoradiotherapy is the standard treatment of NK/T-cell lymphoma. The CHOP protocol which includes cyclophosphamide, doxorubicin, vincristine, and prednisolone was formerly used. However, this treatment was associated with poor long-term outcomes [23]. NK/T-cell lymphoma, nasal type, is resistant to anthracyclines because of the expression of P-glycoprotein in most lymphoma cells [29].

According to the current recommendations, one of the following treatment regimens is proposed for the limited stage: radiotherapy (RT) and chemotherapy with dexamethasone, etoposide, ifosfamide, carboplatin (DeVIC), also known as RT-DeVIC therapy. Radiation therapy is administered at a total dose of 50 Gy. Concurrently, DeVIC is performed in 3 cycles. Cisplatin-based concurrent chemoradiation is preceded by 3 cycles of VIPD (etoposide, ifosfamide, cisplatin, and dexamethasone), 2 cycles of VIDL (etoposide, ifosfamide, dexamethasone, and

L-asparaginase). The final option is modified SMILE (methotrexate, dexamethasone, ifosfamide, etoposide, and PEG-L-asparaginase) with consecutive RT at a total dose of 45–50.4 Gy for 2–4 cycles. For advanced stage, SMILE preceded by autologous hematopoietic cell transplantation (auto-HCT) or allogeneic hematopoietic cell transplantation (allo-HCT) is recommended. If relapse occurs, SMILE is recommended preceded by auto-HCT or allo-HCT; or AspaMetDex (L-asparaginase, methotrexate, dexamethasone) preceded by auto-HCT or allo-HCT [1,19,21,22].

When relapse or resistance to chemotherapy is observed, novel immunotherapy-based methods are proposed. Recent reports indicate promising results of treatment with checkpoint inhibitors, such as pembrolizumab and nivolumab, which are anti-programmed cell death-1 monoclonal antibodies [6,9,29].

Novel treatment methods have improved the 5-year survival in the limited stage from 63.2% before 2010 to 79.4% after 2010. In the advanced stage, 2-year survival was 30.3% before 2010, increasing to 40.5% after 2010 [29].

## Conclusions

The presence of persistent or recurrent symptoms such as nasal obstruction, purulent or bloody nasal discharge (often unilateral), tissue edema, and ulceration despite conventional antibacterial and antifungal treatment should prompt further investigation. Regularly repeated biopsies are needed to establish a final diagnosis of NK/T-cell lymphomas, nasal type.

Progressive necrosis with sinonasal tissue destruction of unknown origin accompanied by general symptoms such as night sweats, weight loss, and paroxysmal high fever should always raise the suspicion of NK/T-cell lymphoma, nasal type. Early diagnosis increases the chance of successful treatment and positive patient outcomes.

## References:

1. Coia B, Vucinic I, Mahovne I, Vukovic-Arar Z: Extranodal lymphomas of head and neck with emphasis on NK/T-cell lymphoma, nasal type. *J Craniomaxillofac Surg*, 2014; 42(2): 149–52
2. Kiessling SY, Soyka MB, Huber GF et al: Delayed diagnosis of sinonasal lymphoma due to bilateral manifestation. *Eur Arch Otorhinolaryngol*, 2017; 274(2): 823–27
3. Deng D, Wang Y, Liu W, Qian Y: Oral and maxillofacial non-Hodgkin lymphomas: Case report with review of literature. *Medicine (Baltimore)*, 2017; 96(35): e7890
4. Vazquez A, Khan MN, Blake DM et al: Extranodal natural killer/T-cell lymphoma: A population-based comparison of sinonasal and extranasal disease. *Laryngoscope*, 2014; 124(4): 888–95
5. Reategui Schwarz E, Oikonomou KG, Reynolds M et al: Extranodal NK/T-cell lymphoma, nasal type, presenting as refractory *Pseudomonas aeruginosa* facial cellulitis. *J Investig Med High Impact Case Rep*, 2017; 5(3): 2324709617716471
6. Yamaguchi M, Miyazaki K: Current treatment approaches for NK/T-cell lymphoma. *J Clin Exp Hematop*, 2017; 57(3): 98–108
7. Mai HC, Chen DX, Lu D, Zhang YS: Extranodal natural killer/T-cell lymphoma presenting as cavernous sinus syndrome. *Mol Clin Oncol*, 2017; 6(4): 543–46
8. Termote K, Dierickx D, Verhoef G et al: Series of extranodal natural killer/T-cell lymphoma, nasal type, with periorbital involvement. *Orbit*, 2014; 33(4): 245–51
9. Harabuchi Y, Takahara M, Kishibe K et al: Extranodal natural killer/T-cell lymphoma, nasal type: Basic science and clinical progress. *Front Pediatr*, 2019; 7: 141
10. Tababi S, Kharrat S, Sellami M et al: Extranodal NK/T-cell lymphoma, nasal type: Report of 15 cases. *Eur Ann Otorhinolaryngol Head Neck Dis*, 2012; 129(3): 141–47

- Sanchez-Romero C, Paes de Almeida O, Henao JR, Carlos R: Extranodal NK/T-cell lymphoma, nasal type in Guatemala: An 86-case series emphasizing clinical presentation and microscopic characteristics. *Head Neck Pathol*, 2019; 13(4): 624–34
- Vásquez J, Serrano M, Lopez L et al: Predictors of survival of natural killer/T-cell lymphoma, nasal type, in a non-Asian population: A single cancer centre experience. *Eccancermedalscience*, 2016; 10: 688
- Hmidi M, Kettani M, Elboukhari A et al: Sinonasal NK/T-cell lymphoma. *Eur Ann Otorhinolaryngol Head Neck Dis*, 2013; 130(3): 145–47
- Tlholoe MM, Kotu M, Khammissa RAG et al: Extranodal natural killer/T-cell lymphoma, nasal type: 'Midline lethal granuloma.' A case report. *Head Face Med*, 2013; 9: 4
- Miyake MM, Oliveira MV, Miyake MM et al: Clinical and otorhinolaryngological aspects of extranodal NK/T-cell lymphoma, nasal type. *Braz J Otorhinolaryngol*, 2014; 80(4): 325–29
- Soon KH, Lim XR, Ng HL, Lim MY: Sinonasal natural killer/T-cell lymphoma presenting as pyrexia of unknown origin with nasal symptoms. *Singapore Med J*, 2014; 55(7): e109–11
- Yen TT, Wang RC, Jiang RS et al: The diagnosis of sinonasal lymphoma: A challenge for rhinologists. *Eur Arch Otorhinolaryngol*, 2012; 269(5): 1463–69
- Kim JW, An JH: Extranodal natural killer/T-cell lymphoma, nasal type, of the orbit mimicking recurrent orbital cellulitis. *J Craniofac Surg*, 2014; 25(2): 509–11
- Ying Z, Zhu J: Extranodal natural killer/T-cell lymphoma: We should and we can do more. *Chin Clin Oncol*, 2015; 4(1): 12
- Kalinka-Warzocho E, Warzocho K: Chłoniak nosowy T/NK-komórkowy – opis przypadku. *Hematologia*, 2010; 1(1): 87–92 [in Polish]
- Gill H, Liang RHS, Tse E: Extranodal natural-killer/T-cell lymphoma, nasal type. *Adv Hematol*, 2010; 2010: 627401
- Tse E, Kwong YL: How I treat NK/T-cell lymphomas. *Blood*, 2013; 121(25): 4997–5005
- Yamaguchi M, Miyazaki K: Current treatment approaches for NK/T-cell lymphoma. *J Clin Exp Hematop*, 2017; 57(3): 98–108
- Sokołowska-Wojdyto M, Florek A, Barańska-Rybak W et al: Natural killer/T-cell lymphoma, nasal type, masquerading as recalcitrant periodontitis in a patient with a diagnosis of Wegener's granulomatosis. *Am J Med Sci*, 2013; 345(2): 163–67
- Luemsamran P, Pornpanich K, Uiprasertkul M et al: NK/T-cell lymphoma of the nasal cavity causing contralateral dacryoadenitis. *Orbit*, 2013; 32(4): 250–52
- Sands NB, Tewfik MA, Hwang SY, Desrosiers M: Extranodal T-cell lymphoma of the sinonasal tract presenting as severe rhinitis: Case series. *J Otolaryngol Head Neck Surg*, 2008; 37(4): 528–33
- Charton J, Witherspoon SR, Itani K et al: Natural killer/T-cell lymphoma masquerading as orbital cellulitis. *Ophthalmic Plast Reconstr Surg*, 2008; 24(2): 143–45
- Lee J, Suh Ch, Park YH et al: Extranodal natural killer T-cell lymphoma, nasal-type: A prognostic model from a retrospective multicenter study. *J Clin Oncol*, 2006; 24(4): 612–18
- Suzuki R: NK/T-cell lymphoma: Updates in therapy. *Curr Hematol Malig Rep*, 2018; 13(1): 7–12