

Research Article

Bicuspid Aortic Valve: Role of Multiple Gene Variants in Influencing the Clinical Phenotype

Elena Sticchi,^{1,2,3} Rosina De Cario ,¹ Alberto Magi,¹ Sabrina Giglio ,^{4,5}
Aldesia Provenzano,⁴ Stefano Nistri,^{1,6} Guglielmina Pepe,^{1,2,3} and Betti Giusti ^{1,2,3}

¹Department of Experimental and Clinical Medicine, Section of Critical Medical Care and Medical Specialities, University of Florence, Italy

²Marfan Syndrome and Related Disorders Regional Referral Center, Careggi Hospital, Florence, Italy

³Excellence Centre for Research, Transfer and High Education for the Development of De Novo Therapies (DENOTHE), University of Florence, Florence, Italy

⁴Department of Biomedical Experimental and Clinical Sciences 'Mario Serio', University of Florence, Italy

⁵Medical Genetic Unit, Meyer Children's University Hospital, Florence, Italy

⁶Cardiology Service, CMSR Veneto Medica, Altavilla Vicentina, Italy

Correspondence should be addressed to Betti Giusti; betti.giusti@unifi.it

Received 25 January 2018; Revised 20 July 2018; Accepted 31 July 2018; Published 5 September 2018

Academic Editor: Graziano Pesole

Copyright © 2018 Elena Sticchi et al. This is an open access article distributed under the Creative Commons Attribution License, which permits unrestricted use, distribution, and reproduction in any medium, provided the original work is properly cited.

Background. Bicuspid aortic valve (BAV) is a common congenital heart defect with increased prevalence of aortic dilatation and dissection. BAV has an autosomal dominant pattern of inheritance with reduced penetrance and variable expressivity. BAV has been described as an isolated trait or associated with other clinical manifestations in syndromic conditions. Identification of a syndromic condition in a BAV patient is clinically relevant in order to personalize indication to aortic surgery. We aimed to point out how genetic diagnosis by next-generation sequencing (NGS) can improve management of a patient with complex BAV clinical picture. **Methods and Results.** We describe a 45-year-old Caucasian male with BAV, thoracic aortic root and ascending aorta dilatation, and connective features evocative but inconclusive for clinical diagnosis of Marfan syndrome (MFS). Targeted (91 genes) NGS was used. Proband genetic variants were investigated in first-degree relatives. Proband carried 5 rare variants in 4 genes: *FBNI*(p.Asn542Ser and p.Lys2460Arg), *NOTCH1*(p.Val1739Met), *LTBPI*(p.Arg1330Gln), and *TGFBR3*(p.Arg423Trp). The two *FBNI* variants were inherited in cis by the mother, showing systemic features evocative of MFS, but with a milder phenotype than that observed in the proband. Careful clinical observation along with the presence of the *FBNI* variants allowed diagnosis of MFS in the proband and in his mother. *NOTCH1* variant was found in mother and brother, not exhibiting BAV, thus not definitely supporting/excluding association with BAV. Interestingly, the proband, his brother and father, all showing root dilatation, and his sister, with upper range aortic root dimension, were carriers of a *TGFBR3* variant. *LTBPI* might also modulate the vascular phenotype. **Conclusions.** Our results underline the usefulness of NGS together with family evaluation in diagnosis of patients with monogenic traits and overlapping clinical manifestations due to contribution of the same genes and/or presence of comorbidities determined by different genes.

1. Background

Bicuspid aortic valve (BAV) disease is the most common congenital heart defect, as it affects 1.3% of the adult general population [1]. Aortic dilatation is a common feature of BAV with a prevalence ranging from 20 to 84% [1], due to differences in assessment techniques, study population, aortic size

thresholds, and heterogeneous nature of the disease related to different genetic and nongenetic individual and population background. An increased risk of aortic dissection has been reported for BAV patients, thus raising concerns for the proper timing of aortic surgery in these patients [2–4].

Familial clustering has been reported, mostly with an autosomal pattern of inheritance with reduced penetrance

and variable expressivity [5]. Actually, the heritability of BAV has been estimated to be 89%, thus suggesting the presence of a relevant genetic contribution [6].

Furthermore, BAV has been described as an isolated trait or associated with other clinical manifestations in syndromic conditions [familial thoracic aortic aneurysm and dissection, Marfan syndrome (MFS), Loeys-Dietz syndrome, Andersen syndrome, Turner syndrome, William Beuren syndrome, Bosley-Salih-Alorainy syndrome, and Athabaskan Brainstem Dysgenesis syndrome] [5, 7, 8]. Identification of a syndromic condition in a BAV patient is clinically relevant in order to personalize indication to aortic surgery [9, 10].

Different genes with divergent inheritance pattern have been described to be associated with BAV [6]. *NOTCH1* (9q34.3, OMIM 190198), a transmembrane receptor involved in signaling pathways regulating cell fate and cardiovascular development processes, represents the main gene demonstrated to be associated with BAV in both familial and sporadic forms [7, 11, 12]. Mutations in *NOTCH1* signaling genes have been associated with a wide spectrum of congenital heart defects [13].

Shortly thereafter, *GATA5* (20q13.33, OMIM 611496) has been also demonstrated to be involved in cardiac morphogenesis and aortic valve development [14] implicated in BAV pathogenesis [7, 15, 16]. The contribution of additional genes, such as *AXINI*, *EGFR*, *ENG*, *NKX2-5*, *NOS3*, *PDIA2*, *TGFBRI*, and *TGFBR2*, has been also suggested in BAV disease [5, 7, 13, 17].

Previous data from our group evidenced the presence of genetic variants in *FBNI* gene, encoding for fibrillin1, a component of connective tissue, in 2 isolated BAV patients with aortic root dilatation and in 2 MFS patients with BAV [18, 19]. Actually, a higher prevalence of BAV among MFS patients with respect to the general population was demonstrated, thus possibly suggesting common underlying mechanisms responsible for the phenotypic expression of these clinical disorders. Fibrillin-1 deficiency could be responsible for matrix alterations, which contribute to aortopathy associated with BAV and MFS [20]. Similar connective tissue histopathological features in BAV and MFS have been reported by some authors; moreover, the aortic wall in both MFS and BAV patients is characterized by an increased metalloproteinase (MMP) activity and a decreased fibrillin-1 expression [20, 21].

Nevertheless, differences in the anatomic site of aortic wall vulnerability in both conditions, MFS and BAV, were evidenced: the maximal aortic dilatation is observed at the level of the proximal thoracic ascending aorta in BAV patients, while it is mainly referred to the aortic root in MFS patients [22]. Therefore, due to differences and similarities between BAV and MFS aortic wall pathology, the pathogenetic mechanisms underlying these conditions are still matter of debate.

We describe here a comprehensive target gene capture/NGS approach, analyzing 91 genes associated with BAV, syndromic and nonsyndromic aortopathy, vessels or valves growth, and remodeling processes, on a patient affected by normally functioning BAV, aortic root, and thoracic ascending aorta dilatation, with connective features evocative

but inconclusive for a connective tissue disorder like MFS. We found rare nonsynonymous exonic variants, in large part predicted to be damaging by in silico analysis, that segregated with his “complex phenotype”, characterized by several clinical manifestations, ranging from vascular alterations (BAV and aortic root/ascending aorta dilatation) to systemic features suggestive of overlapping syndromic traits.

2. Methods

We describe a subject referred to the Center for Marfan Syndrome and Related Disorders (Careggi Hospital, Florence, Italy), affected by BAV, aortic root, and thoracic ascending aorta dilatation with a strong familiarity for thoracic aorta dilatation. His pedigree is reported in Figure 1. Our proband (II-1) was investigated by targeted NGS approach, and findings were validated through traditional Sanger sequencing. Thereafter, rare genetic variants identified in the proband have been investigated in first-degree family members [I-1 (mother), I-2 (father), II-2 (brother), and II-3 (sister)]. The experimental protocol was approved by the local ethical committee. All patients underwent genetic counseling and signed a written informed consent.

2.1. Echocardiographic Evaluation. All echocardiographic measurements had been made by a senior cardiologist (S.N.). BAV was diagnosed when only two cups were unequivocally identified in systole and diastole in the short axis view with a clear “fishmouth” appearance during systole as previously described [23, 24]. Aortic dimensions were assessed at end-diastole in the parasternal long-axis view at four levels by the leading edge method [23–25] and Z-scores were calculated according to age-adjusted nomograms for the aortic root [26]. Aortic or mitral regurgitation was evaluated and graded by multiple criteria combining color Doppler and continuous wave Doppler signals, and aortic valve stenosis was evaluated and graded by peak aortic valve velocity [23].

2.2. Genetic Analysis. Peripheral venous blood was collected in EDTA-coated vacutainer tubes and was stored at -20°C. Genomic DNA was extracted from blood samples using Tecan® Freedom EVO® liquid handling platform (Tecan Group Ltd, Switzerland) and GeneCatcher™ gDNA 0.3–1 mL Blood Kit (Thermo Fisher Scientific, USA). All procedures were performed following manufacturer protocols.

NGS was performed by 454 GS FLX Titanium technology (Roche, Basel, Switzerland). Using a targeted capture approach, we designed a panel of 91 genes regarded as relevant in BAV and syndromic and nonsyndromic aortopathy or involved in vessels or valves growth and remodeling processes by reviewing literature (*COL1A1*, *MTHFR*, *PLOD1*, *ADAMTSL4*, *MFAP2*, *PTGS2*, *SKI*, *TGFB2*, *CAPN2*, *AGT*, *MTR*, *TGFBR3*, *FGF8*, *RET*, *ACTA2*, *B3GAT3*, *LTBP3*, *EFEMP2/fbln4*, *LRP5*, *CCND1*, *LRP6*, *COL2A1*, *LRP1*, *DCN*, *LTBP2*, *TGFB3*, *FBLN5*, *ADAMTSL17*, *CHST14*, *FBNI*, *SMAD3*, *MYH11*, *ABCC6*, *MAPK3*, *PDIA2*, *AXINI*, *MMP2*, *CRYBA1*, *COL1A1*, *ACE*, *KCNJ2*, *EMILIN2*, *SMAD2*, *SMAD4*, *LTBP4*, *TGFB1*, *ADAMTSL10*, *MMADHC*, *ACVRI*, *COL3A1*,

COL5A2, FNI, COL6A3, EMILINI, LTBPI, JAG1, EMILIN3, MMP9, SLC2A10, GATA5, CBS, COL6A1, COL6A2, UFDIL, MAPK1, VHL, ZPLDI, MYLK, AGTRI, PDCD10, TGFB2, FBN2, NKX2-5, B4GALT7, ADAMTS2, AGGF1, MTRR, NOS3, HOXA1, CCM2, KRIT1, COLIA2, TGFB1, PTGSI, ENG, COL5A1, NOTCH1, GNAQ, AGTR2, FLNA, ELN: 870,000 bp). Genomic DNA libraries were prepared according to Roche sample preparation protocol (Rapid Library Preparation Method Manual, Roche Nimblegen Inc., Madison, WI). The customized capture array was designed to capture all coding exons, and flanking intron sequences of the 91 genes, according to the manufacturer's protocol (NimbleGen Arrays User's Guide: 454 Optimized Sequence Capture). Hybridization and washing procedures were performed according to Roche standard protocol. Sequencing run was then performed with the 454 Roche instrument. Sequencing runs have a mean coverage depth 45x. The standard flow files were analyzed with the GS Mapper software, version 2.6 (Roche Diagnostic, Basel, Switzerland). The gene variants calls were also evaluated by using an in-house pipeline developed by our bioinformaticians. Raw reads data were aligned to the human reference genome (hg19) with BWA version 0.7.12 [27]. Alignment and coverage statistics were generated with GATK version 3.3 [28], SAMTOOLS version 1.2 [29], and custom R scripts. Detection of single nucleotide variants and insertions/deletions was performed with the GATK Unified Genotyper by interrogating exons and intronic flanking regions (100bp) and taking into account strand-bias filtering and locus with more than 10X of sequencing coverage. Detected variants were annotated with Variant Effect Predictor version [30].

Sanger sequencing procedures were carried out in order to validate the identified genetic variants. The specific primer sets were designed using the Primer3 algorithm (<http://frodo.wi.mit.edu/primer3>). A bidirectional direct sequencing of PCR products was performed through ABI 3500Dx Sequencer (Applied Biosystems Foster City, CA, USA). Prediction of the effect of mutations was performed by Polyphen-2 (<http://genetics.bwh.harvard.edu/pph2/>), Sorting Tolerant from Intolerant (SIFT, <http://sift.jcvi.org>), FATHMM (<http://fathmm.biocompute.org.uk/>), and MutationTaster (<http://www.mutationtaster.org/>) *in silico* tools.

3. Results

The proband (II-1) is a 45-year-old Caucasian normotensive male (height 181 cm, weight 70 Kg). He presented with mild pectus excavatum and chest asymmetry, retrognathia, dolichocephaly, inguinal hernia, skin striae not associated with marked weight changes, and Beighton score 4/9. Echocardiography of the aorta documented the presence of a BAV with fusion of the right and left coronary cusps and a raphe and no calcification, dilatation of the aortic root (41mm; Z-score 2.56), and of ascending aorta (47 mm), and nonclassic mild mitral valve prolapse (i.e., without significant thickness of the valve leaflets) [31]. Magnetic resonance imaging (MRI) of the lumbosacral region did not show the presence of dural ectasia. No ocular clinical manifestations

were observed in II-1. No family history of MFS or other connective tissue disorders and of aortic dissection or aortic/mitral valve replacement or aortic aneurysm was reported by the proband.

The clinical evaluation of the first-degree family members of II-1 was performed.

The mother (I-1) is a 75-year-old Caucasian normotensive female (height 164 cm, weight 54 Kg). She presents a positive (≥ 7) systemic feature score including myopia >3 DO, mild pectus asymmetry and pectus carinatum deformity, mild thoracolumbar kyphosis, reduced elbow extension, and hindfoot deformity. Echocardiography of the aorta documented normal size of the aortic root diameters at the sinuses of valsalva within normal range (31 mm; Z-score -0.74), ascending aorta dilatation (35 mm), and mild mitral and tricuspid valve prolapse.

The father (I-2) is a 76-year-old Caucasian hypertensive male (height 177 cm, weight 89 Kg). He displays a systemic features' score of 4 for the presence of pectus carinatum deformity, pectus excavatum, and thoracolumbar kyphosis [8]. Echocardiography of the I-2 aorta documented the presence of aortic root at the sinuses of valsalva dilatation (41 mm; Z-score 1.19) with a normal size of the ascending aorta (32 mm).

The brother (II-2) of the proband is a 49-year-old normotensive Caucasian male (height 183 cm, weight 105 Kg) with pectus excavatum, pes planus, and striae distensae. He presented dilated aortic root (42 mm; Z-score 2.13) and normal size of the ascending aorta (30 mm).

The sister (II-3) of the proband is a 43-year-old normotensive Caucasian female (height 170 cm, weight 57 Kg) with severe scoliosis and osteoporosis. She presented normal aortic root (31 mm; Z-score 0.23) and ascending aorta (25 mm).

BAV was present only in the proband out of the 5 family members evaluated. In history taking of each member of the family there was no evidence of either occurrence of BAV or aortic surgery or sudden death.

NGS targeted approach identified in the proband (II-1) 5 rare heterozygous variants [minor allele frequency (MAF) <0.01] (Table 1) in 4 different genes: *FBN1* (p.Asn542Ser and p.Lys2460Arg), *NOTCH1* (p.Val1739Met), *LTBPI* (p.Arg1330Gln), and *TGFB3* (p.Arg423Trp) (Figure 1). These variants were confirmed through Sanger technology (Figure 2).

Characteristics of identified variants and results from *in silico* prediction of the pathogenetic effect were reported in Table 1. Variants detected in the proband were also investigated in his first-degree relatives (Figure 1). *NOTCH1* and *LTBPI* mutations were present in proband's mother (I-1) and brother (II-2). Concerning *FBN1* gene, both p.Asn542Ser and p.Lys2460Arg variants were inherited *in cis* by the mother (I-1) and not found in any of other family members. Finally, the *TGFB3* variant was transmitted by the father to the offspring (Figure 1).

In the proband, we also identified 139 common genetic variants (39 nonsynonymous) in the coding regions (data available if required).

TABLE 1: Characteristics of rare variants identified in the proband case by NGS analysis.

Gene	RefSeq	Exon	Variant description	dbSNP code MAF	In silico analysis					MUTATION TASTER
					SIFT	POLYPHEN	FATHMM	POLYPHEN	FATHMM	
<i>NOTCH1</i>	NM_017617	28	c.[5215G>A]+[=] p.[Val1739Met]+[=]	rs377294245 MAF (ExAC) = 0.000009	Tolerated	Possibly Damaging	Damaging	Possibly Damaging	Damaging	Disease Causing
<i>FBNI</i>	NM_000138	13	c.[1625G>A]+[=] p.[Asn542Ser]+[=]		Tolerated	Benign	Damaging	Benign	Damaging	Disease Causing
<i>FBNI</i>	NM_000138	59	c.[7379A>G]+[=] p.[Lys2460Arg]+[=]	rs144189837 MAF (ExAC) = 0.00007	Tolerated	Probably Damaging	Damaging	Probably Damaging	Damaging	Disease Causing
<i>LTBPI</i>	NM_206963	26	c.[3989G>A]+[=] p.[Arg1330Gln]+[=]	rs141080282 MAF (EU)=0.005	Tolerated	Possibly Damaging	Tolerated	Possibly Damaging	Tolerated	Disease Causing
<i>TGFBR3</i>	NM_003243	8	c.[1267C>T]+[=] p.[Arg423Trp]+[=]	rs766001542 MAF (ExAC) = 0.000003	Tolerated	Benign	Tolerated	Benign	Tolerated	Polymorphism

MAF: minor allele frequency; EU: European population; ExAC: ExAC Consortium population.

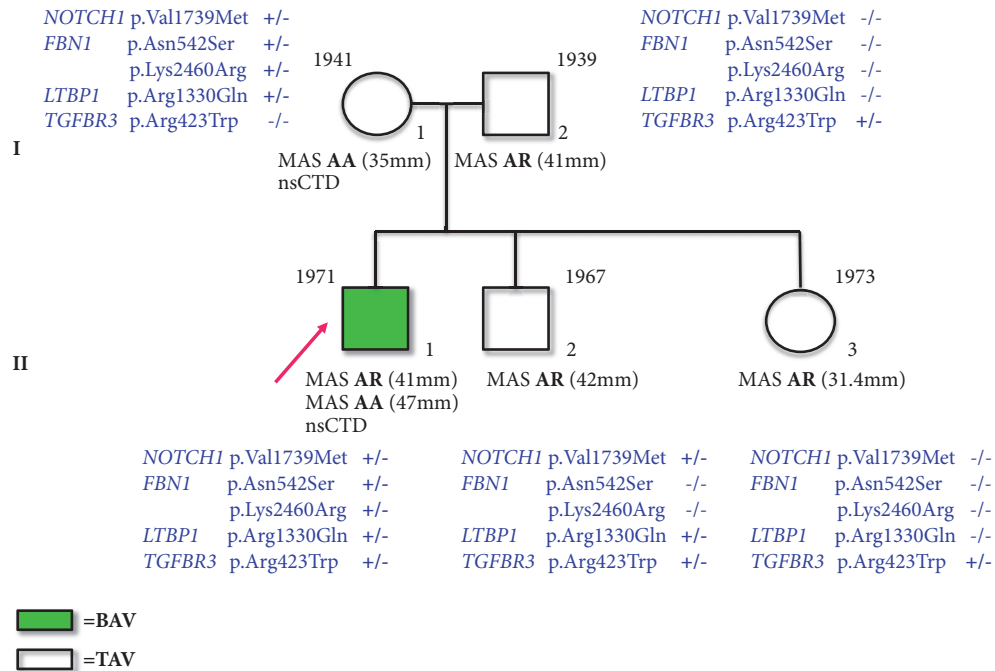


FIGURE 1: Pedigree of bicuspid aortic valve (BAV) family. BAV subjects are evidenced in green, whereas those showing tricuspid aortic valve (TAV) are not highlighted. An arrow indicates the proband case. Variants at *NOTCH1*, *FBNI*, *LTBP1*, and *TGFBR3* loci identified in BAV family members are shown. Birth years are reported at the upper left corner of symbols identifying subjects. MAS: maximal aortic size; AA: ascending aorta; AR: aortic root; nsCTD: nonspecific connective tissue disorders.

4. Conclusions

In the present study, the designed targeted NGS allowed us to identify 5 rare, nonsynonymous exonic variants in a patient affected by complex phenotype with BAV, aortic root and thoracic ascending aorta dilatation, and connective features evocative for MFS. Traditional Sanger sequencing confirmed that these variants in *NOTCH1*, *FBNI*, *LTBP1*, and *TGFBR3* genes were inherited, in various combinations, from the parents, one of which (mother) with a phenotype, upon closer observation, attributable to MFS. In fact, she presented the two different variants in *FBNI* gene and transmitted them *in cis* to the proband. According to the last revised Ghent criteria for MFS diagnosis, the identification of *FBNI* pathogenetic mutation in the proband, exhibiting aortic root dilatation (Z-score >2), allowed diagnosing MFS [8], and the identification of *FBNI* mutations in proband's mother also permitted diagnosing her as potential Marfan patient, even if with a less severe phenotype.

The two mutations in the *FBNI* are c.1625 A>G (p.Asn542Ser) in the exon 13 and c.7379A>G (p.Lys2460Arg) in the exon 59. Both variants determine amino acid changes in calcium-binding epidermal growth factor-like domains (cbEGF4 and cbEGF38, respectively), known to mediate fibrillin assembly into microfibrils and in turn the biomechanical properties of the microfibrillar network [32]. Actually, both nucleotide substitutions do not affect highly conserved amino acids of the cbEGFs; nevertheless, some of *in silico* pathogenicity prediction tools showed a deleterious effect. Although c.7379A>G variant has been hypothesized

to affect splicing process by generating a cryptic splice site, *in vitro* studies did not evidence its influence on mRNA processing [33]. This variant, reported in dbSNP database (rs144189837) with MAF≤0.0002 in Europeans, has been previously identified in patients with features of MFS [33, 34] and in thoracic aortic aneurysm (TAA) with a Marfan-like phenotype [35]. No information was available in literature or mutation databases for the c.1625 A>G variant. These two mutations were already identified together (not specified whether *in trans* or *in cis* due to lack of parents analysis) in our lab in further two patients: the first showing thoracic aortic dissection (TAD) type A and aortic valve substitution, mild myopia, striae distensae, altered lower/upper body segment ratio, and radicular cysts; the other, displaying a further *FBNI* mutation (c.6850C>A; exon 55), affected by severe classic MFS diagnosed on the presence of ectopia lentis, TAA and systemic features with score 10 including myopia, >3DO, pectus carinatum, scoliosis, wrist, and thumb signs, pes planus/hindfoot deformity.

According to international guidelines [10], the definition of MFS diagnosis in the proband determines the indication for an earlier aortic surgery. Moreover, in this patient, due to the presence of aortic root and ascending aorta dilatation, and genetic variants in *FBNI* and other potentially modifier genes, this issue seems of particular relevance. In fact, in this patient, further potentially pathogenetic variants for aortopathy were identified.

NOTCH1 mutation is a nucleotide substitution from guanine to adenine at position 5215 in the coding gene sequence (c.5215G>A, exon 28), responsible for valine to methionine

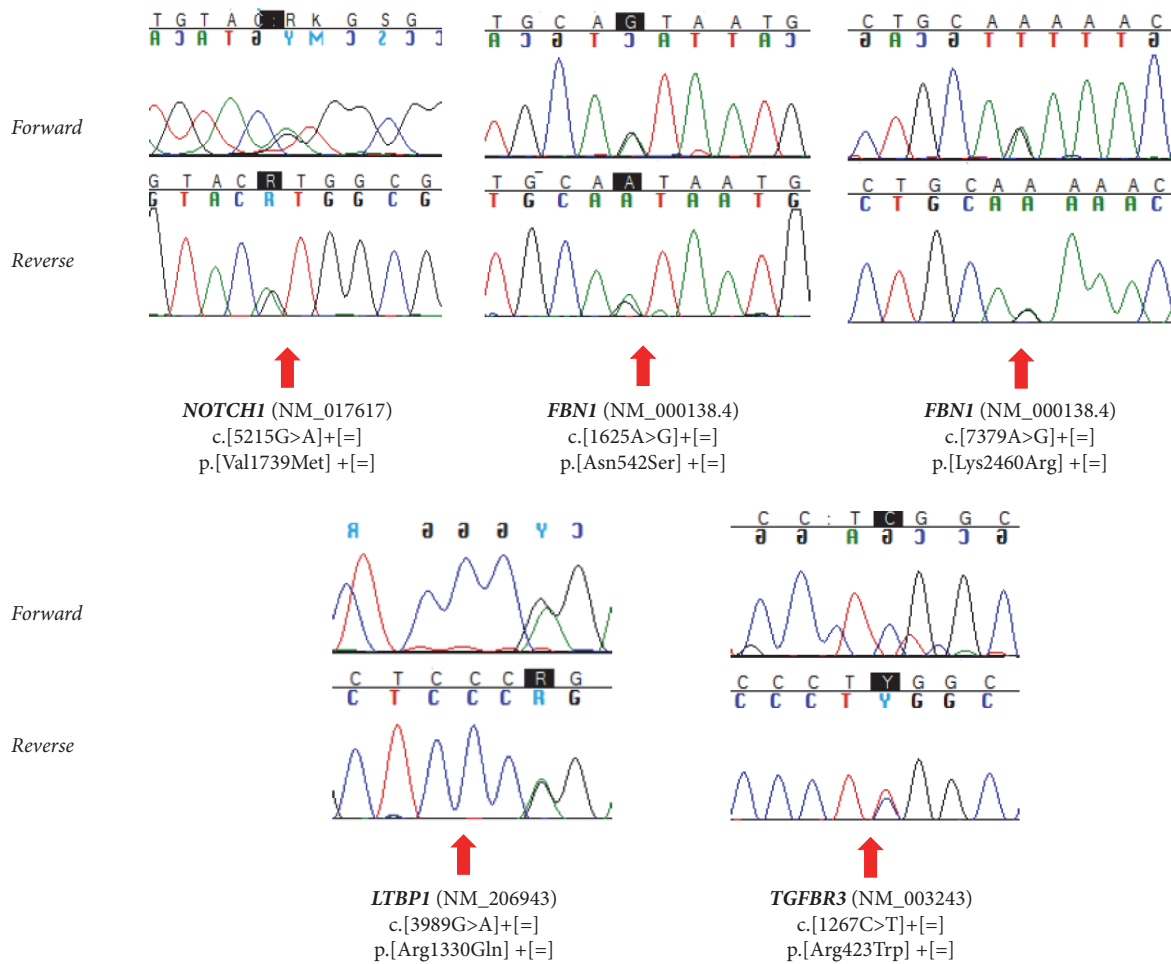


FIGURE 2: Electropherograms showing *NOTCH1*, *FBNI*, *LTBPI*, and *TGFBR3* gene mutations.

amino acid substitution at codon 1739 (p.Val1739Met), in the transmembrane domain of the encoded protein [11]. As cleavage of the intracellular domain, acting as a transcription factor able to modulate target genes expression [36], occurs at the transmembrane domain [37], it could be conceivable that modifications of this domain may result in an altered signal transduction. This variant, classified as damaging by most of *in silico* prediction tools (Table 1), has been described in dbSNP database (rs377294245), with a MAF of 0.00009 and has not been previously described in literature in BAV patients. Nonetheless, other *NOTCH1* mutations have been associated with BAV manifestations (<http://www.hgmd.cf.ac.uk/ac/all.php>). We have therefore identified this variant in proband's mother and brother, who, however, do not exhibit BAV. Nevertheless, due to the incomplete penetrance of BAV trait, the role of *NOTCH1* as BAV causative gene cannot be longer excluded.

The c.3989G>A variant at *LTBPI* gene, also identified in the mother and in the brother, is predicted to be deleterious by Polyphen and Mutation Taster algorithm, and it might contribute to further modulate the phenotypic expression of the disease. *LTBPI*, a member of the *LTBPs* family, is known to have dual function: as structural component

of the extracellular matrix and as modulator of TGF-beta availability essential for tissue formation and homeostasis [38, 39].

A mutation in the exon 8 of *TGFBR3* gene, encoding for the TGF-beta type III receptor often occurring as a coreceptor with other TGF-beta receptor superfamily members [40], was also found (c.1267C>T), with lying in the extracellular region of the protein and that cause amino acid substitution from arginine to tryptophan at codon 423 (p.Arg423Trp). Previous data from literature indicated the contribution of *TGFBR1* and *TGFBR2* genes in thoracic aortic aneurysms and dissections [41, 42]. Only one study showed a *TGFBR2* mutation in a patient with BAV and TAA [43]. No mutations in *TGFBR1* and *TGFBR2* were identified in 11 unrelated Italian patients with familial BAV [13], as well as in previous further two studies on BAV patients [44, 45]. Interestingly, both father and brother, exhibiting aortic root dilatation, and sister of proband, in whom upper range of normal aortic root dimensions were observed, showed *TGFBR3* mutation, thus suggesting a cosegregation of *TGFBR3* variant with the presence of aortic root dilatation.

Beyond these rare genetic variants, other polymorphisms identified in the proband such as *MTHFR* p.Ala222Val

(heterozygous) associated with severe cardiovascular manifestations in MFS patients or abdominal aortic aneurysm [46–48] or *NOS3* p.Glu298Asp (heterozygous) associated with hypertension [49] and abdominal aortic aneurysm [50] could interact to modulate the clinical phenotype. Furthermore, a missense polymorphic variant (p.Ala84Thr), with a global MAF of 0.0274 (MAF 0.0109 in the European population), has been identified in *PLOD1* gene, whose expression/activity alterations have been suggested to be involved in impaired collagen cross-linking in BAV patients [51], so possibly contributing to modulating the clinical phenotype in addition to the *NOTCH1* mutation.

The presence of BAV in only one member of the family did not allow the definition of the contribution of rare or common genetic variants on aortic valve defect. In order to achieve a definite comprehension of larger BAV genetic bases, more informative families with several affected subjects are needed.

After a posttest genetic counseling, a clinical and echocardiographic follow-up to all the family members was recommended on a yearly basis for the proband, mother, father, and brother, biennial for the sister. Moreover, in absence of clinical news, an evaluation in the Marfan Center in Florence was also scheduled at every two years for all the family members. In particular, it was elucidated to the proband that, due to the MFS diagnosis, the threshold for aortic surgery was anticipated from that recommended for uncomplicated BAV (i.e., 55 mm) to the cut-off value recommended for MFS, i.e., 50 mm [9, 10].

On the bases of the current knowledge [9, 10, 52, 53], a similar genetic approach should be taken into consideration, in BAV patients with thoracic aortic dilatation and further clinical manifestations suggestive of syndromic traits, and should be considered with more caution in other forms of BAV-associated aortic dilation patients.

In conclusion, our results underlined the complexity of clinical and genetic diagnosis also in traits considered monogenic, but in which clinical manifestations can overlap due to both contribution of the same genes to different phenotypes as well as presence of comorbidities determined by different genes. Moreover, this paper highlighted the usefulness of high-throughput sequencing technologies to improve diagnosis in a scenario in which an increasing number of genetic traits need to be considered polygenic/multifactorial. Target gene capture/deep sequencing approach can greatly improve the genetic diagnosis/management of patients with BAV. This study once more demonstrated the power of NGS in confirming and expanding clinical phenotypes/genotypes of the extremely heterogeneous conditions, assisting in genetic counseling and in carrier detection as well as providing therapeutic options.

Abbreviations

BAV: Bicuspid aortic valve
 EGF: Epidermal growth factor
 EU: European population
 ExAC: ExAC Consortium population
 MAF: Minor allele frequency

MFS: Marfan syndrome
 MMP: Metalloproteinase
 MRI: Magnetic resonance imaging
 NGS: Next-generation sequencing
 nsCTD: Nonspecific connective tissue disorders
 OMIM: Online Mendelian inheritance in man
 TAA: Thoracic aortic aneurysm
 TAD: Thoracic aortic dissection
 TAV: Tricuspid aortic valve
 WES: Whole exome sequencing approach.

Data Availability

All data supporting our findings are included in the article.

Ethical Approval

Ethical approval was obtained from the institutional review board (Department of Experimental and Clinical Medicine, University of Florence).

Consent

After explanation of the possible consequences of this study, informed written consent from all individual participants included in the study to participate was obtained.

Conflicts of Interest

The authors declare that they have no conflicts of interest.

Authors' Contributions

Betti Giusti, Elena Sticchi, Stefano Nistri, and Guglielmina Pepe were responsible for conception or design of the work. Elena Sticchi, Rosina De Carlo, Alberto Magi, Sabrina Giglio, Aldesia Provenzano, Stefano Nistri, Guglielmina Pepe, and Betti Giusti contributed to data collection and data analysis and interpretation. Elena Sticchi, Betti Giusti, Stefano Nistri, and Guglielmina Pepe drafted the article. Elena Sticchi, Betti Giusti, Stefano Nistri, Guglielmina Pepe, and Sabrina Giglio critically revised the article. Elena Sticchi, Rosina De Carlo, Alberto Magi, Sabrina Giglio, Aldesia Provenzano, Stefano Nistri, Guglielmina Pepe, and Betti Giusti gave the final approval of the version to be published.

Acknowledgments

The authors are grateful to the patient and his family for their cooperation and their participation in the study.

References

- [1] S. Verma and S. C. Siu, "Aortic dilatation in patients with bicuspid aortic valve," *The New England Journal of Medicine*, vol. 370, no. 20, pp. 1920–1929, 2014.
- [2] H. I. Michelena, S. K. Prakash, A. D. Corte et al., "Bicuspid aortic valve identifying knowledge gaps and rising to the challenge

- from the international bicuspid aortic valve consortium (BAV-CON)," *Circulation*, vol. 129, no. 25, pp. 2691–2704, 2014.
- [3] I. Mordi and N. Tzemos, "Bicuspid Aortic Valve Disease: A Comprehensive Review," *Cardiology Research and Practice*, vol. 2012, Article ID 196037, 7 pages, 2012.
 - [4] R. A. Nishimura, C. M. Otto, and R. O. Bonow, "2014 AHA/ACC guideline for the management of patients with valvular heart disease: a report of the American College of Cardiology/American Heart Association Task Force on Practice Guidelines," *Circulation*, vol. 129, no. 23, pp. e521–e643, 2014.
 - [5] Brigitte Laforest and Mona Nemer, "Genetic Insights into Bicuspid Aortic Valve Formation," *Cardiology Research and Practice*, vol. 2012, Article ID 180297, 8 pages, 2012.
 - [6] L. Cripe, G. Andelfinger, L. J. Martin, K. Shooner, and D. W. Benson, "Bicuspid aortic valve is heritable," *Journal of the American College of Cardiology*, vol. 44, no. 1, pp. 138–143, 2004.
 - [7] G. Pepe, R. De Cario, E. Sticchi et al., "Bicuspid aortic valve syndrome and fibrillinopathies: potential impact on clinical approach," *International Cardiovascular Forum Journal*, vol. 1, no. 4, p. 167, 2015.
 - [8] B. L. Loeys, H. C. Dietz, A. C. Braverman et al., "The revised Ghent nosology for the Marfan syndrome," *Journal of Medical Genetics*, vol. 47, no. 7, pp. 476–485, 2010.
 - [9] 2010 ACCF/AHA/AATS/ACR/ASA/SCA/SCAI/SIR/STS/SVM GUIDELINES FOR THE DIAGNOSIS AND MANAGEMENT OF PATIENTS WITH THORACIC AORTIC DISEASE REPRESENTATIVE MEMBERS, L. F. Hiratzka, M. A. Creager et al. et al., "Surgery for aortic dilatation in patients with bicuspid aortic valves: a statement of clarification from the american college of cardiology/american heart association task force on clinical practice guidelines," *Circulation*, vol. 133, no. 14, pp. 1426–1428, 2016.
 - [10] R. Erbel, V. Aboyans, C. Boileau et al., "2014 ESC guidelines on the diagnosis and treatment of aortic diseases," *European Heart Journal*, vol. 35, no. 41, pp. 2873–2926, 2014.
 - [11] V. Garg, A. N. Muth, J. F. Ransom et al., "Mutations in NOTCH1 cause aortic valve disease," *Nature*, vol. 437, no. 7056, pp. 270–274, 2005.
 - [12] E. M. Bonachea, G. Zender, P. White et al., "Use of a targeted, combinatorial next-generation sequencing approach for the study of bicuspid aortic valve," *BMC Medical Genomics*, vol. 7, no. 1, 2014.
 - [13] I. Foffa, L. Ait Ali, P. Panesi et al., "Sequencing of NOTCH1, GATA5, TGFBR1 and TGFBR2 genes in familial cases of bicuspid aortic valve," *BMC Medical Genetics*, vol. 14, no. 1, 2013.
 - [14] B. Laforest and M. Nemer, "GATA5 interacts with GATA4 and GATA6 in outflow tract development," *Developmental Biology*, vol. 358, no. 2, pp. 368–378, 2011.
 - [15] S. LaHaye, J. Lincoln, and V. Garg, "Genetics of valvular heart disease," *Current Cardiology Reports*, vol. 16, no. 6, article no. 487, 2014.
 - [16] E. M. Bonachea, S.-W. Chang, G. Zender et al., "Rare GATA5 sequence variants identified in individuals with bicuspid aortic valve," *Pediatric Research*, vol. 76, no. 2, pp. 211–216, 2014.
 - [17] N. Dargis, M. Lamontagne, N. Gaudreault et al., "Identification of gender-specific genetic variants in patients with bicuspid aortic valve," *American Journal of Cardiology*, vol. 117, no. 3, pp. 420–426, 2016.
 - [18] G. Pepe, S. Nistri, B. Giusti et al., "Identification of fibrillin 1 gene mutations in patients with bicuspid aortic valve (BAV) without Marfan syndrome," *BMC Medical Genetics*, vol. 15, no. 1, 2014.
 - [19] S. Nistri, M. C. Porciani, M. Attanasio, R. Abbate, G. F. Gensini, and G. Pepe, "Association of Marfan syndrome and bicuspid aortic valve: Frequency and outcome," *International Journal of Cardiology*, vol. 155, no. 2, pp. 324–325, 2012.
 - [20] P. W. M. Fedak, M. P. L. de Sa, S. Verma et al., "Vascular matrix remodeling in patients with bicuspid aortic valve malformations: implications for aortic dilatation," *The Journal of Thoracic and Cardiovascular Surgery*, vol. 126, no. 3, pp. 797–806, 2003.
 - [21] M. Nataatmadja, M. West, J. West et al., "Abnormal extracellular matrix protein transport associated with increased apoptosis of vascular smooth muscle cells in Marfan syndrome and bicuspid aortic valve thoracic aortic aneurysm," *Circulation*, vol. 108, supplement 1, pp. II329–II334, 2003.
 - [22] D. Detaint, H. I. Michelena, V. T. Nkomo, A. Vahanian, G. Jondeau, and M. E. Sarano, "Aortic dilatation patterns and rates in adults with bicuspid aortic valves: A comparative study with Marfan syndrome and degenerative aortopathy," *Heart*, vol. 100, no. 2, pp. 126–134, 2014.
 - [23] S. Nistri, C. Basso, C. Marzari, P. Mormino, and G. Thiene, "Frequency of bicuspid aortic valve in young male conscripts by echocardiogram," *American Journal of Cardiology*, vol. 96, no. 5, pp. 718–721, 2005.
 - [24] S. Nistri, J. Grande-Allen, M. Noale et al., "Aortic elasticity and size in bicuspid aortic valve syndrome," *European Heart Journal*, vol. 29, no. 4, pp. 472–479, 2008.
 - [25] M. J. Roman, R. B. Devereux, R. Kramer-Fox, and J. O'Loughlin, "Two-dimensional echocardiographic aortic root dimensions in normal children and adults," *American Journal of Cardiology*, vol. 64, no. 8, pp. 507–512, 1989.
 - [26] R. B. Devereux, G. De Simone, D. K. Arnett et al., "Normal limits in relation to age, body size and gender of two-dimensional echocardiographic aortic root dimensions in persons >15 years of age," *American Journal of Cardiology*, vol. 110, no. 8, pp. 1189–1194, 2012.
 - [27] H. Li and R. Durbin, "Fast and accurate short read alignment with Burrows-Wheeler transform," *Bioinformatics*, vol. 25, no. 14, pp. 1754–1760, 2009.
 - [28] A. McKenna, M. Hanna, E. Banks et al., "The genome analysis toolkit: a MapReduce framework for analyzing next-generation DNA sequencing data," *Genome Research*, vol. 20, no. 9, pp. 1297–1303, 2010.
 - [29] H. Li, B. Handsaker, A. Wysoker et al., "The sequence alignment/map format and SAMtools," *Bioinformatics*, vol. 25, no. 16, pp. 2078–2079, 2009.
 - [30] W. McLaren, B. Pritchard, D. Rios, Y. Chen, P. Flicek, and F. Cunningham, "Deriving the consequences of genomic variants with the Ensembl API and SNP Effect Predictor," *Bioinformatics*, vol. 26, no. 16, Article ID btq330, pp. 2069–2070, 2010.
 - [31] L. A. Freed, D. Levy, R. A. Levine et al., "Prevalence and clinical outcome of mitral-valve prolapse," *The New England Journal of Medicine*, vol. 341, no. 1, pp. 1–7, 1999.
 - [32] P. Handford, "Fibrillin-1, a calcium binding protein of extracellular matrix," *Biochimica et Biophysica Acta (BBA) - Molecular Cell Research*, vol. 1498, no. 2-3, pp. 84–90, 2000.
 - [33] D. Robinson, F. Lin, M. Lyon et al., "Systematic screening of FBN1 gene unclassified missense variants for splice abnormalities," *Clinical Genetics*, vol. 82, no. 3, pp. 223–231, 2012.
 - [34] R. Howarth, C. Yearwood, and J. F. Harvey, "Application of dHPLC for mutation detection of the fibrillin-1 gene for the diagnosis of Marfan syndrome in a National Health Service Laboratory," *Genetic Testing*, vol. 11, no. 2, pp. 146–152, 2007.

- [35] L. Campens, B. Callewaert, L. M. Mosquera et al., "Gene panel sequencing in heritable thoracic aortic disorders and related entities - Results of comprehensive testing in a cohort of 264 patients," *Orphanet Journal of Rare Diseases*, vol. 10, no. 1, article no. 9, 2015.
- [36] R. Kopan and M. X. G. Iragan, "The canonical notch signaling pathway: unfolding the activation mechanism," *Cell*, vol. 137, no. 2, pp. 216–233, 2009.
- [37] C. L. Deatherage, Z. Lu, J.-H. Kim, and C. R. Sanders, "Notch transmembrane domain: secondary structure and topology," *Biochemistry*, vol. 54, no. 23, pp. 3565–3568, 2015.
- [38] V. Todorovic and D. B. Rifkin, "LTBPs, more than just an escort service," *Journal of Cellular Biochemistry*, vol. 113, no. 2, pp. 410–418, 2012.
- [39] T. Massam-Wu, M. Chiu, R. Choudhury et al., "Assembly of fibrillin microfibrils governs extracellular deposition of latent TGF β ," *Journal of Cell Science*, vol. 123, no. 17, pp. 3006–3018, 2010.
- [40] C. B. Brown, A. S. Boyer, R. B. Runyan, and J. V. Barnett, "Requirement of type III TGF- β receptor for endocardial cell transformation in the heart," *Science*, vol. 283, no. 5410, pp. 2080–2082, 1999.
- [41] V. Tran-Fadulu, H. Pannu, D. H. Kim et al., "Analysis of multigenerational families with thoracic aortic aneurysms and dissections due to TGFBR1 or TGFBR2 mutations," *Journal of Medical Genetics*, vol. 46, no. 9, pp. 607–613, 2009.
- [42] E. M. Isselbacher, C. L. L. Cardenas, and M. E. Lindsay, "Hereditary influence in thoracic aortic aneurysm and dissection," *Circulation*, vol. 133, no. 24, pp. 2516–2528, 2016.
- [43] E. Girdauskas, S. Schulz, M. A. Borger, M. Mierzwa, and T. Kuntze, "Transforming growth factor-beta receptor type II mutation in a patient with bicuspid aortic valve disease and intraoperative aortic Dissection," *The Annals of Thoracic Surgery*, vol. 91, no. 5, pp. e70–e71, 2011.
- [44] M. L. Loscalzo, D. L. M. Goh, B. Loeys, K. C. Kent, P. J. Spevak, and H. C. Dietz, "Familial thoracic aortic dilation and bicommissural aortic valve: a prospective analysis of natural history and inheritance," *American Journal of Medical Genetics Part A*, vol. 143, no. 17, pp. 1960–1967, 2007.
- [45] C. B. Arrington, C. T. Sower, N. Chuckwuk et al., "Absence of TGFBR1 and TGFBR2 mutations in patients with bicuspid aortic valve and aortic dilation," *American Journal of Cardiology*, vol. 102, no. 5, pp. 629–631, 2008.
- [46] B. Giustia, M. C. Porciana, T. Brunelli et al., "Phenotypic variability of cardiovascular manifestations in Marfan Syndrome. Possible role of hyperhomocysteinemia and C677T MTHFR gene polymorphism," *European Heart Journal*, vol. 24, no. 22, pp. 2038–2045, 2003.
- [47] T. Brunelli, D. Prisco, S. Fedi et al., "High prevalence of mild hyperhomocysteinemia in patients with abdominal aortic aneurysm," *Journal of Vascular Surgery*, vol. 32, no. 3, pp. 531–536, 2000.
- [48] P. McColgan, G. E. Peck, R. M. Greenhalgh, and P. Sharma, "The genetics of abdominal aortic aneurysms: A comprehensive meta-analysis involving eight candidate genes in over 16,700 patients," *International Surgery*, vol. 94, no. 4, pp. 350–358, 2009.
- [49] M. Jáchymová, K. Horký, J. Bultas et al., "Association of the Glu298Asp polymorphism in the endothelial nitric oxide synthase gene with essential hypertension resistant to conventional therapy," *Biochemical and Biophysical Research Communications*, vol. 284, no. 2, pp. 426–430, 2001.
- [50] C. Fatini, F. Sofi, E. Sticchi et al., "eNOS G894T polymorphism as a mild predisposing factor for abdominal aortic aneurysm," *Journal of Vascular Surgery*, vol. 42, no. 3, pp. 415–419, 2005.
- [51] D. Wågsäter, V. Paloschi, R. Hanemaaijer et al., "Impaired collagen biosynthesis and cross-linking in aorta of patients with bicuspid aortic valve," *Journal of the American Heart Association*, vol. 2, no. 1, p. e000034, 2013.
- [52] S. L. Freeze, B. J. Landis, S. M. Ware, and B. M. Helm, "Bicuspid aortic valve: a review with recommendations for genetic counseling," *Journal of Genetic Counseling*, vol. 25, no. 6, pp. 1171–1178, 2016.
- [53] B. Giusti, E. Sticchi, R. De Cario, A. Magi, S. Nistri, and G. Pepe, "Genetic bases of bicuspid aortic valve: the contribution of traditional and high-throughput sequencing approaches on research and diagnosis," *Frontiers in Physiology*, vol. 8, 2017.