

Central Diabetes Insipidus after Staged Spinal Surgery

Benjamin P. Rosenbaum¹ Michael P. Steinmetz^{1,2}

¹Department of Neurosurgery, Center for Spine Health, Cleveland Clinic Foundation, Cleveland, Ohio

²Department of Neurological Surgery, Case Western Reserve University School of Medicine, MetroHealth Medical Center, Cleveland, Ohio

Address for correspondence Michael P. Steinmetz, MD, Department of Neurosciences, The MetroHealth System, 2500 MetroHealth Drive, Cleveland, OH 44109 (e-mail: msteinmetz@metrohealth.org).

Global Spine J 2013;3:257–260.

Abstract

Diabetes insipidus (DI) is described following penetrating spinal cord trauma but rarely following instrumented spinal fusion. More commonly, hyponatremia is seen following spine surgery, which may be iatrogenic, attributed to the syndrome of inappropriate antidiuretic hormone release. The authors present a case of a 57-year-old woman who underwent a planned two-stage operation for scoliotic deformity correction. On the third postoperative day, the patient developed hypernatremia (sodium levels of 157 mmol/L) and polyuria. In conjunction with endocrinology, the patient was diagnosed with central DI. The patient was treated with desmopressin acetate (DDAVP), which led to resolution of her symptoms. DDAVP was temporary and eventually weaned off. Central DI is a possible cause of hypernatremia following significant spine surgery. Correct diagnosis is paramount for rapid and appropriate treatment.

Keywords

- ▶ diabetes insipidus
- ▶ spinal surgery
- ▶ scoliosis
- ▶ hypernatremia

Diabetes insipidus (DI) is characterized by polydipsia, polyuria, and resultant hypernatremia. Hypernatremia may progress from thirst, confusion, and weakness to seizures or coma. The etiology of DI may be either neurogenic or nephrogenic. Neurogenic DI is caused by a deficiency in antidiuretic hormone (ADH) production, and nephrogenic DI is caused by an insensitivity of the kidneys to ADH. With either cause of DI, the body loses excessive free water and leads to hypernatremia and a hyperosmolar state, which may become symptomatic if left untreated. Hyponatremia following spinal surgery is uncommon and may be due to the syndrome of inappropriate ADH release (SIADH).^{1–7} DI is described following penetrating spinal cord trauma, but the authors are aware of no known reported cases of DI following spinal surgery.^{8–12} We present a case of DI following spinal surgery for scoliotic deformity correction.

Methods

History and Examination

A 57-year-old woman with a history of scoliotic deformity and hypothyroidism was referred to the outpatient clinic with

complaints of debilitating low back pain. She had no previous history of other endocrine, urologic, or menstrual disorders. Imaging demonstrated significant scoliosis from T11 to L5 at a 65-degree left-bending curve with coronal and sagittal imbalance (▶ **Fig. 1**). After evaluation and discussion, a two stage correction procedure was planned consisting of multiple anterior releases of the thoracic and lumbar spine followed by a posterior segmental fixation and deformity correction.

Operations

The patient underwent a planned two-stage operation. The first stage consisted of a retroperitoneal transdiaphragmatic approach, resection of the eleventh rib, and T11–T12, T12–L1, L1–L2, L2–L3, L3–L4, and L4–L5 discectomies. Interbody arthrodesis was performed utilizing rib autograph plus β -tricalcium phosphate. Three days later, the planned second stage was performed consisting of T3–S1 pedicle screw fixation, bilateral ilium fixation, deformity correction, and arthrodesis from T3 to the ilium. Smith-Peterson osteotomies were performed at L1–L2, L2–L3, and L3–L4 with right-sided L5–S1 transforaminal lumbar interbody fusion. Pedicle

received
December 23, 2012
accepted after revision
February 20, 2013
published online
May 9, 2013

© 2013 Georg Thieme Verlag KG
Stuttgart · New York

DOI <http://dx.doi.org/10.1055/s-0033-1345038>.
ISSN 2192-5682.

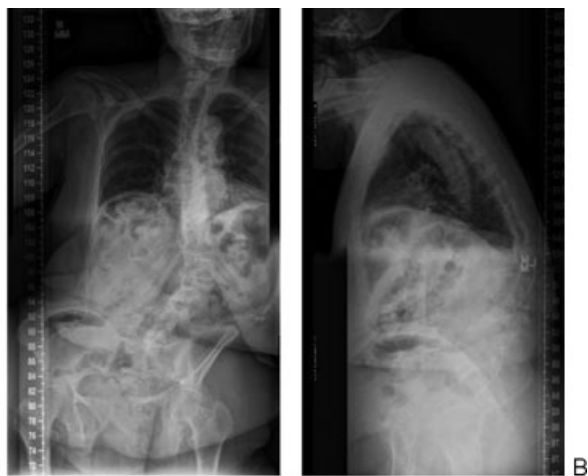

Fig. 1 Preoperative (A) anteroposterior and (B) lateral standing X-ray.

screws were augmented with polymethyl methacrylate bilaterally at T3 and T4. An internal direct-current bone stimulator and bone morphogenetic protein along with local bone autograft were utilized for the dorsal arthrodesis. There were no intraoperative complications, no vital sign swings (e.g., hypotension, hypoxia, bradycardia, or tachycardia), and no changes in somatosensory or motor evoked potentials. Mean arterial pressure remained above 70 mm Hg throughout both stages. In the first stage, surgery lasted 8 hours and included autologous blood transfusion, packed red blood cells, fresh frozen plasma, 6% hetastarch, lactated Ringer solution, and normal saline solution (totaling 4.6 L) with 1.7 L urine output and 1.2 L estimated blood loss. In the second stage, surgery lasted 12.75 hours and the same fluids were used (totaling 6.4 L) with 1.2 L urine output and 2.9 L estimated blood loss. The patient's postoperative radiographs revealed improved coronal and sagittal balance (**Fig. 2**).

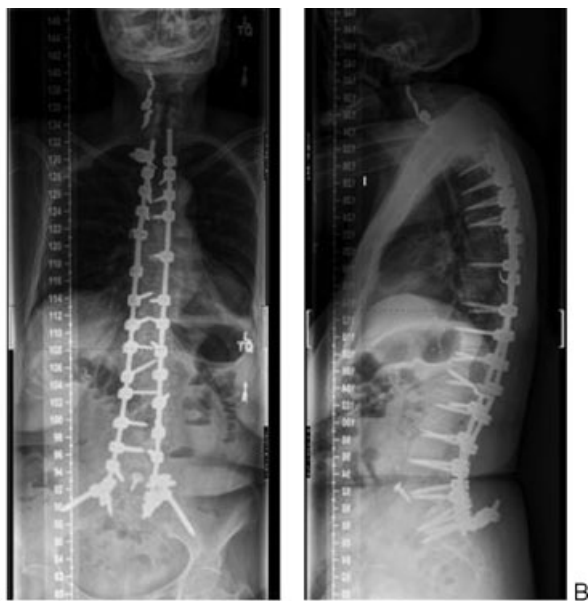

Fig. 2 Postoperative (A) anteroposterior and (B) lateral standing X-ray.

Results

The patient's preoperative sodium was 140 mmol/L. After the first-stage surgery, the patient had an unremarkable postoperative course with routine chest tube management on the regular nursing floor. On postoperative day (POD) 1, the patient's serum sodium was 146 mmol/L, at the upper limit of normal. Postoperatively (second stage), the serum sodium, osmolality, and urine osmolality were closely monitored as serum sodium and urine output trended upward. **Fig. 3** demonstrates the trend in serum sodium and serum osmolality. **Fig. 4** demonstrates the trend in urine osmolality and urine specific gravity. The patient had polyuria with 200 to 300 mL/h of urine output corresponding to the rise in serum sodium and serum osmolality (**Figs. 3 and 4**). She was initially managed with one-half normal saline to replace her urine milliliter for milliliter, then switched to D5W with frequent serum sodium and osmolality checks because her sodium continued to rise. With a continuing rise in serum sodium and polyuria, an endocrinology specialist was consulted. Initially the working diagnosis was dehydrational hypernatremia, but with persistent 200 to 300 mL/h urine output and persistent hypernatremia despite adequate free water resuscitation, desmopressin acetate (DDAVP) was implemented on POD 5. She was placed on 2 µg DDAVP twice daily thereafter and her serum sodium and osmolality corrected toward normal (**Fig. 3**), and a diagnosis of central DI was made given hypernatremia, consistent urine output greater than 250 mL/h, and elevated serum osmolality. DDAVP was eventually stopped in hospital on POD 20 and her serum sodium remained stable without change. Workup for hypothalamic-pituitary dysfunction included adrenocorticotropic hormone stimulation test (Cushing disease), free T4 (thyrotoxicosis), and prolactin levels (prolactinoma), which were all normal.

Notably on POD 7, 2 days after the diagnosis of DI, the patient became encephalopathic and noncontrast head computed tomography demonstrated a remote right thalamic infarct, with no prior comparison imaging. On POD 9, magnetic resonance imaging (MRI) demonstrated small bland acute infarcts in the right corona radiata and left lateral cerebellum (**Fig. 5**). There was no evidence of infarct to the hypothalamus or pituitary gland. On POD 12, magnetic resonance angiography demonstrated reduced filling of the right vertebral artery with probable pseudoaneurysm. The patient underwent a cerebral angiogram on POD 22, which confirmed a pseudoaneurysm of the right vertebral artery, prompting sacrifice of the right vertebral artery.

She was eventually discharged to a rehabilitation facility without DDAVP after a 24-day hospital stay. The patient's DI and encephalopathy had resolved at the time of discharge, and at 3-month follow-up, the patient was doing well with improvement in back pain and no recurrence of DI.

Discussion

SIADH and DI have been described in postsurgical and spinal cord injury population, respectively.¹⁻¹² The pathogenesis of

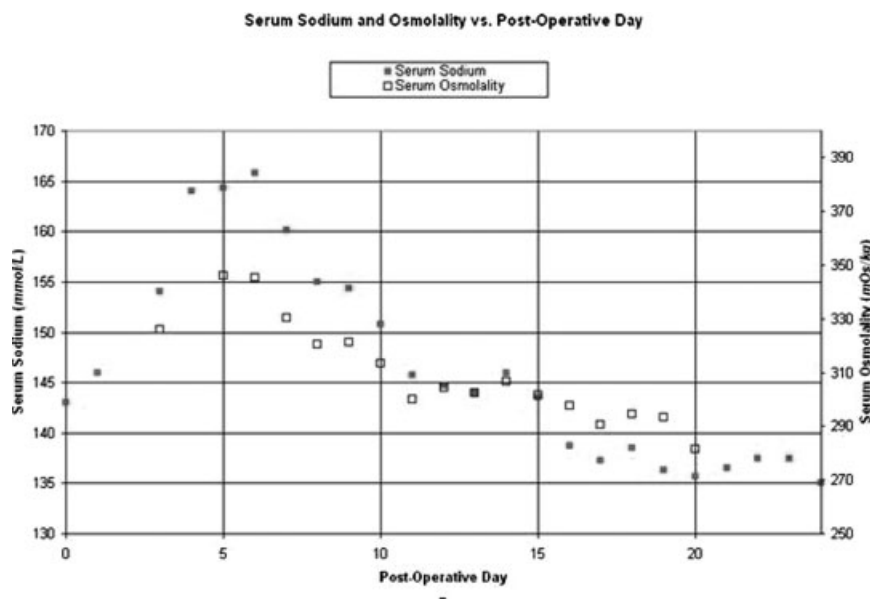


Fig. 3 Serum sodium and serum osmolality versus postoperative day.

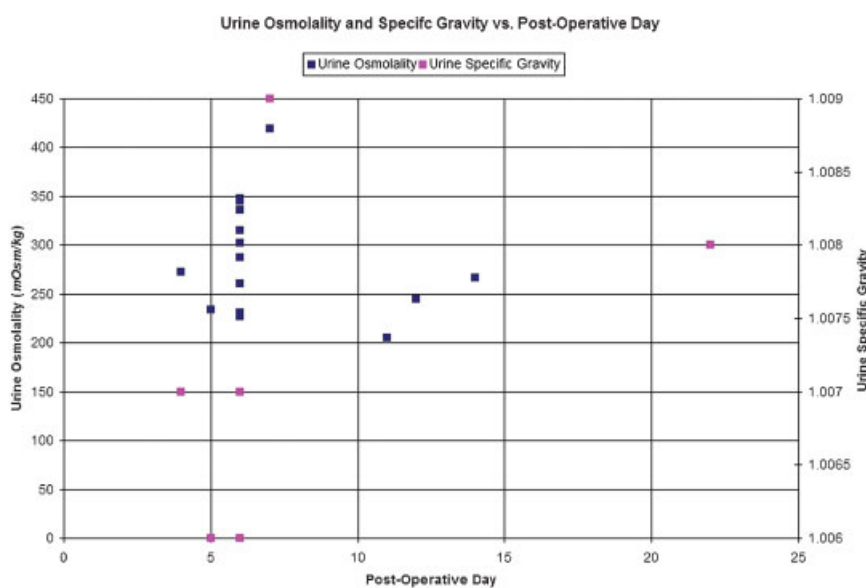


Fig. 4 Urine osmolality and urine specific gravity versus postoperative day.

DI remains uncertain but in spinal cord injury it has been hypothesized to be selective disruption of posterior pituitary circulation due to fat globules, thrombi, and hypovolemia resulting in hypoxia and tissue necrosis.¹² The same causes could be applied to large spinal operations where there is often significant blood loss and hypotension, which may result in hypoperfusion of the posterior pituitary, tissue necrosis, and resultant DI. This hypothesis may also explain the transient nature of the condition.

A prior study states that patients who undergo a revision operation have an approximately two to four times greater risk of being affected by SIADH secretion than those who have primary surgery.⁴ The greater risk of SIADH may also extend

to DI after multiple-stage spinal surgeries. The intracranial infarcts in this patient are confounding. Microemboli to the posterior pituitary may have resulted in DI, but MRI did not demonstrate an infarct in this region. The source of microemboli, if present, remains unclear. The authors do note the difficulty in imaging the pituitary gland and indeed an infarct may have occurred, although it is unlikely from the posterior circulation where a pseudoaneurysm was identified. Of note, it was not until POD 7 that the patient became symptomatic from intracranial infarcts. The patient could have had microemboli prior to that event. The delayed nature of the encephalopathy was either related to intracranial infarcts or sustained hypernatremia. Moreover, the cause of the

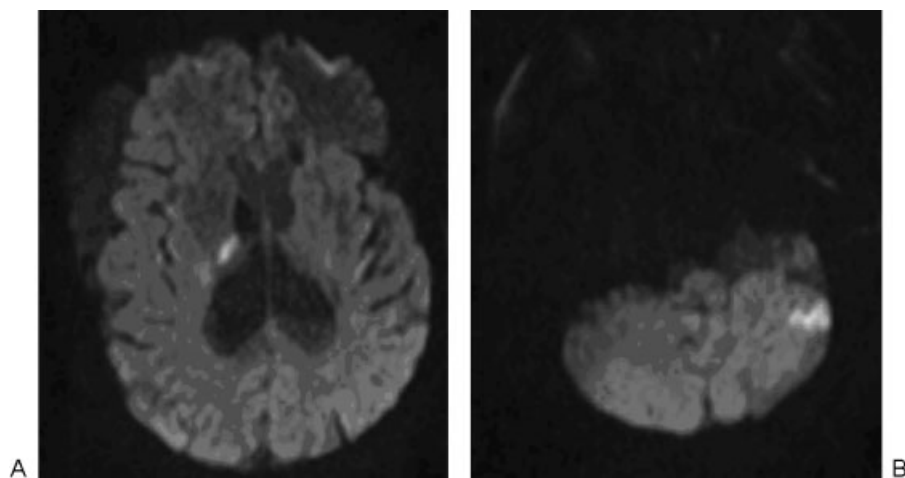


Fig. 5 Axial diffusion-weighted magnetic resonance imaging of the brain on postoperative day 9 demonstrating infarcts of (A) right corona radiata and (B) left lateral cerebellum.

vertebral pseudoaneurysm is also unclear. A unifying etiology for DI, infarcts, and a vertebral pseudoaneurysm is not readily apparent and unlikely given the time of presentation of each. The infarcts and vertebral pseudoaneurysm may be related and DI an additional problem.

The treatment of DI in this patient was not novel, but spinal surgeons should be aware of its possibility post-spinal surgery, particularly in large operations with significant blood loss, hypovolemia, and hypotension. This case illustrates the need to pay special attention to the postoperative fluid and sodium status of the patient having spinal surgery. DI is a condition that may occur. Prompt diagnosis and treatment are paramount.

Acknowledgments

The authors would like to thank Christine Moore, Cleveland Clinic Foundation, for assisting with formatting the figures.

Disclosures

Benjamin P. Rosenbaum, None
Michael P. Steinmetz, Consultant: Biomet Spine

References

- 1 Brazel PW, McPhee IB. Inappropriate secretion of antidiuretic hormone in postoperative scoliosis patients: the role of fluid management. *Spine* 1996;21:724-727
- 2 Bell GR, Gurd AR, Orłowski JP, Andrish JT. The syndrome of inappropriate antidiuretic-hormone secretion following spinal fusion. *J Bone Joint Surg Am* 1986;68:720-724
- 3 Amini A, Schmidt MH. Syndrome of inappropriate secretion of antidiuretic hormone and hyponatremia after spinal surgery. *Neurosurg Focus* 2004;16:E10
- 4 Callewart CC, Minchew JT, Kanim LE, et al. Hyponatremia and syndrome of inappropriate antidiuretic hormone secretion in adult spinal surgery. *Spine* 1994;19:1674-1679
- 5 Elster AD. Hyponatremia after spinal fusion caused by inappropriate secretion of antidiuretic hormone (SIADH). *Clin Orthop Relat Res* 1985;136-141
- 6 Cowley DM, Pabari M, Sinton TJ, Johnson S, Carroll G, Ryan WE. Pathogenesis of postoperative hyponatremia following correction of scoliosis in children. *Aust N Z J Surg* 1988;58:485-489
- 7 Lieh-Lai MW, Stanitski DF, Sarnaik AP, et al. Syndrome of inappropriate antidiuretic hormone secretion in children following spinal fusion. *Crit Care Med* 1999;27:622-627
- 8 Farrell CA, Staas WE Jr. Diabetes insipidus in a quadriplegic patient. *Arch Phys Med Rehabil* 1986;67:132-134
- 9 Iob I, Salar G, Mattisi G, Ori C, Rampazzo A. Diencephalic syndrome following cervical spinal cord trauma. *Acta Neurochir (Wien)* 1989;97:123-127
- 10 Kuzeyli K, Cakir E, Baykal S, Karaarslan G. Diabetes insipidus secondary to penetrating spinal cord trauma: case report and literature review. *Spine* 2001;26:E510-E511
- 11 Closson BL, Beck LA, Swift MA. Diabetes insipidus and spinal cord injury: a challenging combination. *Rehabil Nurs* 1993;18:368-374
- 12 Machiedo G, Bolanowski PJ, Bauer J, Neville WE. Diabetes insipidus secondary to penetrating thoracic trauma. *Ann Surg* 1975;181:31-34