

Lower Extremity Nerve Transfers in Acute Flaccid Myelitis Patients: A Case Series

Amy M. Moore, MD, FACS*
 Carrie Roth Bettlach, RN, MSN,
 FNP-C†
 Thomas T. Tung, MD†
 Julie M. West, MS, PA-C*
 Stephanie A. Russo, MD, PhD†

Background: Acute flaccid myelitis (AFM) is characterized by flaccid paralysis following prodromal symptoms. Complete recovery is rare, and patients typically have residual extremity weakness. This study aimed to describe the technique and outcomes of lower extremity nerve transfers for children with AFM.

Methods: A retrospective review of eight children who developed AFM in 2016 and had lower extremity nerve transfers was performed. Principles of nerve transfer were applied to develop novel nerve transfer procedures to restore function for this patient population. Pre- and postoperative muscle strength grades were reviewed, and qualitative improvements in function were recorded.

Results: A variety of nerve transfers were utilized in eight patients with average time to surgery from AFM diagnosis of 15.7 months. Restoration of gluteal, femoral, hamstring, and gastrocnemius function was attempted. Variable MRC grade improvement was achieved (range MRC grade 0–4). All patients reported subjective improvements in function. Four of five patients with follow-up who underwent nerve transfers for restoration of gluteal function transitioned from wheelchair use to walking with assistive devices as their primary modes of ambulation. No donor site complications occurred.

Conclusions: The unique needs of this patient population and variable patterns of residual weakness require meticulous assessment and development of individualized surgical plans. With appropriate goals and expectations in mind, functional improvement may be achieved, including return to ambulation. (*Plast Reconstr Surg Glob Open* 2021;9:e3699; doi: [10.1097/GOX.0000000000003699](https://doi.org/10.1097/GOX.0000000000003699); Published online 20 July 2021.)

INTRODUCTION

Acute flaccid myelitis (AFM) is a rare, polio-like disease characterized by acute onset of flaccid paralysis.^{1–4} AFM has a predilection for young persons,⁴ with a median age of 4 years.² Neurologic symptoms typically follow a 5- to 8-day prodromal phase of fever, respiratory symptoms, and/or gastrointestinal symptoms.^{2–9} Flaccid paralysis is often asymmetric and may involve any number of limbs,

cranial nerves, and cervical, paraspinal, abdominal, and respiratory musculature.^{4,6}

The Centers for Disease Control and Prevention first recognized AFM as a disease process in the United States in 2014. To date, 645 confirmed cases have occurred with a biennial pattern of peak and nonpeak years.^{1,10} The underlying etiology and pathophysiology are not well understood, but AFM has been associated with enterovirus infections, specifically D68 and A71.^{2,4,6,11–13} The anterior horn cells of the spinal cord are characteristically involved; however, direct muscle insult has also been postulated.^{8,11}

Unfortunately, there is no preventative vaccine or cure for AFM. Initial management approaches for AFM have not been standardized, but are focused on supportive care.^{4,6,14,15} The natural history of the disease and patterns of recovery are still to be determined; however, residual flaccid paralysis of the limbs reminiscent of poliomyelitis has been found. Similar to poliomyelitis, proximal muscle group paralysis with preservation of distal function is characteristic in children with AFM.

*From the *Department of Plastic and Reconstructive Surgery, The Ohio State University Wexner Medical Center, Columbus, Ohio; and †Division of Plastic and Reconstructive Surgery, Washington University School of Medicine, St Louis, Mo.*

Received for publication April 29, 2021; accepted May 17, 2021.

Presented at the Proceedings of the American Society for Peripheral Nerve Annual Meeting, January 2020, Fort Lauderdale, Fla., and at the Proceedings of the American Society for Peripheral Nerve, Koloa, Hawaii.

Copyright © 2021 The Authors. Published by Wolters Kluwer Health, Inc. on behalf of The American Society of Plastic Surgeons. This is an open-access article distributed under the terms of the [Creative Commons Attribution-Non Commercial-No Derivatives License 4.0 \(CCBY-NC-ND\)](https://creativecommons.org/licenses/by-nc-nd/4.0/), where it is permissible to download and share the work provided it is properly cited. The work cannot be changed in any way or used commercially without permission from the journal.

DOI: [10.1097/GOX.0000000000003699](https://doi.org/10.1097/GOX.0000000000003699)

Disclosure: *The authors have no financial interest to declare in relation to the content of this article. No funding was received for this study.*

Related Digital Media are available in the full-text version of the article on www.PRSGlobalOpen.com.

In 2017, peripheral nerve surgeons were introduced to this patient population and improvement in function has been reported after nerve transfer and/or decompression.^{3,5,16,17} The majority of surgical interventions are focused on the upper extremity. However, in the lower extremity, only one case report has been published despite more than 36% of patients having lower extremity involvement.^{5,18} In this study, we report our management algorithm, treatment options, and preliminary outcomes for residual weakness of the lower extremity in children with AFM. Additionally, the surgical techniques of novel lower extremity nerve transfers are described.

METHODS

Retrospective Review

In accordance with the institutional review board, a retrospective review from 2017 to 2020 was performed to identify patients from the 2016 AFM epidemic who received nerve transfers for lower extremity function. The 2016 cohort was selected to allow adequate follow-up time for outcome assessment. Charts were reviewed for demographic information, date of diagnosis, limbs with weakness, ventilator dependence during acute illness phase, time between onset and surgical intervention, preoperative Medical Research Council (MRC) grades, and surgical details.

Indication for Surgery

Patients diagnosed with AFM who had residual weakness 6 months or more after diagnosis were considered for surgical intervention. Children who had viable nerve donors and demonstrated MRC 1–3 strength of their recipient muscles were considered for supercharge end-to-side (SETS) nerve transfers to augment function.^{19–21} Patients with no motor function, but viable nerve donors, had end-to-end (ETE) nerve transfers.^{21,22} Physical examination, not electrodiagnostic testing (including electromyography), was used to determine surgical candidacy because often the electrodiagnostic studies were performed under sedation and patients could not provide voluntary contractions. (See Video 1 [online], which displays preoperative examination of Patient 3 demonstrating active flexion of all toes, extension of the lesser toes, and hip flexion. Hip abduction and knee extension had MRC 1/5 strength, and hip adduction and knee flexion were 0/5.)

Although there are commonalities among cases, each child with AFM presented with unique deficits. Muscle weakness did not follow predictable spinal level or peripheral nerve injury patterns, but had a predilection for the proximal muscle groups. Priority for restoration of function was focused on hip stability (gluteal nerves) and knee extension (femoral nerve), followed by knee flexion (sciatic nerve branches to biceps femoris and semitendinosus) and lower leg function (if absent).

Surgical Technique

A thorough examination was required to determine affected muscles and muscles expendable for transfer. In addition, intraoperative nerve stimulation was utilized

to guide donor nerve selection. Ideal nerve donors had expendable function and antigravity motion with nerve stimulation at 0.5 mA. All nerve coaptations were performed in an ETE or SETS manner, as noted above, with 9-0 nylon epineurial sutures and fibrin glue. Direct coaptations were preferred and utilized unless otherwise noted.

Restoration of Gluteal Nerve Function

Sciatic fascicles can be used to reinnervate the gluteal, hamstring, and femoral nerve muscles, referred to herein as sciatic fascicular transfers. For gluteal nerve function, the sciatic and gluteal nerves were approached through a single incision. In the prone position, a curvilinear incision was made across the buttock from the posterior superior iliac spine to the greater trochanter (Fig. 1A). Dissection was carried down to the gluteus maximus muscle (Fig. 1B). The gluteus maximus was split in line with its fibers while maintaining meticulous hemostasis (Fig. 1C). The sciatic nerve was identified inferior to the piriformis muscle. External neurolysis of the sciatic nerve was performed to mobilize it from any adhesions about the piriformis, obturator internus, gemelli, or quadratus femoris. The superior gluteal nerve was identified superior to the piriformis muscle traveling between gluteus medius and gluteus minimus. The superior gluteal nerve runs with the superior gluteal artery and vein, which were protected. The inferior gluteal nerve was identified between the sciatic and posterior femoral cutaneous nerves. It curves superiorly after exiting beneath the piriformis to segmentally innervate gluteus maximus from its undersurface.

Once the donor and recipient nerves were identified, the epineurium of the sciatic nerve was divided longitudinally to facilitate internal neurolysis. Topography of the sciatic nerve at this level was consistent. The peroneal component was lateral and the tibial component medial. Hamstring branches were found superficial and centrally. A handheld nerve stimulator was utilized to identify functioning and expendable donor fascicles. Donor fascicles demonstrating strong, antigravity function with 0.5 mA were identified and isolated with a vessel loop. Redundant function in the remaining nerve was also confirmed. The gluteal nerves were then exposed. Transfer of the strongest sciatic donor fascicle was performed to either the superior or inferior gluteal nerves. In the first few cases, we targeted the inferior gluteal nerve due to its proximity to the sciatic nerve and to balance the strong hip flexion present in those patients. However, we now prioritize the superior gluteal nerve to restore gluteus medius muscle function due to its importance in hip stability during weight-bearing activities (Figs. 1D, 2).²³

Restoration of Femoral Nerve Function

Femoral nerve function can be achieved via a variety of donors, including sciatic fascicles, nerve to sartorius, obturator nerve, and thoracoabdominal intercostal nerves. We chose to use as many donor options as available given the importance of hip flexion and knee extension with gait. Obturator nerve function was rarely preserved, but it could be used to restore function to the femoral nerve as previously described by Tung et al when available.²⁴

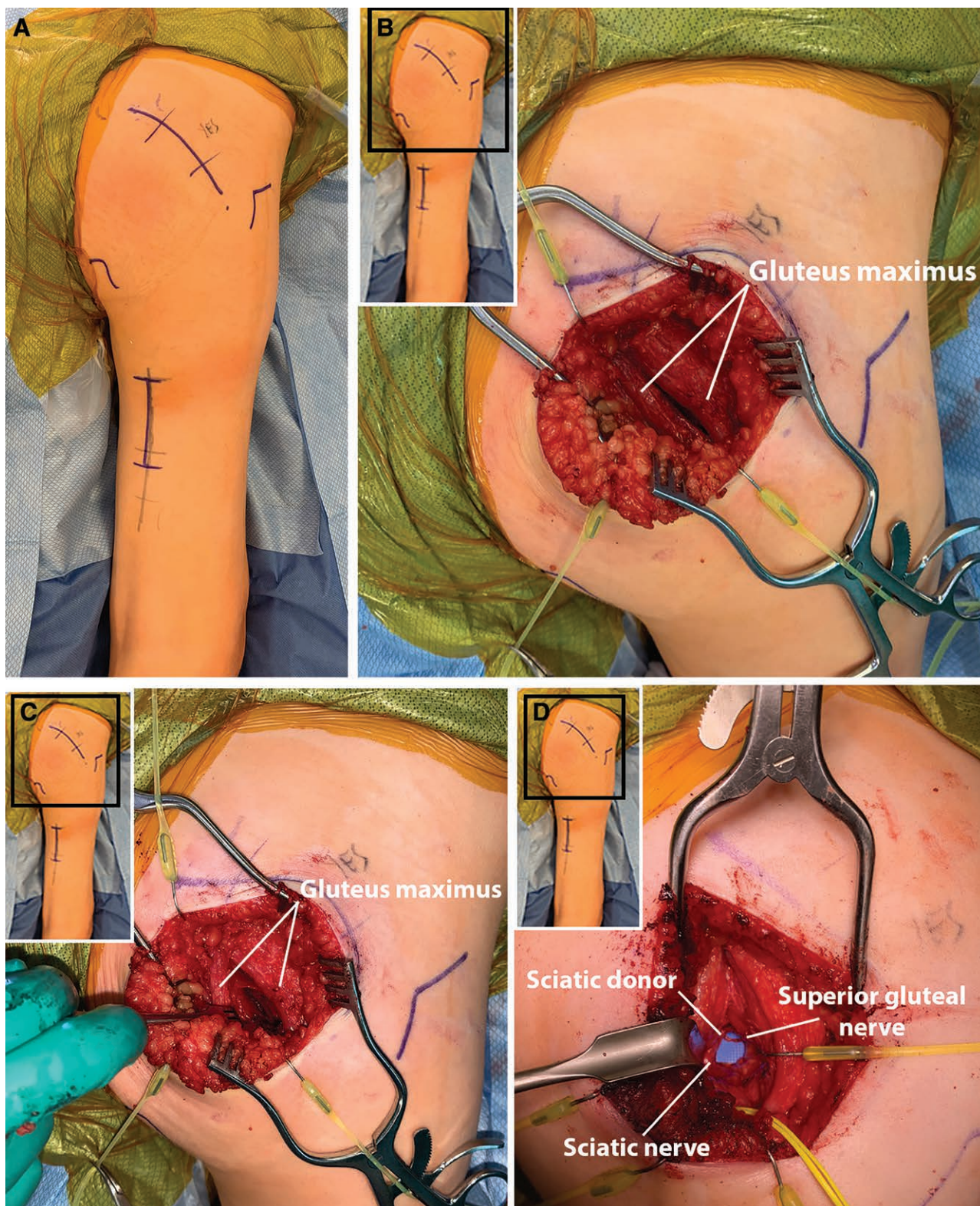


Figure 1. Nerve transfer approach. A, Curvilinear incision was made to (B) expose gluteus maximus. C, Gluteus maximus was split in line with its fibers. D, The selected donor fascicle from the sciatic nerve was coapted to the superior gluteal nerve.

Sciatic Fascicular Transfer

With the patient prone, a 5-cm longitudinal incision was made centered between the biceps femoris and the

semitendinosus just distal to the inferior gluteal crease (Fig. 3A). Dissection was carried down through the subcutaneous tissues, and the intermuscular interval between

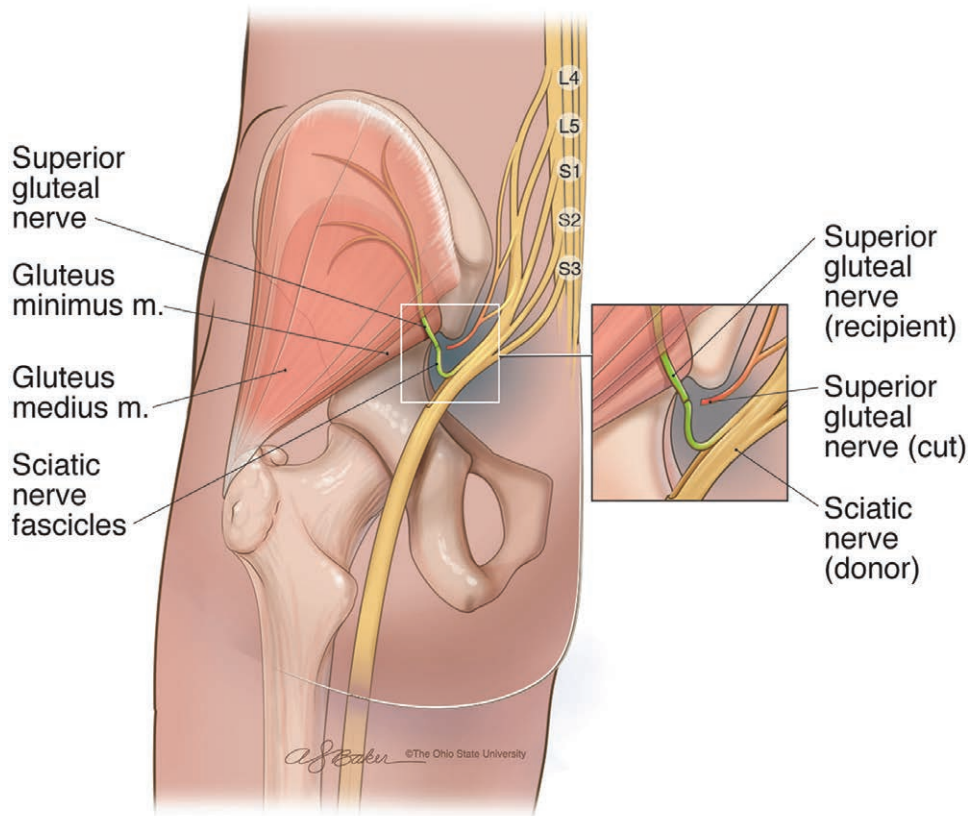


Figure 2. A redundant fascicle was selected from the sciatic nerve for end-to-end transfer to the superior gluteal nerve.

the biceps femoris and the medial hamstring muscles was utilized to expose the sciatic nerve. Internal neurolysis was performed at this level. Donor fascicles were identified (Fig. 4). (See Video 2 [online], which displays a handheld nerve stimulator being utilized to isolate expendable sciatic fascicles for nerve transfer.)

If the sciatic nerve was utilized for restoration of two functions, donor fascicles with different functions were utilized. For example, if fascicles for toe flexion (tibial nerve) were used for gluteal nerve function, the fascicles for toe extension (peroneal nerve) would then be used for femoral nerve function and vice versa.

Once the donor nerves were isolated and gluteal nerve transfers were complete (if performed), the gluteal incision was closed and the leg incisions were temporarily closed with staples and covered in a semioclusive dressing. The patients were then positioned supine. The femoral nerve was approached via a 6- to 8-cm longitudinal incision made just lateral to the palpable femoral pulse beginning just distal to the inguinal ligament (Fig. 3B). Fascial layers were longitudinally divided to reveal the branches of the femoral nerve. Any compressive soft tissue was released to perform the external neurolysis.²⁵ The decompression was considered complete when the femoral nerve glided smoothly and one finger could be easily passed proximally beneath the inguinal ligament.

Femoral nerve neurolysis was performed and function was assessed with hand held stimulation (Fig. 3C). The

branching pattern of the femoral nerve has been previously described.²⁴ The hip was flexed and abducted to facilitate exposure of posterior incision. The sciatic nerve with its tagged donor fascicle was identified in this position. In cases where gluteal function was intact, the entire sciatic exposure was performed in this manner rather than beginning prone. A tunnel was created with blunt dissection just medial to the femur (Fig. 3D). Careful dissection lateral to the superficial femoral artery and medial to the profunda femora was performed to pass the femoral nerve branch posterior for direct coaptation to the sciatic donor fascicle. Due to their distal insertion, the vastus medialis and intermedius branches were most consistently available to neurolyse proximally from the femoral nerve proper to allow for adequate length to traverse the thigh and reach the sciatic nerve posteriorly (Figs. 4, 5).

Nerve to Sartorius Transfer

For unclear reasons, the sartorius nerve was spared in some of the patients with AFM. The femoral nerve was approached as described above (Fig. 6A). When the sartorius nerve was intact, it was used as a donor to restore function to the quadriceps muscles (Fig. 6B).²⁶

Thoracoabdominal Intercostal Nerve Transfer

A lower paramedian incision was made on the abdomen. The anterior rectus sheath was incised longitudinally. The rectus abdominus muscle was retracted

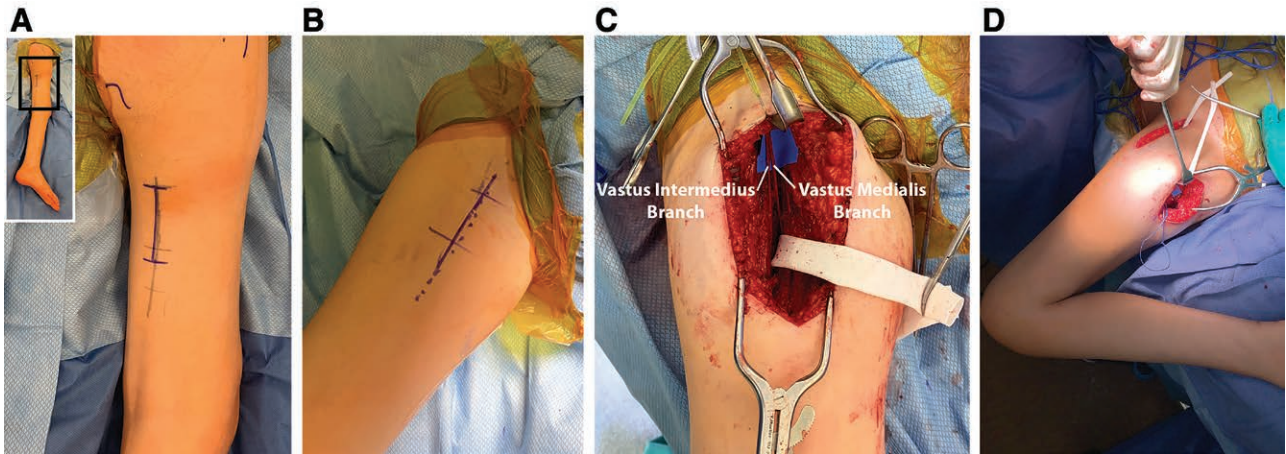


Figure 3. Nerve transfer approach. A, A longitudinal incision was made between biceps femoris and semitendinosus to expose the sciatic nerve. In this case, nerve transfer for restoration of gluteal function was also performed so the initial exposure was made in the prone position. B, The patient was then turned supine and a longitudinal incision beginning at the inguinal ligament was made for exposure of the femoral nerve. C, The femoral nerve branches to vastus medialis and vastus lateralis were neurolysed for transfer. D, A penrose drain was passed through the tunnel between the anterior and posterior exposures. This facilitated passing the femoral recipient branches into the posterior exposure.

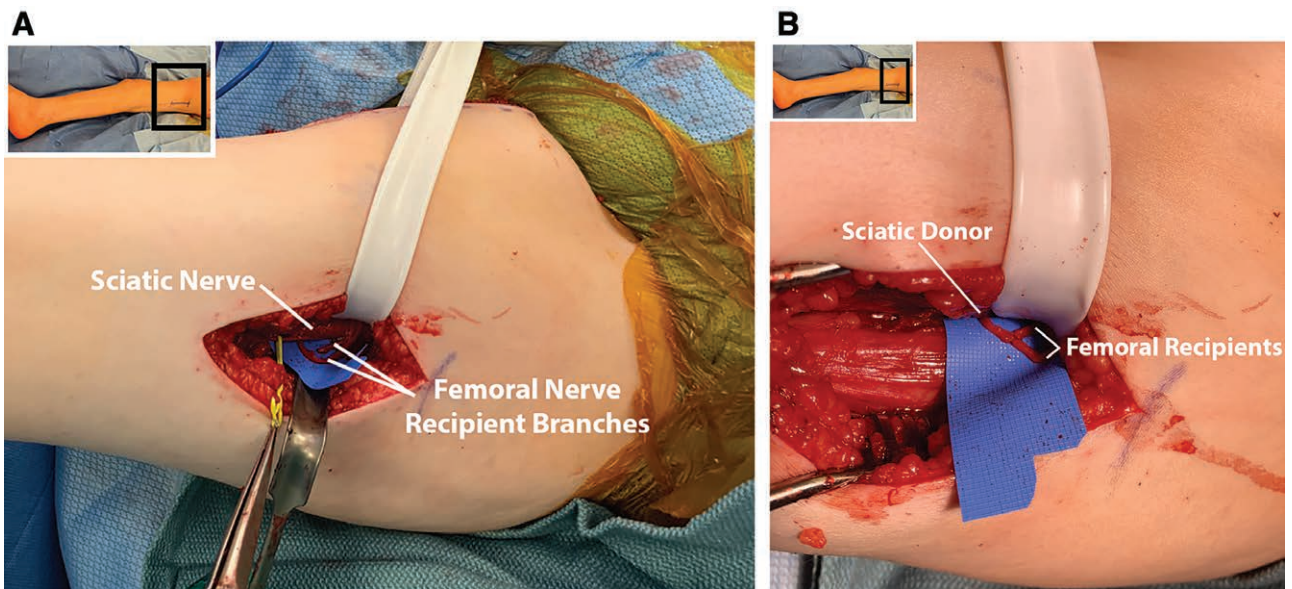


Figure 4. Nerve transfer approach. A, The selected donor fascicle from the sciatic nerve was isolated with a yellow vessel loop. The femoral recipient branches (vastus medialis and vastus intermedius) are also visible. B, In this case, only 1 sciatic fascicle was available for coaptation to the femoral nerve branches.

medially to expose its segmental innervation from the intercostal nerves. The inferior two to three intercostal nerves were neurolysed into the muscle as distal as possible and transected. The femoral nerve branches were exposed as described above. A wide subcutaneous tunnel was created just anterior to the rectus abdominus fascia between the incisions to minimize potential compression of the nerve graft. A sural nerve autograft was harvested using standard surgical technique. Alternatively, the saphenous nerve was harvested from the femoral nerve exposure in the thigh in some cases. A subcutaneous tunnel was created just anterior to the rectus abdominus fascia between the incisions. The sural nerve graft

was coapted to the intercostal donors and femoral nerve branch recipient in a tension-free fashion (Fig. 7).

Restoration of Hamstring Function

Hamstring function can be restored with sciatic fascicular transfers. With the patient in prone positioning, the sciatic nerve was approached via a longitudinal incision centered between the biceps femoris and the semitendinosus just distal to the inferior gluteal crease as described above. The branches to the hamstring muscles are found superficial to the sciatic nerve proper and often are accompanied by vessels. Internal neurolysis of the sciatic nerve was performed as described above and fascicles were identified

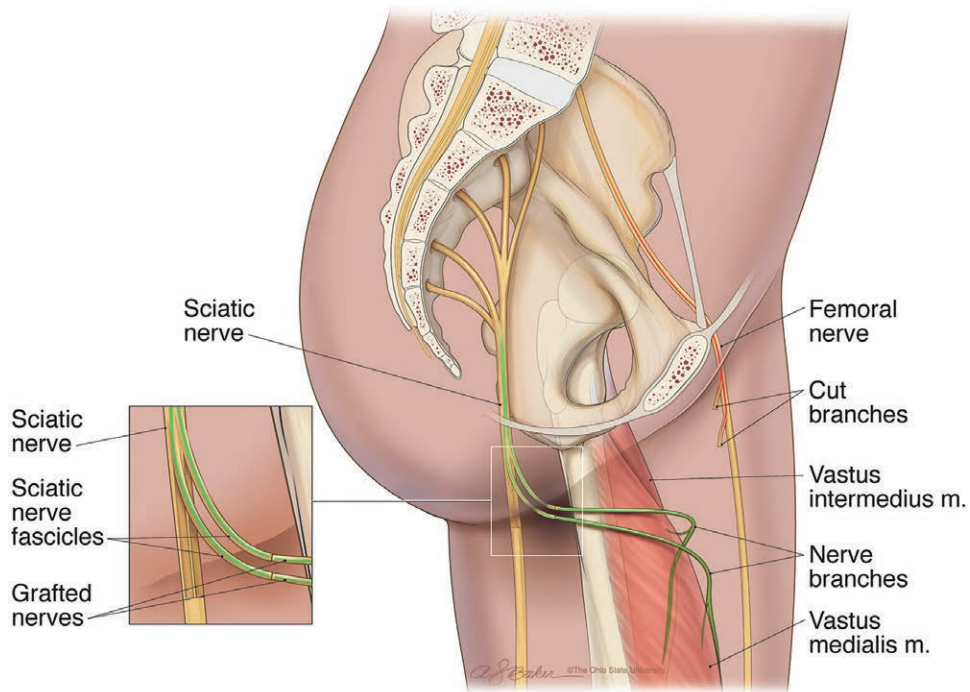


Figure 5. Redundant fascicles from the sciatic nerve were transferred to the nerves to the vastus medialis and vastus lateralis. The vastus medialis and vastus lateralis branches were tunneled medial to the femur for direct coaptation to the sciatic donors.

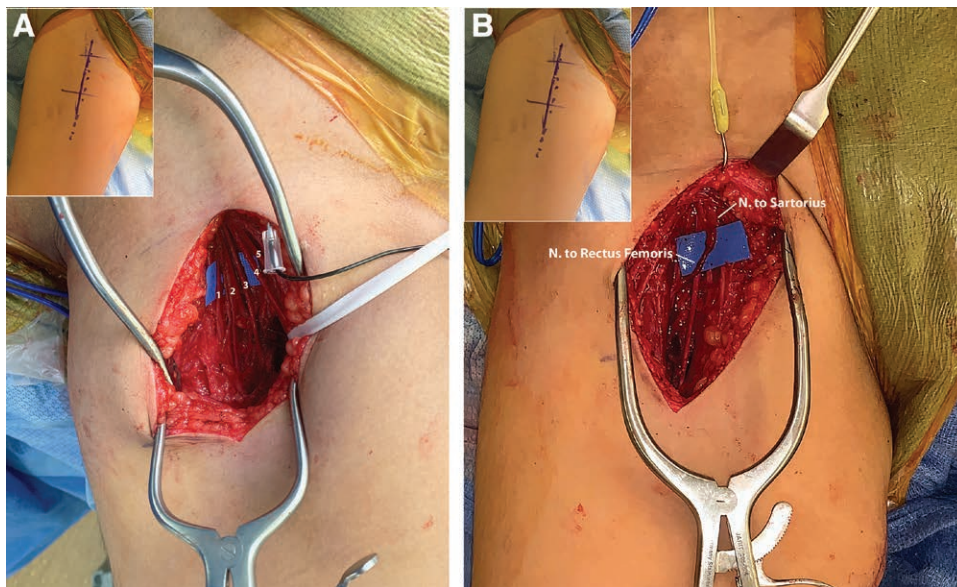


Figure 6. Nerve transfer approach. A, The femoral nerve branches were exposed. From lateral to medial: (1) rectus femoris, (2) vastus lateralis, (3) vastus intermedius, (4) vastus medialis, and (5) saphenous. B, The more proximal and lateral branch to sartorius was coapted to the branch to rectus femoris.

and transferred to the nerve branches of the biceps femoris and semitendinosus nerves without tension (Fig. 8).

Perioperative Care

Postoperatively, knee immobilizers were placed to decrease motion of the extremity for femoral nerve transfers only; otherwise, patients were not immobilized.

Occupational and physical therapy resumed after 3 weeks with a focus on donor activation.²⁷

Outcomes

Motor function was evaluated by the senior author and/or a licensed occupational therapist. Postoperative MRC grades were recorded. Additionally, qualitative

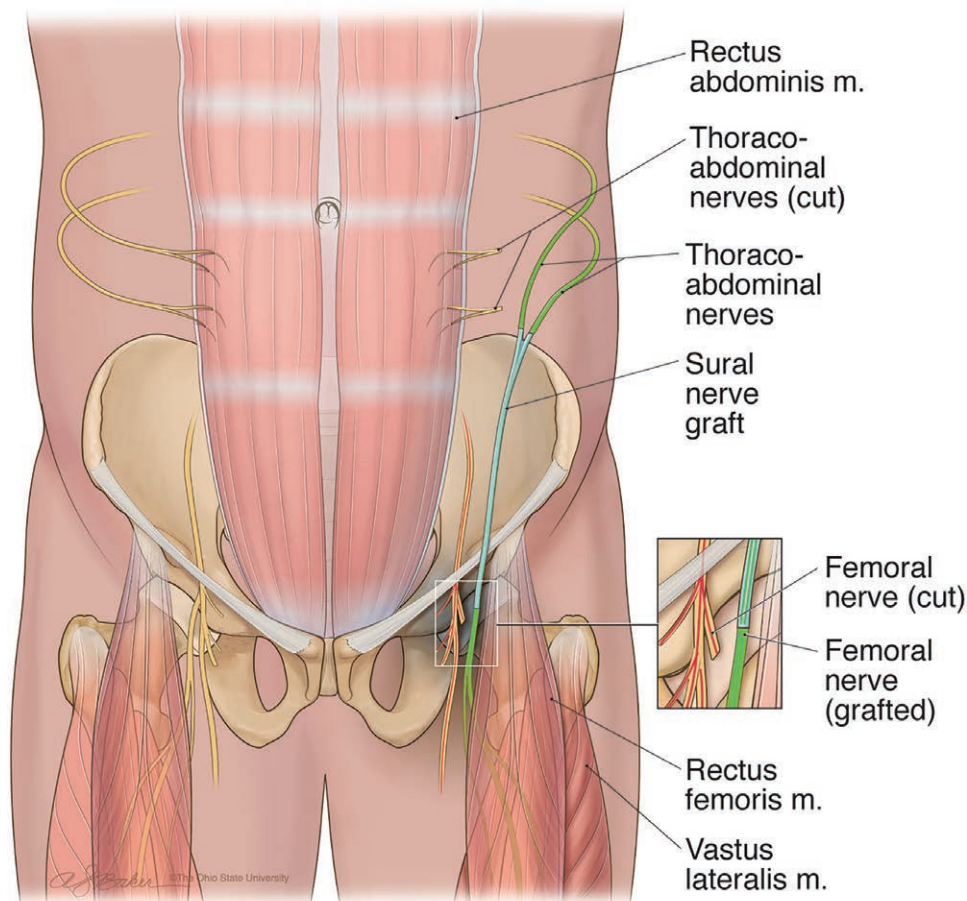


Figure 7. Thoracoabdominal intercostal nerves were transferred to branches of the femoral nerve with an intervening nerve autograft.

changes in function after surgery, such as ability to transfer, stand, or ambulate, were assessed.

RESULTS

For the 2016 AFM epidemic cohort, eight patients with an average age of 4.4 years (range 2–7 years) underwent lower extremity nerve transfers from 2017 to 2018 (Table 1). Average time from diagnosis to surgery was 15.7 months (range 10–20 months), and average follow-up was 29.1 months (range 6–40 months). One of the eight patients was lost to follow-up.

Of the seven remaining patients, five received sciatic fascicular to gluteal nerve transfers (six limbs) (Table 2). The change in MRC grades from before to after surgery ranged from 1 to 4. All were wheelchair dependent for distance preoperatively. Postoperatively, four of the five patients were walking with ankle foot orthoses (AFO) or knee ankle foot orthoses (KAFOs) as their primary modes of ambulation, two with a posterior wheeled walker. (See Video 3 [online], which displays the same patient from Video 1 demonstrating ambulation with a right knee-ankle-foot orthosis following sciatic fascicular transfer (toe flexor) to the inferior gluteal nerve, as well as nerve transfers to restore quadriceps function.) The fifth child was crawling

or using a wheelchair as his primary mode of ambulation at the time of latest follow-up (6 months after surgery).

Nerve transfers for restoration of quadriceps function were performed in seven patients (eight limbs). Nerve transfer donors included varying combinations of nerve to sartorius (seven limbs), thoraco-abdominal intercostal nerves (four limbs), and sciatic nerve fascicles (two limbs). One limb achieved MRC grade 4 function, two limbs had MRC grade 3 function, and five limbs had MRC grade 2 function (Table 2).

Sciatic fascicular nerve transfers for restoration of hamstring function were performed in two patients. The recipient nerves were branches to semitendinosus and biceps femoris for both patients. The MRC grades for knee flexion were 0 preoperatively for both patients and improved to 4 in one patient and 3 in one patient postoperatively.

One patient had transfer of nerve to vastus medialis to the medial gastrocnemius branch for restoration of plantarflexion. His MRC grade improved to 3.

No patient had discernable donor deficits or reduced functional status after surgery. There were no surgical complications. Thoracoabdominal intercostal nerve transfer was aborted intraoperatively in two patients due to denervation of the rectus abdominus and lack of response to intraoperative nerve stimulation.

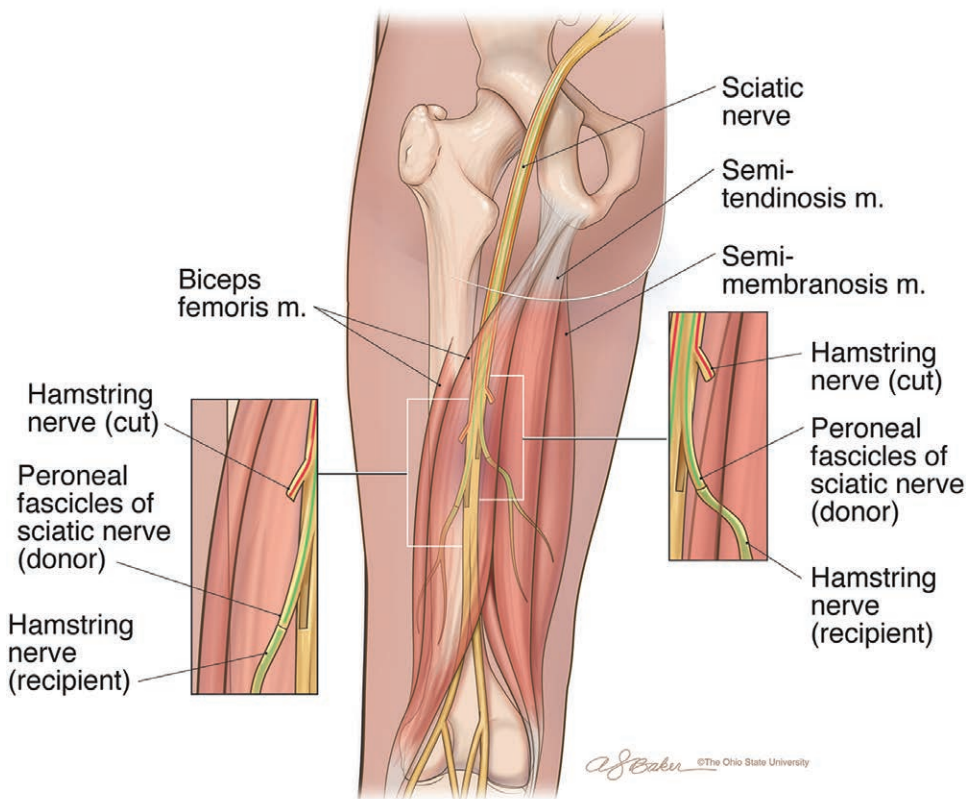


Figure 8. Redundant fascicles from the sciatic nerve (peroneal fascicles shown) were transferred to the nerve branches to the biceps femoris and semitendinosus.

Table 1. Patient Characteristics

Patient	Age at Onset (y)	Age at Surgery (y)	Time from Diagnosis to Surgery (mo)	Length of Follow-up (mo)	Initial Involvement	Required Ventilator
1	5	6	10	40	RUE, BLE	No
2	4	5	10	—	BLE	No
3	6	7	12	38	RUE, RLE	No
4	2	4	19	28	RLE	No
5	4 mo	1	17	31	BLE	No
6	2	3	17	32	All limbs	Yes
7	1	2	17	6	All limbs	No
8	1	3	18	26	All limbs	No
	Avg. 3	Avg. 4.4	Avg. 15.7	Avg. 29.1		

BLE, bilateral lower extremity; RLE, right lower extremity; RUE, right upper extremity.

DISCUSSION

AFM is a devastating diagnosis that has presented a unique set of reconstructive challenges to address functional deficits in the lower extremity. By applying principles for nerve reconstruction established in the upper extremity, we have developed a novel algorithm for the management of lower extremity weakness in patients with AFM. Although not restoring “normal” function or gait, our findings reiterate the famous Sterling Bunnell, MD mantra, “When you have nothing, a little is a lot.”²⁸ We described our surgical techniques and demonstrated recovery of lower extremity function after nerve transfers in children with AFM.

Our overall surgical goal for these children was to restore function and improve independence. Our priority

was for hip stabilization, followed by knee extension, knee flexion and then ankle motion. Given the limited number of functioning and expendable muscles, tendon transfers were not possible. For example, iliopsoas tendon transfers have been utilized to address hip abduction and extension weakness in patients with poliomyelitis,²⁹ but hip flexion was typically too weak to allow for transfer in this cohort of AFM patients. Thus, nerve transfers offer a unique alternative to improve function in this patient population.⁵ For both nerve and tendon transfers, donor site morbidity remains a concern. However, the vast majority of nerve transfers performed in this cohort were considered low risk as the donor functions were expendable. For example, loss of toe flexion or extension in a nonambulatory

Table 2. Relevant Exam Findings and Surgical Procedures

Patient	Age at Surgery	Time from Diagnosis to Surgery	Time from Surgery to Follow-up	Preoperative MRC	Procedures Performed	Postoperative MRC	Subjective Changes
1	6	11	40	RIGHT: Gluteus: 0 Hip adduction: 3 Plantarflexion: 0 Toe extension: 4 LEFT: Gluteus: 0 Hip flexion: 3 Quadriceps: 1 Toe flexion: 4	RIGHT: 1. Sciatic fascicle (toe extensor) to inferior gluteal 2. Adductor longus to inferior gluteal (8-cm saphenous graft) 3. Vastus medialis to medial gastrocnemius LEFT: 1. Sciatic fascicle (toe flexor) to inferior gluteal 2. Sartorius SETS to rectus femoris	RIGHT: Gluteus: 3 Hip adduction: 3 Plantarflexion: 3 Toe extensors: 4 LEFT: Gluteus: 3 Quadriceps: 4 Toe flexors: 4	Preoperative: used wheelchair. Postoperative: walks with posterior walker and bilateral AFOs. Transitioning to Loftstrand crutches.
2	5	10	—	RIGHT: Gluteus: 0 Hip flexion: 3 Quadriceps: 0 Toe flexion: 3 Abdominal strength intact	RIGHT: 1. Sciatic fascicle (toe flexor) to inferior gluteal 2. Rectus abdominus to rectus femoris (saphenous nerve graft 10cm)	—	—
3	7	12	38	RIGHT: Gluteus: 1 Quadriceps: 1 Toe flexion: 4	RIGHT: 1. Sciatic fascicle (toe flexor) to inferior gluteal 2. Rectus abdominus to vastus lateralis SETS (sural 10cm) 3. Sartorius to rectus femoris SETS	RIGHT: Gluteus: 2 Quadriceps: 2 Toe flexion: 5	Preoperative: ambulated with KAFO and walker. Wheelchair for long distances. Postoperative: increased walking distance/endurance. Ambulates with KAFO. Only uses wheelchair for basketball. 6min walk test within normal limits for age.
4	4	20	28	RIGHT: Hip flexion: 4 Quadriceps: 2 Abdominal strength intact	RIGHT: 1. Rectus abdominus to rectus femoris (sural nerve graft 10cm) 2. Sartorius to vastus lateralis	RIGHT: Quadriceps: 2 Abdominal strength intact	Preoperative: ambulated with AFO. Postoperative: ambulates with AFO. Increased endurance for activities and on treadmill.
5	1	19	31	LEFT: Gluteus: 1 Quadriceps: 0 Eversion: 4 Abdominal strength intact	LEFT: 1. Sciatic fascicle (foot eversion) to vastus medialis 2. Rectus abdominus to vastus lateralis (sural nerve graft 10cm) 3. Sartorius to rectus femoris	LEFT: Gluteus: 2 Quadriceps: 2 Eversion: 4 Abdominal strength intact	Preoperative: unable to ambulate. Unable to sit independently due to weak paraspinal muscles. Postoperative: ambulates with HKAFO and walker, but still uses wheelchair. Right leg involved, but had no available donors for nerve transfer.
6	3	17	32	RIGHT: Gluteus: 0 Quadriceps: 0 Hamstrings: 0 Toe flexion: 4 Eversion: 4	RIGHT: 1. Sciatic fascicle (foot eversion) to superior gluteal 2. Sciatic fascicle (toe flexor) to semitendinosus and biceps femoris 3. Sartorius to rectus femoris 4. Aborted rectus abdominus due to denervation	RIGHT: Gluteus: 2 Quadriceps: 2 Hamstrings: 2 Toe flexion: 4 Eversion: 4	Preoperative: unable to bear weight through left leg. Sits independently. Postoperative: ambulates with KAFO.

(Continued)

Table 2. (Continued)

Patient	Age at Surgery	Time from Diagnosis to Surgery	Time from Surgery to Follow-up	Preoperative MRC	Procedures Performed	Postoperative MRC	Subjective Changes
7	2	17	6	RIGHT: Gluteus: 0 Quadriceps: 2 Hamstrings: 0 Hip flexion: 3 Eversion: 3 Toe flexion: 3 Abdominal strength intact	RIGHT: 1. Sciatic fascicle (foot eversion) to superior gluteal 2. Sciatic fascicle (toe flexion) to semitendinosus and biceps femoris 3. Sartorius to rectus femoris SETS and vastus lateralis SETS 4. Aborted rectus abdominus due to denervation	RLE: Gluteus: 2 Quadriceps: 2 Hamstrings: 3 Eversion: 3 Toe flexion: 3	Preoperative: unable to ambulate Postoperative: uses wheelchair. Able to crawl (new function)
8	2	19	26	RIGHT: Quadriceps: 0 LEFT: Gluteus: 0 Quadriceps: 0 Toe Flexion 4 Toe Extension 4	RIGHT: 1. Sartorius to vastus medialis SETS LEFT: 2. Sciatic fascicle (toe flexor) to superior gluteal SETS 3. Sciatic fascicles (toe extension) to rectus femoris and vastus medialis	RIGHT: Quadriceps: 3 LEFT: Gluteus: 3 Quadriceps: 2	Preoperative: used wheelchair. Postoperative: posterior walker, transitioning to front walker as primary mode of ambulation with KAFO on left. Stand 42 minutes without assistance. FES bike endurance improved to >30 min.

Strength measures of the muscles/motions that were recipients of the nerve transfers are bolded. All nerve transfers were end-to-end unless otherwise noted. Age reported in years, and times in months. FFMT, free functional muscle transfer; HKAFO, hip knee ankle foot orthosis.

child would have minimal functional impact. However, no donor site deficits were observed in this cohort.

Hip stabilization and restoring the ability to stand and weight shift was the primary goal of intervention and was achieved with sciatic fascicular transfers to the gluteal nerves. Capitalizing on the redundancy of fascicles in the proximal sciatic nerve that contributed to toe motion, we were able to perform ETE nerve transfers to the either the superior or inferior gluteal nerve. The ability to weight-shift is important to reduce the risk of pressure sores in patients with tetraplegia,³⁰⁻³³ and independent transfers facilitate functional mobility and performance of activities of daily living.^{33,34} This is particularly important for children with AFM who often have proximal upper extremity weakness that further limits weight-shift and transfer abilities.

The secondary surgical goal was achieving ambulation. We felt that this would be best achieved with the additional restoration of femoral and/or hamstring function. However, given the paucity of proximal muscle function and lack of abundant nerve donors, continued bracing and the use of assistive devices was expected. The patients in this cohort demonstrated life-changing improvements in function following surgery. Four of the five patients who were wheelchair-dependent are now able to ambulate and the fifth child is able to crawl. The importance of ambulation for engagement in activities and social development cannot be understated. The ability to get out of a wheelchair increases independence and provides a degree of

return to “typical” childhood. In children with cerebral palsy, the inability to ambulate has been associated with difficulty participating in activities and forming friendships.³⁵⁻³⁷ Although MRC grades typically associated with success (MRC 3–4) were identified in only some patients, the global qualitative improvement and increased exercise tolerance cannot be discounted. These findings are particularly notable, given the late presentations and many month plateaus of function before our interventions.

As AFM is a recently recognized condition, literature regarding surgical outcomes is lacking. A previous case report noted return of MRC 4 knee extension 31 months following transfer of the contralateral obturator nerve (anterior branch) to the femoral nerve.⁵ The surgical technique for sciatic-to-femoral nerve transfers has been described, but no patient outcomes were included.²³ Remaining surgical papers focus on the upper extremity, with moderate success reported following upper extremity nerve transfers,^{3,17,19-21} similar to the findings for lower extremity transfers in this cohort. Additionally, the secondary sequelae of AFM have not been established. Children with poliomyelitis who have weakness about the hip frequently develop hip contractures, dysplasia, subluxation, or dislocation.²⁹ It is conceivable that nerve transfers that provide adequate tone to stabilize the hip may prevent these secondary sequelae, even if they are not powerful enough to allow independent ambulation. However, it is unclear whether patients with AFM will suffer any of the late sequelae seen in poliomyelitis and other paralytic

conditions. Long-term evaluation and follow-up is needed to determine the natural history of AFM.

Limitations of this study include the retrospective study design and the small number of patients. Additionally, it is difficult to determine the contribution of individual nerve transfers to the overall improvement in function. For example, no patient with follow-up had transfer of the thoraco-abdominal intercostal nerves in isolation. Utilizing as many available donor nerves as possible was preferred, to maximize the potential for functional recovery. Finally, there was no control cohort and the natural history of AFM is largely unknown. However, because the majority of patients in this cohort were a year or more from diagnosis, it is unlikely that substantial functional gains would have occurred after that time. Despite the small cohort in this study, these promising results provide support for consideration of lower extremity nerve transfers in children with AFM.

CONCLUSIONS

The unique needs of this patient population and variable patterns of residual weakness require meticulous assessment and development of individualized surgical plans. It is important to counsel the family regarding appropriate goals and expectations. However, in many cases, the surgical risks are low and potential benefits are monumental. The described nerve transfer procedures have established the possibility of achieving ambulation and substantially improving independence in this long-term follow-up study. These novel nerve transfers offer hope for improved function and independence in the face of a devastating disease.

Amy M. Moore, MD, FACS

Department of Plastic and Reconstructive Surgery
The Ohio State University Wexner 1 Center
915 Olentangy River Rd
Suite 2100
Columbus, OH 43212
E-mail: amy.m.moore@osumc.edu

PATIENT CONSENT

Parents or guardians provided written consent for the use of the patients' images.

REFERENCES

- McLaren N, Lopez A, Kidd S, et al. Characteristics of patients with acute flaccid myelitis, United States, 2015–2018. *Emerg Infect Dis.* 2020;26:212–219.
- McKay SL, Lee AD, Lopez AS, et al. Increase in acute flaccid myelitis – United States, 2018. *MMWR Morb Mortal Wkly Rep.* 2018;67:1273–1275.
- Pino PA, Intravia J, Kozin SH, et al. Early results of nerve transfers for restoring function in severe cases of acute flaccid myelitis. *Ann Neurol.* 2019;86:607–615.
- Messacar K, Schreiner TL, Van Haren K, et al. Acute flaccid myelitis: a clinical review of US cases 2012–2015. *Ann Neurol.* 2016;80:326–338.
- Doi K, Sem SH, Hattori Y, et al. Contralateral obturator nerve to femoral nerve transfer for restoration of knee extension after acute flaccid myelitis: a case report. *JBJS Case Connect.* 2019;9:e0073.
- Hopkins SE. Acute flaccid myelitis: etiologic challenges, diagnostic and management considerations. *Curr Treat Options Neurol.* 2017;19:48.
- Ayers T, Lopez A, Lee A, et al. Acute flaccid myelitis in the United States: 2015–2017. *Pediatrics.* 2019;144:e20191619.
- Gordon-Lipkin E, Muñoz LS, Klein JL, et al. Comparative quantitative clinical, neuroimaging, and functional profiles in children with acute flaccid myelitis at acute and convalescent stages of disease. *Dev Med Child Neurol.* 2019;61:366–375.
- Messacar K, Sillau S, Hopkins SE, et al. Safety, tolerability, and efficacy of fluoxetine as an antiviral for acute flaccid myelitis. *Neurology.* 2019;92:e2118–e2126.
- CDC. AFM cases and outbreaks. Available at: <https://www.cdc.gov/acute-flaccid-myelitis/cases-in-us.html>. Updated 4/6/2020. Accessed 5/2/2020.
- Sun S, Bian L, Gao F, et al. A neonatal mouse model of Enterovirus D68 infection induces both interstitial pneumonia and acute flaccid myelitis. *Antiviral Res.* 2019;161:108–115.
- Dyda A, Stelzer-Braid S, Adam D, et al. The association between acute flaccid myelitis (AFM) and enterovirus D68 (EV-D68) – what is the evidence for causation? *Euro Surveill.* 2018;23:17-00310.
- Downey R, McElvain D, Murphey DK, et al. Acute flaccid myelitis among hospitalized children in Texas, 2016. *Pediatr Neurol.* 2020;106:50–55.
- Taylor DR, Krishnakumar S. Acute flaccid myelitis in children. *Pediatr Rev.* 2019;40:602–604.
- Murphy OC, Messacar K, Benson L, et al; AFM working group. Acute flaccid myelitis: cause, diagnosis, and management. *Lancet.* 2021;397:334–346.
- Saltzman EB, Rancy SK, Sneag DB, et al. Nerve transfers for enterovirus D68-associated acute flaccid myelitis: a case series. *Pediatr Neurol.* 2018;88:25–30.
- Nath RK, Somasundaram C. Functional improvement of upper and lower extremity after decompression and neurolysis and nerve transfer in a pediatric patient with acute flaccid myelitis. *Am J Case Rep.* 2019;20:668–673.
- Kidd S, Lopez A, Nix WA, et al. Vital signs: clinical characteristics of patients with confirmed acute flaccid myelitis, United States, 2018. *MMWR Morb Mortal Wkly Rep.* 2020;69:1031–1038.
- Farber SJ, Glaus SW, Moore AM, et al. Supercharge nerve transfer to enhance motor recovery: a laboratory study. *J Hand Surg Am.* 2013;38:466–477.
- Kale SS, Glaus SW, Yee A, et al. Reverse end-to-side nerve transfer: from animal model to clinical use. *J Hand Surg Am.* 2011;36:1631–1639.e2.
- Moore AM, Franco M, Tung TH. Motor and sensory nerve transfers in the forearm and hand. *Plast Reconstr Surg.* 2014;134:721–730.
- Moore AM. Nerve transfers to restore upper extremity function: a paradigm shift. *Front Neurol.* 2014;5:40.
- Reiman MP, Bolgla LA, Loudon JK. A literature review of studies evaluating gluteus maximus and gluteus medius activation during rehabilitation exercises. *Physiother Theory Pract.* 2012;28:257–268.
- Tung TH, Chao A, Moore AM. Obturator nerve transfer for femoral nerve reconstruction: anatomic study and clinical application. *Plast Reconstr Surg.* 2012;130:1066–1074.
- Jacobson L, Dengler J, Moore AM. Nerve entrapments. *Clin Plast Surg.* 2020;47:267–278.
- McInnes CW, Ha AY, Power HA, et al. Femoral nerve decompression and sartorius-to-quadriceps nerve transfers for partial femoral nerve injury: a cadaveric study and early case series. *J Neurosurg.* 2020:1–8.

27. Kahn LC, Moore AM. Donor activation focused rehabilitation approach: maximizing outcomes after nerve transfers. *Hand Clin.* 2016;32:263–277.
28. Entin MA. Sterling Bunnell—surgical giant at work. *Surg Clin North Am.* 1964;44:889–895.
29. Joseph B, Watts H. Polio revisited: reviving knowledge and skills to meet the challenge of resurgence. *J Child Orthop.* 2015;9:325–338.
30. Sonenblum SE, Sprigle SH. Some people move it, move it... for pressure injury prevention. *J Spinal Cord Med.* 2018;41:106–110.
31. Vos-Draper TL, Morrow MMB. Seating-related pressure injury prevention in spinal cord injury: a review of compensatory technologies to improve in-seat movement behavior. *Curr Phys Med Rehabil Rep.* 2016;4:320–328.
32. Leclercq C, Hentz VR, Kozin SH, et al. Reconstruction of elbow extension. *Hand Clin.* 2008;24:185–201, vi.
33. You JS, Kim YL, Lee SM. Effects of a standard transfer exercise program on transfer quality and activities of daily living for transfer-dependent spinal cord injury patients. *J Phys Ther Sci.* 2017;29:478–483.
34. Nyland J, Quigley P, Huang C, et al. Preserving transfer independence among individuals with spinal cord injury. *Spinal Cord.* 2000;38:649–657.
35. Bjornson KF, Belza B, Kartin D, et al. Ambulatory physical activity performance in youth with cerebral palsy and youth who are developing typically. *Phys Ther.* 2007;87:248–257.
36. Beckung E, Hagberg G. Neuroimpairments, activity limitations, and participation restrictions in children with cerebral palsy. *Dev Med Child Neurol.* 2002;44:309–316.
37. Kang LJ, Palisano RJ, Orlin MN, et al. Determinants of social participation—with friends and others who are not family members—for youths with cerebral palsy. *Phys Ther.* 2010;90:1743–1757.