

## Open Access

## Endoscopic Double Metallic Stenting in the Afferent and Efferent Loops for Malignant Afferent Loop Obstruction with Billroth II Anatomy

Kazunari Nakahara<sup>1</sup>, Yoshinori Sato<sup>1</sup>, Keigo Suetani<sup>1</sup>, Ryo Morita<sup>1</sup>, Yosuke Michikawa<sup>1</sup>, Shinjiro Kobayashi<sup>2</sup> and Fumio Itoh<sup>1</sup>

Departments of <sup>1</sup>Gastroenterology and Hepatology and <sup>2</sup>Gastroenterological and General Surgery, St. Marianna University School of Medicine, Kawasaki, Japan

Placement of endoscopic self-expandable metallic stents (SEMSs) is widely performed for malignant gastrointestinal obstructions as an effective palliative procedure.<sup>1-3</sup> However, because only one report exists on SEMS placement at the bifurcation of a surgically reconstructed intestine,<sup>4</sup> the safety and efficacy of the procedure have not been elucidated. We present a case of double SEMS placement at the bifurcation in Billroth-II gastrojejunostomy.

A 75-year-old man who had undergone distal gastrectomy with Billroth-II reconstruction was admitted to our institution because of obstructive jaundice due to pancreatic head cancer. We performed percutaneous transhepatic biliary drainage (PTBD), and then a biliary metallic stent was placed percutaneously. Contrast medium injection to the afferent loop through the PTBD tube demonstrated an afferent loop stricture because of tumor invasion (Fig. 1). Therefore, we performed enteral metallic stenting with a rendezvous technique. A guidewire was passed through the stricture through the PTBD tube into the stomach. After an endoscope was inserted into the stomach, the guidewire was grasped and withdrawn through the channel, and an enteral stent (22 mm×6 cm; Niti-S, TaeWoong Medical, Gimpo, Korea) was placed in the stricture (Fig. 2A). However, the expanded stent compressed

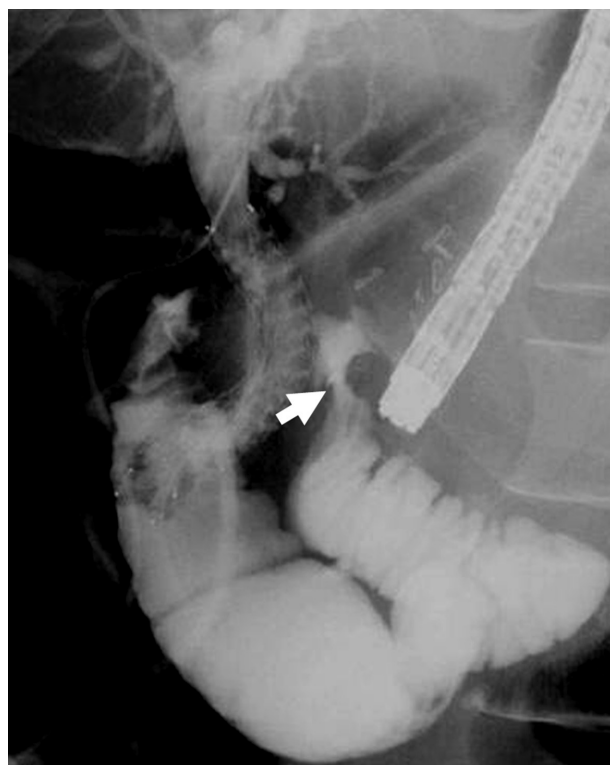


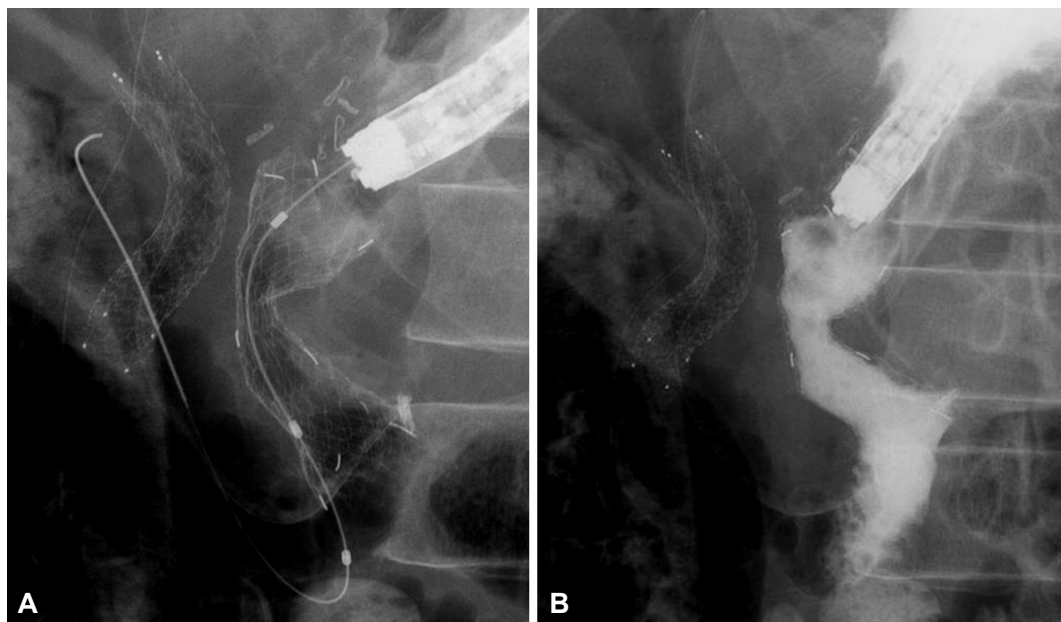Fig. 1. Contrast medium injection to the afferent loop through a percutaneous transhepatic biliary drainage tube demonstrating an afferent loop stricture (arrow).

the efferent loop, causing efferent loop obstruction. Contrast radiography showed that the contrast medium flowed only into the afferent loop (Fig. 2B). Therefore, a guidewire was passed through the stented side and into the efferent loop. Then, an enteral stent (22 mm×10 cm; Niti-S) was placed from the efferent loop to the stomach (Fig. 3A). After effer-

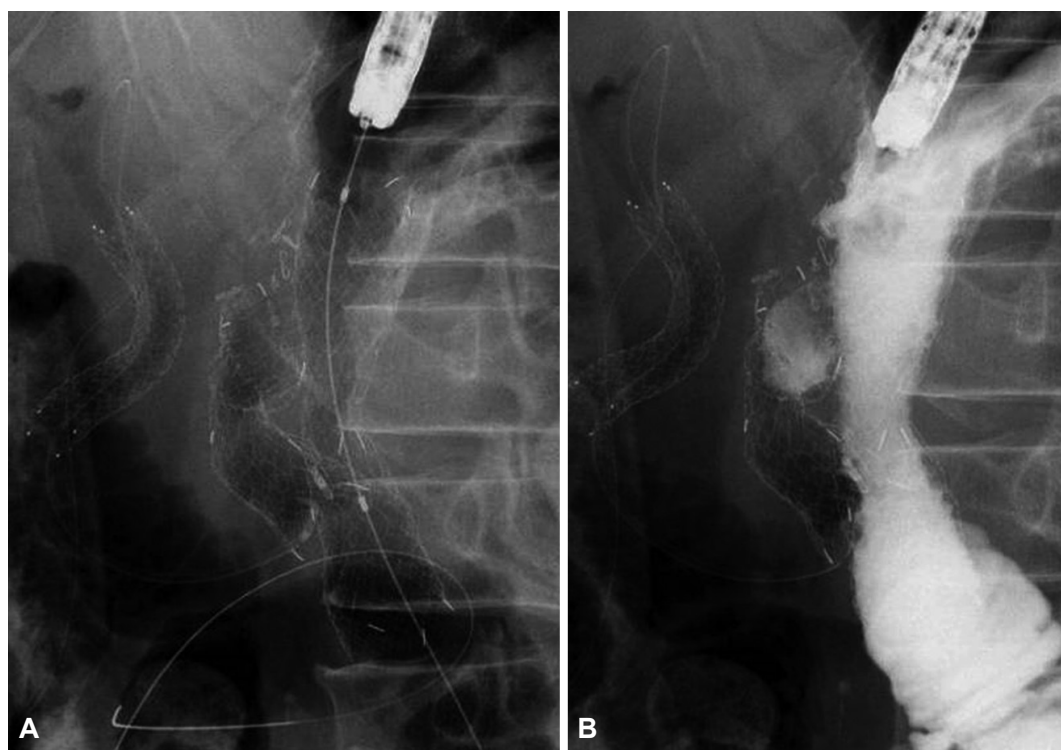
Received: March 25, 2015 Accepted: June 1, 2015

Correspondence: Kazunari Nakahara  
Department of Gastroenterology and Hepatology, St. Marianna University  
School of Medicine, 2-16-1, Sugao, Miyamae-ku, Kawasaki 216-8511, Japan  
Tel: +81-44-977-8111, Fax: +81-44-976-5805, E-mail: nakahara@marianna-u.ac.jp

© This is an Open Access article distributed under the terms of the Creative Commons Attribution Non-Commercial License (<http://creativecommons.org/licenses/by-nc/3.0>) which permits unrestricted non-commercial use, distribution, and reproduction in any medium, provided the original work is properly cited.



**Fig. 2.** (A) An enteral stent placed in the afferent loop stricture. (B) Contrast radiograph showing that contrast medium flows only into the afferent loop.



**Fig. 3.** (A) Additional enteral stent placed extending from the efferent loop to the stomach. (B) Substantial contrast medium flow into the efferent loop after efferent loop stenting.

ent loop stenting, substantial contrast medium flow into the efferent loop was observed (Fig. 3B). Oral feeds were initiated a day after stent placement, and the patient was subsequently discharged. He died of primary cancer progression 5 months after stent placement, although there were no stent problems.

In recent years, malignant gastrointestinal obstruction of the esophagus, stomach, duodenum, and colon has been widely managed with endoscopic SEMS placement as an effective palliative treatment. However, because there are few studies on the use of metallic stents in the obstruction of a surgically

reconstructed intestine, particularly stenting at the bifurcation of the surgically reconstructed intestine, the safety and efficacy of the procedure have not been elucidated. To the best of our knowledge, only one report exists on SEMS placement at the bifurcation of a surgically reconstructed intestine.<sup>4</sup> Kwong et al.<sup>4</sup> reported a case of concurrent afferent and efferent stents after a pancreaticoduodenectomy. Although their case eventually required three efferent limb stents for recurrent malignant obstruction along with an afferent limb stent, there were no serious complications.

In the present case, the expanded afferent stent compressed the efferent loop, causing efferent loop obstruction. Because an expanded stent may cause intestinal obstruction, endoscopists should be careful while performing enteral stenting at the bifurcation of a surgically reconstructed intestine. Especially, during afferent loop stenting, an additional efferent

loop stent should be considered for the passage of food into the efferent loop.

#### Conflicts of Interest

---

The authors have no financial conflicts of interest.

#### REFERENCES

1. Maetani I, Ogawa S, Hoshi H, et al. Self-expanding metal stents for palliative treatment of malignant biliary and duodenal stenoses. *Endoscopy* 1994;26:701-704.
2. Baron TH. Expandable metal stents for the treatment of cancerous obstruction of the gastrointestinal tract. *N Engl J Med* 2001;344:1681-1687.
3. Ross AS, Semrad C, Waxman I, Dye C. Enteral stent placement by double balloon enteroscopy for palliation of malignant small bowel obstruction. *Gastrointest Endosc* 2006;64:835-837.
4. Kwong WT, Fehmi SM, Lowy AM, Savides TJ. Enteral stenting for gastric outlet obstruction and afferent limb syndrome following pancreaticoduodenectomy. *Ann Gastroenterol* 2014;27:413-417.