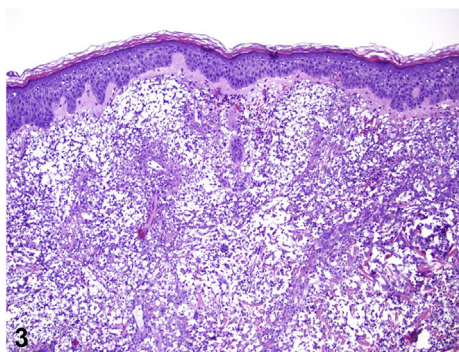
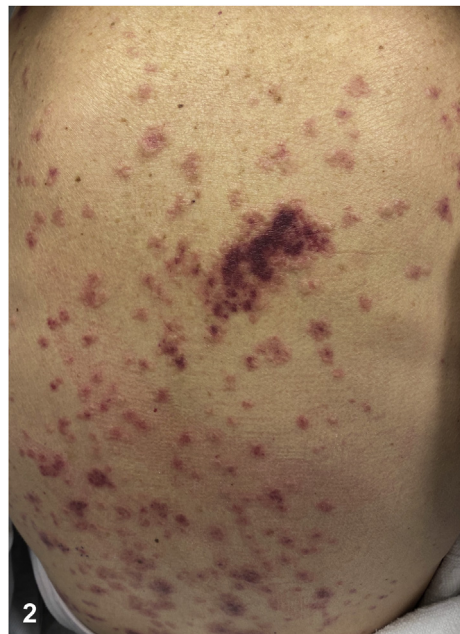
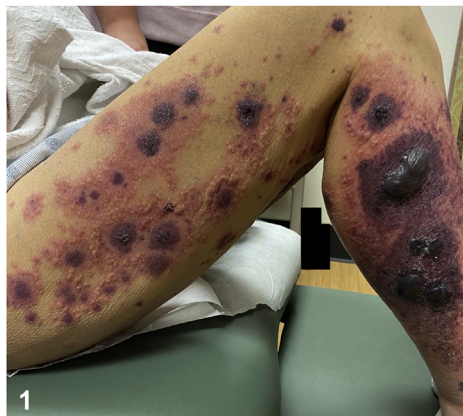
Eruption of hemorrhagic bullae and vesicles



Sabah Osmani, BA,^a Jiasen Wang, MD,^b Hillary Elwood, MD,^b and Therese A. Holguin, MD^b
Albuquerque, New Mexico

Key words: medication side-effects; vasculitis.



A 59-year-old female former smoker with idiopathic nonischemic heart failure presented with a 3-day history of a bullous eruption that rapidly progressed to involve her back, forehead, and ears. She denied illicit drug use, and her vitals were within normal ranges. Examination revealed violaceous plaques with central bullae on the bilateral lower extremities and scattered across the back (Figs 1 and 2). Individual bullae were surrounded by

From the University of New Mexico School of Medicine, Albuquerque^a; University of New Mexico Department of Dermatology, Albuquerque.^b

Funding sources: None.

IRB approval status: Not applicable.

Correspondence to: Sabah Osmani, BA, University of New Mexico School of Medicine, 2425 Camino de Salud, Albuquerque, NM 87106. E-mail: SaOsmani@salud.unm.edu.

JAAD Case Reports 2022;21:80-2.
2352-5126

© 2022 by the American Academy of Dermatology, Inc. Published by Elsevier, Inc. This is an open access article under the CC BY-NC-ND license (<http://creativecommons.org/licenses/by-nc-nd/4.0/>).

<https://doi.org/10.1016/j.jidcr.2021.04.040>

rims of erythema with coalescing vesicles. Red, edematous, urticarial plaques were noted on the forehead. All lesions were exquisitely tender to light palpation. A punch biopsy was obtained (Fig 3) from a peripheral red papule. Direct immunofluorescence (DIF) showed focal perivascular deposition of immunoglobulin M, C3, and fibrin.

Question 1: What is the most likely diagnosis?

- A. Warfarin-induced skin necrosis
- B. Meningococemia
- C. Drug-induced vasculitis
- D. Levamisole-cocaine–induced vasculitis
- E. Cryoglobulinemia

Answers:

A. Warfarin-induced skin necrosis — Incorrect. Warfarin-induced skin necrosis typically occurs during the initial hypercoagulable state following warfarin initiation, especially without concurrent heparin bridge. The histopathology typically demonstrates cutaneous necrosis with intravascular fibrin thrombi in the absence of vascular inflammation.¹

B. Meningococemia — Incorrect. Patients with meningococemia are typically febrile and acutely ill. There is a headache and photophobia. The skin examination reveals a rapidly progressive blanching rash with petechiae and/or ecchymoses, as opposed to the bullous plaques and vesicles seen in this patient with normal vital signs.

C. Drug-induced vasculitis — Correct. By mechanisms not clearly understood, certain drugs can cause a vasculitis that may be associated with various antibodies in the patient's serum. These occur secondary to neutrophil activation and other immunologic events and involve antinuclear antibodies, perinuclear and centrally accentuated antineutrophil cytoplasmic antibodies, antimyeloperoxidase antibodies, and antihistone antibodies.

D. Levamisole-cocaine–induced vasculitis — Incorrect. Levamisole is a substance found in up to 70% of street cocaine. The substance is associated with 3 different clinical syndromes, including cocaine-induced midline destructive lesions, agranulocytosis, and cutaneous vasculitis.² This patient did not have a history of illicit drug use, making this cause of vasculitis less likely.

E. Cryoglobulinemia — Incorrect. Mixed cryoglobulinemia is a type of vasculitis that is found almost exclusively in patients with hepatitis C. It can affect multiple organs, including the skin, where it resembles other forms of vasculitis.

Question 2: Which histologic features are associated with this diagnosis?

A. Robust perivascular and interstitial neutrophilic infiltrate with leukocytoclasia, extravasated erythrocytes, and a well-developed fibrinoid necrosis of vessel walls. The infiltrate may also contain lymphocytes, histiocytes, and/or eosinophilia

B. Cutaneous necrosis with intravascular fibrin deposits without vascular inflammation

C. Acute vasculitis of the dermal vessels with endothelial swelling and fibrin thrombi

D. Epidermal atrophy, vacuolar alteration of the basal layer, superficial and deep perivascular and periadnexal lymphohistiocytic infiltrate, and dermal mucin deposition

E. Mild perivascular lymphocytic infiltrate with scattered neutrophils and slight dermal edema

Answers:

A. Robust perivascular and interstitial neutrophilic infiltrate with leukocytoclasia, extravasated erythrocytes, and a well-developed fibrinoid necrosis of vessel walls. The infiltrate may also contain lymphocytes, histiocytes, and/or eosinophilia — Correct. These are the histologic findings of a leukocytoclastic vasculitis. Leukocytoclastic vasculitis may be due to drug-induced vasculitis, levamisole-induced vasculitis, or other causes. Additionally, it is important to perform DIF whenever autoimmune bullous dermatitis or vasculitis is suspected. Specifically, when diagnosing leukocytoclastic vasculitis, DIF of the lesional skin has been shown to provide a higher positivity compared with DIF of the perilesional skin.³ In this case, DIF showed focal perivascular deposition, which along with the histopathologic findings supports the diagnosis of leukocytoclastic vasculitis.

B. Cutaneous necrosis with intravascular fibrin deposits without vascular inflammation — Incorrect. This is typically seen with warfarin-induced skin necrosis.

C. Acute vasculitis of the dermal vessels with endothelial swelling and fibrin thrombi — Incorrect. These are the histologic findings of skin lesions in meningococemia and other causes of septic vasculitis (ie, infectious).

D. Epidermal atrophy, vacuolar alteration of the basal layer, superficial and deep perivascular and periadnexal lymphohistiocytic infiltrate, and dermal mucin deposition — Incorrect. These features are associated with subacute cutaneous lupus erythematosus.⁴ In addition to drug-induced vasculitis, some medications may also cause drug-induced lupus, although the clinical presentation differs.

E. Mild perivascular lymphocytic infiltrate with scattered neutrophils and slight dermal edema — Incorrect. These are the typical histologic findings of urticaria and are nonspecific. Although the lesions on the patient's forehead resemble urticarial lesions, this is not the underlying diagnosis in this case.

Question 3: On review of medications, the patient was taking hydralazine, carvedilol, lisinopril, spironolactone, warfarin, iron, and aspirin for at least 6 months. Which of these medications was the most likely offender?

- A.** Hydralazine
- B.** Carvedilol
- C.** Lisinopril
- D.** Spironolactone
- E.** Warfarin

Answers:

A. Hydralazine — Correct. Hydralazine is a known cause of antineutrophil cytoplasmic antibody–positive drug-induced vasculitis that typically presents with pulmonary, renal, or skin involvement. Additional culprits of drug-induced vasculitis are propylthiouracil, biologicals (ie, tumor necrosis factor inhibitors), cocaine, montelukast,

statins, and various antibiotics.⁵ Hydralazine can also cause drug-induced lupus syndrome.

B. Carvedilol — Incorrect. β -Blockers are an extremely rare cause of cutaneous vasculitis. Only 1 case of carvedilol-induced vasculitis has been reported.

C. Lisinopril — Incorrect. Angiotensin-converting enzyme inhibitors are an extremely rare cause of cutaneous vasculitis.

D. Spironolactone — Incorrect. Spironolactone has not been reported to be a cause of cutaneous vasculitis.

E. Warfarin — Incorrect. Warfarin use may cause warfarin-induced skin necrosis but does not typically cause vasculitis, as seen in this patient.

Abbreviation used:

DIF: direct immunofluorescence

Conflicts of interest

None disclosed.

REFERENCES

1. Kakagia DD, Papanas N, Karadimas E, Polychronidis A. Warfarin-induced skin necrosis. *Ann Dermatol*. 2014;26(1):96-98. <https://doi.org/10.5021/ad.2014.26.1.96>
2. Sayadi L, Laub D. Levamisole-induced vasculitis. *Eplasty*. 2018;18:ic5.
3. Barnadas MA, Pérez E, Gich I, et al. Diagnostic, prognostic and pathogenic value of the direct immunofluorescence test in cutaneous leukocytoclastic vasculitis. *Int J Dermatol*. 2004;43(1):19-26. <https://doi.org/10.1111/j.1365-4632.2004.01714.x>
4. Solhjoo M, Bansal P, Goyal A, Chauhan K. Drug-induced lupus erythematosus. In: *StatPearls [Internet]*. StatPearls Publishing; 2022. Accessed December 20, 2020. <http://www.ncbi.nlm.nih.gov/books/NBK441889/>
5. Grau RG. Drug-induced vasculitis: new insights and a changing lineup of suspects. *Curr Rheumatol Rep*. 2015;17(12):71. <https://doi.org/10.1007/s11926-015-0545-9>