



Original Article

# Surgical microanatomy of the occipital artery for suboccipital muscle dissection and intracranial artery reconstruction

Yuto Hatano, Nakao Ota, Kosumo Noda, Yasuaki Okada, Yosuke Suzuki, Shusei Fukuyama, Shuichi Tanada, Atsumu Hashimoto, Tomomasa Kondo, Takanori Miyazaki, Yu Kinoshita, Hiroyasu Kamiyama, Sadahisa Tokuda, Rokuya Tanikawa

Department of Neurosurgery, Sapporo Teishinkai Hospital, Higashi-ku, Sapporo, Hokkaido, Japan.

E-mail: Yuto Hatano - hattar.8nomi267@gmail.com; Nakao Ota - nakao1980@gmail.com; Kosumo Noda - kosumo119@gmail.com; Yasuaki Okada - yasu.vio04nagata@gmail.com; Yosuke Suzuki - showtime55555@gmail.com; Shusei Fukuyama - kyokui090208@gmail.com; Shuichi Tanada - tanada0718@gmail.com; Atsumu Hashimoto - hashimoto.acchan19860405@gmail.com; Tomomasa Kondo - tomomasa.kondo@gmail.com; Takanori Miyazaki - t.miyazaki0911@gmail.com; Yu Kinoshita - yu19811129@gmail.com; Hiroyasu Kamiyama - kamiyama1007@gmail.com; Sadahisa Tokuda - s\_tokuda@teishinkai.jp; \*Rokuya Tanikawa - taniroku@gmail.com



\*Corresponding author:

Rokuya Tanikawa,  
Stroke Center, Department  
of Neurosurgery, Sapporo  
Teishinkai Hospital, 3-1,  
Higashi 1, Kita 33, Higashi-ku,  
Sapporo, Hokkaido, Japan.

taniroku@gmail.com

Received : 11 January 19

Accepted : 01 May 19

Published : 28 June 19

DOI

10.25259/SNI-16-2019

Quick Response Code:



## ABSTRACT

**Background:** The occipital artery (OA) is an important donor artery for posterior fossa revascularization. Harvesting the OA is difficult in comparison to the superficial temporal artery because the OA runs between suboccipital muscles. Anatomical knowledge of the suboccipital muscles and OA is essential for harvesting the OA during elevation of the splenius capitis muscle (SPL) for reconstruction of the posterior inferior cerebellar artery. We analyzed the running pattern of the OA and its anatomic variations using preoperative and intraoperative findings.

**Methods:** From April 2012 to March 2018, we surgically treated 162 patients with suboccipital muscle dissection by OA dissection using the lateral suboccipital approach. The running pattern and relationship between the suboccipital muscles and OA were retrospectively analyzed using the operation video and preoperative enhanced computed tomography (CT) images. The anatomic variation in the running pattern of the OA was classified into two types: lateral type, running lateral to the muscle and medial type, running medial to the longissimus capitis muscle (LNG).

**Results:** The medial pattern was observed in 107 (66%) patients and the lateral pattern in 54 (33.3%); 1 (0.6%) patient had the OA running between the LNGs.

**Conclusion:** Preoperative CT is effective in determining the running course of the OA, which is important for safely harvesting the OA during SPL elevation. There is a risk of causing OA injury in patients with the lateral pattern. This is the first report showing that the OA rarely runs in between the LNGs.

**Keywords:** Occipital artery to posterior inferior cerebellar artery bypass, Occipital artery, Suboccipital muscle dissection

## INTRODUCTION

The occipital artery (OA) is often used as an important donor for the reconstruction of the posterior inferior cerebellar artery (PICA) and is rarely available as a donor for the

anterior inferior cerebellar artery and posterior cerebral artery.<sup>[1,4]</sup> Harvesting the OA is not easy in comparison with the superficial temporal artery because the OA runs between the suboccipital muscles. Hence, the anatomical knowledge of the suboccipital muscles and OA is essential for harvesting the OA safely and quickly. Simplifying OA dissection would help surgeons concentrate on the intradural anastomosis and achieve shorter operative times. We believe that preoperatively assessing the practical anatomy of the suboccipital muscles will help surgeons dissect the OA quickly, efficiently, and safely. The present study analyzed the running pattern of the OA and its anatomic variations using intraoperative and preoperative findings.

## MATERIALS AND METHODS

### Patients

This study was approved by the institutional review board at our hospital. Patient consent was not required in this study due to its retrospective nature. From April 2012 to March 2018, we surgically treated 162 patients with suboccipital muscle dissection with OA harvesting for the lateral suboccipital approach. The indications were intracranial aneurysms in 79 patients, microvascular decompression in 35, acoustic tumors in 18, other tumors in 27, and other reasons in 3.

### Analysis of the running pattern of the occipital artery

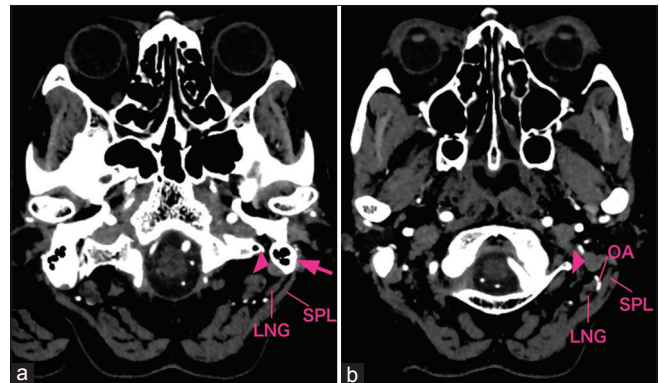
The running pattern and relationship between the suboccipital muscles and OA were retrospectively analyzed using operation videos and preoperative enhanced computed tomography (CT) images by the author and discussed with other neurosurgeons. Head CT was performed using a 320-row CT scanner Aquilion ONE VISION edition (Toshiba Medical Systems, Tochigi, Japan). All scans were analyzed in their original format with a 0.5 mm slice thickness scaled to Level 60/Window 200.

The longissimus capitis muscle (LNG) is inserted posterior to the margin of the mastoid process. It is easy to identify the insertion and follow the running course of the LNG using thin-slice CT by changing the window width and level. The other muscles that enter the mastoid process, such as the posterior belly of the digastric muscle and the splenius capitis muscle (SPL), can be distinguished by their insertion and running course [Figure 1]. The running patterns of the OA were classified into two types: lateral type, running lateral to the LNG and medial type, running medial to the LNG.

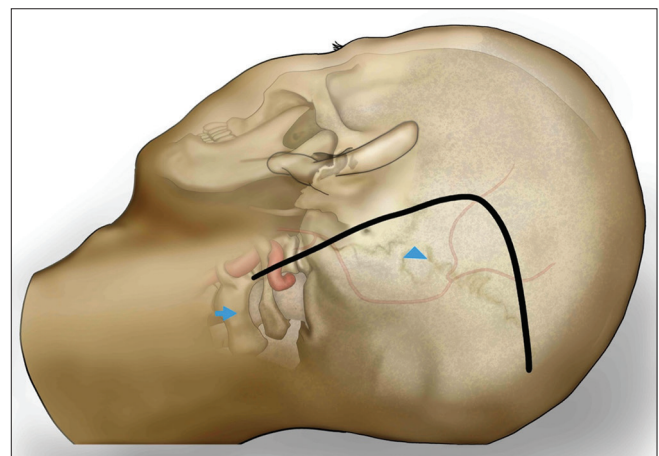
### Surgical technique

The patient was placed in the park-bench position. The head was fixed and flexed to avoid venous congestion and rotated to the side opposite to the site of the lesion using

the stretching neck-shoulder angle, in which the ipsilateral mastoid body could be placed at the highest point for surgery.<sup>[2,3,5-7]</sup> An L-shaped skin incision was made from near the midline, 1 cm above the superior nuchal line (SNL), and the apex on the asterion, to near the C2 [Figure 2]. The lateral skin incision was extended to the tip of the mastoid process. The subcutaneous part of the OA was found at 1 cm–5 cm from the midline along the horizontal skin incision, as it crosses the incision. The scalp flap was then reflected inferiorly. As a result, the sternocleidomastoid muscle (SCM) and SPL were exposed first, and then, the OA was localized in all three muscles, which included the SCM, SPL, and SNL. The tendon of the SCM was detached from the occipital bone and retracted laterally to expose the attachment of the SPL. The SPL was detached and retracted inferomedially to reveal the OA. Here, the belly of the SPL was carefully dissected to preserve a significant amount of protective fatty tissue. The OA was followed proximally to the inferior edge of the



**Figure 1:** Enhanced computed tomography images of the suboccipital anatomy (left side). (a) Mastoid process (arrow); arrowhead: posterior belly of the digastric muscle. (b) The lateral running pattern showing an OA running lateral to the LNG. SPL: Splenius capitis muscle; LNG: Longissimus capitis muscle.



**Figure 2:** Incision for the lateral suboccipital approach (left side). Arrowhead: asterion, arrow: C2.

**Table 1:** Clinical profiles.

| Characteristic    | n   | %    |
|-------------------|-----|------|
| Male              | 74  | 45.7 |
| Female            | 88  | 54.3 |
| Medial pattern    | 107 | 66.1 |
| Lateral pattern   | 54  | 33.3 |
| Penetrate pattern | 1   | 0.6  |

posterior belly of the digastric muscle.<sup>[2,3,5-7]</sup> The anatomic variations of the running pattern of the OA were identified around the LNG. The running pattern of the OA was classified into two types, running lateral or medial to the LNG. The LNG was also detached from the mastoid process and retracted inferomedially. The OA was then dissected from the surrounding tissue, and after achieving sufficient dissection, the semispinalis capitis muscle was detached and retracted medially. When exposure of the suboccipital triangle is necessary, the superior oblique capitis muscle can be dissected and reflected inferolaterally. The V3 segment is exposed in the suboccipital triangle, and the vertebral venous plexus is treated without inducing bleeding.<sup>[7]</sup> Finally, the rectus capitis posterior major and minor muscles were detached and retracted medially, and craniotomy could be performed. The full length of the dissected OA was retracted anteriorly from the scalp incision, and the integrity of the donor OA was kept intact until the recipient artery was completely prepared.

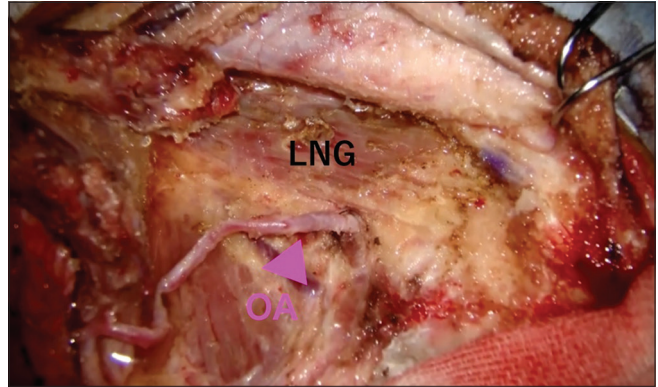
**RESULTS**

The mean age of the 162 patients included in this study was 57 years, with 88 women and 74 men [Table 1]. In terms of the running pattern of the OA, the medial pattern was observed in 107 patients (66.1%) [Figure 3] and the lateral pattern in 54 (33.3%) [Figure 4]. One patient (0.6%) had an OA running between the LNG [Figure 5]. There were no differences between the intraoperative and preoperative CT findings.

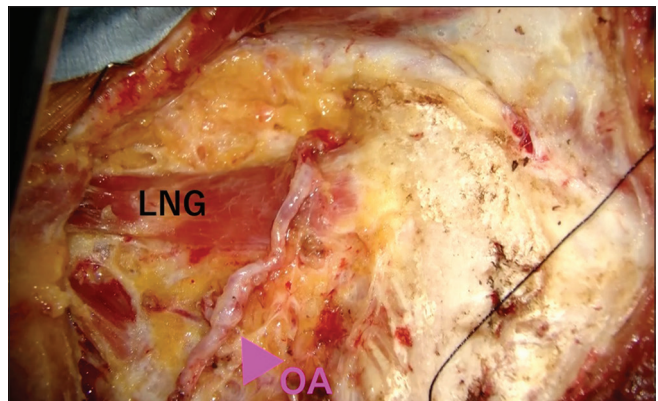
**DISCUSSION**

The present study showed that the running pattern of OA can be classified into two types, namely running lateral or medial to the LNG. The medial pattern was observed in approximately 2/3 patients and the lateral pattern in 1/3. Only one patient exhibited an OA running between the LNGs. LNG has been rarely reported to have a superficial and deep insertion since it has multiple muscle bellies (Lang, 1979). This study is the first report that shows the OA running in between the LNGs.

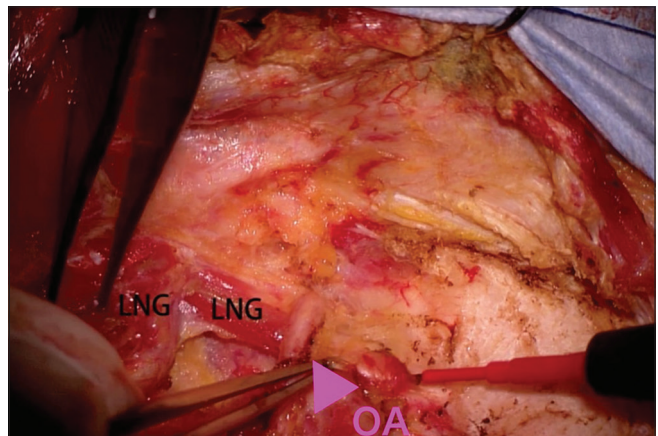
The OA has been widely used as a donor artery for posterior fossa extracranial-intracranial bypass surgery, especially for OA-PICA anastomosis,<sup>[6,8]</sup> which is an important approach



**Figure 3:** Medial pattern (left side). LNG: Longissimus capitis muscle, OA: Occipital artery.



**Figure 4:** Lateral pattern (left side). LNG: Longissimus capitis muscle, OA: Occipital artery.



**Figure 5:** The LNG has a superficial and deep insertion and the OA runs between the muscles. LNG: Longissimus capitis muscle, OA: Occipital artery.

in the treatment of complicated aneurysms or brain tumors involving the vertebral artery or the PICA when the parent artery must be sacrificed. Failure of the bypass could lead to catastrophic ischemia of the cerebellum and brainstem.<sup>[8]</sup> The

OA-PICA anastomosis is considered to be more challenging than superficial temporal artery-middle cerebral artery bypass due to the narrow and deep surgical corridor that must be navigated to reach the recipient vessels.<sup>[9]</sup> Further, the OA runs between multiple muscle layers, and harvesting it is more difficult than harvesting the superficial temporal artery, which runs in a single epigaleal layer.

Anatomic variations in the running pattern of the OA were identified around the LNG. SPL elevation is associated with the risk of OA injury in case of the lateral pattern because the tendon of the SPL can be easily confused with the LNG due to their close proximity. The running pattern of OA can be recognized through preoperative enhanced CT images and there were no differences between the intraoperative and preoperative CT findings in this study. Preoperative CT angiography showing the course of the OA superimposed onto the patient's scalp anatomy can be especially helpful.

The surgical technique used in this study was a widely accepted one. Hence, advancements in this procedure have clinical implications for harvesting the OA. Performing the layer-by-layer muscle dissection can make the operative field wider and shallower in contrast to that achieved in the direct transmuscular approach; thus, making it easy to perform microsurgical anastomosis. In addition, muscle atrophy is less frequent because the muscle belly is not injured. Hence, suboccipital muscle dissection is routinely performed for suboccipital lesions.

The limitations of this study are that it is a retrospective evaluation and includes the unblinded review of the preoperative CT images and intraoperative videos. The frequency of superficial or deep insertion of the LNG is unknown because we could not recognize it during the operation; therefore, we proceeded to detach and confirm the LNG in all operations. Moreover, in this study, only one patient had an OA penetrating through the LNG.

## CONCLUSION

Anatomical knowledge of the suboccipital muscles and OA is essential for harvesting the OA as the bypass donor. It is important to understand the variations in the running pattern of the OA and the relationship between suboccipital muscles. In this regard, the present study revealed the effectiveness of preoperative CT imaging to determine the running course of the OA. The findings of this paper can be used as a reference to preoperatively determine the running pattern of the OA to perform the harvest procedure safely and with minimal complications.

## Financial support and sponsorship

Nil.

## Conflicts of interest

There are no conflicts of interest.

## REFERENCES

1. Czabanka M, Ali M, Schmiedek P, Vajkoczy P, Lawton MT. Vertebral artery-posterior inferior cerebellar artery bypass using a radial artery graft for hemorrhagic dissecting vertebral artery aneurysms: Surgical technique and report of 2 cases. *J Neurosurg* 2011;114:1074-9.
2. Fukuda H, Evins AI, Burrell JC, Stieg PE, Bernardo A. A safe and effective technique for harvesting the occipital artery for posterior fossa bypass surgery: A cadaveric study. *World Neurosurg* 2014;82:e459-65.
3. Kawashima M, Rhoton AL Jr, Tanriover N, Ulm AJ, Yasuda A, Fujii K, *et al.* Microsurgical anatomy of cerebral revascularization. Part II: Posterior circulation. *J Neurosurg* 2005; 102:132-47.
4. Khodadad G. Short-and long-term results of microvascular anastomosis in the vertebrobasilar system, a critical analysis. *Neurol Res* 1981;3:33-65.
5. Kubota H, Tanikawa R, Katsuno M, Izumi N, Noda K, Ota N, *et al.* Vertebral artery-to-vertebral artery bypass with interposed radial artery or occipital artery grafts: Surgical technique and report of three cases. *World Neurosurg* 2014; 81:202. e1-8.
6. Ota N, Goehre F, Miyazaki T, Kinoshita Y, Matsukawa H, Yanagisawa T, *et al.* Bypass revascularization applied to the posterior cerebral artery. *World Neurosurg* 2016;96:460-72.
7. Ota N, Tanikawa R, Miyama M, Miyazaki T, Kinoshita Y, Matsukawa H, *et al.* A contralateral transcondylar fossa approach with bilateral V3 segment exposure for repairing complex vertebral artery aneurysms. *World Neurosurg* 2017; 99:340-7.
8. Ota N, Tanikawa R, Yoshikane T, Miyama M, Miyazaki T, Kinoshita Y, *et al.* Surgical microanatomy of the posterior condylar emissary vein and its anatomical variations for the transcondylar fossa approach. *Oper Neurosurg (Hagerstown)* 2017;13:382-91.
9. Tanikawa R, Sugimura T, Seki T, Izumi N, Noda K, Hashimoto M, *et al.* Basic surgical techniques and pitfalls in vascular reconstruction in the posterior fossa: Surgical anatomy for oa-pica anastomosis. *Jpn J Neurosurg* 2008;17:587-95.

**How to cite this article:** Hatano Y, Ota N, Noda K, Okada Y, Suzuki Y, Fukuyama S, *et al.* Surgical microanatomy of the occipital artery for suboccipital muscle dissection and intracranial artery reconstruction. *Surg Neurol Int* 2019;10:127.