





Erratum

Erratum to “Platelet-Rich Fibrin Promotes Periodontal Regeneration and Enhances Alveolar Bone Augmentation”

Qi Li,^{1,2} Shuang Pan ,³ Smit J. Dangaria,¹ Gokul Gopinathan ,¹ Antonia Kolokythas,⁴ Shunli Chu,² Yajun Geng,⁵ Yanmin Zhou ,² and Xianghong Luan ¹

¹UIC Brodie Laboratory for Craniofacial Genetics, 801 South Paulina, Chicago, IL 60612, USA

²Department of Implantology, Stomatological Hospital, Jilin University, Changchun, Jilin 130021, China

³Department of Endodontics, School of Dentistry, Harbin Medical University, Harbin, China

⁴Department of Oral and Maxillofacial Surgery, UIC College of Dentistry, Chicago, IL, USA

⁵The First Hospital of Jilin University, Jilin, China

Correspondence should be addressed to Yanmin Zhou; zhouym1962@126.com and Xianghong Luan; luan@tamhsc.edu

Received 20 March 2019; Accepted 28 March 2019; Published 1 April 2020

Copyright © 2020 Qi Li et al. This is an open access article distributed under the Creative Commons Attribution License, which permits unrestricted use, distribution, and reproduction in any medium, provided the original work is properly cited.

In the article titled “Platelet-Rich Fibrin Promotes Periodontal Regeneration and Enhances Alveolar Bone Augmentation” [1], in Figure 7(a), the distance between the implant margin and the alveolar socket was incorrectly referred to as 2.5 cm. It should be corrected to 2.5 mm as mentioned in figure’s description. The corrected figure is shown below.

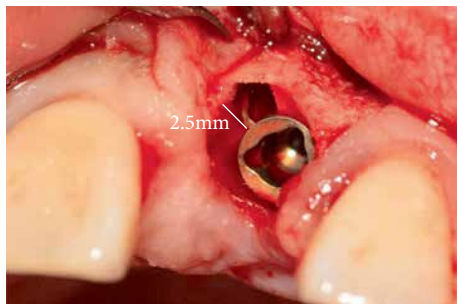


FIGURE 7: Case I: (a) reveals a 2.5 mm gap at the mesial aspect of the implant replacing the upper left incisor.

References

- [1] Q. Li, S. Pan, S. J. Dangaria et al., “Platelet-rich fibrin promotes periodontal regeneration and enhances alveolar bone augmentation,” *BioMed Research International*, vol. 2013, Article ID 638043, 13 pages, 2013.