

Laparoscopic Guidance or Revision of Ventriculoperitoneal Shunts in Children

Sherman Yu, MD, Denis D. Bensard, MD, David A. Partrick, MD, John K. Petty, MD, Frederick M. Karrer, MD, Richard J. Hendrickson, MD

ABSTRACT

Background: Ventriculoperitoneal shunt is the preferred treatment for hydrocephalus. Known complications include infection, obstruction, and disconnection with the fractured fragment migrating in the peritoneal cavity. We report 17 cases of laparoscopic evaluation and revision of ventriculoperitoneal shunts in children.

Methods: From January 2000 through October 2002, we retrospectively reviewed our experience with laparoscopy and ventriculoperitoneal shunts.

Results: Laparoscopy was performed in 17 children with a malfunctioning shunt, presumed shunt dislodgment or disconnection, reinsertion of a shunt after externalization, and primary shunt placement. Six patients (35%) were converted to an open laparotomy due to dense adhesions. Eleven patients (65%) underwent successful laparoscopic-assisted ventriculoperitoneal shunt placement: 5/11 (45%) had lysis of adhesions or pseudocyst marsupialization with repositioning of a functional shunt, or both; 3/11 (27%) had successful retrieval of a disconnected catheter with reinsertion of a new catheter; 2/11 (18%) had laparoscopic confirmation of satisfactory placement and function, requiring no revision; 1/11 (9%) had an initial shunt placed with laparoscopic guidance due to the obesity. Operative time for the laparoscopic procedure ranged from 30 minutes to 60 minutes. All laparoscopic procedures used 1-mm or two 5-mm ports. Perioperatively, no adverse neurological sequelae occurred due to the pneumoperitoneum.

Conclusions: Laparoscopic guidance or revision of ventriculoperitoneal shunts permits (1) direct visualization of catheter insertion within the peritoneal cavity, (2) satisfactory positioning, (3) lysis of adhesions or marsupialization

with catheter repositioning, or both, and (4) retrieval of fractured catheters.

Key Words: Laparoscopy, Ventriculoperitoneal shunt, Children, Hydrocephalus.

INTRODUCTION

Ventriculoperitoneal (VP) shunt is the preferred treatment for hydrocephalus. VP shunt malfunction causing elevated intracranial pressure may be due to obstruction or catheter fracture, which requires surgical intervention. The obstruction may be proximal (pump failure), or distal within the peritoneum due to adhesions, cerebrospinal fluid (CSF) pseudocysts, or catheter fracture.¹ Distal shunt malfunctions are responsible for 25% to 30% of shunt failures.²

When distal obstruction or a catheter fracture is diagnosed, an initial laparoscopic approach may be diagnostic and therapeutic, avoiding the morbidity of a formal laparotomy.³⁻⁷ Laparoscopy permits diagnostic evaluation of the peritoneum, visualization of a patent and functional catheter, and identification and retrieval of a fragmented catheter.^{8,9}

VP shunt infection may require shunt externalization until the peritoneal infection has been eradicated. Reinsertion of the VP shunt using laparoscopy permits diagnostic evaluation, lysis of adhesions as indicated, and safe placement of the VP shunt within a satisfactory peritoneal location.

We report our experience with laparoscopic assistance during VP shunt revision or insertion within the peritoneum.

METHODS

From January 2000 through October 2002, a retrospective analysis was performed on the use of laparoscopy and VP shunt surgeries in children and adolescents. Perioperative antibiotics are routinely given before incision. With the patient under general anesthesia, an infraumbilical 5-mm STEP port (Tyco Healthcare, Norwalk, CT) is placed by

From the Division of Pediatric Surgery, The Children's Hospital/The University of Colorado Health Science Center, Denver, Colorado, USA (all authors).

Presented at the 13th International Congress and Endo Expo 2004, SLS Annual Meeting, New York, New York, USA, September 30, 2004.

Address reprint requests to: Richard J. Hendrickson, MD, The Children's Hospital, 1056 East 19th Ave, B323, Denver, CO 80218, USA. Telephone: 303 861 6530, Fax: 303 764 8077, E-mail: Hendrickson.Richard@tchden.org

© 2006 by JLS, *Journal of the Society of Laparoendoscopic Surgeons*. Published by the Society of Laparoendoscopic Surgeons, Inc.

using the Hasson technique. Using carbon dioxide (CO₂), a pneumoperitoneum of 10 mm Hg is achieved and a 5-mm 30-degree scope is advanced through the STEP port into the peritoneum. With regards to the pneumoperitoneum, we do not routinely clamp the VP shunt, relying on the functioning 1-way valve in the VP shunt circuit instead.

A second 5-mm STEP port is placed under direct visualization, either in the right or left mid abdominal wall. The second port is used as a working port for catheter retrieval, catheter positioning or repositioning, lysis of adhesions, or fenestration of CSF pseudocysts.

Laparoscopic lysis of adhesions and fenestration of CSF pseudocysts is performed using electrocautery or sharp dissection using laparoscopic scissors, or both, and the Maryland dissector. Repositioning of a functional catheter is performed using a laparoscopic Maryland dissector. Placement of the distal VP shunt is performed by making a small stab incision under the costal margin and inserting a sharp groove director into the peritoneum under direct visualization. The VP shunt is then advanced into the peritoneum via the groove director and optimal positioning is achieved using a laparoscopic Maryland dissector. Documentation of a functional catheter is achieved by viewing CSF dripping out of the catheter tip. In cases of suspected VP shunt infection, peritoneal fluid is aspirated via the 5-mm working port and sent for culture.

This study was reviewed and approved by the Colorado Multiple Institutional Review Board (COMIRB #04–0768).

RESULTS

Laparoscopy was performed in 17 patients. Age range was 9 months to 19 years. Indications for laparoscopic assistance were malfunctioning shunt, presumed shunt dislodgment or fracture, reinsertion after externalization, and primary shunt placement in obese patients or patients with multiple previous abdominal surgeries.

Six patients (35%) were converted to a laparotomy. Five of these patients had extensive adhesiolysis not amenable to a safe laparoscopic approach. One patient was converted to a ventriculopleural shunt due to an inability to achieve adequate surface area after adhesiolysis.

Eleven patients (65%) had successful laparoscopic-assisted VP shunt placement. Five (45%) patients had adhesiolysis with repositioning of a functional VP shunt (**Figure 1**). Three (27%) patients had retrieval of a fractured catheter and reinsertion of a new VP shunt (**Figure 2**).

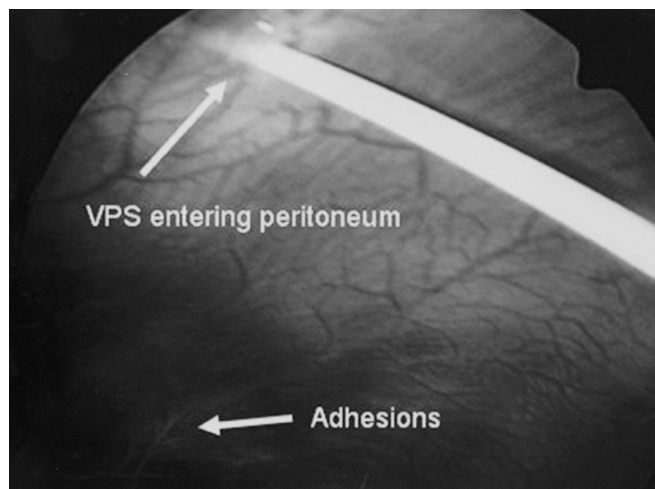


Figure 1. Intraoperative photo illustrating a ventriculoperitoneal shunt catheter entering the anterior abdominal wall after adhesiolysis.

Two (18%) patients had laparoscopic confirmation of a functioning catheter in a satisfactory position, requiring no revision (**Figure 3**). One (9%) patient had the initial VP shunt inserted with laparoscopic assistance due to obesity.

Operative time for laparoscopy ranged from 30 minutes to 60 minutes and was performed concurrently with the neurosurgery team. No peritoneal complications during laparoscopy occurred, and blood loss was minimal. Perioperatively, no adverse neurologic sequelae occurred due to the pneumoperitoneum.

DISCUSSION

Over a 2-year period, an initial laparoscopic approach was performed in 17 patients with a VP shunt malfunction requiring surgical intervention. We were able to safely and effectively perform laparoscopic VP shunt placement in 65% of the cases, offering these patients the advantages of laparoscopy over laparotomy.

In 1 patient, the laparoscopic approach was used for the initial placement of the VP shunt because of the patient's obesity. The remaining cases were all reoperative, accounting for the 35% conversion rate from dense adhesions. Because the average patient with hydrocephalus undergoes 2.1 shunt revisions every 3 years, the more minimally invasive approach is preferable.¹⁰

An initial laparoscopic approach is advocated when a distal obstruction is due to adhesions or pseudocysts.^{3–7} Laparoscopic adhesiolysis or pseudocyst marsupialization can be performed safely in most cases by using electro-

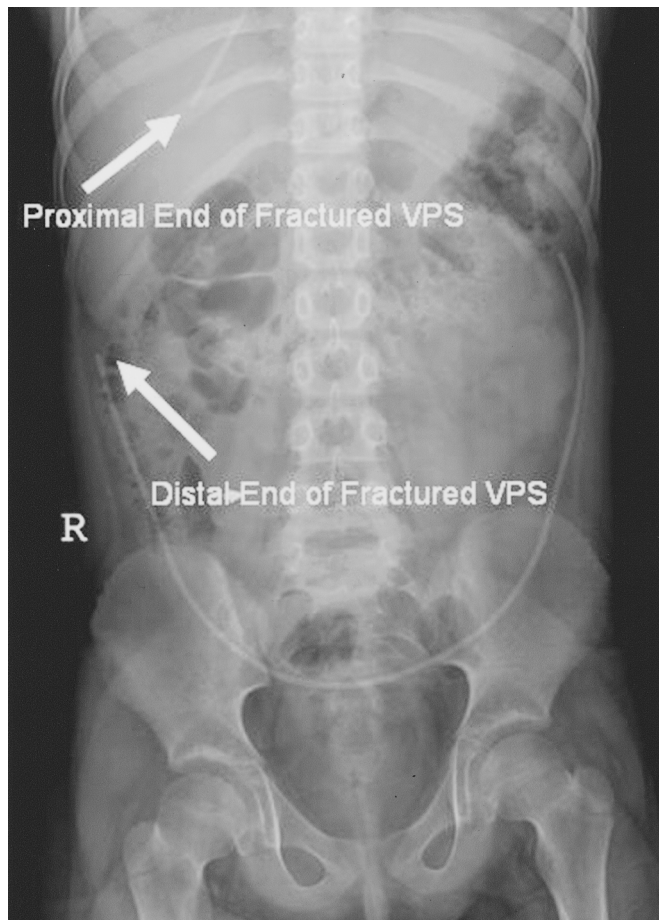


Figure 2. Abdominal radiograph demonstrating a ventriculoperitoneal shunt fracture with migration of the proximal catheter out of the peritoneum.

cautery, sharp dissection, or both. Although an initial laparoscopic approach was attempted in all cases, 6 patients demonstrated dense adhesions not amenable to safe laparoscopic adhesiolysis.

When distal VP shunts disconnect or fracture, their location within the peritoneum can be varied. Laparoscopic retrieval and replacement of the VP shunt can easily be performed.^{8,9} Placement of the working 5-mm port in either the right or left mid abdominal wall is opposite to the planned side of the new catheter. This allows optimal use of this working port for catheter retrieval, repositioning, or initial positioning.

Moreover, a proximal cause of a nonfunctioning catheter can be evaluated laparoscopically. In 2 cases, we were able to laparoscopically observe proper functioning of the shunt within the peritoneum, requiring no further revision of the intraabdominal portion of the catheter.

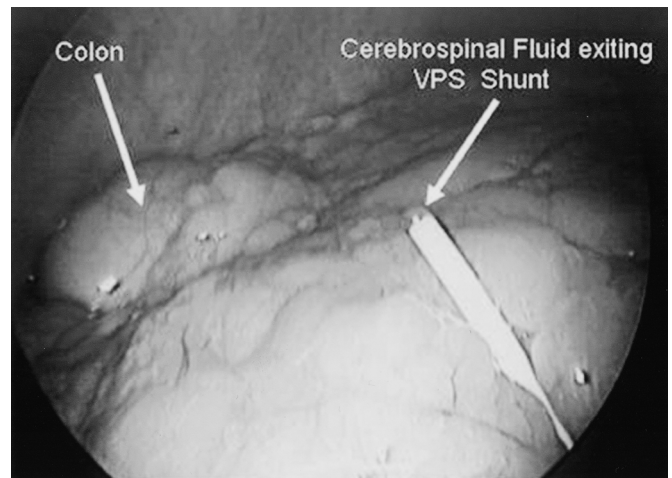


Figure 3. Intraoperative photo demonstrating a functional ventriculoperitoneal shunt catheter with cerebrospinal fluid exiting the catheter, requiring no revision.

During pneumoperitoneum, a theoretical risk exists of pressure transmission into the central nervous system. We do not routinely clamp the VP shunt and rely solely on the 1-way valve. No neurologic sequelae have occurred when this technique has been used. Visualization of CSF dripping out of the functioning shunt confirms that the intracranial pressure exceeds our pneumoperitoneum. A pneumoperitoneum of 10 mm Hg using CO₂ appears to be safe and effective for laparoscopic procedures in these patients with VP shunts.

CONCLUSION

An initial laparoscopic approach for VP shunt malfunctions requiring surgery is advocated. If the adhesions are too dense or laparoscopic adhesiolysis cannot be safely performed, then conversion to a formal laparotomy is warranted.

Laparoscopic guidance or revision of VP shunts permits direct visualization and positioning of the catheter within the peritoneum, allowing for optimal functioning. In addition, minimally invasive adhesiolysis, marsupialization of pseudocysts, and retrieval of fractured catheters can be performed safely and without the morbidity associated with a laparotomy. And given that children with VP shunts undergo frequent revisions, laparoscopy appears preferable to laparotomy. Moreover, no adverse neurologic sequelae occurred perioperatively due to the pneumoperitoneum.

References:

1. Rolle U, Grafe G, Brock D, Grosser K. Laparoscopy-assisted abdominal shunt revisions in children with hydrocephalus. *Eur J Pediatr Surg.* 1998;8(suppl 1):60.
2. Khosrovi H, Kaufman HH, Hrabovsky E, Bloomfield SM, Prabhu V, el-Kadi HA. Laparoscopic-assisted distal ventriculoperitoneal shunt placement. *Surg Neurol.* 1998;49(2):127–134.
3. Acharya R, Ramachandran CS, Singh S. Laparoscopic management of abdominal complications in ventriculoperitoneal shunt surgery. *J Laparoendosc Adv Surg Tech A.* 2001;11(3):167–170.
4. Oh A, Wildbrett P, Golub R, Yu LM, Goodrich J, Lee T. Laparoscopic repositioning of a ventriculo-peritoneal catheter tip for a sterile abdominal cerebrospinal fluid (CSF) pseudocyst. *Surg Endosc.* 2001;15(5):518.
5. Reardon RR, Scarborough TK, Matthews BD, Marti JL, Preciado A. Laparoscopically assisted ventriculoperitoneal shunt placement using 2-mm instrumentation. *Surg Endosc.* 2000;14(6):585–586.
6. Roth JS, Park AE, Gewitz R. Minilaparoscopically assisted placement of ventriculoperitoneal shunts. *Surg Endosc.* 2000;14(5):461–463.
7. Khaitan L, Brennan EJ Jr. A laparoscopic approach to ventriculoperitoneal shunt placement in adults. *Surg Endosc.* 1999;13(10):1007–1009.
8. Pierangeli E, Pizzoni C, Lospalluti A, Gigante N, Colamaria A. Laparoscopic removal of two dislocated ventriculoperitoneal catheters: case report. *Minim Invasive Neurosurg.* 1999;42(2):86–88.
9. Deisnberger W, Langhans M, Winking M, Boker DK. Retrieval of a disconnected ventriculoperitoneal shunt catheter by laparoscopy in a newborn child: case report. *Minim Invasive Neurosurg.* 1995;38(3):123–124.
10. Raimondi AJ. Hydrocephalus. In: Raimondi AJ, ed. *Pediatric Neurosurgery: Theoretical Principles Art of Surgical Techniques.* New York, NY: Springer-Verlag; 1987;453–491.