

Received: 2019.12.17

Accepted: 2020.02.27

Available online: 2020.04.20

Published: 2020.05.24

# Successful Outcome Following Intravenous Lipid Emulsion Rescue Therapy in a Patient with Cardiac Arrest Due to Amitriptyline Overdose

## Authors' Contribution:

Study Design A  
Data Collection B  
Statistical Analysis C  
Data Interpretation D  
Manuscript Preparation E  
Literature Search F  
Funds Collection G

ABCDEF 1 **Ana María Angel-Isaza**  
ABCDEF 1,2 **Luis Alfonso Bustamante-Cristancho**  
EF 3 **Francisco L. Uribe-B**

1 Emergency Department, Fundación Valle del Lili, Santiago de Cali, Colombia  
2 Intensive Care Unit, Fundación Valle del Lili, Santiago de Cali, Colombia  
3 Clinical Research Center (Centro de Investigaciones Clínicas), Fundación Valle del Lili, Santiago de Cali, Colombia

**Corresponding Author:** Ana María Angel-Isaza, e-mail: [ana.angel@fvl.org.co](mailto:ana.angel@fvl.org.co), [anaangelmd@hotmail.com](mailto:anaangelmd@hotmail.com)

**Conflict of interest:** None declared

**Patient:** Female, 28-year-old  
**Final Diagnosis:** Amitriptyline poisoning  
**Symptoms:** Cardiac arrest • hypotension • seizures  
**Medication:** —  
**Clinical Procedure:** Lipid emulsion  
**Specialty:** Toxicology

**Objective:** Management of emergency care


**Background:** The management of patients with tricyclic antidepressant drug overdose can be a challenge for the emergency department physician. Tricyclic antidepressants block alpha-adrenergic receptors and the anticholinergic effects may lead to cardiotoxicity, resulting in arrhythmias and hypotension that can lead to patient mortality. This report is of a case of a 28-year-old woman who presented with cardiac arrest due to amitriptyline overdose and who responded to intravenous lipid emulsion (ILE) therapy.

**Case Report:** A 28-year-old woman was admitted to the emergency department with amitriptyline overdose. She suffered a cardiac arrest followed by cardiovascular and neurological complications. Hypotension and lack of a pulse did not respond to treatment with high-dose sodium, but she stabilized following treatment with ILE. The prompt response from the emergency team guaranteed rapid intervention that may have influenced the successful results.

**Conclusions:** Despite the frequency and severity of poisoning with tricyclic antidepressants, there is little consensus among physicians regarding patient management. This case showed the successful use of ILE as rescue therapy in a patient in cardiac arrest following amitriptyline overdose. However, the successful outcome obtained in this case is not a recommendation for the use of ILE as a first-line treatment for the management of patients with tricyclic antidepressant drug overdose. Controlled clinical studies are required to evaluate the safety and efficacy of ILE in the management of tricyclic antidepressant drug overdose.


**MeSH Keywords:** Antidepressive Agents • Arrhythmias, Cardiac • Drug Overdose • Fat Emulsions, Intravenous

**Full-text PDF:** <https://www.amjcaserep.com/abstract/index/idArt/922206>

 1540

 1

 2

 27



## Background

The management of patients with tricyclic antidepressant drug overdose can be a challenge for the emergency department physician. Tricyclic antidepressants block alpha-adrenergic receptors, and the anticholinergic effects may lead to cardiotoxicity, resulting in arrhythmias and hypotension, which can be fatal [1]. Neurological manifestations are also common and include convulsions and coma [1].

The use of intravenous lipid emulsion (ILE) therapy has recently emerged as rescue therapy for the treatment of lipophilic drug toxicities [2]. The main indications for the use of ILE are cardiac arrest or shock that are refractory to conventional treatments following toxicity from highly liposoluble drugs, including tricyclic antidepressants [3].

In 2018, Giwa et al. reported a case of severe toxicity due to tricyclic antidepressant overdose in a patient who presented with hypotension, seizures, ventricular arrhythmias, and cardiac arrest [4]. In this previously reported case, sodium bicarbonate, magnesium, and norepinephrine were used to treat cardiotoxicity associated with tricyclic antidepressant overdose, but ILE was not used to treat recurrent arrhythmias and cardiac arrest [4]. Engels et al. reported the use of a three-hour ILE infusion with a high dose of vasopressor infusion that were administered following hospital admission and admission to the intensive care unit [5]. Another case of tricyclic antidepressant overdose reported by Sabah et al. described the administration of ILE after 24 hours following hospital admission in a patient who did not completely regain consciousness [6]. Other authors have described cases involving multidrug overdose, including amitriptyline toxicity, which were treated successfully with ILE [7,8]. Tricyclic antidepressant toxicity presents with several classical signs and symptoms, and there are several therapeutic options available. This report is of a case of a 28-year-old woman who presented with cardiac arrest due to amitriptyline overdose and who responded to ILE rescue therapy.

## Case Report

A 28-year-old woman weighing 60 kg, with a past medical history of depression, was admitted to the emergency department with seizures following an intentional overdose of 3.7 gm of amitriptyline. She had last been seen at 09:30 hours and was found in a comatose state at 11:00 hours by her husband. The exact time of the ingestion of amitriptyline was unknown. The seizures were initially treated successfully with diazepam, and she was intubated for airway protection.

The patient developed cardiac arrest with no detectable pulse or cardiac electrical activity and received advanced

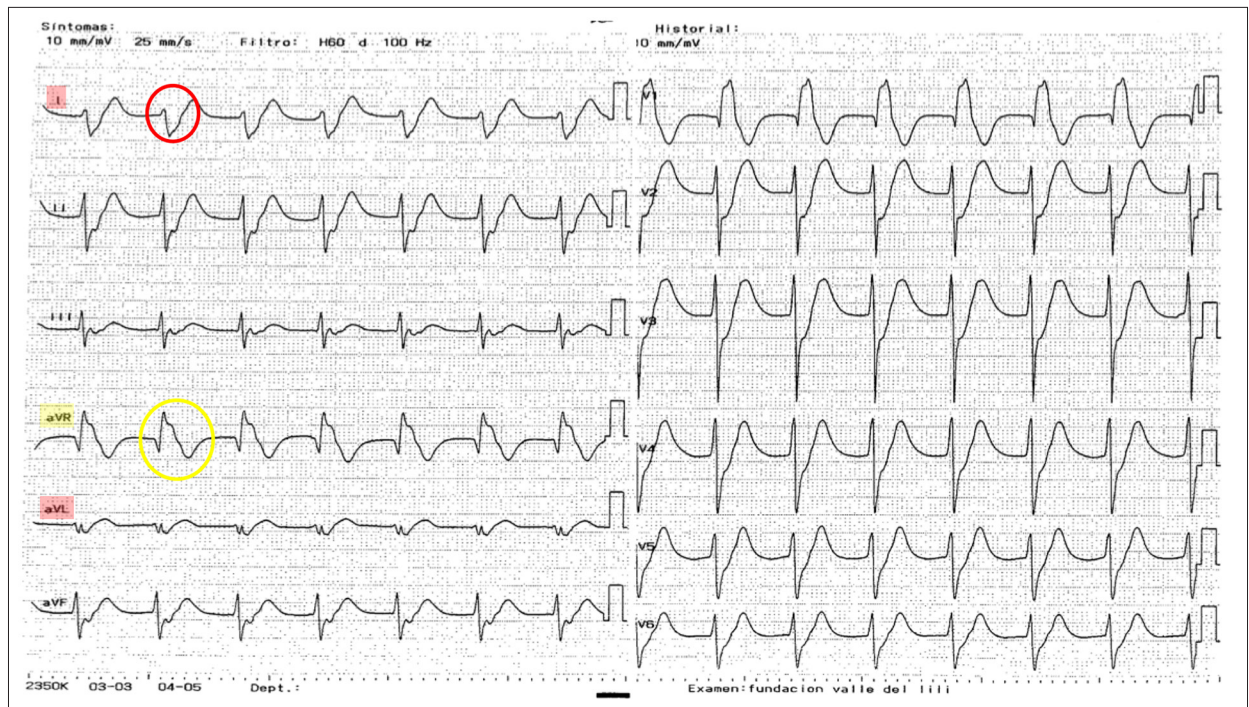
**Table 1.** Laboratory findings in a 28-year-old woman with amitriptyline overdose\*.

Date	03.08.18	03.08.18	04.08.18
Time	13: 33 hrs	17: 46 hrs	5: 30 hrs
pH	7.356	7.399	7.409
PCO <sub>2</sub> (mmHg)	31.2	33.8	35
PO <sub>2</sub> (mmHg)	78.4	84	160
HCO <sub>3</sub> (mmol/L)	17	20.4	21.6
BE (mmol/L)	-7.2	-3.7	-2.4
SO <sub>2</sub> (%)	96	98	99
Lactate (mmol/l)	2.6		1.8
Leukogram (×10 <sup>3</sup> u/L)	15.55		18.78
Neutrophils (%)	95		92
Lymphocytes (%)	2.2		3.5
Hemoglobin (g/dL)	15.6		13.2
Hematocrit (%)	40.7		38.8
Platelets (×10 <sup>3</sup> /uL)	390		234
Sodium (mmol/l)	145		147
Potassium (mmol/l)	3.6		3.9
Creatinine (mg/dL)	0.71		0.97
Urea nitrogen (mg/dL)	–		9.10
Alanine transaminase (ALT) (U/L)	198		162
Aspartate aminotransferase (AST) (U/L)	235		210
Alkaline phosphatase (U/L)	57.9		–
Total bilirubin (mg/dL)	0.34		0.30

\* Laboratory data when the patient arrived at the emergency department, and a day after her hospital admission.

The data shows metabolic acidosis with hyperlactatemia, increased transaminase levels, hemoconcentration, and leukocytosis, but with adequate renal function and normal electrolyte concentrations.

cardiopulmonary resuscitation for 5 minutes until the return of spontaneous circulation. She remained comatose with generalized myoclonic movements, a blood pressure of 111/53 mmHg, heart rate of 103 beats/min, respiratory rate of 25 per minute with a Kussmaul breathing, a core temperature of 36°C, blood glucose of 137 mg/dl, and a normal arterial blood oxygen



**Figure 1.** The electrocardiogram (ECG) features in a 28-year-old woman with amitriptyline overdose. The electrocardiogram (ECG), amplitude 1 mV and speed 25 mm/sec. Red shows leads I and aVL, and yellow shows aVR. The QRS duration is >100 msec. Right axis deviation with negative QRS complexes in leads I and aVL are shown in the red circle. The R-wave amplitude is >3 mm in lead aVR. The positive R wave in aVR is shown in the yellow circle.

saturation of 100%. Initial blood gas analysis showed metabolic acidosis with arterial lactate of 2.6 mmol/l (Table 1). The electrocardiogram (ECG) showed a QRS interval >100 ms and a corrected QT interval of 475 ms (Figure 1), which was treated with a bolus of 150 ml of 3% hypertonic saline and 100 mEq of 8.4% sodium bicarbonate. Because the ECG changes persisted, 4 gm of magnesium sulfate was also administered.

An emergency ultrasound showed gastric contents with mixed echogenicity. The patient had a second cardiac arrest, and cardiopulmonary resuscitation was commenced. Intravenous epinephrine (3 mg) and sodium bicarbonate (100 mEq) were administered with no response, which prompted the administration of a 1.5 mL/kg bolus of 20% lipid emulsion. After 10 minutes, the patient regained a pulse. Treatment with vasopressors commenced, and an infusion of intravenous lipid emulsion (ILE) therapy continued at 0.25 mL/kg/min for 30 minutes, at which time the QRS interval normalized (Figure 2). The patient was weaned off vasopressors and mechanical ventilation during the next 24 hours, and she had no residual neurological deficit.

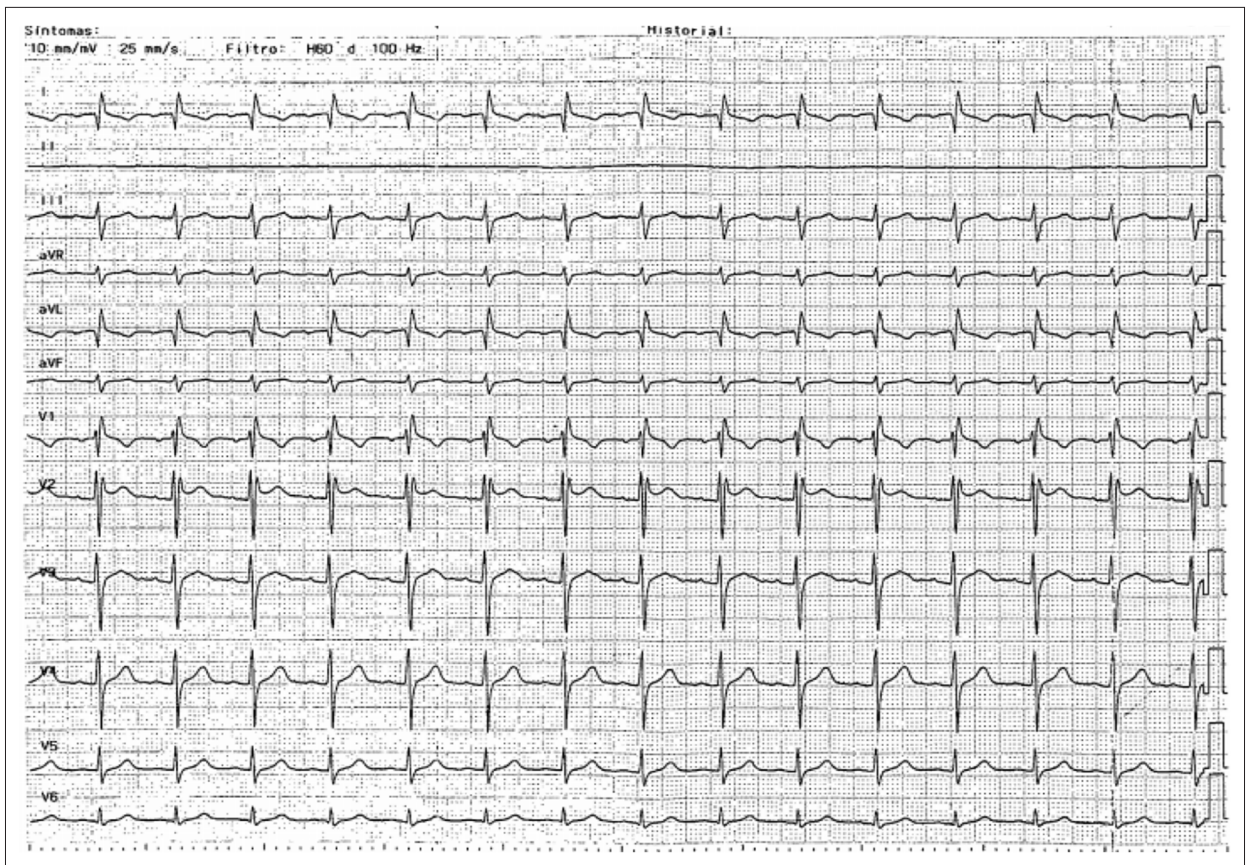
## Discussion

Amitriptyline is highly lipophilic and has a large volume of distribution [9]. In adults, life-threatening symptoms can occur

with doses that exceed 1000 mg [9]. The patient described in this case report had consumed almost four times the lethal dose of amitriptyline (3,700 mg), and cardiovascular and neurologic toxicity occurred. Tricyclic antidepressants affect the cardiac conduction system and the myocardium by blocking the fast sodium channel and slowing phase zero depolarization, resulting in lengthening of the cardiac action potential [10,11]. The conduction delay prolongs the QRS complex [10], and the increase in the duration of repolarization prolongs the QT interval [11]. Patients with a QRS >100 ms are more likely to develop respiratory depression and convulsions [12–14]. These changes were present in the initial electrocardiogram (ECG) for the patient in this report.

The patient arrived at our hospital more than four hours after taking an overdose of amitriptyline. The administration of activated charcoal or gastric lavage was not indicated. The potential application of ultrasound in the detection of pills in the stomach has been previously described [15]. The sensitivity and specificity of gastric ultrasound in the visualization of ingested pills after 60 minutes following ingestion are 20.8% and 79.1%, respectively [15,16]. The presence of food or lack of fluid inside the stomach, the dissolution of the tablets, or their passage to the pylorus may impair the visualization of ingested pills using gastric ultrasound, and gastric lavage may not show benefit [16]. Also, in this case, toxicity was already





**Figure 2.** The electrocardiogram (ECG) after administration of intravenous lipid emulsion (ILE) therapy. The electrocardiogram (ECG), amplitude 1 mV and speed 25 mm/sec. ILE was given as rescue therapy following amitriptyline overdose. The QRS duration is normalized, the terminal R wave is <3 mm in aVR.

established, and gastric lavage may have had little effect by the time the patient was being treated in hospital.

First-line treatment for wide-complex dysrhythmia and for reversing conduction delays and correcting hypotension is sodium loading [17]. Increasing the extracellular concentration of sodium may overwhelm the effective blockade of sodium channels, possibly through gradient effects [17]. Sodium loading effectively reduces the prolongation of the QRS complex, increases blood pressure, and suppresses ventricular dysrhythmias [18]. Hypertonic sodium chloride and sodium bicarbonate are significantly more effective than hyperventilation in reversing the QRS interval [3]. The successful use of magnesium sulfate in the treatment of refractory ventricular fibrillation has also been reported [19].

Lidocaine is another treatment option in cases where cardiac arrhythmias persist [20]. However, lidocaine is a known sodium channel blocker that has been used to treat cardiotoxicity induced by other sodium channel blockers, with efficacy that may be partly explained by competitive binding [20]. Tricyclic antidepressants induce a dose-dependent block of the inward

sodium current, with slow recovery time, and the rapid on/off kinetics may result in more sodium channels being available to propagate an action potential [21]. Lidocaine may improve the tricyclic antidepressant-induced delayed phase zero conduction velocity, resulting in the normalization of the wide QRS complex. However, although clinical data are limited, some reports have shown beneficial effects of lidocaine in the treatment of overdose from tricyclic antidepressants [21,22].

Intravenous lipid emulsion (ILE) therapy has been shown to increase the survival rates in cardiac arrest following bupivacaine overdose [23]. The administration of lipids compartmentalizes the lipophilic drug into the lipid phase and away from its target receptors [24]. The lipophilic drugs with high lipid solubility (with  $\log P > 2.0$ ) favor lipid extraction from the serum, known as the lipid sink theory [24]. Also, the infusion of triglycerides and phospholipids provides a sustained fatty acid energy source to cardiac myocytes under conditions of drug toxicity [25].

In a recent systematic review of the efficacy of ILE therapy in poisoning, a beneficial effect was reported in 71% of the clinical cases identified, and most reports of the use of its use in

amitriptyline overdose were associated with patient survival [3]. However, there have been no controlled clinical studies on the effects of ILE therapy in tricyclic drug overdose, and data derived from individual clinical studies or case series should be interpreted with caution [26]. ILE is currently used as rescue therapy in lipophilic drug toxicity associated with cardiac arrest after standard advanced cardiac life support (ACLS) has commenced, and when other treatments have failed [3]. Although this case has demonstrated the effects of ILE as rescue therapy, this and other cases suggest potential benefits for the use of ILE therapy at the same time as standard therapy, but not immediately after the ingestion of the drug overdose. In a rat model, the administration of ILE early after oral amitriptyline overdose resulted in reduced survival and no improvement in cardiac function [27]. Also, in this rat model, blood concentrations of amitriptyline were higher in the ILE-treated group, which suggests that either drug absorption from the gastrointestinal tract was increased or drug redistribution was reduced when ILE was given early after oral drug overdose [27].

## References:

1. Woolf AD, Erdman AR, Nelson LS et al: Tricyclic antidepressant poisoning: An evidence-based consensus guideline for out-of-hospital management. *Clin Toxicol (Phila)*, 2007; 45(3): 203–33
2. Agarwala R, Ahmed SZ, Wiegand TJ: Prolonged use of intravenous lipid emulsion in a severe tricyclic antidepressant overdose. *J Med Toxicol*, 2014; 10(2): 210–14
3. Gosselin S, Hoegberg LC, Hoffman RS et al: Evidence-based recommendations on the use of intravenous lipid emulsion therapy in poisoning. *Clin Toxicol (Phila)*, 2016; 54(10): 899–923
4. Giwa A, Oey E: The return of an old nemesis: Survival after severe tricyclic antidepressant toxicity, a case report. *Toxicol Rep*, 2018; 5: 357–62
5. Engels PT, Davidow JS: Intravenous fat emulsion to reverse haemodynamic instability from intentional amitriptyline overdose. *Resuscitation*, 2010; 81: 1037–39
6. Sabah KMN, Chowdhury AW, Islam MS et al: Amitriptyline-induced ventricular tachycardia: A case report. *BMC Res Notes*, 2017; 10(1): 286
7. Harvey M, Cave G: Case report: Successful lipid resuscitation in multi-drug overdose with predominant tricyclic antidepressant toxidrome. *Int J Emerg Med*, 2012; 5(1): 8
8. Le Fevre P, Gosling M, Acharya K et al: Dramatic resuscitation with Intralipid in an epinephrine unresponsive cardiac arrest following overdose of amitriptyline and propranolol. *BMJ Case Rep*, 2017; 2017. pii: bcr2016218281
9. Woolf AD, Erdman AR, Nelson LS et al: Tricyclic antidepressant poisoning: An evidence-based consensus guideline for out-of-hospital management. *Clin Toxicol (Phila)*, 2007; 45(3): 203–33
10. Brennan FJ: Electrophysiological effects of imipramine and doxepin on normal and depressed cardiac Purkinje fibers. *Am J Cardiol*, 1980; 46: 599–606
11. Wolfe TR, Caravati EM, Rollins DE: Terminal 40-ms frontal plane QRS axis as a marker for tricyclic antidepressant overdose. *Ann Emerg Med*, 1989; 18(4): 348–51
12. Manini AF, Nelson LS, Skolnick AH et al: Electrocardiographic predictors of adverse cardiovascular events in suspected poisoning. *J Med Toxicol*, 2010; 6(2): 106–15
13. Boehnert MT, Lovejoy FH Jr.: Value of the QRS duration versus the serum drug level in predicting seizures and ventricular arrhythmias after an acute overdose of tricyclic antidepressants. *N Engl J Med*, 1985; 313: 474–79
14. Hansen CS, Pottgård A, Ekelund U et al: Association between QTc prolongation and mortality in patients with suspected poisoning in the emergency department: A transnational propensity score matched cohort study. *BMJ Open*, 2018; 8(7): e020036
15. Amital Y, Silver B, Leikin JB et al: Visualization of ingested medications in the stomach by ultrasound. *Am J Emerg Med*, 1992; 10(1): 18–23
16. Sullivan S, Wolterstorff C, Johnson J et al: Accuracy of trans-abdominal ultrasound in a simulated massive acute overdose. *Am J Emerg Med*, 2016; 34(8): 1455–57
17. Nelson LS, Lewin NA, Howland MA et al: Goldfrank's toxicologic emergencies. 9<sup>th</sup> ed. New York, McGraw Hill Medical, 2015
18. Blackman K, Brown SG, Wilkes GJ: Plasma alkalization for tricyclic antidepressant toxicity: A systematic review. *Emerg Med (Fremantle)*, 2001; 13(2): 204–10
19. Citak A, Soysal DD, Ucsel R et al: Efficacy of long duration resuscitation and magnesium sulphate treatment in amitriptyline poisoning. *Eur J Emerg Med*, 2002; 9(1): 63–66
20. Foianini A, Joseph Wiegand T, Benowitz N: What is the role of lidocaine or phenytoin in tricyclic antidepressant-induced cardiotoxicity? *Clin Toxicol (Phila)*, 2010; 48(4): 325–30
21. Whitcomb DC, Gilliam FR III, Starmer CF et al: Marked QRS complex abnormalities and sodium channel blockade by propoxyphene reversed with lidocaine. *J Clin Invest*, 1989; 84: 1629–36
22. Dolara P, Franconi F: Hypertonic sodium chloride and lidocaine in a case of imipramine intoxication. *Clin Toxicol*, 1977; 10: 395–98
23. Rosenblatt MA, Abel M, Fischer GW, Itzkovich CJ, Eisenkraft JB: Successful use of a 20% lipid emulsion to resuscitate a patient after a presumed bupivacaine-related cardiac arrest. *Anesthesiology*, 2006; 105(1): 217–18
24. French D, Smolin C, Ruan W et al: Partition constant and volume of distribution as predictors of clinical efficacy of lipid rescue for toxicological emergencies. *Clin Toxicol*, 2011; 49(9): 801–9
25. Cao D, Heard K, Foran M et al: Intravenous lipid emulsion in the Emergency Department: A systematic review of recent literature. *J Emerg Med*, 2015; 48(3): 387–97
26. Levine M, Hoffman RS, Lavergne V et al: Systematic review of the effect of intravenous lipid emulsion therapy for non-local anesthetics toxicity. *Clin Toxicol*, 2016; 54(3): 194–221
27. Perichon D, Turfus S, Gerostamoulos D et al: An assessment of the *in vivo* effects of intravenous lipid emulsion on blood drug concentration and haemodynamics following oro-gastric amitriptyline overdose. *Clin Toxicol*, 2013; 51(4): 208–15

## Conclusions

This report is of a case of a 28-year-old woman who presented with cardiac arrest due to amitriptyline overdose and who responded to intravenous lipid emulsion (ILE) therapy. Despite the frequency and severity of poisoning with tricyclic antidepressants, there is little consensus among physicians regarding patient management. This case showed the successful use of ILE as rescue therapy for patients with cardiac arrest due to overdose with amitriptyline. The prompt response from the emergency team guaranteed rapid intervention that may have influenced the outcome. However, the successful outcome obtained in this case is not a recommendation for the use of ILE as a first-line treatment for the management of patients with tricyclic antidepressant drug overdose. Controlled clinical studies are required to evaluate the safety and efficacy of ILE in the management of tricyclic antidepressant drug overdose.

## Conflict of interest

None.