

# Volume analysis of heat-induced cracks in human molars: A preliminary study

Michael A. Sandholzer<sup>1,2</sup>,  
Katharina Baron<sup>1,3</sup>,  
Patrick Heimel<sup>4</sup>,  
Brian D. Metscher<sup>5</sup>

<sup>1</sup>Department of Anthropology, University of Vienna, Althanstrasse, 1090 Vienna, Austria, <sup>2</sup>School of Dentistry, University of Birmingham, St. Chads Queensway, Birmingham B4 6NN, United Kingdom, <sup>3</sup>Faculty of Science, FNWI, University of Amsterdam, Amsterdam, The Netherlands, <sup>4</sup>Department of Oral Surgery, Medical University of Vienna, Sensengasse, <sup>5</sup>Department of Theoretical Biology, University of Vienna, Althanstrasse, 1090 Vienna, Austria

**Address for correspondence:**  
Mr. Michael A. Sandholzer M.Sc,  
School of Dentistry, University of Birmingham, St Chad's Queensway, Birmingham - B4 6NN, UK.  
E-mail: m.sandholzer@gmail.com

## Abstract

**Context:** Only a few methods have been published dealing with the visualization of heat-induced cracks inside bones and teeth. **Aims:** As a novel approach this study used nondestructive X-ray microtomography (micro-CT) for volume analysis of heat-induced cracks to observe the reaction of human molars to various levels of thermal stress. **Materials and Methods:** Eighteen clinically extracted third molars were rehydrated and burned under controlled temperatures (400, 650, and 800°C) using an electric furnace adjusted with a 25°C increase/min. The subsequent high-resolution scans (voxel-size 17.7 µm) were made with a compact micro-CT scanner (SkyScan 1174). In total, 14 scans were automatically segmented with Definiens XD Developer 1.2 and three-dimensional (3D) models were computed with Visage Imaging Amira 5.2.2. The results of the automated segmentation were analyzed with an analysis of variance (ANOVA) and uncorrected *post hoc* least significant difference (LSD) tests using Statistical Package for Social Sciences (SPSS) 17. A probability level of  $P < 0.05$  was used as an index of statistical significance. **Results:** A temperature-dependent increase of heat-induced cracks was observed between the three temperature groups ( $P < 0.05$ , ANOVA *post hoc* LSD). In addition, the distributions and shape of the heat-induced changes could be classified using the computed 3D models. **Conclusion:** The macroscopic heat-induced changes observed in this preliminary study correspond with previous observations of unrestored human teeth, yet the current observations also take into account the entire microscopic 3D expansions of heat-induced cracks within the dental hard tissues. Using the same experimental conditions proposed in the literature, this study confirms previous results, adds new observations, and offers new perspectives in the investigation of forensic evidence.

**Key words:** Fire victims, forensic odontology, forensic science, heat-induced changes, X-ray microtomography


## Introduction

Burned human remains are frequently found after natural disasters or house fires,<sup>[1,2]</sup> as a result of either

direct contact with open flames or the exposure to high temperatures.<sup>[3]</sup> In some cases fire is used to destroy forensic evidence and prevent clear identification and recovery.<sup>[4]</sup> Positive identification and investigation of burned human remains require a great deal of experience and care.<sup>[5]</sup>

Andersen *et al.*,<sup>[6]</sup> classified six grades of fire injuries to teeth and jaws: (0) No injury, (1) injury to anterior teeth, (2) injury to anterior and posterior teeth (unilaterally), (3) injury to anterior and posterior teeth (bilaterally), (4) fragments of jaw bone including teeth and/or roots, and (5) no dental remains. Bohnert *et al.*,<sup>[7]</sup> listed the effects of fire on the skull based on observations of cremations

### Access this article online

<b>Website:</b> www.jfds.org	<b>Quick Response Code</b> 
<b>DOI:</b> 10.4103/0975-1475.132545	

carried out at 670 to 810°C. Teeth are primarily protected by the soft tissue, muscles and fat for 10 to 24 min, and consequently the temperature inside the oral cavity does not rise above 87°C, depending on the nutritional state, age, temperature, and time of exposure. In 23.4% of the incomplete cremations in forensic cases, the soft tissue of the skull is affected and the heat gets access to the oral cavity.<sup>[8]</sup> Therefore, the posterior teeth are preserved due to the layers of skin, muscle, and fatty tissue and are more likely to be used for the identification process of the deceased.<sup>[3]</sup> A general estimation of burning temperature could provide important information to reconstruct a criminal act. The results provided in this study are of current importance for the field of forensic odontology, providing a more detailed understanding of thermal stress induced three-dimensional (3D) alterations in human teeth.

Recently, the focus of analysis has shifted from macroscopic heat-induced changes to the microscopic changes. In general, macroscopic changes can be influenced by a large number of external factors such as time and temperature of heat exposure, availability of oxygen, as well as material properties; and therefore do not seem to be the ideal tool for temperature estimation.<sup>[9]</sup> So far, microstructure and ultrastructure of burned bones and teeth have mainly been examined by using histology,<sup>[10,11]</sup> X-ray diffraction (XRD),<sup>[12]</sup> Fourier transform infrared spectroscopy (FTIR),<sup>[13]</sup> small-angle X-ray scattering (SAXS),<sup>[14]</sup> and scanning electron microscope (SEM).<sup>[15,16]</sup> All of these sophisticated but destructive methods have been used throughout many decades, and can be useful for the estimation of cremation temperature range of bones and teeth as well as for the characterization of dental filling materials. However, the destruction of the material is sometimes not acceptable for evidence from forensic cases.

Therefore, noninvasive and nondestructive methods had to be found in order to analyze heat-induced changes of bones and teeth.

### Visualization of heat-induced changes

Savio *et al.*,<sup>[17]</sup> evaluated the effects of high temperatures on human teeth using periapical radiographs. In their study, 90 unrestored and endodontically treated human teeth were analyzed after exposure to temperatures from 200-1,100°C using an electric furnace with a constant increase of 30°C/min. A visible increase of heat-induced cracks was found.

The first use of 3D imaging methods on burned bones was by Thompson and Chudek,<sup>[18]</sup> who used magnetic resonance imaging (MRI) to visualize heat-induced changes. The authors used 1.5 cm thick sections of sheep bone and exposed them two times for 30 min at 700°C using an electric furnace. Due to the reduced resolution, the scans could not show the detailed 3D alterations of skeletal tissue.

### Aim of micro-CT study

For a better understanding of the heat-induced 3D changes inside teeth, the noninvasive imaging technology of micro-CT was used for the first time in this application. This experimental study provides image data for a qualitative 3D reconstruction as well as quantitative results. This novel approach to evaluating burned human teeth produced results for a more detailed understanding of thermal stress-induced 3D alterations in human teeth as well as useful statistical data for interpretation and estimation of burning temperatures.

## Subjects and Methods

### Human teeth sampling and preparation

A total of 18 human third molars from clinical extractions were cleaned to eliminate blood residues, and disinfected in a 5% sodium hypochlorite solution for 30 min. A declaration of consent was filled out by every donor involved in this study. Teeth were excluded from the study because of unknown patient age, damages (e.g. broken roots), endodontic treatments, dental restorations or caries. The 18 intact third molars (nine female and nine male, mean age: 23.06 ± 2.15 years) were rehydrated by using phosphate buffered saline at room temperature.

### Thermal treatment

The 18 teeth were randomly divided into three groups before subjecting them to the thermal stress. Six teeth of each temperature group (400, 650, and 800°C) were put in crucibles and burned at the same time in an electric furnace (Medlin Naber N3R, Vienna, Austria) with 25°C increase per min starting at room temperature. The time of thermal stress exposure for each group was on average 13.25 min to reach 400°C; 23.25 min to reach 650°C, and 31.5 min to reach 800°C. As soon as the desired temperature was reached the specimens were removed from the furnace, cooled to room temperature in air and then stored in conical tubes padded with cotton. The macroscopic changes of the teeth were described and documented by direct vision of the samples and photographs using a compact digital camera.

### Micro-CT study

This study was performed using a SkyScan 1174 compact micro-CT scanner (SkyScan, Kontich, Belgium). The general settings for the scans were a voxel size of 17.7 µm, exposure time of 3,500-4,500 ms (800 µA, 50 kV), 180° rotation (with three projections images per degree), 0.5 mm aluminum filter, and random movement, resulting in a mean scanning time of 56 h. The resulting slices were reconstructed using NSRECON (SkyScan, Kontich, Belgium). The original scanning files (1024 × 1024 pixels) were stored in 16-bit TIFF format; the reconstructed files were saved as 8-bit JPEGs for easier handling during the 3D reconstruction.

### 3D Reconstruction

Following the tomographic reconstruction (SkyScan NRECON; SkyScan, Kontich, Belgium) and conversion

of the raw data (Adobe® Photoshop Creative Suite 4) the scans were segmented, measured, and reconstructed. The automated segmentation was done with Definiens XD Developer 1.2 (Definiens AG, Munich, Germany) based on a specially developed image analysis algorithm, which allowed the classification of voxel (3D pixel) data into objects representing the dental pulp, cracks, and dental tissue on the basis of grey scale and shape differences. To control the results of the automated segmentation, additional manual segmentation was carried out in five cases using Visage Imaging Amira 5.2.2 (Visage Imaging Inc., San Diego, USA). The resulting data (voxels representing the volume of the three classes) of the automated segmentation were analyzed with Statistical Package for Social Sciences (SPSS) 17 (SPSS Inc., Chicago, USA) software package. The final 3D reconstruction was also performed with Visage Imaging Amira 5.2.2.

**Statistical analysis**

The results of the automated segmentation were analyzed with an analysis of variance (ANOVA) and uncorrected *post hoc* least significant difference (LSD) tests using SPSS 17 (SPSS Inc., Chicago, USA) software package. A probability level of  $P < 0.05$  was used as an index of statistical significance.

**Results**

**Heat-induced changes**

Three teeth completely broke apart during the heating process and one tooth during the subsequent handling. In total, 14 teeth (400°C group,  $n = 5$ ; 650°C group,  $n = 5$ ; 800°C,  $n = 4$ ) were included in the statistical data analysis.

**400°C group**

At 400°C the teeth showed a loss of brightness of the crown and root. In two cases the root acquired a brown color. A partial or full debonding of the crown alongside the dentin-enamel junction was observed in none of the

specimens. In the micro-CT images only small cracks were visible in the crown region, whereas multiple small cracks were in the root region [Figure 1]. These cracks were frequently located in the root and usually did not reach the dentin-enamel junction. In the 3D models, the 400°C group showed mostly longitudinal cracks, and in rare cases also in the transverse direction. The mean volume of cracks was 2.95% (SD:  $\pm 1.83\%$ , values ranging from 1.61–4.38%) [Table 1] of the total tooth volume.

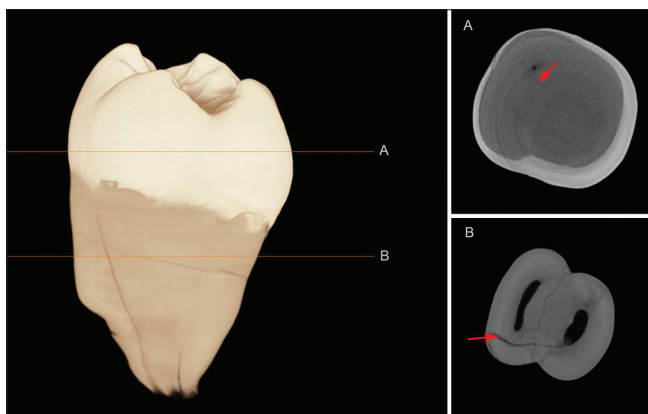
**650°C group**

The teeth subjected to 650°C became fragile and showed grayish-black discoloration of the whole tooth. A partial or full debonding of the crown alongside the dentin-enamel junction was observed in all specimens. Fragmentation after the separation of the crown could be observed in two specimens. In the micro-CT images a variety of cracks were identified [Figure 2]. Deep cracks were evident in the root, whereas the enamel surface showed small cracks. The

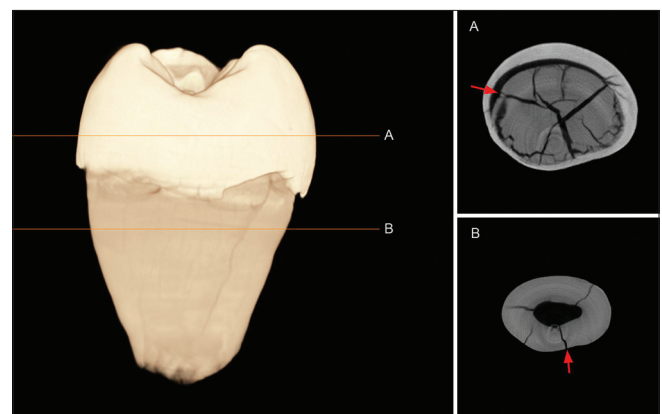
**Table 1: Volume obtained from automated segmentation data**

	TEMP	PC	PDM	PDP
Tooth 13	400°C	1.61	95.29	3.10
Tooth 4		2.22	92.48	5.30
Tooth 10		2.50	93.76	3.74
Tooth 18		4.05	93.12	2.83
Tooth 7		4.38	93.15	2.47
Tooth 11	650°C	5.02	89.76	5.32
Tooth 17		6.54	90.35	3.11
Tooth 14		6.57	89.99	3.44
Tooth 5		8.81	87.15	4.04
Tooth 2		11.83	82.92	5.25
Tooth 15	800°C	4.03	91.77	4.20
Tooth 9		5.55	89.63	4.82
Tooth 12		14.51	81.28	4.21
Tooth 6		14.54	83.20	2.26

TEMP: Temperature group, PC: Percentage cracks, PDM: Percentage dental material, PDP: Percentage dental pulp



**Figure 1:** Three dimensional surface rendering and corresponding X-ray microtomography slice of a burned molar (400°C, tooth 7) showing no debonding of the enamel. (a) Small longitudinal cracks present in the crown region, (b) multiple longitudinal and transverse cracks and small cracks in the root region



**Figure 2:** 3D surface rendering with corresponding micro-CT slices of a burned molar (650°C, tooth 5) showing partial debonding of the enamel. (a) The majority of the cracks (longitudinal, transverse, and contour) are present in the dentin-enamel junction area, (b) Deep cracks are evident in the root region

vast majority of the cracks were present in the area of the dentin-enamel junction. In general, this region showed a small amount of cracks accompanied by many small cracks around the dentin-enamel border. The cracks did also affect the enamel, but only rarely propagated out through the enamel. In the 3D models, the 650°C group mostly showed cracks in longitudinal and transverse direction arising from the dental pulp, and a complex contour pattern could be found [Figure 3]. The mean volume of cracks was 7.75% (SD:  $\pm 2.65\%$ , values ranging from 5.02 – 11.83%) [Table 1] of the total tooth volume.

### 800°C group

In general, the teeth subjected to 800°C became very fragile and showed chalky white discoloration of the root and slightly grayish color variations of the crown. A partial or full debonding of the crown alongside the dentin-enamel junction was observed in all specimens. Fragmentation after the separation of the crown could be observed in two specimens. In the micro-CT images a variety of cracks was observed [Figure 4]. The vast majority of the cracks were present in the area of the dentin-enamel junction. In general, this region showed massive cracks with many small cracks around the dentin-enamel border. The cracks did also affect the enamel and did propagate out through the enamel. In the 3D models, the 800°C group mostly showed cracks in longitudinal and transverse direction arising from the dental pulp, and a complex contour pattern could be found. The mean volume of cracks was 9.65% (SD:  $\pm 5.65\%$ , values ranging from 4.03 – 14.54%) [Table 1] of the total tooth volume.

### Statistical analysis

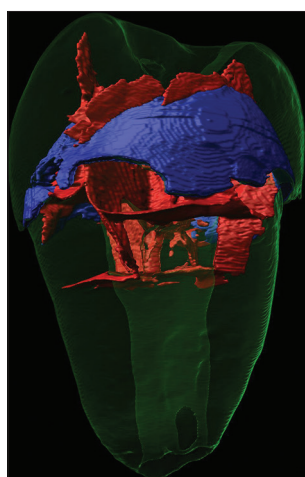
The results of the volume data elicited from the automated segmentation, which were analyzed with SPSS 17, are given in Table 1. A statistically significant ( $P < 0.05$ , ANOVA *post hoc* LSD) temperature-dependent increase

of heat-induced cracks was observed between 400 and 650°C ( $P = 0.049$ ), as well as 400 and 800°C ( $P = 0.014$ ). ANOVA tests ( $P < 0.05$ ) also showed that in this study the total volume of the tooth as well as the volume of the dental pulp did not influence the total volume of cracks.

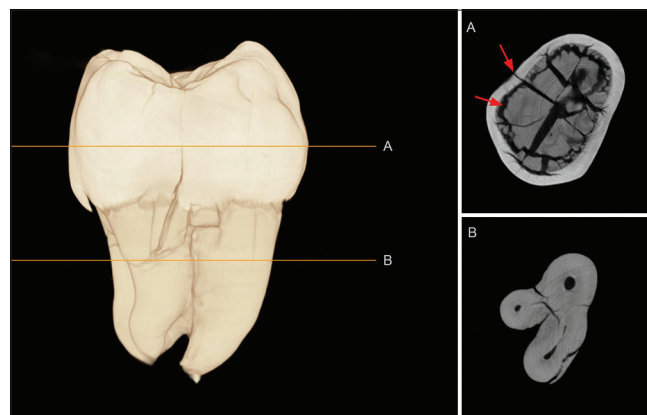
## Discussion

An important factor, generally not taken into account in lab-based experiments but present in an actual house fire is the fast increase of temperature, possible usage of fire accelerants, the longer duration of heat exposure, and the fast cooling due to quench water. These facts are expected to lead to modified results. This study used a 25°C gradual increase per min, comparable to other previous experimental studies dealing with heat-induced changes of teeth.<sup>[10,17]</sup>

The macroscopic heat-induced color changes of this study correspond with previous observations of unrestored human teeth.<sup>[19-21]</sup> In total, four specimens of the 650°C and 800°C temperature group had a completely fragmented crown [Figure 5]. The different material properties of dentin and enamel cause a separation and fragmentation of the crown between 400 and 500°C.<sup>[11]</sup> The partial or full debonding of the crown alongside the dentin-enamel junction is strongly related to the final temperature and heat-induced dentinal shrinkage.<sup>[22,23]</sup> Hughes and White<sup>[22]</sup> indicate that teeth undergo dehydration which makes the dentin material more brittle and dentin-enamel junction weaker. Additionally, the location of the origin of the cracks near the dental pulp cavity is caused by the intertubular tensile stress, allowing the crack to propagate through the structurally modified dentin and enamel.<sup>[22]</sup> Moreover, the organic and water content of the dentin, which is expected to be higher in young teeth, supports the rapid evaporation of the stored water, leading to a more complex crack pattern.<sup>[11]</sup> The statistical results have primarily been influenced by two

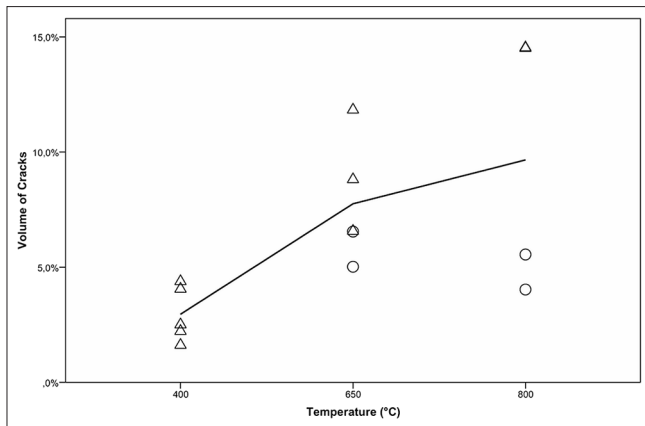


**Figure 3:** 3D reconstruction model (650°C, tooth 5). Cracks in longitudinal and transverse direction arising from the dental pulp (shown in red), and complex contour pattern at the dentin-enamel junction (blue)



**Figure 4:** 3D surface rendering and corresponding micro-CT slices of burned molar (800°C, tooth 12) showing partial debonding of the enamel. (a) The majority of the massive cracks (longitudinal, transverse, and contour) are present in the dentin-enamel junction area, (b) Deep cracks evident in the root region





**Figure 5:** Scatter plot of group classifications including interpolation line. Triangles indicate the presence of the crown, while circles indicate its absence after the heat exposure. In the 400°C group enamel was generally preserved, while enamel was often missing in the 650 and 800°C groups

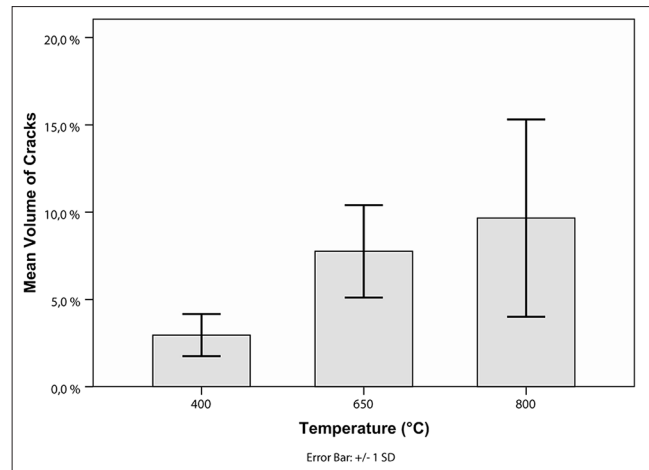
factors. Firstly, by the small sample size ( $n = 14$ ) and secondly, the separation of the crown led to a variance in the total volume of cracks [Figure 6]. Nonetheless, a general increase in heat-induced crack volume could be observed giving an additional indication of high-temperature exposure.

In the last few years, micro-CT scanning technology has become commonly used in various fields of biology and medicine, including forensic sciences.<sup>[23]</sup> The most important advantage of micro-CT over MRI and CT is its high resolution. Whilst earlier MRI studies on heat-induced changes of bones used a voxel size of 230  $\mu\text{m}$ ,<sup>[18]</sup> micro-CT provided a voxel size as small as 17.7  $\mu\text{m}$ , allowing the visualization of fine cracks, normally only visible in light microscopic observations. However, as micro-CT is based on X-ray transmission images, teeth fillings with metal compositions would lead to artifacts influencing the image data analysis.

The automated segmentation approach used in this study gave accurate and repeatable results. All measurements were computed using the same image algorithm; therefore, an intraexaminer error is not present. Manual control of the segmentation results were additionally carried out in five cases, but showed no major influence on the originally elicited data. This novel approach has advantages in comparison to previously proposed methods. In contrast to histological sections, SEM, XRD, SAXS, and FTIR; micro-CT is nondestructive and can therefore also be used in forensic and archeological investigations without destroying the specimen.

## Conclusion

This small-scale preliminary study showed how isolated human teeth react to high temperatures and indicated a temperature-specific volume of cracks. Relevant data of the



**Figure 6:** Mean volume of cracks is shown ( $\pm 1$  standard deviation (SD)). The error bars indicate a small variation of crack volume in the 400°C group, whilst in the 650 and 800°C group the variation of crack volume was much higher due to presence/absence of crown

cracks could be effectively elicited from the burned remains using modern techniques and analytical methods. The use of micro-CT proved to have clear advantages over earlier, mostly invasive or destructive, methods. Although this study had a limited sample size, micro-CT appears to be a feasible supportive method for determining temperatures of burned human remains. This technique revealed novel insights into heat-induced changes of teeth, offering new perspectives for forensic investigations as well as archeological excavation material.

## References


1. Lain R, Taylor J, Croker S, Craig P, Graham J. Comparative dental anatomy in disaster victim identification: Lessons from the 2009 Victorian bushfires. *Forensic Sci Int* 2011;205:36-9.
2. Sledzik W, Rodriguez I, Damnumm F. The taphonomic fate of human remains in mass disasters. In: Haglund W, Sorg M, editors. *Advances in Forensic Taphonomy: Method, Theory and Archaeological Perspectives*. 1<sup>st</sup> ed. Boca Raton: CRC Press; 2002. p. 321-30.
3. Anderson SG, Bernstein ML, Berryman HE, Bowers CM, Bush MA, Bush PJ *et al.* Human Identification. In: Herschaft EE, Alder ME, Ord DK, Rawson RD, Smith ES, editors. *Manual of Forensic Odontology*. 4<sup>th</sup> ed. American Society of Forensic Odontology; 2007. p. 7-102.
4. Ubelaker DH. The forensic evaluation of burned skeletal remains: A synthesis. *Forensic Sci Int* 2009;183:1-5.
5. Griffiths CJ, Bellamy GD. Protection and radiography of heat affected teeth. *Forensic Sci Int* 1993;60:57-60.
6. Andersen L, Juhl M, Solheim T, Borrman H. Odontological identification of fire victims-potentialities and limitations. *Int J Leg Med* 1995;107:229-34.
7. Bohnert M, Rost T, Pollak S. The degree of destruction of human bodies in relation to the duration of the fire. *Forensic Sci Int* 1998;95:11-21.
8. Gerling I, Meißner A, Reiter M, Oehmichen M. Tod durch thermische Einwirkung: Analyse von 106 obduzierten Fällen des Lübecker Instituts für Rechtsmedizin 1990-1998. [Death due to thermal exposure: Analysis of 106 cases at the Institute

- of Legal Medicine Lübeck, 1990-1998] In: Oehmichen M, editor. *Hyperthermie, Brand und Kohlenmonoxid*. 1<sup>st</sup> ed. Lübeck: Schmidt-Römhild; 2000. p. 241-56.
9. Walker P, Miller K, Richman R. Time, temperature and oxygen availability: An experimental study of the effects of environmental conditions on the color and organic content of cremated bone. In: Schmidt C, Symes S, editors. *The Analysis of Burned Human Remains*. 1<sup>st</sup> ed. Amsterdam: Academic Press; 2008. p. 129-35.
  10. Ferreira JL, Ferreira AE, Ortega AI. Methods for the analysis of hard dental tissue exposed to high temperatures. *Forensic Sci Int* 2008;178:119-24.
  11. Myers SL, Williams JM, Hodges JS. Effects of extreme heat on teeth with implications for histologic processing. *J Forensic Sci* 1999;44:805-9.
  12. Piga G, Thompson TJ, Malgosa A, Enzo S. The Potential of X-Ray diffraction in the analysis of burned remains from forensic contexts. *J Forensic Sci* 2009;54:534-9.
  13. Thompson TJ, Gauthier M, Islam M. The application of a new method of fourier transform infrared spectroscopy to the analysis of burned bone. *J Archaeol Sci* 2009;36:910-4.
  14. Sandholzer MA, Sui T, Korsunsky A, Walmsley AD, Lumley PJ, Landini G. (in press) X-ray scattering evaluation of ultrastructural changes of human dental tissue with thermal treatment. *J Forensic Sci*.
  15. Fairgrieve S. SEM analysis of incinerated teeth as an aid to positive identification. *J Forensic Sci* 1994;39:557-65.
  16. Holden JL, Phakey PP, Clement JG. Scanning electron microscope observations of heat-treated human bone. *Forensic Sci Int* 1995;74:29-45.
  17. Savio C, Merlati G, Danesino P, Fassina G, Menghini P. Radiographic evaluation of teeth subjected to high temperatures: Experimental study to aid identification processes. *Forensic Sci Int* 2006;158:108-16.
  18. Thompson TJ, Chudek JA. A novel approach to the visualisation of heat-induced structural change in bone. *Sci Justice* 2007;47:99-104.
  19. Merlati G, Danesino P, Savio C, Fassina G, Osculati A, Menghini P. Observations on dental prostheses and restorations subjected to high temperatures: Experimental studies to aid identification processes. *J Forensic Odontostomatol* 2002;20:17-24.
  20. Merlati G, Savio C, Danesino P, Fassina G, Menghini P. Further study of restored and unrestored teeth subjected to high temperatures. *J Forensic Odontostomatol* 2004;22:34-9.
  21. Moreno S, Merlati G, Marin L, Savio C, Moreno F. Effects of high temperatures on different dental restorative systems: Experimental study to aid identification processes. *J Forensic Dent Sci* 2009;1:17-23.
  22. Hughes CE, White CA. Crack propagation in teeth: A comparison of perimortem and postmortem behavior of dental materials and cracks. *J Forensic Sci* 2009;54:263-6.
  23. Sandholzer MA, Walmsley AD, Lumley PJ, Landini G. Radiologic evaluation of heat-induced shrinkage and shape preservation of human teeth using micro-CT. *J Forensic Radiol Imaging* 2013;1:107-11.

**How to cite this article:** Sandholzer MA, Baron K, Heimel P, Metscher BD. Volume analysis of heat-induced cracks in human molars: A preliminary study. *J Forensic Dent Sci* 2014;6:139-44.  
**Source of Support:** Nil, **Conflict of Interest:** None declared

Announcement

iPhone App



Download

iPhone, iPad  
application

A free application to browse and search the journal's content is now available for iPhone/iPad. The application provides "Table of Contents" of the latest issues, which are stored on the device for future offline browsing. Internet connection is required to access the back issues and search facility. The application is Compatible with iPhone, iPod touch, and iPad and Requires iOS 3.1 or later. The application can be downloaded from <http://itunes.apple.com/us/app/medknow-journals/id458064375?ls=1&mt=8>. For suggestions and comments do write back to us.