

Case Report

Beauveria bassiana keratitis: Management of an atypical clinical presentation

Pietro Ducange^{a,1}, Tommaso Verdina^{a,*}, Fabio Stiro^a, Antonella Grottola^b, Gabriella Orlando^c, Giancarlo Delvecchio^a, Rodolfo Mastropasqua^a

^a Institute of Ophthalmology, University of Modena and Reggio Emilia, Modena, Italy

^b Microbiology and Virology Unit, Azienda Ospedaliero-Universitaria Policlinico Modena, Modena, Italy

^c Infectious Disease Unit, Azienda Ospedaliero-Universitaria Policlinico Modena, Modena, Italy



ARTICLE INFO

Keywords:

Corneal ulcer
Fungal keratitis
Beauveria bassiana
Voriconazole

ABSTRACT

We report an atypical presentation of *Beauveria bassiana* keratitis which unusually presented in a 85-year-old patient with a corneal ulcer with an anterior segment inflammation and *hypopyon*. Despite negative culture and unspecific results from panfungal PCR-based sequencing, the patient was treated for a presumed fungal infection. Following clinical deterioration an emergency surgical intervention with apposition of a corneal patch was performed. Infection resolution was achieved following the introduction of systemic voriconazole to the topical one.

1. Introduction

Fungal keratitis (FK) is a corneal infection, which represents 35–50% of all microbial keratitis. Its prevalence varies according to climate (mainly noted in tropical and subtropical countries), agricultural activity and extension of urbanization and patient age, gender and socio-economic background [1]. FK is mostly caused by filamentous fungi (especially *Aspergillus*, *Fusarium*, *Curvularia*, *Paecilomyces* and *Beauveria* species) or yeasts (*Candida albicans* or *Candida* spp.) [2]. In 40–60% of cases, FK is consequent to corneal trauma with plant origin material. Other causes include corneal surgery (keratoplasty, refractive surgery), topical/systemic treatment with corticosteroids and the use of contact lenses [3].

Diagnostic delay and poor response to medical therapies, frequently cause a severe visual impairment, presenting a notable treatment challenge. Currently, FK treatment includes the use of topical and systemic antifungal drugs such as polyenes, imidazoles, triazoles and fluorinated pyrimidine administered orally and natamycin and amphotericin B topically. Voriconazole (VCZ; topical and oral) and posaconazole (oral) have recently been reported as newly discovered triazoles for FK treatment [4]. However, available drugs have a limited spectrum of activity, low intraocular penetration and can have toxic effects over the corneal epithelium, resulting in limited effectiveness and often mandatory

surgical intervention.

Beauveria bassiana (*B. bassiana*) is a ubiquitous filamentous fungus of the Ascomycota division found in soil. Since it is an entomopathogenic fungus, it is used as an insecticide, and is rarely found as a cause of human infection: *B. bassiana* has been isolated in opportunistic lung and tissue infections in immunocompromised patients [5] and several clinical cases of FK have been reported [6].

However, as clinical features of this rare fungus have not been fully determined and there seems to be a large variability in therapy response, currently there are no standardized therapeutic protocols. *B. bassiana* keratitis is therefore one of the most difficult corneal infections to manage. We report a case of *B. bassiana* keratitis with an unusual presentation.

2. Case

An 85-year-old male, one-eye sighted (amblyopia in the left eye), was unsuccessfully treated elsewhere following accidental contact with dirty gutter rain water, treated with ofloxacin drops 4 times/day (t/day), and, after 10 days without significant response, a supplementation of chloramphenicol/dexamethasone acetate drops was added 4 t/day. Forty days from the incident, the patient was referred to our clinic (Day 0) with reactive conjunctivitis and increasing pain in the right tearful eye,

* Corresponding author.

E-mail address: tommaso.verdina@gmail.com (T. Verdina).

¹ These authors contributed equally to this paper and should be considered as co-first authors.

suffering from photophobia.

An initial instrumental and clinical investigation revealed visual acuity of 0.1 decimals with the presence of a deep stromal corneal abscess associated with edema, cellularity in the anterior chamber and *hypopyon*. Chloramphenicol/dexamethasone drops treatment was interrupted and replaced with levofloxacin drops every hour and cycloplegic drops 2t/day were introduced. Following the administration of oxibuprocaine hydrochloride eye drops, a corneal swab of the ulcer and a corneal scraping (with a rough plastic handle passed over the corneal ulcer tissue in the central and peripheral portion of the lesion) were performed.

Molecular searching for bacteria, fungi and *Acanthamoeba* was undertaken. Corneal scraping was performed for fungal pathogen culture only, since the patient was already under topical antibiotic therapy. The collected clinical material was in part directly sown on blood agar and chocolate agar plates and directly inoculated in liquid Tryptic Soy Broth (TSB) medium. Both plates were incubated for nine days at 37 °C in a CO₂ enriched atmosphere, without any growth observed. TSB was incubated for six days at 37 °C and at 25 °C and then a subculture on blood and Sabouraud agar plates was performed, incubated for 3 days at 37 °C in a CO₂ enriched atmosphere and at 25 °C. Also in this case, no growth was observed.

Molecular corneal swab analysis was negative for bacteria and *Acanthamoeba*. The presence of a fungal infection was investigated by panfungal PCR-based sequencing. An automated purification of the DNA by QIA Symphony SP instrument (QIAGEN, Hilden, Germany), and subsequent amplification by a panfungal nested PCR of Internal Transcribed Spacer region (ITS), comprising the ITS1-5.8S-ITS2 rDNA was performed. Fungal DNA was amplified in a total volume of 50 µl containing 100 ng of DNA, 25 µl of DreamTaq Green PCR master mix (Fermentas International Inc., Canada) and 40 pmoles of each primer [outer primers: NS5 (AACTTAAAGGAATTGACGGAAG) [7] and NL4 (GGTCCGTGTTTCAAGACGG) [8]; inner primers ITS1 (TCCGTAGGTGAACCTGCGG) and ITS4 (TCCTCCGCTTATTGATATGC) [7]. Nested amplification product was electrophoresed in a 3% agarose gel and purified using a QIAquick PCR purification kit (QIAGEN). Finally, bidirectional Sanger sequencing of amplicons was performed with primers ITS1 and ITS4, using BigDye Terminator v3.1 Cycle Sequencing Ready Reaction kit (Applied Biosystems, Foster City, CA), and analyzed on the ABI PRISM 3100 Analyzer (Applied Biosystems). Sequences were analyzed and edited using CLC Main Workbench software (QIAGEN). The consensus sequence generated was finally compared with GenBank's reference sequence database (<http://www.ncbi.nlm.nih.gov/GenBank/>).

As described by Vu et al. the identification criteria for filamentous fungal species a coverage of 100% and an identity >99.6%, with best match sequences derived from referenced cultures [9]. In our case, the fungal sequence amplified by the corneal swab did not satisfy this identification criteria and was therefore undetermined. Further, the culture obtained through corneal scraping resulted negative for filamentous fungi and yeasts.

At day +3 further deterioration of the right eye was observed with a deep stromal corneal abscess which appeared denser with irregular margins. The patient presented increasing pain with decreased visual acuity (finger count at 20 cm). Fungal infection was assumed and the patient was hospitalized. Topical therapy with natamycin 5% eye-drops was administered every hour; antibiotic eye-drops were maintained (levofloxacin drops 6t/day). Another corneal scraping was performed on the central and peripheral portion of the lesion and tested for microbiological analysis, resulting negative for bacteria, yeasts and filamentous fungi searches.

At day +8, as a clinical improvement was not observed, VCZ 1% drops were added to the topical therapy and administered every hour.

At day +9 stability of the corneal abscess was registered and the ulcer staining of the abscess was reduced; however, an underlying endothelial plaque appeared with a worsening of the anterior chamber

reaction and the appearance of *hypopyon* mixed with blood and a fibrin reaction within the pupil foramen. The patient presented with ocular discomfort but was without pain. Topical therapy was maintained and oral therapy with VCZ 400 mg cps 2t/day was added for one day, which was then reduced to 200mg 2t/day from day +10. Serum levels of VCZ were evaluated using the liquid chromatography-tandem mass spectrometry (LC-MS/MS) [10].

Unfortunately, at day +22 a progressive corneal thinning at the corneal ulcer was revealed with the appearance of a descemetocoele. Then, at day +23, corneal perforation occurred with iris engagement in correspondence to the corneal ulcer, and the anterior chamber depth was dramatically reduced with persistence of *hypopyon* and fibrin reaction. The right eye presented increasing conjunctival redness and the patient referred ocular pain. Emergency corneal patch surgery was scheduled.

At day +24 a surgical intervention was performed. The corneal necrotic tissue was manually removed up to the pre-descemetocoele level. A 5mm diameter corneal patch was obtained from a donated cornea after the removal of the endothelium layer and was applied with interrupted sutures Nylon 10.0 to the cornea. The endothelial plaque below the perforation area and the extensive fibrin membranes above the iris surface were subsequently removed. VCZ 0.1 mg/ml and Vancomycin were injected into the anterior chamber and conjunctiva was sutured.

The excised corneal tissue was sent to the microbiology laboratory for analysis. The culture resulted positive for *Staphylococcus hominis*. Molecular analysis by panfungal PCR-based sequencing showed the presence of *B. bassiana*. In particular, we amplified a fragment of 569 bp presenting a 100% coverage and identity with a best match sequence derived from referenced culture CBS 127308 of *B. bassiana*. Post-operatively, natamycin and VCZ eye-drops 6t/day and levofloxacin 4t/day, oral VCZ 400 mg 2t/day were maintained.

At day +27, the corneal patch lost transparency with the progressive appearance of an epithelial defect and the cornea appeared denser with fibrin reaction in anterior chamber and *hypopyon*. The patient described ocular discomfort and a foreign body sensation. As serum levels of VCZ (0.50 µg/ml) were lower than the appropriate efficacious therapeutic range (1.00–6.00 µg/ml), systemic VCZ therapy was modified to 450 mg 2t/day for one day, and then subsequently reduced to 300 mg 2t/day and natamycin was interrupted.

At day +29, the serum concentration of VCZ was within the therapeutic range (4.31 µg/ml), and corneal opacification was resolved. At day +30, fibrinolytic reaction in the anterior chamber and *hypopyon* was also recorded as resolved.

At day +33 the patient was discharged with the following therapy: tropicamide 1% drops 2t/day, ofloxacin drops 4t/day, topical VCZ 1% drops 6t/day, oral VCZ 300 mg 2t/day.

The patient was instructed to return every 2 weeks for follow-up. At first follow up visit (day +47) progressive improvement of the cornea defect was observed. However, a mild inflammatory reaction involving the corneal patch with a deep neovascularization appeared. A topical dexamethasone acetate therapy 2t/day was prescribed and ofloxacin drops were interrupted. Topical VCZ was maintained 6 t/day and gradually reduced to 2t/day for 12 weeks, after which topical VCZ was interrupted.

At 2-month follow-up (day +60), systemic VCZ was interrupted, and topical steroid reduced to once/day (at night). The patient referred that he did no longer suffer from any ocular discomfort.

During patient hospitalization and the administration of systemic VCZ therapy, QT time at electrocardiogram (ECG) and the activities of serum glutamic oxaloacetic transaminase and glutamic pyruvic transaminase were monitored, every three days. All values remained within normal ranges (mean values: 454±13 msec, 20.2 U/L, 19.2 U/L, respectively). Moreover, VCZ serum levels remained within the therapeutic range (mean value=4.46 ± 1.09 µgr/ml) during the period of systemic VCZ therapy.

Digital images of the anterior segment of the eye were performed

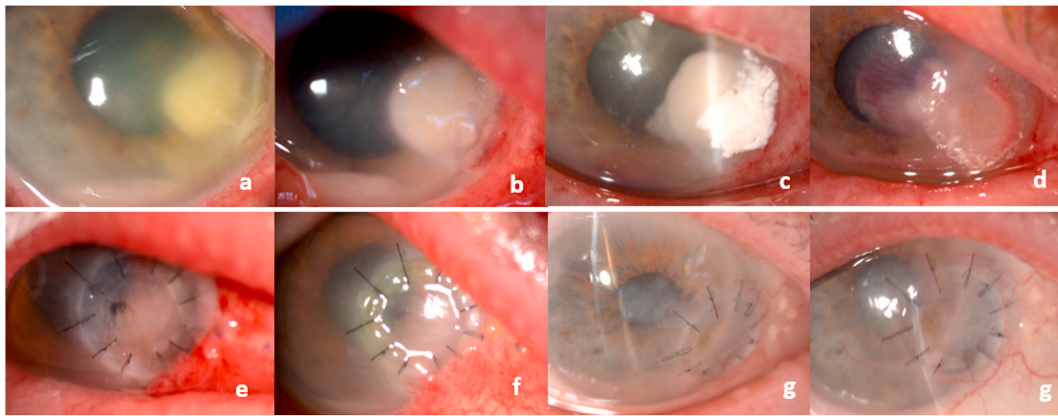


Fig. 1. Corneal ulcer progression from day +3 to day +24 (upper) and gradual resolution following surgical procedure (down). a) day +3; b) day +6; c) day +21; d) day +24 (surgery); e) day +27; f) day +33; g) day +60.

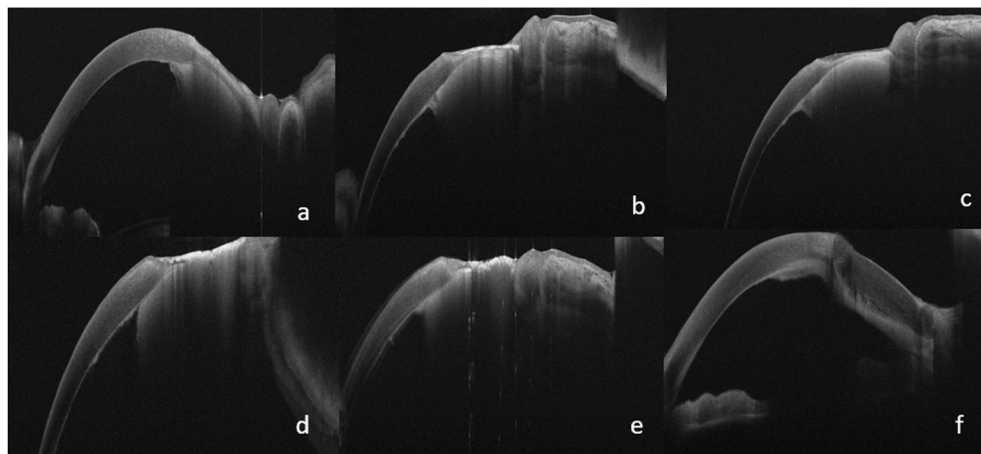


Fig. 2. AS-OCT of the cornea with worsening of corneal defect from day +6 to day +22; final picture showing resolution of corneal defect following surgery. a) day +6; b) day +9; c) day +12; d) day +17; e) day +22; f) day +30 (6 days after surgery).

using a camera connected to the slit lamp (Fig. 1). Corneal tissue was also evaluated using anterior segment optical coherence tomography (AS-OCT, MS-39, CSO, Florence, Italy) (Fig. 2).

3. Discussion

The management of FK is challenging and delays in achieving a correct diagnosis may be harmful [11]. *B. bassiana* keratitis rarely causes corneal infection, and unlike that caused by other filamentous fungi, this infection is generally limited to a superficial involvement of the cornea, without stromal infiltration or anterior chamber inflammation [12]. In this case, we encountered an endothelial plaque along with anterior chamber inflammation and *hypopyon*, usually typical of *Aspergillus* and *Fusarium* infections.

To the best of our knowledge there are no reports in literature on atypical presentations of *B. Bassiana* keratitis. Our literature search identified 17 cases of *B. Bassiana* human infection: 3 of them with systemic involvement [5] and 14 with ocular involvement, all limited to the cornea [6]. The predilection of *B. Bassiana* for corneal tissue can be explained by the fact that it produces *Chitinase*, a hydrolytic enzyme that allows its penetration into insects. Due to the similarity of insects' chitin with human corneal keratin and collagen, this enzyme allows to adhere to the corneal tissue thus invading the stroma, encouraged also by the relative immunotolerance and avascularity of the corneal tissue. Moreover, human cornea presents an ideal temperature (below 35 °C) for the growth of *B. Bassiana* [13].

In all previous papers, microbiological diagnosis of *B. Bassiana* was achieved with corneal scraping, using the specific characteristics of the fungal colonies for the identification of the species. In some recent reports, the diagnosis was confirmed by molecular biology techniques [7, 13].

In our case, the cultural examination resulted negative for fungal pathogens. This could be probably due to the fact that *B. bassiana*, differently from other filamentous fungi, shows a slow growth only after 7 days at 25 °C on Sabouraud dextrose agar, whilst at 37 °C, it either does not grow or grows with extremely difficulty.

However, despite these cultural characteristics, *B. bassiana* can only be identified with certainty by means of molecular biology techniques [14]. PCR is reported to show a higher sensitivity for infectious keratitis compared to culture (98% versus 47% respectively), but a slightly lower specificity (83% versus 100% respectively) [15]. Molecular techniques, such as ITS rDNA sequencing, have become important tools for the rapid identification of human pathological moulds.

Nevertheless, it is not always possible to obtain a definitive identification of the infectious agent, as occurred in our case report for the molecular analysis of our first clinical sample (corneal swab).

For this reason we think that a methodological culture standardization of microbiology laboratories could be useful to avoid that this filamentous fungi be considered in the “other species” class and that a more precise diagnostic identification could lead to a better final result, providing more realistic values of the incidence of *B. bassiana* keratitis.

Regarding the clinical aspect of the infection, in our case *B. bassiana*

keratitis presented with an atypical appearance with a corneal endothelial plaque and an anterior chamber reaction with hypopyon and this is not a common expression of this infectious agent. Furthermore, the limit between the edge of the plaque and those of the endothelium were not well defined, and this was noticed to be a typical aspect of filamentous keratitis [16].

The atypical nature of our case does not currently find a clear explanation. The diagnostic delay may have allowed the fungus to increase its virulence until an appropriate antifungal therapy was started. The addition of systemic VCZ enabled infection control. Systemic VCZ may be more effective in the treatment of FK because it provides more stable drug levels at the infection site [17]. In literature, some studies have confirmed the effectiveness of systemic therapy [18] and only 1 case reported successful resolution of *B. bassiana* infection with topical VCZ [19].

In our case, the systemic use of VCZ proved to be decisive, even despite the major risk of associated systemic intolerance. Therefore, we recommend the initiation of systemic VCZ therapy immediately upon diagnosis, rather than waiting for the infection to worsen. This could reduce the need for emergency surgical interventions and improved overall results.

To date, VCZ seems to have a better therapeutic activity not only in cases of *B. bassiana*, but also in the case of other filamentous fungi, and in some studies, results seem better than those achieved with natamycin 5% [20]. Topical VCZ, although it easily passes the corneal intact epithelium, carries a greater corneal toxicity risk being a galenic preparation.

Finally, regarding the surgical strategy, in our case we decided to perform a corneal patch rather than a tectonic penetrating keratoplasty due to the peripheral decentralized position of the perforated ulcer, which would have involved the execution of a large diameter transplant, with consequent greater risk of failure also due to the presence of hypopyon and corneal perforation. We expect that the patient may need further surgery to improve the visual acuity, such as a cornea transplant and cataract surgery, which will be assessed when the patient further stabilizes.

In conclusion, the diagnosis and management of *B. bassiana* keratitis is challenging. Successful infection control seems to require a timely and effective diagnostic approach, specific antifungal therapy and, where necessary, surgical intervention. From our experience molecular biology appears to be an important tool in obtaining an earlier identification of the fungus, due to its higher sensitivity. The presence of an endothelial plaque or an anterior chamber's involvement could be an expression of this infection. Finally, our case confirms the efficacy of both topical and systemic VCZ therapy for *B. bassiana* keratitis. However, due to the extreme rarity of *B. bassiana* corneal infection and the few data available in literature, it is not yet possible to suggest a standardization of *B. bassiana* keratitis management and further investigations are required to identify early diagnosis possibilities and subsequent best management.

Statement of ethics

The research was conducted ethically in accordance with the World Medical Association Declaration of Helsinki. The patient has given a written informed consent to publish the case (including publication of images).

Declaration of competing interest

The authors declare no conflict of interest.

Acknowledgements

The authors would like to thank Filippo Ferrari and Mario Sarti for cultural examinations, and Johanna Chester for her critical revision of content and editorial assistance.

References

- [1] L. Kredics, V. Narendran, C.S. Shobana, C. Vágvölgyi, P. Manikandan, Filamentous fungal infections of the cornea: a global overview of epidemiology and drug sensitivity, *Mycoses* 58 (4) (2015) 243–260.
- [2] P. Thomas, Tropical ophthalmomycoses, in: D. Seal, U. Pleyer (Eds.), *Ocular Infection*, second ed., Informa Healthcare, New York, 2007, pp. 271–305.
- [3] S.L. Watson, M.I. Cabrera-Aguas, L. Keay, P.I. Khoo, D. McCall, M.M. Lahra, The clinical and microbiological features and outcomes of fungal keratitis over 9 years in Sydney, Australia, *Mycoses* 63 (1) (2020 Jan) 43–51.
- [4] N.V. FlorCruz, J.R. Evans, Medical interventions for fungal keratitis, *Cochrane Database Syst. Rev.* 4 (2015 Apr 9), CD004241, <https://doi.org/10.1002/14651858.CD004241.pub4>.
- [5] S. Gurcan, H.M. Tugrul, Y. Yorük, B. Ozer, M. Tatman-Otkun, M. Otkun, First case report of empyema caused by *Beauveria bassiana*, *Mycoses* 49 (2006) 246–248.
- [6] L.A. Oya, M.E. Medialdea Hurtado, M.D. Rojo Martin, A. Aguilera Perez, A. Alastruey-Izquierdo, C. Miranda Casas, M. Rubio Prats, S. Medialdea Marcos, J. M. Navarro Mari, Fungal keratitis due to *Beauveria bassiana* in a contact lenses wearer and review of published reports, *Mycopathologia* 181 (9–10) (2016 Oct) 745–752.
- [7] T.J. White, T. Bruns, S. Lee, J. Taylor, Amplification and direct sequencing of fungal ribosomal RNA genes for phylogenetics, in: M.A. Innis, D.H. Gelfand, J. J. Sninsky, T.J. White (Eds.), *PCR Protocols: A Guide to Methods and Applications*, Academic Press, San Diego, CA, 1990, pp. 315–322.
- [8] I. Morales-Rodriguez, J. Yañez-Morales Mde, H.V. Silva-Rojas, G. Garcia-de-Los-Santos, D.A. Guzmán-de-Peña, Biodiversity of *Fusarium* species in Mexico associated with ear rot in maize, and their identification using a phylogenetic approach, *Mycopathologia* 163 (1) (2007 Jan) 31–39.
- [9] D. Vu, M. Groenewald, M. de Vries, T. Gehrman, B. Stielow, U. Eberhardt, et al., Large-scale generation and analysis of filamentous fungal DNA barcodes boosts coverage for kingdom fungi and reveals thresholds for fungal species and higher taxon delimitation, *Stud. Mycol.* 92 (2019 Mar) 135–154.
- [10] H. Mei, X. Hu, J. Wang, R. Wang, Y. Cai, Determination of voriconazole in human plasma by liquid chromatography-tandem mass spectrometry and its application in therapeutic drug monitoring in Chinese patients, *J. Int. Med. Res.* 48 (3) (2020 Mar), 300060519887019, <https://doi.org/10.1177/0300060519887019>. Epub2019Nov27.
- [11] M.A. Dahlgren, A. Lingappan, K.R. Wilhelmus, The clinical diagnosis of microbial keratitis, *Am. J. Ophthalmol.* 143 (2007) 940–944.
- [12] E.Y. Tu, A.J. Park, Recalcitrant *Beauveria bassiana* keratitis: confocal microscopy findings and treatment with posaconazole (Noxafil), *Cornea* 26 (8) (2007 Sep) 1008–1010.
- [13] A. Mitani, A. Shiraishi, H. Miyamoto, A. Sunada, A. Ueda, S. Asari, et al., Fungal keratitis caused by *Beauveria bassiana*: drug and temperature sensitivity profiles: a case report, *BMC Res. Notes* 7 (2014) 677.
- [14] M. Ligozzi, L. Maccacaro, M. Passilongo, E. Pedrotti, G. Marchini, R. Koncan, et al., A case of *Beauveria bassiana* keratitis confirmed by internal transcribed spacer and LSU rDNA D1–D2 sequencing, *New. Microbes. New. Infect.* 2 (2014) 84–87.
- [15] H.Y. Liu, G.C. Hopping, U. Vaidyanathan, Y.C. Ronquillo, P.C. Hoopes, M. Moshirfar, Polymerase chain reaction and its application in the diagnosis of infectious keratitis, *Med. Hypothesis, Discov. Innovation (MEHDI) Ophthalmol.* 8 (3) (2019 Fall) 152–215.
- [16] Y. Takezawa, T. Suzuki, A. Shiraishi, Observation of retrocorneal plaques in patients with infectious keratitis using anterior segment optical coherence tomography, *Cornea* 36 (10) (2017 Oct) 1237–1242.
- [17] M.A. Thiel, A.S. Zinkernagel, J. Burhenne, C. Kaufmann, W.E. Haefeli, Voriconazole concentration in human aqueous humor and plasma during topical or combined topical and systemic administration for fungal keratitis, *Antimicrob. Agents Chemother.* 51 (1) (2007 Jan) 239–244.
- [18] V.Y. Bunya, K.M. Hammersmith, C.J. Rapuano, B.D. Ayres, E.J. Cohen, Topical and oral voriconazole in the treatment of fungal keratitis, *Am. J. Ophthalmol.* 143 (1) (2007) 151–153.
- [19] A. Ogawa, Y. Matsumoto, T. Yaguchi, S. Shimmura, K. Tsubota, Successful treatment of *Beauveria bassiana* fungal keratitis with topical voriconazole, *J. Infect. Chemother.* 22 (2016) 257–260.
- [20] N.V. Prajna, T. Krishnan, J. Mascarenhas, et al., The mycotic ulcer treatment trial: a randomized trial comparing natamycin vs voriconazole, *JAMA Ophthalmol* 131 (4) (2013) 422–429.