



Clinical Manifestation and Epidemiological Finding of *Trichomonas vaginalis* Infection in Unusual Areas of Body in Neonates: A Systematic Review

Mahdiyeh Taheri¹, *Reza Ghasemikhah^{2,3}

1. Department of Reproductive Health and Midwifery, School of Nursing and Midwifery, Shabid Beheshti University of Medical Sciences, Tebran, Iran
2. Departments of Parasitology and Mycology, School of Medicine, Arak University of Medical Sciences, Arak, Iran
3. Infectious Diseases Research Center, Arak University of Medical Sciences, Arak, Iran

*Corresponding Author: Email: ghasemikhah@gmail.com

(Received 03 Mar 2021; accepted 21 Jul 2021)

Abstract

Background: This study intends to increase awareness on the clinical and laboratory diagnosis as well as health care of newborns with trichomoniasis from infected mothers, to introduce this organism as a respiratory pathogen with lower prevalence in other areas, and to outline its manifestations and symptoms.

Methods: All case report articles in English language regarding the presence of *T. vaginalis* in unusual areas among infants, which were available in Scopus, PubMed, Science Direct, Google scholar, and Web of Science published between 1980 and 2021 were searched and reported by two independent researchers. Titles and abstracts of all articles were reviewed for initial screening.

Results: After searching the articles and evaluating their quality, 9 full text articles were selected. All reported cases were from 8 different cities (4 countries) in the world. In most cases, the parasite was in the respiratory tract, but it was also reported in the brain and urogenital tract. The most common clinical symptom was respiratory distress.

Conclusion: Although the possibility of trichomoniasis infection in unusual areas such as genitals is low, according to the reports collected from around the world, this parasite can also be present outside the genitals. Perhaps, reviewing trichomoniasis along with other diagnoses in these cases may lead to early diagnosis and treatment of the affected neonates.

Keywords: *Trichomonas vaginalis*; Neonate; Neonates

Introduction

Trichomoniasis is a common, universal, and sexually transmitted urinary tract infection (1, 2) caused by a *Trichomonas vaginalis* (3). According to the WHO report in 2016, there were approximately 370 million new cases of three treatable

STIs (sexually transmitted diseases) worldwide annually, with the highest prevalence belonging to the trichomoniasis (156 million new cases), (4). Worldwide, researchers have reported a prevalence of 1.3%-16.5% of *T. vaginalis* in reproduc-



tive tract infections (5, 6). Among 15- to 59-year-olds in 2018 in the United States, the number of prevalent *T. vaginalis* infections was 2.6 million overall, 470,000 among men, and 2.1 million among women; the numbers of incident infections were 6.9 million, 3.3 million, and 3.5 million among all persons, men, and women, respectively (7). Worldwide, trichomoniasis is more common in women than in men (4). The prevalence of this infection is higher in women than men (8, 9). In addition to females, this infection is more common in non-Hispanic blacks, smokers, and socioeconomically disadvantaged groups (10, 11).

This infection is seen in women in the vagina and urethra, and in men only in the urethra (12). Most cases of trichomoniasis are asymptomatic in men and women (13), but its symptomatic cases lead to urethral discharge and dysuria in men (1, 14). Many women with trichomoniasis also develop other sexually transmitted infections, making it difficult to identify the clinical signs of trichomoniasis alone. In 50% to 70% of these cases, there is vaginal discharge, which in 10% of cases is foul-smelling (15). Twenty-five to fifty percent of affected women report vagina irritation and pruritus, and more than 50% report dyspareunia. Internal or external dysuria may also be observed. In 10% of women, there is a lower abdominal discomfort, and this, especially if accompanied by tenderness in a two-hand examination, indicates the possibility of concomitant salpingitis from other pathogens, which may be higher in the presence of HIV (15).

Since trichomoniasis is a sexually transmitted disease, there is a possibility of infection with this parasite in pregnant women. Infection during pregnancy can be associated with problems such as mother-to-child transmission during childbirth, ascending chorioamnionitis (16), premature rupture of membranes, low birth weight, and preterm labor (17).

Neonates' lungs are reported to be one of the most common unusual areas for this parasite. Evidence of respiratory complaints has been found in newborns due to trichomoniasis, including periods of bradycardia, tachycardia, apnea, rhinitis, nasal discharge and sputum, infection,

and pneumonia. In these cases, although tests for other causes of respiratory disease have been negative, in most cases trichomoniasis was randomly observed by microscopic examination of the aspirated contents of the trachea, nasal secretions, stomach contents, or in tissue cultures. In most reports, patients' respiratory status improves after metronidazole treatment, and *T. vaginalis* usually undetectable in subsequent specimens. Based on the available evidence, *T. vaginalis* should be considered as a cause of respiratory disease in infants, especially in premature infants. Modern molecular techniques are essential in the rapid and sensitive diagnosis of trichomoniasis (18).

Prevention and treatment of trichomoniasis is currently based on the drug therapy, and metronidazole is currently the most common drug used to treat trichomoniasis (19, 20). However, an increasing number of studies report the creation of drug-resistant strains and mutation of metronidazole, and shortcomings of other drugs against *T. vaginalis* (10). Over the years, significant efforts have been made to find new drugs to treat trichomonas vaginalis, but so far few drugs with high biological activity and low cytotoxicity have been found that can completely eradicate trichomoniasis (21, 22). There is also no commercial vaccine against trichomoniasis (23). All these facts demonstrate the potential of *T. vaginalis* in creating severe disease outside the urogenital tract. They also emphasize on the importance of treating this parasite during pregnancy. In addition, related studies highlight the need to re-evaluate the symptoms caused by this parasite as in most cases, only the cases of *T. vaginalis* parasite that are found in the genital tract have been studied.

We aimed to collect data and provide information on the invasion of unusual sites by this parasite, and also the symptoms, method of clinical diagnosis and treatment of trichomoniasis in neonates to increase awareness on this issue and promote the health of newborns.

Methods

A systematic review of all case report articles, published between 1980 and 2021, related to the presence of *T. vaginalis* in areas other than the genital area of neonates was performed. The reporting method of systematic studies and meta-analysis (PRISMA) was used in this study (24) in four stages of search strategy, review and analysis of systematic articles, evaluation of inclusion and exclusion criteria, and qualitative evaluation. Thus, the search for articles was conducted using the above protocol. In order to prevent bias and increase the reliability and validity of the study, three researchers simultaneously searched for articles and evaluated the quality of articles separately based on the criteria of Jadad.

All stages and strategy of the search, data collection, and qualitative data analysis were independently approved by two researchers (MT and RG) and selected articles were confirmed by the third researcher.

Inclusion and exclusion criteria

All case reports in English (1980 to 2021) that reported the parasite in unusual areas (genitals) in the body of neonates (both sexes) were included in this study. Exclusion criteria were insufficient information or lack of access to the full text of articles, irrelevant topics, reporting of unusual places in age groups other than neonates, and being published before 1980.

Search strategy

To identify related articles, two researchers (MT and RG) independently searched the online international databases. The search protocol was based on the two keywords: "Trichomonas vaginalis" and "Neonate". Advance search method was used to search for articles in databases such as Scopus, PubMed, Science Direct, and Web of science. Thus, first, the keyword: "Trichomonas vaginalis" and then "Neonate" were entered in search engine using the operator "AND", and this way, all the articles reporting abnormal sites of *T. vaginalis* in neonates were ob-

tained. In the Science Direct database, after searching for articles using the keywords, the "case report type limit" was applied to obtain only this type of articles. In the Google scholar database, the keywords were entered in the "title" space, and then all the articles found were examined until the sixth page of the search. We only searched for articles published from Jan 1980 to Jan 2021.

Data item and data extraction process

Search results were downloaded to EndNote edition version 8. After removing duplicate items, titles and abstracts of all related articles were collected as primary information for article screening. The full texts of the articles, originally considered as related articles, were made available to the researchers by removing the name of the journals and authors. Each article was independently reviewed by two researchers (MT and RG) and if the article was excluded, the reason for its exclusion was recorded. The third researcher was the final decision maker if the first two researchers did not agree on any article. In the initial search, 69 related articles were collected. Gender, age, city of residence, infected area, patient symptoms during initial examination, initial diagnosis, final diagnosis, diagnostic method and treatment were studied by reviewing the full texts of the articles and information recorded in the form of tables and graphs. Finally, due to the significant variation in study methods, the results were summarized and reported using descriptive statistics without using meta-analysis. Using CARE checklist, the qualitative evaluation of selected articles was performed in following order; title, keywords, abstract, introduction, patient information, clinical findings, timeline, evaluation and diagnostic method, therapeutic intervention, follow-up and results, discussion, patient perspective and informed consent (25).

Results

We found 102 articles and finally, 11 cases report in 9 articles, which provided information about

the patient's age and sex, the organ involved, the initial and final diagnosis, and treatment methods,

were selected for the review (Fig. 1).

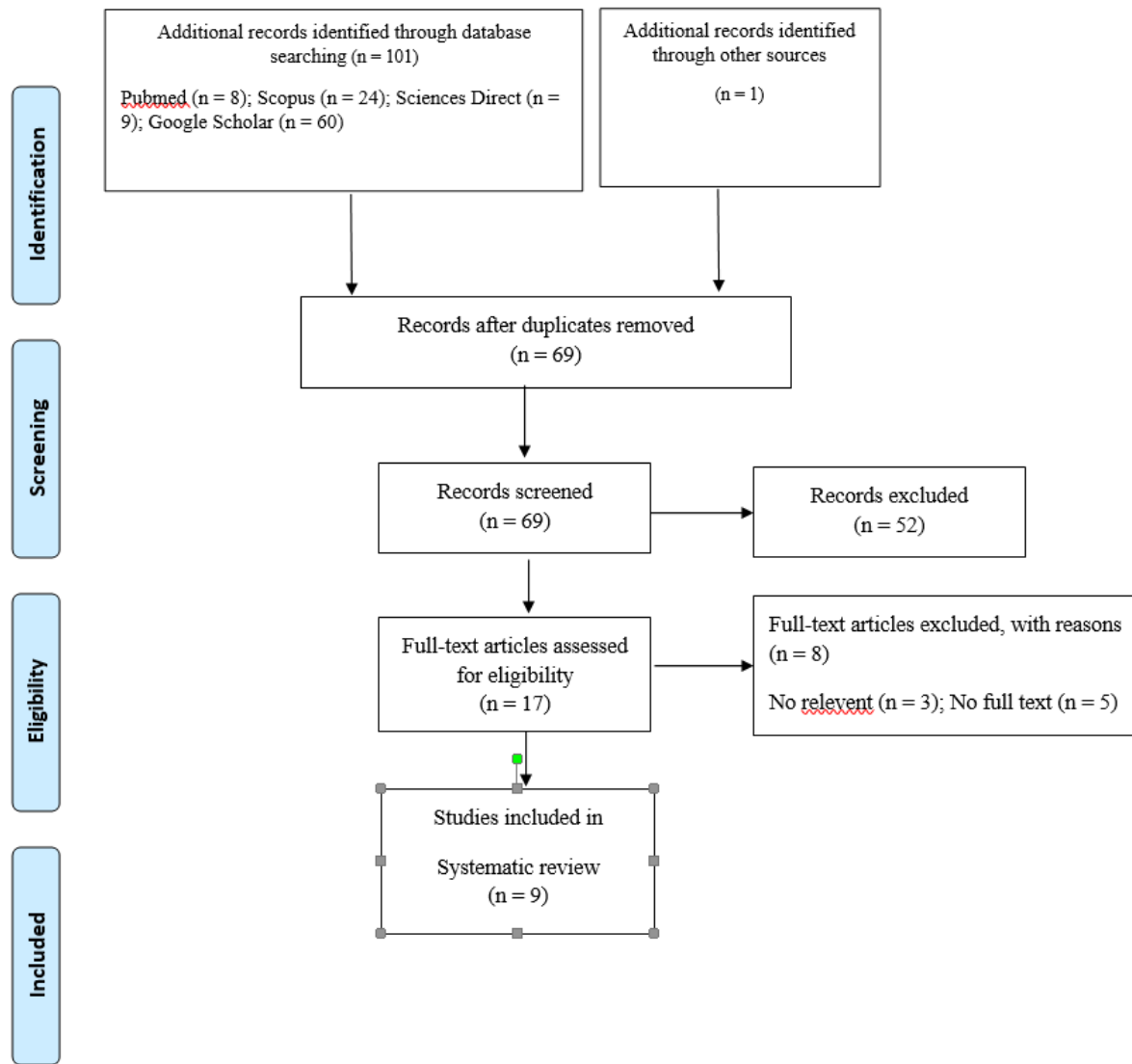


Fig. 1: Preferred reporting items for systematic reviews (PRISMA) flow diagram of the study

Clinical information about the patient's gender and age, involved organ, symptoms during the first clinical examination, initial and final diagnosis, and treatment methods are presented in Table 1.

According to the search conducted in the studies listed in Table 1, all reported cases were from 8 different cities (4 countries) in the world (Fig. 2). The most common clinical symptoms of neonates with trichomoniasis in the lung are respira-

tory distress (7 cases), tachypnea, exhaustion (2 cases each), low Apgar score, bradycardia, lethargy, poor appetite, and white and thick sputum (1 case each), respectively. The most common clinical symptoms of neonates with urinary tract trichomoniasis are, low Apgar score (2 cases), urinary tract infection and respiratory distress (1 case each), respectively.

Table 1: Specifications of reported cases of *Trichomonas vaginalis* infection in unusual location

<i>First author</i>	<i>Cities</i>	<i>Year of publication</i>	<i>Sex</i>	<i>Age</i>	<i>Unusual location</i>	<i>Symptoms at the beginning of the examination</i>	<i>Initial diagnosis</i>	<i>Specimen</i>	<i>Diagnostic method</i>
Hamilton et al (26)	Louisiana USA	2018	F	24	Brain	Hemodynamic instability, oliguria, convulsions, respiratory distress	Sepsis	CSF	Microscopic method
Bruins et al (27)	zwolle, Netherland	2013	M	25	Respiratory track	Respiratory distress, Exhaustion Bradycardia	Suspected of infection	Tracheal secretions and urine samples	PRC
Bruins et al (27)	zwolle, Netherland	2013	F	25	Respiratory track	Respiratory distress, exhaustion	-	Throat and vaginal discharge	PRC
Trintis et al, (28)	Baltimore USA	2010	F	29	Respiratory track	Respiratory distress	Chori-omni-onitis	Urine sample	Microscopic method
Carter et al, (29)	Alabama USA	2008	F	2 w*	Respiratory track	Lethargy, poor appetite, respiratory distress	-	Throat sample	Microscopic method
Hoffman et al, (30)	Pennsylvania USA	2003	F	27	Urinary tract	Low Apgar score, urinary tract infection	Sepsis	Urine sample	Microscopic method
Smith et al, (31)	Los angeles, USA	2003	F	24	Urinary tract	Low Apgar score, respiratory distress	Sepsis	Urine culture	Microscopic culture
Temesvari et al (32)	Kecskmét, hungary	2002	F	33	Respiratory track	Tachypnea, respiratory distress	-	Tracheal and stomach secretion	Microscopic method
Temesvari et al (32)	Kecskmét, hungary	2002	M	35	Respiratory track	Tachypnea, respiratory distress	-	Tracheal and stomach secretion	Microscopic method
Danesh et al, (33)	LA, USA	1995	F	2 w*	Vagina	Constipation, vaginal discharge	-	Vaginal discharge	Microscopic culture

The clinical symptoms observed in neonates with trichomoniasis in the brain include respiratory distress, oliguria, seizures, and hemodynamic in-

stability. The clinical symptoms observed in neonates with trichomoniasis in the vagina include vaginal discharge and constipation. The most

common unusual site of infection caused by *T. vaginalis* the airways (64%), as well as the urinary tract (18%), brain (9%), and vagina (9%), respectively. The most common diagnostic tests used for *T. vaginalis* are the tracheal specimens (4 cases),

urine specimens (3 cases), pharyngeal specimens (2 cases), urine culture and cerebrospinal fluid (1 case each), respectively.

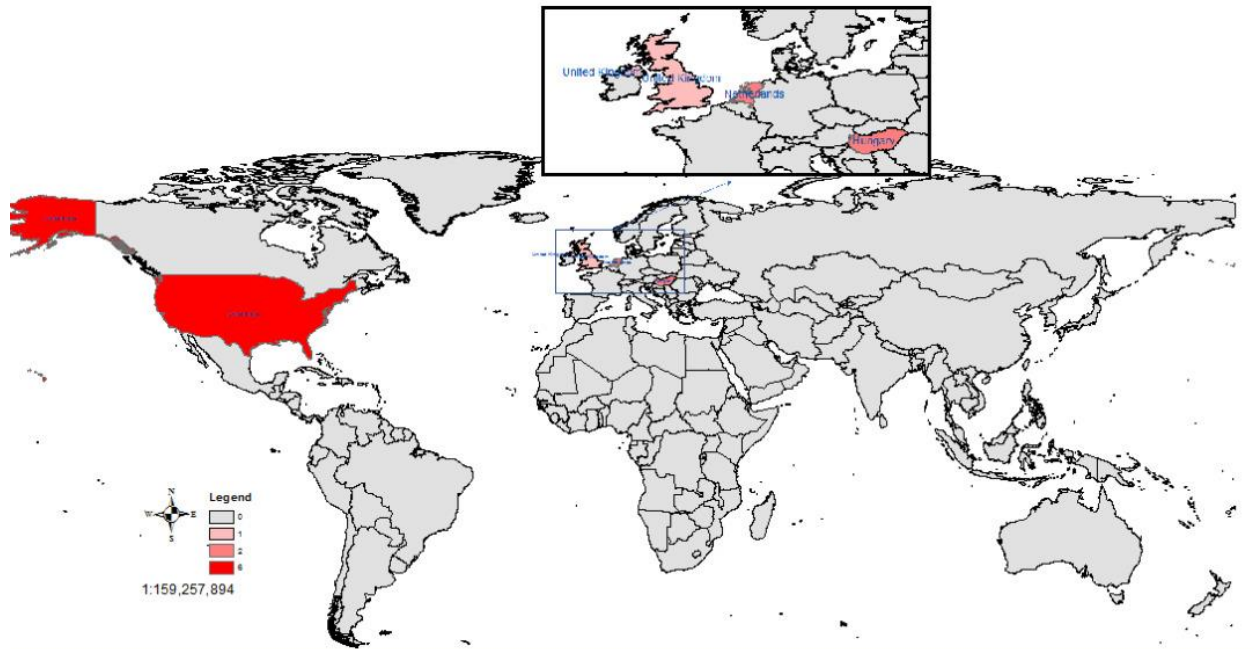


Fig. 2: Cases of neonate contamination with trichomoniasis in different countries

Nine of the neonates reported in these studies were born as preterm (37 wk before delivery) and only two were born as term. In all reported neonates with trichomoniasis, metronidazole alone was used for treatment in 9 of the cases, and in one case, metronidazole was used in combination with vancomycin and cefotaxime and later, ampicillin and tobramycin were used. In 6 cases, the infant was first treated according to another initial diagnosis. For instance in 4 cases, the initial diagnosis of sepsis was made for the infant, and in the other two cases, the initial diagnosis of chorioamnionitis and meningitis was made. This can be used as a good guide for diagnosing physicians.

Discussion

Pregnant women with trichomoniasis rarely transmit the infection to their baby during vaginal delivery. Therefore, the newborns of infected mothers may become infected during childbirth (34). Infection with this parasite in neonates varies from asymptomatic to severe disease (1). Typically, neonates born to infected mothers are asymptomatic, but may weigh less or experience self-limiting vaginitis with severe vaginal discharge (35), because the parasite is usually seen in the vaginal areas of neonates (8 and 9). Sometimes, vaginitis in the newborns of mothers with vaginitis caused by *T. vaginalis* require antimicrobial treatment (26). Presence of infection in areas other than urogenital area are generally uncommon (18), but rare cases of the parasite have been

reported in other areas such as lungs, cerebrospinal fluid, perinephric abscess, and brain abscess (12, 14, 26).

In a study, nine cases of *T. vaginalis* in the respiratory tract were reported (five in neonates, one in infant, two in adults, and one unspecified). In this study, the presence of this parasite in three of the neonates led to respiratory distress and in two cases, to pneumonia. This finding is in line with present study in which, respiratory distress was the most common symptom in neonates with trichomoniasis in the lungs. Moreover, in most common case (4 cases) in above study, the specimen taken from neonates was a tracheal specimen, which is also consistent with the present study, and of course in one case, the parasite of *T. vaginalis* was observed in the nasopharyngeal secretion. Another important point in the above study is that, 4 of the mentioned neonates were born as preterm, which is in line with the present study. In this study, in three cases of neonates, only metronidazole was used for the treatment and in one case, metronidazole was used in combination with ampicillin and in another case only ampicillin and tobramycin were used for the treatment (29).

Despite the small number of cases, it is clear that *T. vaginalis* parasite can survive outside the genital tract and, in the most common form, can cause respiratory distress, or be asymptomatic. Apparently, the neonates become infected when passing through birth canal during delivery. In all cases in this study, the method of delivery was NVD in 7 cases, cesarean section in one case, and unknown in two cases. It does not appear to be a specific risk factor for *T. vaginalis* infection of the respiratory tract.

Conclusion

T. vaginalis parasite is most likely to be present in the lungs of neonates and then, in their urinary tract, brain and vagina, respectively. Moreover, the most common clinical symptom of this infection is respiratory distress. In the reviewed studies, most of the affected neonates were preterm

and born by vaginal delivery, and the most common sampling site for the parasite was tracheal and pharyngeal secretion, also associated with trichomoniasis infection. For example, in people with urinary tract infections, the parasite is present in the urine sample, and in infants with brain abscess, the parasite is present in cerebrospinal fluid (CSF). Moreover, in neonates with trichomoniasis, the parasite is seen in vaginal discharge. This study points to the importance of treating trichomoniasis in mothers to prevent the infection in neonates. It also introduces the *T. vaginalis* parasite as a causative agent of infection in infants/neonates, as well as its symptoms and the organs that the parasite may infect. The results of this study can be used for early diagnosis of pregnant women and treatment of trichomonas vaginalis.

Journalism Ethics considerations

Ethical issues (Including plagiarism, informed consent, misconduct, data fabrication and/or falsification, double publication and/or submission, redundancy, etc.) have been completely observed by the authors.

Acknowledgements

The authors of this study would like to thank the Infectious Diseases Research Center of Arak University of Medical Sciences for their help and support.

Conflict of interest

The authors declare that they have no competing interests.

References

1. Meites E, Gaydos CA, Hobbs MM, et al (2015). A Review of Evidence-Based Care of Symptomatic Trichomoniasis and Asymptomatic *Trichomonas vaginalis* Infections. *Clin Infect Dis*, 61 Suppl 8(Suppl 8):S837-48.

2. Oliveira AS, Ferrão AR, Pereira FM, Martinez-de-Oliveira J, Palmeira-de-Oliveira A (2016). *Trichomonas vaginalis*: An Updated Overview towards Diagnostic Improvement. *Acta Parasitol*, 61(1):10-21.
3. Cosentino LA, Campbell T, Jett A, Macio I, Zamborsky T, Cranston RD, Hillier SL (2012). Use of nucleic acid amplification testing for diagnosis of anorectal sexually transmitted infections. *J Clin Microbiol*, 50 (6):2005-8.
4. Rowley J, Vander Hoorn S, Korenromp E, et al (2019). Chlamydia, gonorrhoea, trichomoniasis and syphilis: global prevalence and incidence estimates, 2016. *Bull World Health Organ*, 97(8):548- 62.
5. Anh PK, Khanh NT, Ha DT, et al (2003). Prevalence of lower genital tract infection among women attending maternal and child health and family planning clinics in Hanoi, Vietnam. *Southeast Asian J Trop Med Public Health*, 34(2):367-73.
6. García PJ, Chavez S, Feringa B, Chiappe M, Li W, Jansen KU, Cárcamo C, Holmes KK (2004). Reproductive tract infections in rural women from the highlands, jungle, and coastal regions of Peru. *Bull World Health Organ*, 82(7):483-92.
7. Lewis FMT, Spicknall IH, Flagg EW, Papp JR, Kreisel KM (2021). Incidence and Prevalence of *Trichomonas vaginalis* Infection among Persons Aged 15 to 59 Years: United States, 2018. *Sex Transm Dis*, 48(4):232-237.
8. Silver BJ, Guy RJ, Kaldor JM, Jamil MS, Rumbold AR (2014). *Trichomonas vaginalis* as a cause of perinatal morbidity: a systematic review and meta-analysis. *Sex Transm Dis*, 41(6):369-76.
9. Cotch MF, Pastorek JG 2nd, Nugent RP, et al (1997). *Trichomonas vaginalis* associated with low birth weight and preterm delivery. The Vaginal Infections and Prematurity Study Group. *Sex Transm Dis*, 24(6):353-60.
10. Tompkins EL, Beltran TA, Gelner EJ, Farmer AR (2020). Prevalence and risk factors for *Trichomonas vaginalis* infection among adults in the U.S., 2013-2014. *PLoS One*, 15(6):e0234704.
11. Ambrozio CL, Nagel AS, Jeske S, Bragança GC, Borsuk S, Villela MM (2016). *Trichomonas vaginalis* prevalence and risk factors for women in southern Brazil. *Rev Inst Med Trop Sao Paulo*, 22;58:61.
12. Ifeanyi OE, Chinedum OK, Chijioko UO (2018). *Trichomonas vaginalis*: complications and treatment. *Int J Curr Res Med Sci*, 10.
13. Patel EU, Gaydos CA, Packman ZR, Quinn TC, Tobian AAR (2018). Prevalence and Correlates of *Trichomonas vaginalis* Infection among Men and Women in the United States. *Clin Infect Dis*, 2;67(2):211-217.
14. Van Der Pol B (2016). Clinical and Laboratory Testing for *Trichomonas vaginalis* Infection. *J Clin Microbiol*, 54(1):7-12.
15. Kissinger P, Adamski A (2013). Trichomoniasis and HIV interactions: a review. *Sex Transm Infect*, 89(6):426-33.
16. Otgonjargala B, Becker K, Batbaatar G, et al (2017). Effect of Mycoplasma hominis and cytomegalovirus infection on pregnancy outcome: A prospective study of 200 Mongolian women and their newborns. *PLoS One*, 3;12(3):e0173283.
17. Nas FS, Yahaya A, Muazu L, Halliru SAN, Ali M (2020). Prevalence of *Trichomonas vaginalis* among pregnant women attending ante-natal care in Kano, Nigeria *Eur J Med Health Sci*, 2(2), 39-45.
18. Martínez-Girón R, Esteban JG, Ribas A, Doganci L (2008). Protozoa in respiratory pathology: a review. *Eur Respir J*, 32(5):1354-70.
19. Graves KJ, Ghosh AP, Schmidt N, et al (2019). *Trichomonas vaginalis* virus among women with trichomoniasis and associations with demographics, clinical outcomes, and metronidazole resistance. *Clin Infect Dis*, 69(12):2170-6.
20. Rigo GV, Petro-Silveira B, Devereux M, McCann M, Dos Santos AL, Tasca T (2019). Anti-*Trichomonas vaginalis* activity of 1, 10-phenanthroline-5, 6-dione-based metallodrugs and synergistic effect with metronidazole. *Parasitology*, 146(9):1179-83.
21. Mendoza-Oliveros T, Arana-Argáez V, Alvaréz-Sánchez LC, et al (2019). Immune response of BALB/c mice toward putative calcium transporter recombinant protein of *Trichomonas vaginalis*. *Korean J Parasitol*, 57(1):33.
22. Mirasol-Meléndez E, Brieba LG, Díaz-Quezada C, et al (2018). Characterization of multiple enolase genes from *Trichomonas vaginalis*. Potential novel targets for drug and vaccine design. *Parasitol Int*, 67(4):444-453.

23. Zhang Z, Li Y, Wang S, et al (2020). The Molecular Characterization and Immunity Identification of *Trichomonas vaginalis* Adhesion Protein 33 (AP33). *Front Microbiol*, 11:1433.
24. Moher D, Liberati A, Tetzlaff J, Altman DG; PRISMA Group (2009). Preferred reporting items for systematic reviews and meta-analyses: the PRISMA statement. *PLoS Med*, 6(7):e1000097.
25. Riley D S, Barber M S, Kienle G S, et al (2017). CARE guidelines for case reports: explanation and elaboration document. *J Clin Epidemiol*, 89:218-235.
26. Hamilton H, Pontiff KL, Bolton M, et al (2018). *Trichomonas vaginalis* Brain Abscess in a Neonate. *Clin Infect Dis*, 66(4):604-607.
27. Bruins MJ, van Straaten IL, Ruijs GJ (2013). Respiratory disease and *Trichomonas vaginalis* in premature newborn twins. *Pediatr Infect Dis J*, 32(9):1029-30.
28. Trintis J, Epie N, Boss R, Riedel S (2010). Neonatal *Trichomonas vaginalis* infection: a case report and review of literature. *Int J STD AIDS*, 21(8):606-7.
29. Carter JE, Whithaus KC (2008). Neonatal respiratory tract involvement by *Trichomonas vaginalis*: a case report and review of the literature. *Am J Trop Med Hyg*, 78(1):17-9.
30. Hoffman DJ, Brown GD, Wirth FH, Gebert BS, Bailey CL, Anday EK (2003). Urinary tract infection with *Trichomonas vaginalis* in a premature newborn infant and the development of chronic lung disease. *J Perinatol*, 23(1):59-61.
31. Smith LM, Wang M, Zangwill K, Yeh S (2002). *Trichomonas vaginalis* infection in a premature newborn. *J Perinatol*, 22(6):502-3.
32. Temesvári P, Kerekes A, Tege A, Szarka K (2002). Demonstration of *Trichomonas vaginalis* in tracheal aspirates in infants with early respiratory failure. *J Matern Fetal Neonatal Med*, 11(5):347-9.
33. Danesh IS, Stephen JM, Gorbach J (1995). Neonatal *Trichomonas vaginalis* infection. *J Emerg Med*, 13(1):51-4.
34. Hiemstra I, Van Bel F, Berger HM (1984). Can *Trichomonas vaginalis* cause pneumonia in newborn babies? *Br Med J (Clin Res Ed)*, 289(6441):355-6.
35. Wynn A, Ramogola-Masire D, Gaolebale P, et al (2018). Prevalence and treatment outcomes of routine *Chlamydia trachomatis*, *Neisseria gonorrhoeae* and *Trichomonas vaginalis* testing during antenatal care, Gaborone, Botswana. *Sex Transm Infect*, 94(3):230-235.