

## Review Article

# A Review of the Phenotype of Synpolydactyly Type 1 in Homozygous Patients: Defining the Relatively Long and Medially Deviated Big Toe with/without Cupping of the Forefoot as a Pathognomonic Feature in the Phenotype

Mohammad M. Al-Qattan 

*Division of Plastic and Hand Surgery, Department of Surgery at King Saud University, Riyadh, Saudi Arabia*

Correspondence should be addressed to Mohammad M. Al-Qattan; moqattan@hotmail.com

Received 18 January 2020; Accepted 2 May 2020; Published 16 May 2020

Academic Editor: Przemko Tylzanowski

Copyright © 2020 Mohammad M. Al-Qattan. This is an open access article distributed under the Creative Commons Attribution License, which permits unrestricted use, distribution, and reproduction in any medium, provided the original work is properly cited.

Synpolydactyly type 1 (SPD1, OMIM 186000) is inherited as autosomal dominant and is caused by *HOXD13* mutations. The condition is rare and is known for its phenotypic heterogeneity. In the homozygous state, the phenotype is generally more severe and is characterized by three main features: a more severe degree of syndactyly, a more severe degree of brachydactyly, and the frequent loss of the normal tubular shape of the metacarpals/metatarsals. Due to the phenotypic heterogeneity and the phenotypic overlap with other types of syndactyly, no pathognomonic feature has been described for the homozygous phenotype of SPD1. In the current communication, the author reviews the literature on the phenotypes of SPD1 in homozygous patients. The review documents that not all homozygous patients show a severe hand phenotype. The review also defines the “relatively long and medially deviated big toe with/without cupping of the forefoot” as a pathognomonic feature in the phenotype. Illustration of this feature is done through a demonstrative clinical report in a multigeneration family with SPD1 and *HOXD13* polyalanine repeat expansion. Finally, the pathogenesis of the clinical features is reviewed.

## 1. Introduction

Synpolydactyly type 1 (SPD1) is inherited as autosomal dominant and is caused by *HOXD13* mutations. It has also been given other names such as syndactyly type IIA and the Vordingborg syndactyly [1]. In the heterozygous state, classic hand features include fusion of the third and fourth fingers with duplication within the syndactylous web. In the feet, there is classically cutaneous webbing of the fourth and fifth toes. In the homozygous state, the phenotype is generally more severe and this was reviewed by Malik and Grzeschik [2] and Al-Qattan [3]. Malik and Grzeschik [2] stressed on the extreme phenotypic heterogeneity in SPD1 and classified the clinical variants into three categories according to the degree of severity of the phenotype: heterozygous patients showing a very mild phenotype (frequently, clinodactyly or camptodactyly of the little finger is the only manifestation

of the gene mutation), patients with classic SPD1 features (usually seen in heterozygous patients but may be seen in homozygous patients), and homozygous patients with severe phenotypes. Al-Qattan [3] stressed on the three main features of the homozygous phenotype: syndactyly frequently involves the postaxial three or four digits, a more severe degree of concurrent brachydactyly, and the frequent loss of the normal tubular shapes of the metacarpals/metatarsals (they may become polygonal in shape; and in some cases, they attain the shape of the carpal/tarsal bones). However, these severe features are not always seen in every homozygous patient. Due to the phenotypic heterogeneity and the phenotypic overlap with other types of syndactyly, no pathognomonic feature has been described for the homozygous phenotype of SPD1.

In the current communication, the author reviews the literature on the phenotype of SPD1 in homozygous patients

TABLE 1: A summary of the phenotypes in the heterozygous parents and their homozygous children in previously reported families with SPD1 caused by *HOXD13* polyalanine repeat expansions.

Authors	The phenotype in the heterozygous parents	1—syndactyly	2—brachydactyly	3—the shapes of metacarpals/metatarsals	4—the big toe sign	5—cupping of the forefeet
Akarsu et al. [8]; Akarsu et al. [9]	Mild or classic SPD1 phenotype in the hands and feet. Some parents had no abnormalities (i.e., nonpenetrant)	Involved the postaxial 3-4 digits in the hands and feet	Moderate to severe in the hands, mild to moderate in the feet	Short broad metacarpals	Yes	Yes
Muragaki et al. [12]	Classic phenotypes in the hands and feet	Involved the postaxial 3 digits in the hands	Moderate and more pronounced in the middle phalanges of the fingers and toes	Polygonal metacarpals, short broad second metatarsals, replacement of metatarsals III-IV with a single tarsal-like bone	Yes	No
Horsnell et al. [10]	Classic phenotypes in the hands and feet	Involved the postaxial 3 digits in the hands and feet	Moderate and more pronounced in the middle phalanges of the fingers and toes	Broad or polygonal metacarpals. The metatarsals were relatively preserved	Yes	No
3 et al. (2007)	Classic or mild phenotype. Some had a mild phenotype (with normal feet). Partial duplication of the first metatarsal was also seen	Involved the postaxial 3 digits in the hands and feet	Moderate and more pronounced in the middle phalanges of the fingers and toes	Broad or polygonal metacarpals. The metatarsals were relatively preserved	Yes	No

TABLE 2: A summary of the phenotypes in the heterozygous parents and their homozygous children in previously reported families with SPD1 caused by *HOXD13* missense and truncating mutations.

Mutations in <i>HOXD13</i> (authors)	The heterozygous parents	1—syndactyly	2—brachydactyly	3—the shapes of metacarpals/metatarsals	4—the big toe sign	5—cupping of the forefeet
G11A (missense at the N-terminus) [7]	Very mild phenotype: bilateral little finger camptodactyly, brachydactyly of the 4 <sup>th</sup> and 5 <sup>th</sup> toes	Classic SPD1 (digits 3-4 in the hands and digits 4-5 in the feet)	Mild in the hands and feet, more pronounced in the middle phalanges	Some metacarpals were slightly broad. The metatarsals were preserved	Yes	Yes
T313R (missense at the DNA-binding domain) [4]	No abnormalities (i.e., nonpenetrance)	One hand had no syndactyly; the other hand had digits 3-4 syndactyly. Both feet had cutaneous syndactyly of the middle 3 toes	Moderate in the hands and feet, more pronounced in the middle phalanges	Metacarpal-to-carpal transformation. The metatarsals were broad or polygonal	Yes	Yes
Q248X (nonsense) [14]	Very mild phenotype (isolated little finger clinodactyly) or classic SPD1 phenotype	Usually involved the middle, ring, and little fingers in the hands. Variable in the feet but frequently involved the postaxial 4 toes	Moderate in the hands and mild in the feet	Preserved	Yes	Yes

TABLE 3: A summary of the phenotypes in the heterozygous parents and their homozygous child of the family reported in the current review.

	The heterozygous mother	The heterozygous father	The homozygous child
The hands	Classic SPD1 hand phenotype: isolated syndyactyly of the middle and ring fingers	Classic SPD1 hand phenotype: isolated syndyactyly of the middle and ring fingers	Syndyactyly involved all fingers in the right hand and the postaxial 3 fingers in the left hand. Cupping of the right hand was noted. There was metacarpal-to-carpal transformation bilaterally.
The feet	No abnormalities	Classic SPD1 foot phenotype: webbing of the 4 <sup>th</sup> and 5 <sup>th</sup> toes in the left foot. Bilateral little toe brachydactyly was also present	The big toes were relatively long and medially deviated. Cupping of the forefeet was also noted bilaterally leading to plantar flexion deformity of the toes. Cutaneous syndactyly was seen between the 3 <sup>rd</sup> and 4 <sup>th</sup> toes bilaterally. X-rays showed metatarsal-to-tarsal transformation bilaterally.

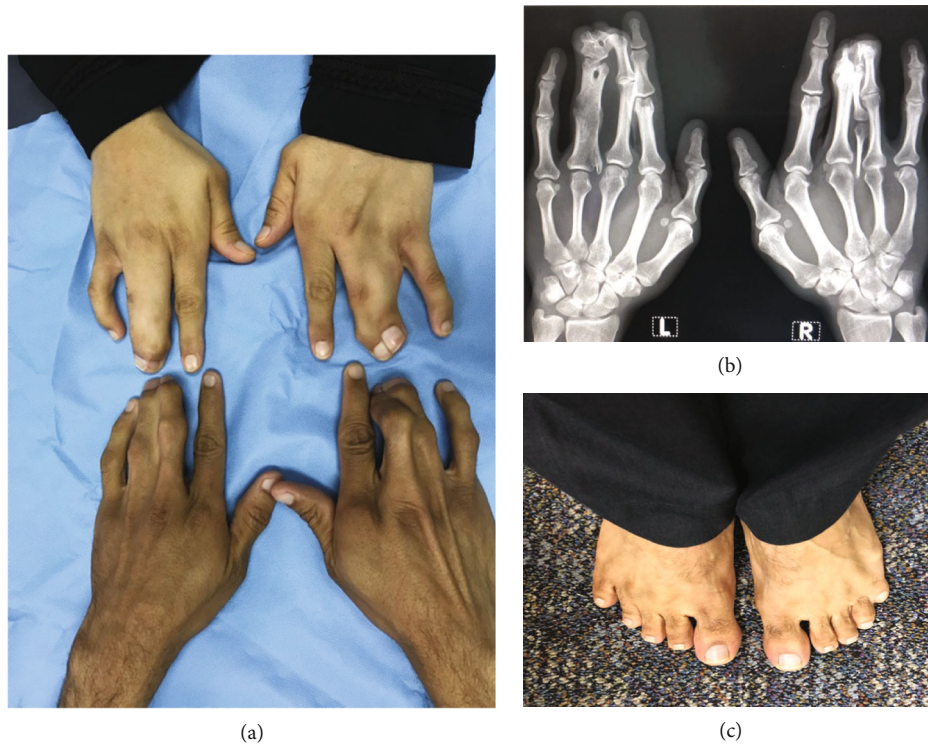


FIGURE 1: The phenotypes in the heterozygous parents: (a) the hands of the mother (above) and father (below) showing synpolydactyly of the third and fourth digits; (b) X-ray of the hands of the father showing the duplication within syndactyly; (c) the feet of the father showing bilateral little toe brachydactyly and webbing between the 4th and 5th toes in the left foot.

and defines the “relatively long and medially deviated big toe with/without cupping of the forefoot” as a pathognomonic feature of the phenotype. Illustration of this feature is done by a demonstrative clinical report. Finally, the pathogenesis of the clinical features is reviewed.

*1.1. A Review of the Different HOXD13 Mutations Associated with SPD1.* The *HOXD13* gene codes for a protein with 343 amino acids. The protein normally carries a 15-amino acid polyalanine repeat in the N-terminus, while the DNA-binding homeodomain is at the C-terminus [4]. Three types of *HOXD13* mutations have been associated with SPD1: expansions of the N-terminal polyalanine repeat, missense mutations at either the N- or C-terminus, and putative null or loss-of-function mutations (such as the nonsense mutations) [4]. Alterations in function with these mutations have also been studied. Polyalanine repeat expansions result in cytoplasmic aggregation of the mutant *HOXD13* protein [5]. The degree of aggregation is influenced by the length of the repeat, and hence, there is a correlation between the *HOXD13* expansion size and the severity of the phenotype [6]. Missense mutations at the N-terminus result in a reduction in the half-life of the mutant *HOXD13* protein; and experimentally, there is interference with Gli3R function during limb pre patterning [7]. Missense mutations at the C-terminus prevent binding to the DNA-binding domain [4]. Finally, truncating mutations result in loss-of-function.

*1.2. A Review of Previously Reported Families with SPD1 and Homozygous Patients.* Tables 1 and 2 summarize the phenotype of all previously reported families with homozygous patients. There were four families with polyalanine repeat expansions [8–12]. The phenotype in the heterozygous parents varied from a very mild phenotype (such as isolated clinodactyly of the little finger) to the classic phenotype described in the introduction. Homozygous patients had a more severe syndactyly involving the postaxial 3 fingers/toes, a variable degree of brachydactyly, and the loss of the normal tubular shape of metacarpals/metatarsals. Brachydactyly was more pronounced in the postaxial digits and mostly affected the middle phalanges; and in some cases, the middle phalanx was absent. In all homozygous patients, the big toe was relatively long and medially deviated. Cupping of the forefoot (leading to plantar flexion of the postaxial toes) was not seen in all homozygous patients. It is important to note that the big toe/forefoot feature was not specifically mentioned by the authors; but the feature was clear in the illustrations.

There were two families with missense mutations [4, 7] and one family with a truncating nonsense mutation [13]. The phenotypes in these 3 families are summarized in Table 2. All heterozygous parents were either normal (i.e., with nonpenetrance) or with a very mild phenotype (such as isolated camptodactyly of the little finger). The phenotype in homozygous patients was more severe, and all patients had the big toe/forefoot cupping feature. Once again, this



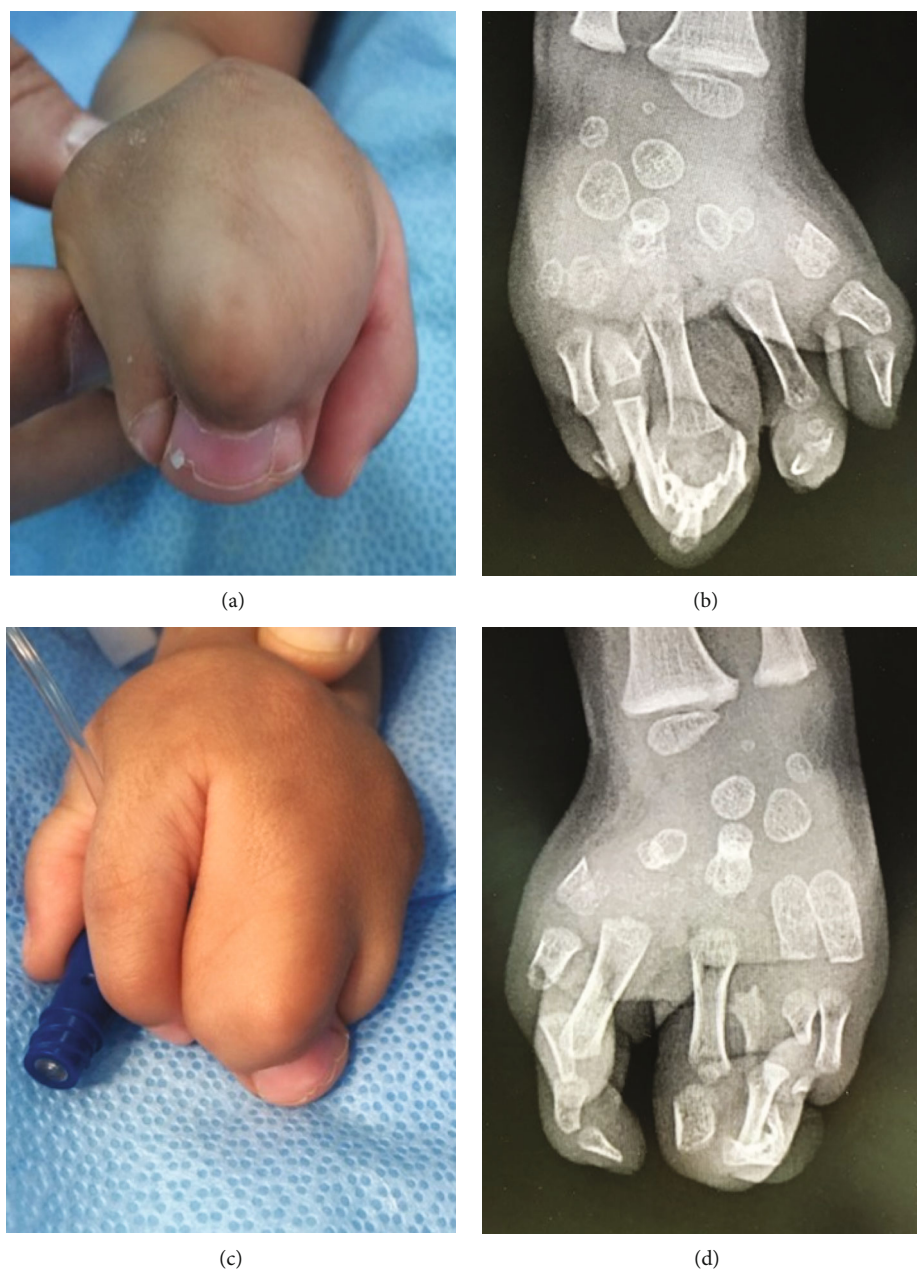


FIGURE 2: The hands of the homozygous child: (a) clinical appearance of the right hand showing syndactyly of all fingers and “cupping” of the hand; (b) X-ray of the right hand (after surgical separation of the index finger). Note that the metacarpals have attained the shape of carpal bones; (c) clinical appearance of the left hand showing syndactyly of the middle, ring, and little fingers; (d) X-ray of the left hand also showing a metacarpal-to-carpal transformation.

pathognomonic feature was noted by the current author from the illustrations; and the feature was not specifically mentioned by the authors of these reports. The phenotype in the homozygous patient described by Ibrahim et al. [4] illustrated the significant variation of the well-known phenotypic characteristics of homozygous patients. Hand syndactyly was mild in that homozygous patient (one hand had no syndactyly, and the other hand had syndactyly of the 3rd web without polydactyly). In contrast, the degree of loss of the normal shape of the metacarpals in the same patient was severe; and metacarpals attained the shape of carpal bones [4]. This demonstrated that the three characteristic

features of the homozygous phenotype (as described by [3]) may not all be present in every patient. In fact, all three features may be lacking in homozygous patients. For example, syndactyly, brachydactyly, and shape changes of the metacarpals/metatarsals were all mild in the homozygous patients reported by Brison et al. [7].

*1.3. A Demonstrative Clinical Report.* The family of the index patient is a multigeneration family with features of SPD1. The parents are affected first cousins with classic features of SPD1 (Table 3, Figure 1). The parents never had surgical correction of their deformities. Their boy had a severe

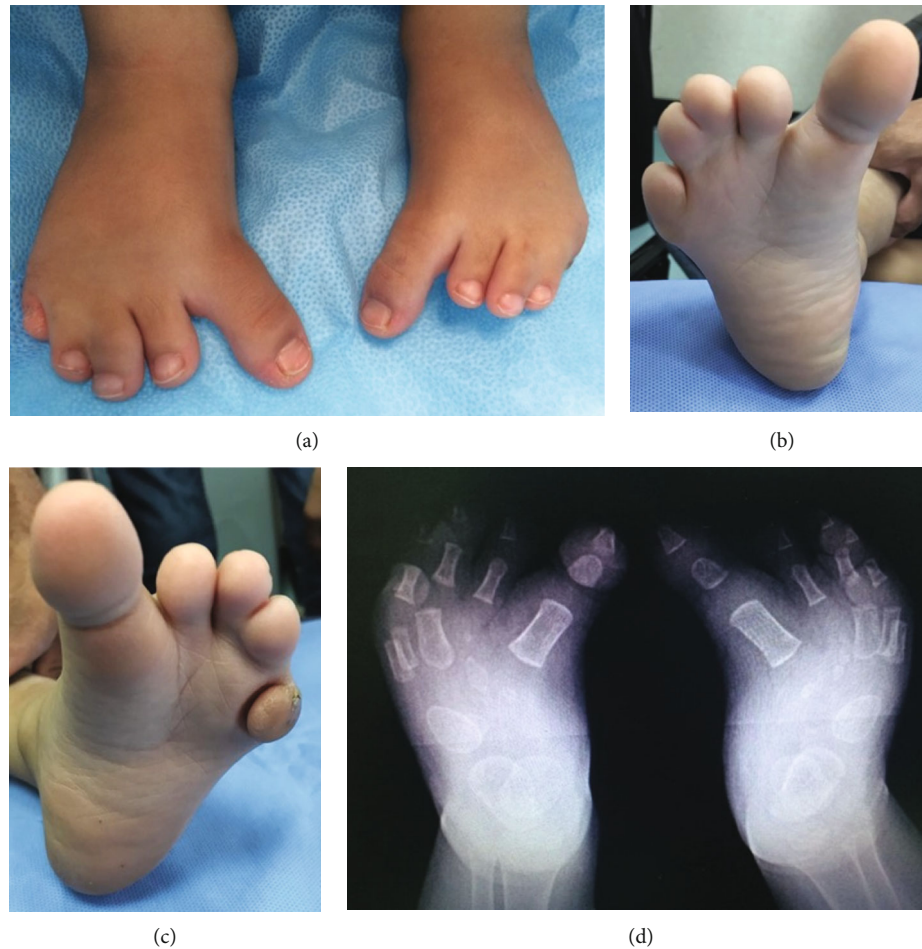

FIGURE 3: The feet of the homozygous child: (a) note the relatively long and medially deviated big toes. Also, note the plantar flexion deformity of the postaxial four toes; (b) cupping of the forefoot on the right; (c) cupping of the forefoot on the left; (d) X-rays of the feet. Note the metatarsal-to-tarsal transformation.

phenotype, and the parents presented the child to the author requesting surgical correction of his deformities. The pregnancy was uneventful. Anthropometric measurements revealed normal stature, weight, and head circumference. Systemic examination showed no abnormalities, and ultrasound of the abdomen was normal. All abnormalities were confirmed to the hands and feet. His phenotype is summarized in Table 3 and Figures 2 and 3. Relatively long and medially deviated big toes and cupping of forefeet (leading to plantar flexion deformities of the lateral four toes) were noted bilaterally (Figure 3).

Venous blood samples were obtained from the parents and child after a written informed consent. Whole-exome sequencing (CentoXome GOLD®) was performed. The index case was found to be homozygous and the parents were found to be heterozygous for the following variant in the *HOXD13* gene: c.209\_210insGGCTGCGGCGGCGGCA GCGGC p.(Ala65\_Ala71dup) which is an in-frame insertion of 21 bps in exon 1, which causes the duplication of 7 residues. The variant has been confirmed by Sanger sequencing. It is classified as pathogenic (class 1) according to the recom-

mendations of Centogene and ACMG. Kjaer et al. [14] reported this variant as disease-causing for SPD1 in one large family with segregation.

*1.4. A Review of the Pathogenesis of the Clinical Features of the Homozygous Phenotype.* This will be discussed separately for syndactyly. The pathogenesis of brachydactyly, shape changes for the metacarpals/metatarsals, and the big toe pathognomonic feature will be grouped together since these features have the same pathogenesis.

*1.5. How Does a Defective HOXD13 Protein Cause Syndactyly?* The author has previously offered a 3-step unified pathway of pathogenesis for syndactyly [15]. In the first step, there is either the overactivation of the WNT canonical pathway or the suppression of the bone morphogenetic protein canonical pathway. This leads to an overexpression of fibroblast growth factor 8, which is considered the second step. The final and third step is the suppression of retinoic acid in the interdigital mesenchyme leading to suppression of both apoptosis and extracellular matrix degradation and

hence resulting in syndactyly. A defective HOXD13 acts on the third step because experimental models have shown that the mutated *Hoxd13* has a direct suppressive effect on retinoic acid in the autopod [16]. Hence, the homozygous phenotype is expected to have a more severe syndactyly.

*1.6. The Pathogenesis of Brachydactyly, Shape Changes for the Metacarpals/Metatarsals, and the Big Toe Pathognomonic Feature.* The expression of HOXD13 in the digital zones during development has a major influence on the length of bones within the digital rays [17]. As the expression of HOXD13 decreases, the degree of brachydactyly increases. Hence, brachydactyly in homozygous patients is expected to be more severe than in heterozygous patients. Other heterozygous mutations of *HOXD13* cause isolated brachydactyly such as brachydactyly type E (OMIM113300), and the reason for this is unclear.

The big toe is the preaxial digit in the foot; and our review shows that there is relative preservation of the length of the big toes in the homozygous SPD1 phenotype. It is important to note that the length of the big toe is normal, but it appears relatively long compared to the brachydactylous postaxial toes. This may be explained by the well-known distribution of HOXD13 activities within the autopod. HOXD13 has the lowest expression in the preaxial digit compared to other digits [18]. In contrast, *HOXA13* is highly expressed in the preaxial digit and influences its development and length. In mice, *Hoxa13* loss of function results in the lack of formation of all preaxial digits [19]. In humans, mutations in *HOXA13* cause the hand-foot-uterus syndrome (OMIM 140000) which typically presents with short thumbs and big toes [20]. Hence, the degree of brachydactyly associated with a defective HOXD13 protein is expected to be less pronounced in the preaxial digit because of an undisturbed *HOXA13*.

The mesopod (the area of carpal bones) normally has no HOXD13 expression, and this zone is sometimes called the “no HOXD land” [18]. This brought up the theory that the length of the bones in any zone within the autopod will decrease and will eventually attain the shape of carpal bones as the HOXD13 activity is decreased [18]. Hence, the severe loss of HOXD13 activity in the zones of metacarpals/metatarsals may explain the metacarpal/metatarsal-to-carpal/tarsal transformation seen in some homozygous patients with SPD1 (see Figures 2(b) and 2(d) and 3).

## 2. Conclusions

The current report is the most comprehensive review of the phenotypes of SPD1 in homozygous patients. The review documents that not all homozygous patients show a severe hand phenotype. The review also defines the “relatively long and medially deviated big toe with/without cupping of the forefoot” as a pathognomonic feature in the phenotype.

## Conflicts of Interest

There are no conflicts of interest.

## References

- [1] S. Malik, “Syndactyly: phenotypes, genetics and current classification,” *European Journal of Human Genetics*, vol. 20, no. 8, pp. 817–824, 2012.
- [2] S. Malik and K. H. Grzeschik, “Synpolydactyly: clinical and molecular advances,” *Clinical Genetics*, vol. 73, no. 2, pp. 113–120, 2008.
- [3] M. M. Al-Qattan, “Type II familial synpolydactyly: report on two families with an emphasis on variations of expression,” *European Journal of Human Genetics*, vol. 19, no. 1, pp. 112–114, 2011.
- [4] D. M. Ibrahim, N. Tayebi, A. Knaus et al., “A homozygous HOXD13 missense mutation causes a severe form of synpolydactyly with metacarpal to carpal transformation,” *American Journal of Medical Genetics. Part A*, vol. 170, no. 3, pp. 615–621, 2016.
- [5] A. N. Albrecht, U. Kornak, A. Böddrich et al., “A molecular pathogenesis for transcription factor associated poly-alanine tract expansions,” *Human Molecular Genetics*, vol. 13, no. 20, pp. 2351–2359, 2004.
- [6] F. R. Goodman, S. Mundlos, Y. Muragaki et al., “Synpolydactyly phenotypes correlate with size of expansions in HOXD13 polyalanine tract,” *Proceedings of the National Academy of Sciences of the United States of America*, vol. 94, no. 14, pp. 7458–7463, 1997.
- [7] N. Brison, P. Debeer, S. Fantini et al., “An N-terminal G11A mutation in HOXD13 causes synpolydactyly and interferes with Gli3R function during limb pre-patterning,” *Human Molecular Genetics*, vol. 21, no. 11, pp. 2464–2475, 2012.
- [8] A. N. Akarsu, O. Akhan, B. S. Sayli, U. Sayli, G. Baskaya, and M. Sarfarazi, “A large Turkish kindred with syndactyly type II (synpolydactyly). 2. Homozygous phenotype?,” *Journal of Medical Genetics*, vol. 32, no. 6, pp. 435–441, 1995.
- [9] A. N. Akarsu, I. Stoilov, E. Yilmaz, B. S. Sayli, and M. Sarfarazi, “Genomic structure of HOXD13 gene: a nine polyalanine duplication causes synpolydactyly in two unrelated families,” *Human Molecular Genetics*, vol. 5, no. 7, pp. 945–952, 1996.
- [10] K. Horsnell, M. Ali, S. Malik et al., “Clinical phenotype associated with homozygosity for a HOXD13 7-residue polyalanine tract expansion,” *European Journal of Medical Genetics*, vol. 49, no. 5, pp. 396–401, 2006.
- [11] S. Malik, K. M. Girisha, M. Wajid et al., “Synpolydactyly and HOXD13 polyalanine repeat: addition of 2 alanine residues is without clinical consequences,” *BMC Medical Genetics*, vol. 8, no. 1, 2007.
- [12] Y. Muragaki, S. Mundlos, J. Upton, and B. R. Olsen, “Altered growth and branching patterns in synpolydactyly caused by mutations in HOXD13,” *Science*, vol. 272, no. 5261, pp. 548–551, 1996.
- [13] M. Kurban, M. Wajid, L. Petukhova, Y. Shimomura, and A. M. Christiano, “A nonsense mutation in the HOXD13 gene underlies synpolydactyly with incomplete penetrance,” *Journal of Human Genetics*, vol. 56, no. 10, pp. 701–706, 2011.
- [14] K. W. Kjaer, L. Hansen, H. Eiberg et al., “A 72-year-old Danish puzzle resolved—comparative analysis of phenotypes in families with different-sized HOXD13 polyalanine expansions,” *American Journal of Medical Genetics. Part A*, vol. 138, no. 4, pp. 328–339, 2005.
- [15] M. M. Al-Qattan, “A review of the genetics and pathogenesis of syndactyly in humans and experimental animals: a 3-step



- pathway of pathogenesis,” *BioMed Research International*, vol. 2019, Article ID 9652649, 10 pages, 2019.
- [16] P. Kuss, P. Villavicencio-Lorini, F. Witte et al., “Mutant Hoxd13 induces extra digits in a mouse model of synpolydactyly directly and by decreasing retinoic acid synthesis,” *The Journal of Clinical Investigation*, vol. 119, no. 1, pp. 146–156, 2009.
- [17] M. M. Al-Qattan, “Embryology of familial (non-syndromic) brachydactyly of the hand,” *The Journal of Hand Surgery, European Volume*, vol. 39, no. 9, pp. 926–933, 2014.
- [18] J. M. Woltering and D. Duboule, “The origin of digits: expression patterns versus regulatory mechanisms,” *Developmental Cell*, vol. 18, no. 4, pp. 526–532, 2010.
- [19] C. Fromental-Ramain, X. Warot, N. Messadecq, M. LeMeur, P. Dolle, and P. Chambon, “Hoxa-13 and Hoxd-13 play a crucial role in the patterning of the limb autopod,” *Development*, vol. 122, no. 10, pp. 2997–3011, 1996.
- [20] F. R. Goodman, C. Bacchelli, A. F. Brady et al., “Novel HOXA13 mutations and the phenotypic spectrum of hand-foot-genital syndrome,” *American Journal of Human Genetics*, vol. 67, no. 1, pp. 197–202, 2000.