

# Two case reports of an unusual association between Klippel-Feil syndrome and amyotrophic lateral sclerosis: Do they share same genetic defect?

Koneru Lakshmi Umamaheshwar, Amit Sehrawat, Manoj K. Parashar, Kshitij Mavade

Department of Medicine, Netaji Subhash Chandra Bose Medical College, Jabalpur, Madhya Pradesh, India

## Abstract

Klippel-Feil syndrome (KFS) is an unusual skeletal disorder characterized by congenital fusion of two or more cervical vertebrae which can be sporadic or familial. KFS emerges to be a failure of the normal segmentation and fusion of the mesodermal somites during 3<sup>rd</sup> and 8<sup>th</sup> weeks of embryonic development. The triad of low posterior hairline, short neck, and restricted neck motion is present only in 50% and often associated with scoliosis, spina bifida, Sprengel's deformity, cervical ribs, deafness, cleft palate, renal anomalies, congenital heart defects, and so on because of heterogeneous nature of the disease. The significance of KFS lies in the secondary effects produced on the nervous system, which usually presents with features of progressive cord and brain stem compression with relatively minor trauma. We here report two cases of KFS presented in association with amyotrophic lateral sclerosis. Only two such cases have been described in the literature in 1954 and 1975.

## Key Words

Amyotrophic lateral sclerosis, bone morphogenetic protein, Klippel-Feil syndrome, Pax-1, sonic hedgehog

For correspondence:

Dr. Koneru Lakshmi Umamaheshwar, C/o B. R. Nandi, Shubham Nagar, Khan Colony, Chhindwara - 480 002, Madhya Pradesh, India. E-mail: bobby.kl17@gmail.com

*Ann Indian Acad Neurol 2013;16:705-7*

## Case Reports

### Case 1

Thirty-eight-year-old right-handed smoker male presented with progressive slurring of speech, difficulty in chewing and swallowing since 8 months. He complained of choking spells, nasal regurgitation, nonradiating neck pain, weakness and atrophy of right thumb and index finger along with muscle twitching in all limbs. There were no paresthesias, dyspnea, trauma, bladder, and bowel difficulties or significant family history. Examination revealed short neck, low posterior hairline, kyphoscoliosis with convexity to right, restricted neck movements on lateral flexion and extension with negative compression test. He had preserved language function with slurred, hypernasal speech. His right soft palate was sagging with absent gag reflex. Bilateral thenar and hypothenar muscles were atrophied. Fasciculation's were present in tongue, biceps, triceps, pectorals, and quadriceps. Brisk limb

Deep Tendon Reflexes, extensor planters with normal sensory examination were present. Jaw jerk was absent. Magnetic resonance imaging (MRI) cervical spine revealed right kyphoscoliosis, partial fusion of C3-4 without cord compression and butterfly vertebra at C4 [Figure 1]. The Nerve Conduction Velocity-Electromyography (NCV-EMG) study showed low CMAP (Compound Motor Action Potential) in both

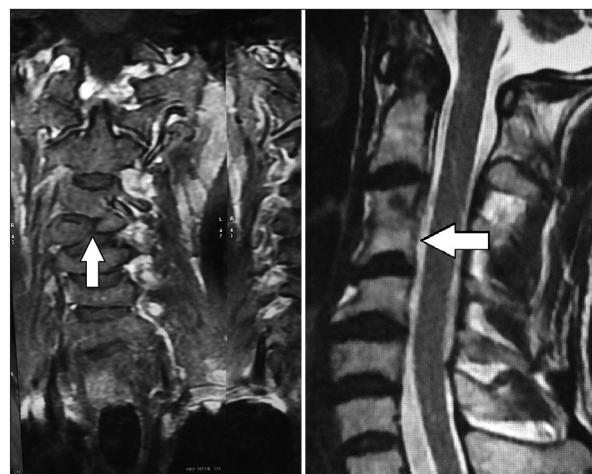


Figure 1: Magnetic resonance imaging cervical spine showing partial fusion of C3-4 without cord compression and butterfly vertebra at C4

### Access this article online

#### Quick Response Code:



#### Website:

www.annalsofian.org

#### DOI:

10.4103/0972-2327.120456

facial nerves and denervation potentials in right upper limb suggestive of anterior horn cell disease. Audiometry, abdominal ultrasonography, echocardiography does not revealed other abnormalities. We examined his father and only daughter but could not find any evidence of Klippel-Feil syndrome (KFS) or amyotrophic lateral sclerosis (ALS). Final diagnosis was made as Klippel-Feil anomaly type II with definite ALS with bulbar presentation, using revised El-Escorial world federation of neurology criteria. Other possible differentials were excluded by relevant history, radiological, electrodiagnostic (EMG), biochemical (*viz.* Cerebrospinal Fluid, complete analysis, thyroid profile, lipid profile, S. calcium, Fasting Blood Sugar (FBS), T. proteins) and hematological [Complete Blood Count (CBC), Erythrocyte Sedimentation Rate (ESR)] investigations.

### Case 2

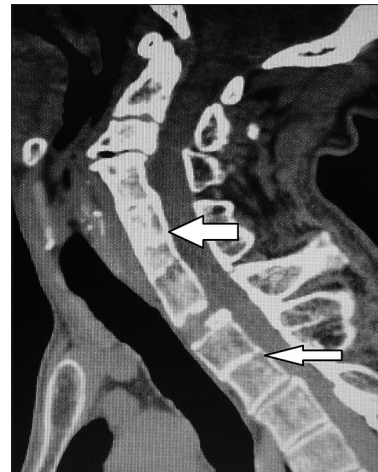A case of 42-year-old right-handed male smoker presented with predominantly distal progressive asymmetrical weakness of all limbs, more on left, since 2 years. Also, slurred speech, difficult chewing and swallowing, choking spells, nasal regurgitation, limb cramps were present since 4 months. There were no paresthesias, dyspnea, trauma, bladder, and bowel difficulties. Examination revealed short neck, low posterior hairline, and restricted neck movements on lateral flexion with negative compression test. Speech was low volume, hypernasal with preserved language function. Bilateral atrophied thenar and hypothenar muscles, brisk DTR, extensor planters, fasciculation's of tongue, arm and thigh, absent jaw and gag reflex were evident. Sensory examination was normal. X-ray cervical spine revealed multiple fused vertebrae with wasp-waist sign. On MRI multiple block vertebrae C4-D1, butterfly vertebrae D2-3, cervical scoliosis without cord compression, wine glass appearance with loss of fibers of posterior third of internal capsule were evident [Figures 2 and 3]. The NCV-EMG study showed decreased amplitude in both facial nerves, denervation involving muscles of all limbs suggesting anterior horn cell disease. Digging into family history did not reveal any significant information. Final diagnosis was made as Klippel-Feil anomaly type I with definite ALS with bulbar involvement, using revised El-Escorial world federation of neurology criteria. Other possible differentials were excluded by relevant history, radiological, electrodiagnostic, biochemical (*viz.* CSF-complete analysis, thyroid profile, lipid profile, S. calcium, FBS, T. proteins) and hematological (CBC, ESR) investigations.

### Discussion

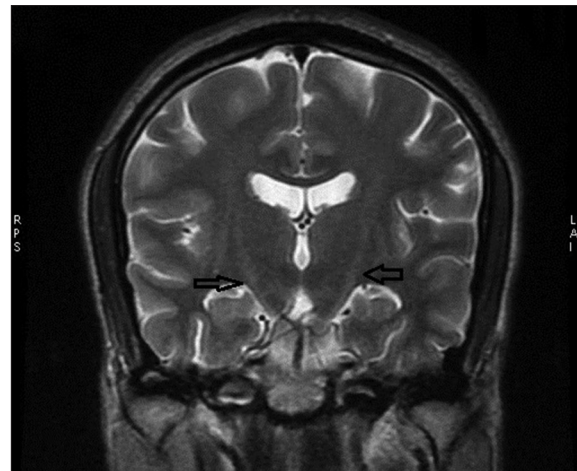
KFS is defined as congenital fusion of two or more cervical vertebrae, results from faulty segmentation along the embryo's developing axis during 3-8 weeks of gestation with incidence of 1:40,000 to 1:42,000 births.<sup>[1]</sup> Klippel and Feil proposed a classification:

- Type I: Extensive cervical and upper thoracic spinal fusion
- Type II: One or two interspace fusions, often associated with hemivertebrae and occipitioatlantal fusion
- Type III: Both cervical and lower thoracic or lumbar fusion.

Type II is commonest; C2-3 and C5-6 inter-spaces are most often fused.<sup>[2]</sup> The triad of low posterior hairline, short neck, and restricted neck motion is present in only 50%.



**Figure 2: Multiple block vertebrae C4-D1, butterfly vertebrae D2-3, cervical scoliosis without cord compression**



**Figure 3: Magnetic resonance imaging brain showing wine glass appearance**

Restricted rotational neck motion, neck pain are commonest presentation. Some presents with weakness, spasticity, dysmetria, nystagmus, sensory loss, and lower cranial nerve involvement due to progressive cord and brain stem compression, as minor trauma alters force transfer mechanics and make nonfused segments excessively mobile causing symptoms. In both of our cases, there was no associated cervical cord and brainstem pathology as supported by neuroimaging. We could not find any other coexisting congenital anomalies associated with KFS as well. Only two such cases have been reported by Floris *et al* and Rodriguez Cuartero *et al.*,<sup>[3,4]</sup> Rodriguez Cuartero *et al.*, described an unusual association of KFS and other abnormalities (Sprengel's deformity, spina bifida, craniostenosis, and basilar impression) together with neurological signs of amyotrophic lateral sclerosis, in a 36-year-old woman.

ALS, commonest degenerative disease of the motor neurons, incidence being 3-5/100000, occurs sporadically in 90-95% and familial in 5-10%.<sup>[5]</sup> Current research into pathophysiology of ALS has focused on glutamate excitotoxicity in the contrary the mechanisms that lead to disease onset remains unknown.

Assuming that the abnormal gene or gene product plays a role in triggering onset and propagation in familial ALS is reasonable. But additional factors must be postulated to intervene between birth and disease onset as the disease does not appear to start at birth even in familial ALS. Acquired nucleic acid changes may trigger disease onset in sporadic ALS.<sup>[6]</sup> This hypothesis relies on the observation that smoking (as in our cases), only established risk factor, provides a mechanism, that is, induction of changes in nucleic acids.<sup>[7]</sup> In support of this hypothesis, Ravits *et al.*,<sup>[8]</sup> established an irrefutable role for corticospinal neurons in the early spread of ALS and provided possible existence of one or more "agents of spread". The affirmation of spread substantiates the concept of a biological focal onset to ALS. Whether KFS acts as a trigger for ALS is to be proved. We here by looking into embryology and pathogenesis of both diseases, hypothesize a possible interwoven etiopathogenic association between two.

KFS is sporadic, but seldom can be inherited.<sup>[9]</sup> Mutations in the GDF6 and GDF3 genes have been identified to cause KFS. These genes are precursors of the bone morphogenetic protein (BMP) family, involved in regulation of bone and cartilage differentiation. BMP is involved in setting up boundaries between bones during skeletal development. Another *Pax* family of regulatory genes is implicated in sclerotomal resegmentation necessary for proper vertebra development. *Pax-1* expression is detected very early in the predifferentiated somites. Signals from the notochord and ventral floor plate of the neural tube, mediated by the sonic hedgehog (SHH) protein, induce the somite to divide into dermomyotome and the ventromedial sclerotome. This coincides with intense *Pax-1* expression, suggesting its role in the somites dorsoventral specification.<sup>[10]</sup> Murine *Pax-1* mutants undulated show multiple fusion of vertebral bodies and fusion of the dens with the anterior atlantal arch, reminiscent of the human KFS. It is, therefore, conceivable that segmentation defects in KFS may be explained by over-/underexpression of *Pax-1* during vertebral development. So, it can be concluded that BMP, SHH, and *Pax* family are involved in pathogenesis of KFS.

Further during embryogenesis of neurons, neural plate in the spinal cord region expresses the transcription factors *Pax-3*, *Pax-7*, *MSX1*, and *MSX2*. This expression pattern is altered by SHH expressed in the notochord and BMPs 4 and 7 (BMP4 and BMP7) expressed in the non neural ectoderm at the border of the neural plate. The SHH and BMP signals regulate the development and regulation of motor neurons and sensory neurons, respectively. Thus, the SHH and BMP signals regulate the differentiation of motor and sensory neurons, respectively. Therefore, as both SHH and BMP are necessary for development of vertebrae and motor neurons, both ALS and

KFS can present in the same patient, with ALS being triggered by smoking or environmental risk factors.

## Conclusion

To our best knowledge, the association of KFS and ALS has only been described in two case reports. This is not commonly reported in western texts, as it might be a new Indian variant of ALS with young age of presentation. To conclude, in the light of the relevant literature, rather than speculating whether these two have a causal relation, evaluating coexistence of both the diseases seems more feasible. Further studies are needed to prove the association and genetic basis.

## References

1. Thomsen MN, Schneider U, Weber M, Johannisson R, Niethard FU. Scoliosis and congenital anomalies associated with Klippel-Feil syndrome types I-III. *Spine (Phila Pa 1976)* 1997;22:396-401.
2. Nagib MG, Maxwell RE, Chou SN. Identification and management of high-risk patients with Klippel-Feil syndrome. *J Neurosurg* 1984;61:523-30.
3. Floris V, Vizioli R, Maccagnani F. Syndrome of the Klippel-Feil type, hemivertebra and delayed amyotrophic lateral sclerosis. *Riv Neurol* 1954;24:429-36.
4. Rodriguez Cuartero A, Vilchez Medina J, Peláez Redondo J. Klippel-Feil syndrome and associated malformations. Comments on an unusual case. *Minerva Med* 1975;66:1331-40.
5. Armon C. Epidemiology of ALS/MND. In: Shaw P, Strong M, editors. *Motor Neuron Disorders*. Philadelphia: Elsevier Sciences; 2003. p. 167-206.
6. Armon C. Acquired nucleic acid changes may trigger sporadic amyotrophic lateral sclerosis. *Muscle Nerve* 2005;32:373-7.
7. Armon C. Smoking may be considered an established risk factor for sporadic ALS. *Neurology* 2007;73:1693-8.
8. Ravits J, Paul P, Jorg C. Focality of upper and lower motor neuron degeneration at the clinical onset of ALS. *Neurology* 2007;68:1571-5. [Medline].
9. Larson AR, Josephson KD, Pauli RM, Opitz JM, Williams MS. Klippel-Feil anomaly with Sprengel anomaly, omovertebral bone, thumb abnormalities, and flexion-crease changes: Novel association or syndrome? *Am J Med Genet* 2001;101:158-62.
10. Koseki H, Wallin J, Wilting J, Mizutani Y, Kispert A, Ebensperger C, *et al.* A role for Pax-1 as mediator of notochordal signals during the dorsoventral vertebrae. *Development* 1993;119:649-60.

**How to cite this article:** Umamaheshwar KL, Sehrawat A, Parashar MK, Mavade K. Two case reports of an unusual association between Klippel-Feil syndrome and amyotrophic lateral sclerosis: Do they share same genetic defect?. *Ann Indian Acad Neurol* 2013;16:705-7.

**Received:** 02-04-13, **Revised:** 14-05-13, **Accepted:** 29-06-13

**Source of Support:** Nil, **Conflict of Interest:** Nil