

# Diagnosis of Neuroinvasive Astrovirus Infection in an Immunocompromised Adult With Encephalitis by Unbiased Next-Generation Sequencing

Samia N. Naccache,<sup>1,2</sup> Karl S. Peggs,<sup>3</sup> Frank M. Mattes,<sup>4</sup> Rahul Phadke,<sup>5</sup> Jeremy A. Garson,<sup>7</sup> Paul Grant,<sup>4</sup> Erik Samayoa,<sup>1,2</sup> Scot Federman,<sup>1,2</sup> Steve Miller,<sup>1,2</sup> Michael P. Lunn,<sup>6</sup> Vanya Gant,<sup>4</sup> and Charles Y. Chiu<sup>1,2,8</sup>

<sup>1</sup>Department of Laboratory Medicine, University of California, San Francisco, and <sup>2</sup>UCSF-Abbott Viral Diagnostics and Discovery Center, San Francisco, California; Departments of <sup>3</sup>Clinical Hematology, <sup>4</sup>Clinical Microbiology, <sup>5</sup>Neuropathology, <sup>6</sup>Neurology, University College London Hospitals NHS Foundation Trust, and <sup>7</sup>Research Department of Infection, Division of Infection and Immunity, University College London, United Kingdom; and <sup>8</sup>Department of Medicine, Division of Infectious Diseases, University of California, San Francisco

(See the Major Article by Brown et al on pages 881–8, and the Editorial Commentary by Calistri and Palù on pages 889–91.)

**Metagenomic next-generation sequencing (NGS) was used to diagnose an unusual and fatal case of progressive encephalitis in an immunocompromised adult presenting at disease onset as bilateral hearing loss. The sequencing and confirmatory studies revealed neuroinvasive infection of the brain by an astrovirus belonging to a recently discovered VA/HMO clade.**

**Keywords.** VA/HMO astrovirus clade; encephalitis; deafness; next-generation sequencing; pathogen discovery.

The etiology of acute encephalitis remains undiagnosed in approximately 60% of cases [1]. Timely diagnosis is hindered by the lack of available assays to rapidly survey the breadth of common, rare, or unknown agents responsible for encephalitis. Unbiased metagenomic next-generation sequencing (NGS) offers

the possibility for pathogen identification without a priori knowledge of the target [2]. We recently developed a rapid cloud-compatible bioinformatics pipeline (sequence-based ultra-rapid pathogen identification [SURPI]) to detect any pathogen in the GenBank reference database [3]. NGS testing and SURPI analysis were previously used to diagnose neuroleptospirosis in a child with a fulminant encephalitis that had eluded all conventional testing, prompting evidence-based therapy and clinical recovery [2]. Here we used NGS to search for an infectious etiology in an unusual case of progressive encephalitis presenting as bilateral hearing loss.

## CASE REPORT

A 42 year-old man with chronic lymphocytic leukemia underwent allogeneic bone marrow transplant in September 2013. The graft was mismatched at a single human leukocyte antigen allele (DQB1), and was T-cell depleted using in vivo alemtuzumab. He was engrafted on day 12 after transplant. Aside from persistent lymphopenia and diarrhea from norovirus infection, his posttransplant course was unremarkable until mid-October when he developed tinnitus and rapidly progressive sensorineural deafness, resulting in subtotal hearing loss bilaterally (>95 dB) over 2–3 weeks. Brain magnetic resonance imaging (MRI) was unremarkable, as was cerebrospinal fluid (CSF) analysis (4 leukocytes/ $\mu$ L with 50% neutrophils and 50% lymphocytes, 6 red blood cells/ $\mu$ L, glucose 2.4 mmol/L [normal range, 2.2–4.7 mmol/L], protein 61 mg/dL [normal range, 15–45 mg/L], absence of oligoclonal bands). Viral polymerase chain reaction (PCR) testing of CSF was negative for enterovirus and herpesvirus infection. The patient was treated empirically with high-dose valacyclovir, broad-spectrum antibiotics, and 2 g/kg intravenous immunoglobulin (IVIG). Despite these interventions, he developed new symptoms of central dyspnea, postural hypotension, nausea, and gradually worsening balance. Repeat neurological assessment confirmed persistent vestibulocochlear dysfunction 6 weeks after symptom onset.

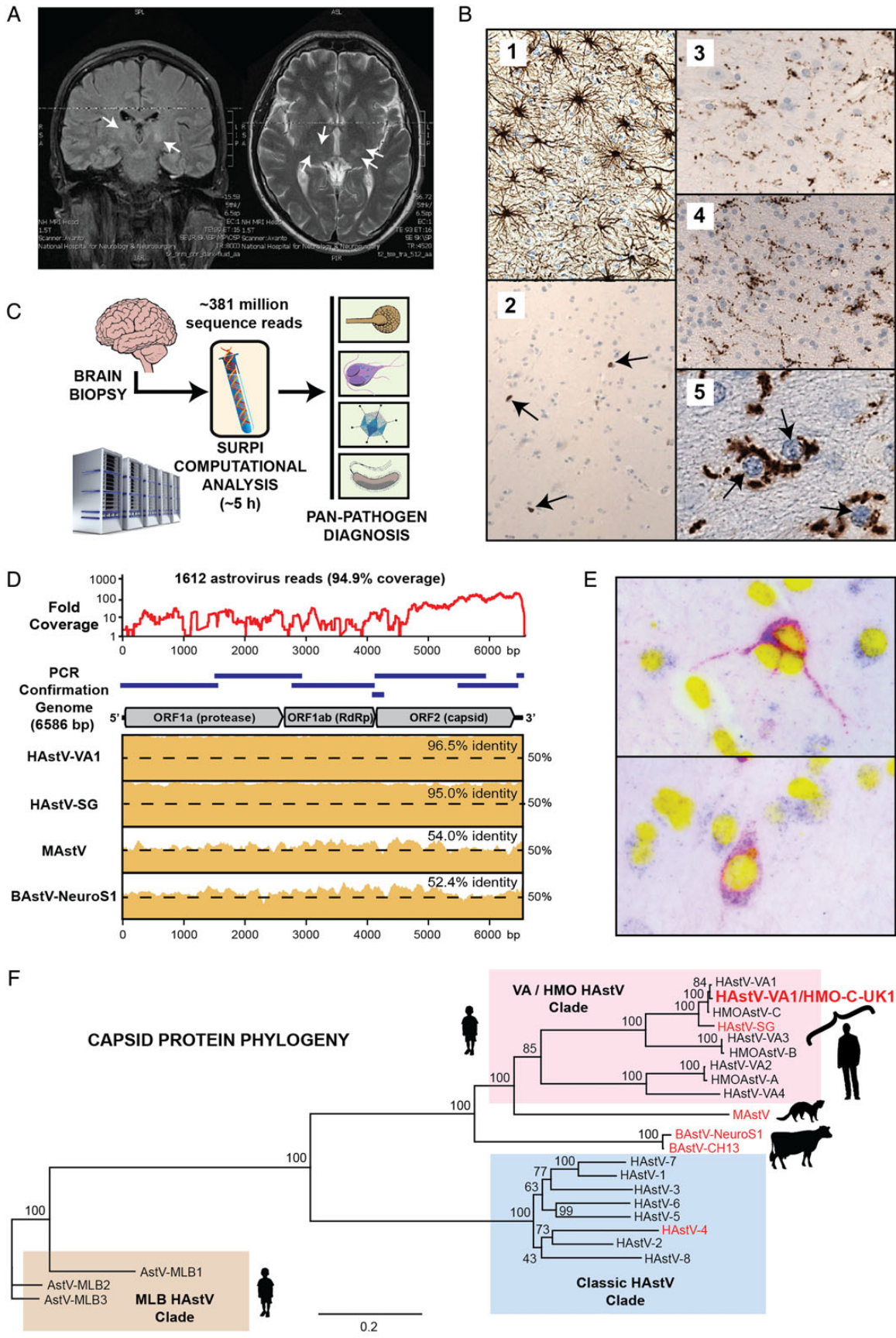
By mid-December, the patient had become increasingly withdrawn, irritable, and intermittently agitated. He remained lymphopenic (lymphocytes  $0.54 \times 10^6/\mu$ L [normal range,  $1.2\text{--}3.6 \times 10^6/\mu$ L]). MRI scans of the brain were unremarkable, as was serum testing for antineuronal antibodies; an electroencephalogram revealed only diffuse encephalopathy. Given continued suspicion for a viral etiology, the patient was treated with high-dose glucocorticoids and again with IVIG. He began refusing fluids, food, and medication, and was detained under the UK

Received 17 July 2014; accepted 15 September 2014; electronically published 7 January 2015.

Correspondence: Charles Y. Chiu, MD, PhD, Department of Laboratory Medicine, University of California, San Francisco, 185 Berry St, Box 0134, San Francisco, CA 94107 (charles.chiu@ucsf.edu).

**Clinical Infectious Diseases**® 2015;60(6):919–23

© The Author 2015. Published by Oxford University Press on behalf of the Infectious Diseases Society of America. This is an Open Access article distributed under the terms of the Creative Commons Attribution-NonCommercial-NoDerivs licence (<http://creativecommons.org/licenses/by-nc-nd/4.0/>), which permits non-commercial reproduction and distribution of the work, in any medium, provided the original work is not altered or transformed in any way, and that the work is properly cited. For commercial re-use, please contact [journals.permissions@oup.com](mailto:journals.permissions@oup.com). DOI: 10.1093/cid/ciu912



Mental Health Act. Repeat MRI scanning showed interval development of new, nonenhancing signal abnormalities in both thalami and midbrain with cranial nerve involvement but no meningeal enhancement (Figure 1A). Near the end of December, a frontal lobe biopsy was performed. Histology revealed reactive gliosis and diffuse infiltration with CD3<sup>+</sup>/8<sup>+</sup> lymphocytes (Figure 1B). Extensive microbiological testing of the biopsy tissue for an infectious etiology was negative (Supplementary Table 1).

Given the absence of a diagnosis and the patient's progressive neurological deterioration, CSF and brain biopsy tissue were analyzed in January 2014 by metagenomic next-generation sequencing (NGS) [2]. NGS analysis of the brain biopsy, genome assembly, and in situ hybridization revealed findings of neuroinvasive astrovirus (AstV) infection. Despite lack of approved therapies, the patient was treated with ribavirin and IVIG. However, he did not respond to these interventions, and remained in a minimally conscious state following withdrawal of sedation in March 2014. He eventually died at the end of May, 4 months after the NGS diagnosis and approximately 7.5 months after onset of symptoms.

## METHODS

Written consent for clinical sample analysis was obtained on the patient's behalf from his spouse. This study was approved by the institutional review boards of the University of California, San Francisco and University College London. Methods for nucleic acid extraction, NGS sequencing, bioinformatics analysis, confirmatory PCR, and in situ hybridization are provided in the Supplementary Appendix.

## RESULTS

In total, 381 014 716 and 6 658 656 reads were obtained using NGS from biopsy tissue and CSF, respectively, with sample-to-

answer turnaround times of 96 and 48 hours, and corresponding SURPI analysis times of 5 hours and 2.5 hours (Figure 1C) [3]. From brain tissue RNA, 1612 of 134 068 968 reads (0.0012%) were identified as AstV, with no credible reads corresponding to other viral or nonviral pathogens. Mapping of all 1612 astrovirus reads to the genome of astrovirus VA1 (HAsV-VA1) or the nearly identical astrovirus HMO-C (HMOAst-C) [4] resulted in 94.9% coverage of the viral genome (Figure 1D and Supplementary Figure 1). In the CSF sample, AstV reads were absent, with only detection of *Anellovirus* and phage sequences corresponding to nonpathogenic viral flora (Supplementary Tables 3 and 4). The finding of AstV sequences in brain tissue was confirmed by reverse transcription (RT) PCR testing (Supplementary Figure 2A and B). A CSF sample collected intraoperatively at the time of brain biopsy was also weakly positive by RT-PCR (cycle threshold = 34) (Supplementary Figure 2), but CSF samples taken 1 and 10 days prior to the procedure were negative (Supplementary Table 1). Follow-up RT-PCR and Sanger sequencing were also used to bridge gaps and recover the full genome of the virus, provisionally named "human astrovirus VA-1/HMO-C, strain UK1" (HAsV-VA1/HMO-C-UK1).

HAsV-VA1/HMO-C-UK1 was found to share 96.5% nucleotide identity to HAsV-VA1/HMO-C, associated with acute diarrhea in children [4, 5]; 95% identity to HAsV-SG, detected in brain tissue from a boy with X-linked agammaglobulinemia and fatal encephalitis [6]; and 52%–54% identity to AstVs linked to neurological disease in minks ("shaking mink syndrome") [7] and cattle (bovine encephalitis) [8, 9] (Figure 1D). The diagnosis of neuroinvasive AstV brain infection was confirmed by in situ hybridization of brain tissue using probes derived from the HAsV-VA1/HMO-C-UK1 capsid, demonstrating viral localization to neurons (Figure 1E). Phylogenetic analysis placed the AstV in a VA/HMO clade that includes the previously described VA-1 and

**Figure 1.** A, Magnetic resonance imaging of the brain. Coronal (left) and axial (right) views show T2-weighted abnormalities in the thalamus and midbrain (white arrows). B, Histological and immunohistochemical studies of brain biopsy tissue. A brain biopsy from the right frontal lobe showed diffuse striking reactive gliosis in the neuroparenchyma highlighted by immunostaining for glial fibrillary acidic protein (1). Diffuse scattering of small numbers of reactive T lymphocytes immunopositive for CD3 (2, black arrows) is seen. Immunostaining for CD8, a microglial marker, revealed marked microglial activation within the cortex (3) and white matter (4). Microglial cell processes were often seen in close contact with neurons (5, black arrows). No viral inclusions were observed. C, A metagenomic next-generation sequencing assay for infectious disease diagnosis. Using the sequence-based ultra-rapid pathogen identification (SURPI) pipeline [3], >381 million reads generated from the patient's brain biopsy sample were analyzed in approximately 5 hours for potential pathogens. D, Genome recovery and pairwise comparative analysis of human astrovirus (HAsV) VA1/HMO-C-UK1. Mapping of 1612 Astroviridae reads identified by SURPI resulted in recovery of >94.9% of the 6586 base pair (bp) genome (coverage plot; shown mapped to the genome of HAsV-VA1/HMO-C-UK1), with sequence confirmation using polymerase chain reaction (PCR) (blue lines). Pairwise identity plots revealed high (>95%) nucleotide identity shared between the patient's astrovirus (AstV) strain (HAsV-VA1/HMO-C-UK1) and other VA-1/HMO-C viruses. E, In situ hybridization of brain tissue from the affected patient. Nucleic acid hybridization using probes to the AstV capsid gene (red) and the GAPDH control (blue) reveals selective labeling of infected neurons (yellow, nuclei stained with DAPI). The estimated proportion of cells staining positive for AstV was approximately 0.6%. F, Phylogenetic tree of human and encephalitic mammalian AstVs. VA-1/HMO-C viruses in the VA/HMO clade associated with encephalitis in humans (HAsV-VA1/HMO-C-UK1 and HAsV-SG) are more closely related to encephalitic AstVs in other mammals (MAstV and BAsV) than to classic HAsVs 1–8 or AstVs in the MLB clade. Mammalian AstVs linked to encephalitis are highlighted in red text. Abbreviations: BAsV, bovine astrovirus; DAPI, 4',6-diamidino-2-phenylindole; GAPDH, glyceraldehyde-3-phosphate dehydrogenase; HMOAst-C, astrovirus HMO-C; MAstV, mink astrovirus; ORF, open reading frame; RdRp, RNA-dependent RNA polymerase; SURPI, sequence-based ultra-rapid pathogen identification.

HMO-C AstVs [10], and that segregates away from classical HAstVs 1–8 (Figure 1F).

## DISCUSSION

AstVs are common causes of viral gastroenteritis in humans, but have recently been described as potential causative agents of encephalitis [6, 11]. In humans, 2 studies have previously detected AstV in brain tissue from children with fatal encephalitis. The first case was in a 15-year-old immunocompromised boy with X-linked agammaglobulinemia who was found to be infected by HAstV-SG, a member of the VA/HMO clade (Figure 1F) [6]. Interestingly, the boy lived in close proximity to a mink farm, suggesting a potential zoonotic link between HAstV-SG infection and a related mink astrovirus. The second case was a 7-month-old infant with severe combined immunodeficiency who developed disseminated multiorgan disease from HAstV 4, with viral detection in brain tissue by RT-PCR [11]. Similar to the other 2 cases, our patient, the first documented case of astrovirus infection in an adult, was severely immunocompromised due to his bone marrow transplant and prior chemotherapy.

Serological studies of VA-1/HMO-C astrovirus infection reveal high prevalence rates in the human population, with seropositivity in 36% of children by age 10 and rising to 65% in adults [12]. It is thus striking that documented human cases of astrovirus encephalitis are hitherto rare [6, 11]. We postulate that astrovirus infection, akin to poliomyelitis, is asymptomatic or associated with self-resolving acute diarrhea in most individuals, with severe disease only rarely observed. Our patient's mildly abnormal histology, with minor inflammatory T-cell infiltrates in the microglia (Figure 1A), and lack of CSF oligoclonal bands suggest that he was unable to mount an effective inflammatory response against this virus. Thus his clinical course of a chronic, progressive encephalitis from astrovirus infection may be reflective of his highly immunocompromised state. Low astrovirus levels found in CSF likely indicate inefficient production of free virions, with the site of infection largely restricted to brain parenchyma.

We believe that our patient's astrovirus infection occurred via the fecal-oral route, which is typical for enteric viruses. However, although this mechanism of transmission is consistent with his norovirus-associated diarrhea beginning posttransplant, chronic shedding of HAstV-VA1/HMO-C-UK1 in stool was not observed (Supplementary Table 1). Unlike the previously reported case of VA-1/HMO-C astrovirus encephalitis in a child in close proximity to a mink farm [6], our patient did not report any unusual exposures or travel history, raising concern that his infection may have been community acquired.

Treatment of patients with putative astrovirus encephalitis is challenging given the paucity of cases to date and lack of a

known efficacious therapy. High-dose IVIG was previously shown to play a role in the treatment of severe astrovirus gastroenteritis [13]. Although empiric administration of high-dose IVIG and glucocorticoids may have temporarily stabilized our patient's condition, treatment did not halt progression of the infection. The utility of ribavirin for treatment of neuroinvasive astroviral infections is unknown, and no vaccine is available.

Astrovirus testing is not routine in cases of encephalitis, and conventional RT-PCR assays detect only classical astroviruses types 1–8 and do not target members of the VA/HMO clade. This study highlights the feasibility of deploying metagenomic NGS as a clinical diagnostic assay that targets all potential pathogens simultaneously. As NGS becomes an increasingly accessible technology, we envision its routine application for “pan-microbial” diagnosis of infectious diseases in the near future.

## Supplementary Data

Supplementary materials are available at *Clinical Infectious Diseases* online (<http://cid.oxfordjournals.org>). Supplementary materials consist of data provided by the author that are published to benefit the reader. The posted materials are not copyedited. The contents of all supplementary data are the sole responsibility of the authors. Questions or messages regarding errors should be addressed to the author.

## Notes

**Acknowledgments.** We thank staff at the University of California, San Francisco Genomics Core Facility for sequencing; the Gladstone Histology and Light Microscopy Core for use of their fluorescence microscope; Shekar Menon at Affymetrix for advice on QuantiGene in situ hybridization optimization; and Deanna Lee, Sneha Somasekar, and Nancy Joseph for discussions on optimal tissue extraction methods.

**Author contributions.** K. S. P., F. M. M., R. P., V. G., and M. P. L. participated in care of the patient. S. N. N., V. G., and C. Y. C. conceived and designed the experiments. S. N. N., E. S., J. A. G., and P. G. performed the experiments. S. N. N., S. F., and C. Y. C. analyzed the data. C. Y. C. and S. M. contributed reagents/materials/analysis tools. S. N. N., K. S. P., J. A. G., M. P. L., S. M., V. G., and C. Y. C. wrote the article. All authors read and approved the final manuscript. C. Y. C. had full access to all of the data in the study and had final responsibility for the decision to submit for publication.

**Disclaimer.** The funders had no role in the data collection, analysis, patient recruitment, or decision to publish.

**Financial support.** This study was supported by a grant from the National Institutes of Health (R01-HL105704), a University of California Discovery Award, and an Abbott Viral Discovery Award to C. Y. C. Work undertaken at University College London (by K. S. P., F. M. M., R. P., J. A. G., P. G., M. P. L., and V. G.) received partial support from the National Institute for Health Research Biomedical Research Centre and Experimental Cancer Medicine Centre.

**Potential conflicts of interest.** All authors: No reported conflicts.

All authors have submitted the ICMJE Form for Disclosure of Potential Conflicts of Interest. Conflicts that the editors consider relevant to the content of the manuscript have been disclosed.

## References

1. Glaser CA, Honarmand S, Anderson LJ, et al. Beyond viruses: clinical profiles and etiologies associated with encephalitis. *Clin Infect Dis* 2006; 43:1565–77.

2. Wilson MR, Naccache SN, Samayoa E, et al. Actionable diagnosis of neuroleptospirosis by next-generation sequencing. *N Engl J Med* **2014**; 370:2408–17.
3. Naccache SN, Federman S, Veeraraghavan N, et al. A cloud-compatible bioinformatics pipeline for ultrarapid pathogen identification from next-generation sequencing of clinical samples. *Genome Res* **2014**; 24:1180–92.
4. Kapoor A, Li L, Victoria J, et al. Multiple novel astrovirus species in human stool. *J Gen Virol* **2009**; 90(pt 12):2965–72.
5. Finkbeiner SR, Li Y, Ruone S, et al. Identification of a novel astrovirus (astrovirus VA1) associated with an outbreak of acute gastroenteritis. *J Virol* **2009**; 83:10836–9.
6. Quan PL, Wagner TA, Briese T, et al. Astrovirus encephalitis in boy with X-linked agammaglobulinemia. *Emerg Infect Dis* **2010**; 16: 918–25.
7. Blomstrom AL, Widen F, Hammer AS, Belak S, Berg M. Detection of a novel astrovirus in brain tissue of mink suffering from shaking mink syndrome by use of viral metagenomics. *J Clin Microbiol* **2010**; 48:4392–6.
8. Bouzalas IG, Wuthrich D, Walland J, et al. Neurotropic astrovirus in cattle with nonsuppurative encephalitis in Europe. *J Clin Microbiol* **2014**; 52:3318–24.
9. Li L, Diab S, McGraw S, et al. Divergent astrovirus associated with neurologic disease in cattle. *Emerg Infect Dis* **2013**; 19:1385–92.
10. Jiang H, Holtz LR, Bauer I, et al. Comparison of novel MLB-clade, VA-clade and classic human astroviruses highlights constrained evolution of the classic human astrovirus nonstructural genes. *Virology* **2013**; 436:8–14.
11. Wunderli W, Meerbach A, Gungor T, et al. Astrovirus infection in hospitalized infants with severe combined immunodeficiency after allogeneic hematopoietic stem cell transplantation. *PLoS One* **2011**; 6: e27483.
12. Burbelo PD, Ching KH, Esper F, et al. Serological studies confirm the novel astrovirus HMOAstV-C as a highly prevalent human infectious agent. *PLoS One* **2011**; 6:e22576.
13. Bjorkholm M, Celsing F, Runarsson G, Waldenstrom J. Successful intravenous immunoglobulin therapy for severe and persistent astrovirus gastroenteritis after fludarabine treatment in a patient with Waldenstrom's macroglobulinemia. *Int J Hematol* **1995**; 62:117–20.