

Magnetic Resonance Imaging of Lateral Meniscus Root Tears in the Pediatric and Adolescent Knee

Is the Diagnosis Missed, Mentioned, or Made?

John Schlechter,^{*†‡} DO, Theresa Pak,[‡] DO, Bryn Gornick,[†] BS, and Edward McDonald,[§] DO

Investigation performed at Children's Hospital of Orange County, Orange, California, USA

Background: Failure to address meniscus root tears may place undue loads on anterior cruciate ligament (ACL) reconstructive surgery in the adult population. Because the intraoperative management of lateral meniscus posterior root tears (LMPRTs) may diverge from standard meniscal work and requires specialty items, preoperative diagnosis may be advantageous.

Purpose: To evaluate the reliability of radiologist interpretations of preoperative knee magnetic resonance imaging (MRI) scans of lateral meniscus root pathology in a mixed pediatric and adolescent population.

Study Design: Cohort study (diagnosis); Level of evidence, 2.

Methods: A retrospective review of medical records was performed to identify patients younger than 18 years with an arthroscopically confirmed LMPRT who underwent knee arthroscopy between March 1, 2010, and April 1, 2020. Arthroscopic findings were compared with the reading radiologist's preoperative MRI interpretations, and patients were stratified into 2 groups: (1) LMPRT diagnosis made preoperatively or (2) diagnosis missed or only mentioned to describe pathology nonspecific to the root. Variables such as body mass index (BMI), open physes, time from injury to MRI, time from MRI to surgery, MRI magnet field strength, musculoskeletal radiologist designation, insurance type, and tear grade were assessed between groups.

Results: Overall, 1116 knee arthroscopies were performed, with 49 LMPRTs found; all 49 LMPRTs were found concomitantly with ACL tears (49/535; 9.2%). The average patient age was 15.97 years (range, 11.52-17.97 years). There were 50 MRI scans for 49 patients. An LMPRT was diagnosed based on preoperative MRI scans in 12 of these 50 scans (24%) and mentioned or missed in 38 of the 50 scans (76%). No significant difference was seen between the diagnosis-made versus diagnosis-mentioned/missed groups in BMI, skeletal maturity, time from injury to MRI, time from MRI to surgery, MRI magnet strength, fellowship training of the reading radiologist, tear grade, or insurance type.

Conclusion: In 76% of patients, a definitive diagnosis of LMPRT was not made on preoperative MRI scans. Notably, all LMPRTs found intraoperatively were found concomitantly with ACL tears.

Keywords: meniscus root tears; MRI; pediatric; ACL

The meniscus roots play a vital role in maintaining proper knee kinematics. Adult literature has suggested that neglected meniscus root tears alter normal loading mechanics of the knee and may increase the risk of premature osteoarthritis.² Previous biomechanical studies have suggested that posterior root tears may behave like total meniscectomies.¹ Other studies have shown poor functional outcome scores in pediatric patients having undergone total meniscectomies.¹⁷

Lateral meniscus posterior root tears (LMPRTs) are more likely than medial meniscus root tears to be associated with anterior cruciate ligament (ACL) pathology.¹⁴ Additionally, the lateral meniscus posterior root has been shown to be important for translational and rotational stability in ACL-compromised knees.^{7,13} Failure to identify and address meniscus root tears may place undue loads on ACL grafts and lead to inferior postoperative outcomes.

Given the unique appearance of the posterior root of the lateral meniscus on magnetic resonance imaging (MRI) scans, a tear of this well-defined structure is often difficult to identify, even by fellowship-trained musculoskeletal radiologists.² Further, lateral meniscus root tears may be missed more frequently than medial meniscus root tears on MRI scans.¹⁰

The Orthopaedic Journal of Sports Medicine, 10(8), 23259671221114629

DOI: 10.1177/23259671221114629

© The Author(s) 2022

This open-access article is published and distributed under the Creative Commons Attribution - NonCommercial - No Derivatives License (<https://creativecommons.org/licenses/by-nc-nd/4.0/>), which permits the noncommercial use, distribution, and reproduction of the article in any medium, provided the original author and source are credited. You may not alter, transform, or build upon this article without the permission of the Author(s). For article reuse guidelines, please visit SAGE's website at <http://www.sagepub.com/journals-permissions>.

Pediatric and adolescent patients are at risk of meniscus root tears, and as many as 1 in 6 patients with meniscal pathology may have root pathology.¹⁶ With limited pediatric-specific outcome studies on meniscus root injuries, it is not surprising there is an interest in investigating this injury in the increasingly athletic pediatric population. Some pediatric-specific studies have suggested that the majority of patients have satisfactory outcomes after arthroscopic repair of meniscus root injuries.^{11,15}

To our knowledge, no study has compared the difference between preoperative diagnosis of LMPRT MRI scans versus operative diagnosis of LMPRT in a mixed pediatric and adolescent population. The primary goal of this retrospective study was to determine the frequency of missed LMPRTs in a cohort comprising a mixed pediatric and adolescent population.

METHODS

Institutional review board approval was waived for this study. We performed a retrospective chart review of patients younger than 18 years who underwent knee arthroscopy by a single surgeon between March 1, 2010, and April 1, 2020. The electronic medical records for each patient in this cohort were searched for Current Procedural Terminology (CPT) codes for either lateral meniscus root repair (CPT 29882, 29883) or partial lateral meniscectomy (CPT 29881). Next, the operative report for each patient identified was reviewed for the noted presence of LMPRT during arthroscopy. The preoperative MRI radiologist reports for these patients were then reviewed.

The following patients were excluded from the study: those without a preoperative MRI scan with a radiologist's report within 6 months of their surgery, those with presence or history of discoid meniscus, those with history of previous ACL reconstruction, those with a history of prior knee injury resulting in an altered morphology of the tibial plateau, and those with a history of prior knee surgery on the ipsilateral side. LMPRTs that were diagnosed on MRI scans but not real on arthroscopy were not investigated.

After identifying patients with an arthroscopically confirmed LMPRT using the LaPrade classification system,⁹ we revisited the preoperative MRI scans to identify evidence for a diagnosis of LMPRT. A preoperative diagnosis was considered "made" if the reading radiologist explicitly stated whether there was a tear of the posterior root of the lateral meniscus. If the reading radiologist used language to describe lateral meniscal pathology nonspecific to the

root, this was characterized as a "mentioned" diagnosis. If there was no mention at all of lateral meniscal pathology, the case was categorized as a "missed" diagnosis. For the purposes of this study, diagnosis mentioned and diagnosis missed were combined into a single group.

We recorded patient characteristics such as date of birth, sex, body mass index (BMI), insurance type (commercial or government), sport played at time of injury, age at time of injury, and skeletal maturity (defined as closure of the distal femoral physis on standard knee radiographs). Reported symptoms such as pain, locking, catching, loss of motion, and instability were assessed. Physical examination findings such as lateral joint line tenderness, results of McMurray test, and laterality were also recorded, as were data related to preoperative MRI, including days from injury to MRI examination, location where the MRI was performed, magnet strength (1.5 T or 3.0 T), days from MRI examination to surgery, fellowship training of the reading radiologist, the radiologist's MRI findings, and the radiologist's interpretation of the MRI scan. In terms of surgical management, the following data were recorded: days from injury to surgery, surgeon's finding at the time of arthroscopy, surgeon classification of the tear, surgical management of the root tear (root repair vs meniscectomy vs both repair and meniscectomy), and whether concomitant ACL reconstruction was performed.

After data collection, data were sent to an independent statistician for analysis. Descriptive statistics, including average and standard deviation for continuous variables and percentages for categorical variables, were calculated. Generalized linear mixed models were performed to compare the diagnosis-made group to the diagnosis-mentioned/missed group. Subject was included in the analyses as a random factor to take into account variability due to non-independence of the data. Alpha was set at $P < .05$ to declare significance, and analyses were performed using SPSS (Version 26; IBM Corp).

RESULTS

In total, 1116 knee arthroscopies were performed during the study period, and 49 LMPRTs were found. All 49 LMPRTs were found with concomitant ACL tears (49/535; 9.2%). There were 50 preoperative MRI scans to review for the 49 patients because 1 patient had 2 preoperative MRI scans due to reinjury after her initial preoperative visit but before her scheduled surgery. Thus, MRI scans were included for 24 girls and 26 boys. A flow diagram of patient

*Address correspondence to John Schlechter, DO, 1310 West Stewart Drive, Suite 508, Orange, CA 92868, USA (email: john_schlechter@yahoo.com) (Twitter: @Dr_Schlechter).

[†]Children's Hospital of Orange County, Orange, California, USA.

[‡]Riverside University Health System, Moreno Valley, California, USA.

[§]Community Memorial Health System, Ventura, California, USA.

Final revision submitted March 23, 2022; accepted April 20, 2022.

One or more of the authors has declared the following potential conflict of interest or source of funding: J.S. has received education payments from Arthrex and Micromed and speaking fees from Arthrex. T.P. has received education payments from SportsTek Medical. AOSSM checks author disclosures against the Open Payments Database (OPD). AOSSM has not conducted an independent investigation on the OPD and disclaims any liability or responsibility relating thereto.

Ethical approval for this study was waived by Children's Hospital of Orange County.

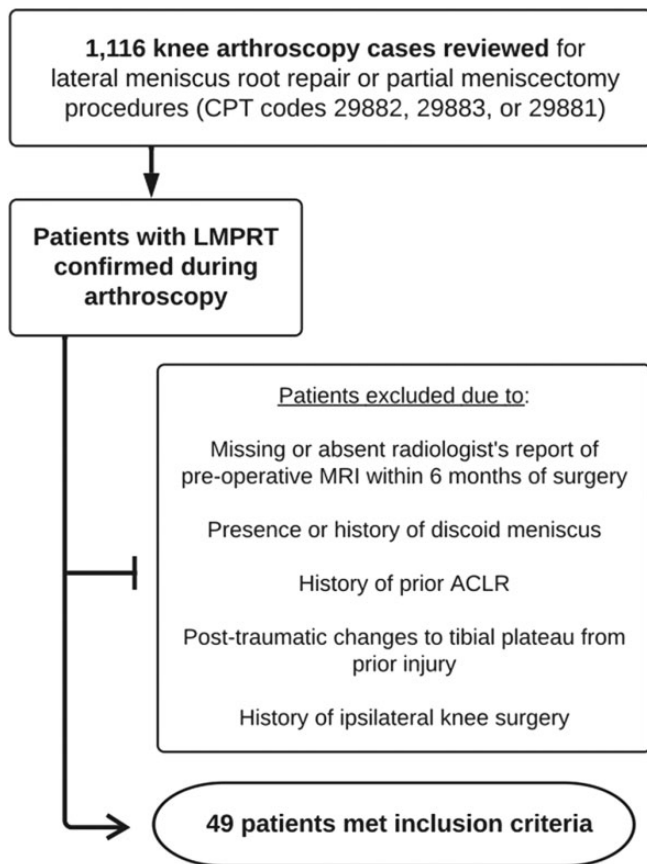


Figure 1. Flow diagram demonstrating patient selection and study methods. ACLR, anterior cruciate ligament reconstruction; CPT, Current Procedural Terminology; LMPRT, lateral meniscus posterior root tear; MRI, magnetic resonance imaging.

enrollment is shown in Figure 1, and patient and MRI characteristics are shown in Table 1.

Of the 50 MRI scans, the radiologist made a preoperative MRI diagnosis of LMPRT in 12 (24%) (diagnosis-made group). The diagnosis was missed in 19 images (38%), and the radiologist's notation of lateral meniscal pathology (not specific to the root, as described above) was mentioned in 19 images (38%), for a total of 38 images (76%) (diagnosis-missed/mentioned group). The average time from injury to MRI was 74.94 days, and the average time from MRI to surgery was 59.12 days.

Overall, the mean patient age was 15.97 years (range, 11.52-17.97 years), and the mean \pm standard deviation body mass index was 25.66 ± 4.88 . With regard to insurance type, 29 patients had private commercial insurance, whereas 21 had government insurance. No significant differences were found in patient sex between the study groups (female patients: 5 [diagnosis made] vs 19 [diagnosis missed/mentioned]; $P = .638$). Overall, 44 patients were classified as skeletally mature. There was no significant difference in the status of the physis between the groups (closed physis: 12 [diagnosis made] vs 32 [diagnosis missed/mentioned]; $P = .306$).

Both 1.5-T ($n = 41$) and 3.0-T ($n = 9$) MRI field strengths were used for our study. We found no difference in the strength of the magnet in MRI performance between the 2 groups ($P = .935$). Of the reading radiologists, 14 were musculoskeletal fellowship trained. In addition, fellowship training did not make a difference in the accuracy of MRI diagnosis ($P = .255$).

During the review, we identified a previously undescribed tear pattern in which root tears also had a concomitant radial tear of the midbody. We modified the LaPrade classification system to include this tear type as "type 6," indicating that an LMPRT with a concomitant radial tear of the midbody of the lateral meniscus was observed. We noted no difference between the study groups in regard to surgeon classification of tear ($P = .97$).

DISCUSSION

In the current study, the final interpretation of the preoperative MRI scans did not provide a clear, definitive diagnosis of an LMPRT in 76% of arthroscopically confirmed tears. To our knowledge, this is the first study to investigate the accuracy of the preoperative MRI diagnosis of LMPRTs in a mixed pediatric and adolescent population.

The lateral meniscus posterior root has a broad attachment and crosses the midline to attach to the medial tibial eminence. Disruption of this attachment compromises hoop stresses and anchoring to the tibial plateau.¹³ Neglected meniscus root tears place excess stress on the articular cartilage and increase the risk of premature osteoarthritis. Some authors propose that these tears behave like total meniscectomies.³

Given the unique anatomy of the meniscus root, diagnosis using advanced imaging such as MRI poses diagnostic and therapeutic challenges. Many studies investigating the diagnosis of knee internal derangement have emphasized the importance of careful evaluation of the posterior horn of the lateral meniscus.⁴ Complete agreement between MRI interpretations and intraoperative diagnosis is not feasible, as some tears are not detectable on MRI slices.

Munger et al¹² investigated the diagnostic ability of MRI to detect meniscal injuries in pediatric and adolescent patients undergoing arthroscopic primary ACL reconstruction. They emphasized the overall need for more pediatric-specific research, as findings within the orthopaedic adult literature may not always be applicable to pediatric and adolescent populations. In their pediatric and adolescent group, there were 26 patients (24.3%) with unrecognized meniscal injuries on MRI scans of ACL-deficient knees. The authors noted the importance of these findings as highlighting the potential benefits of patient counseling, operative planning, and anticipatory guidance on postoperative rehabilitation, recovery expectations, and surgical outcomes.

No LMPRT in our study population occurred in isolation. All were diagnosed concomitantly with ACL tears (49/535; 9.2%). The finding that all LMPRTs in this study were present with ACL pathology is similar to what has previously been reported. Wilson et al¹⁶ compared meniscus root

TABLE 1
Patient Variables and MRI Performance^a

Variable ^b	Diagnosis Made (n = 12)	Diagnosis Missed/Mentioned (n = 38)	P
Patient characteristics			
Sex: female (n = 24)	5	19	.638
Age when injured, y (15.97 ± 1.44)	16.54 ± 1.10	15.79 ± 1.51	.12
Body mass index (25.66 ± 4.88)	26.27 ± 4.97	25.47 ± 4.90	.509
Skeletal maturity: closed physis (n = 44)	12	32	.306
Insurance type			.499
Commercial (n = 29)	8	21	
Government (n = 21)	4	17	
Injury characteristics			
Time from injury to MRI, d (74.94 ± 173.89)	112.25 ± 319.50	63.16 ± 95.416	.415
Time from injury to surgery, d (134.06 ± 183.02)	174.42 ± 320.35	121.32 ± 114.687	.408
Time from MRI to surgery, d (59.12 ± 40.61)	62.17 ± 55.26	58.16 ± 35.671	.819
Lateral joint line tenderness: yes (n = 23)	7	16	.354
MRI characteristics ^c			
MRI magnet			.935
1.5 T (n = 41)	10	31	
3.0 T (n = 9)	2	7	
Musculoskeletal trained radiologist			.255
Yes (n = 14)	5	9	
No (n = 36)	7	29	
Tear classification on MRI scan ^d			.97
1 (n = 11)	5	6	
2a (n = 3)	0	3	
2b (n = 2)	0	2	
2c (n = 3)	1	2	
3 (n = 3)	0	3	
4 (n = 14)	0	14	
6 (n = 14)	6	8	

^aData are presented as No. of patients or mean ± SD. MRI, magnetic resonance imaging.

^bData in parentheses describe the overall cohort for that variable.

^c50 MRI scans were counted for 49 patients in this table because 1 patient had 2 MRI scans.

^dTears were classified according to the modified LaPrade classification system.¹² Type 6 indicated a lateral meniscus posterior root tear with a concomitant radial tear of the midbody of the lateral meniscus.

injuries with nonroot meniscal tears in patients of all ages and found that meniscus root injuries were far less likely to occur in isolation. The 9.2% rate of concomitant ACL tears is similar to that reported by a large epidemiological study published in 2019, wherein 262 patients with LMPRTs were found in a total of 3956 patients undergoing ACL reconstruction (6.6%).¹⁴

Krych et al⁸ published a similar study regarding the preoperative identification of LMPRTs. Those authors retrospectively investigated the rate of preoperative MRI diagnoses in a consecutive series of arthroscopically confirmed LMPRTs, with the hypothesis that the majority of LMPRTs would be detected on preoperative MRI scans. Their cohort of 45 patients had an average age of 27 years (range, 14-54 years). However, our study population was younger, with an average age at the time of injury of 15.97 years (range, 11.52-17.97 years). Our finding that final interpretation of preoperative MRI scans did not provide a definitive diagnosis of LMPRT in 76% of patients is novel for its derivation from a completely pediatric and adolescent cohort. Our study also differs from that by Krych et al in that we classified each preoperative MRI scan using

the categories they used (“diagnostic” and “missed”) in combination with a third category: “mentioned.” This third category was used to classify lateral meniscal pathology with greater granularity, whereby although the lateral meniscus was mentioned, the root was not specifically isolated. This highlights the possibility of encountering a root tear with an inconclusive MRI reading.

Similar to the findings in this study, Krych et al⁸ concluded that 15 of 45 LMPRTs (only 33%) were initially diagnosed based on preoperative MRI interpretations, meaning that preoperative MRI scans did not correctly identify a posterior root tear or avulsion in 67% of their study population. Another interesting aspect of the Krych et al study is that the 30 MRI scans associated with missed diagnoses were retrospectively reviewed in an unblinded manner by musculoskeletal-trained radiologists who worked in consensus. The results of this unblinded review showed that 15 of the 30 missed LMPRTs were “clearly evident” and should have been diagnosed, 12 were found to be “subtly evident,” and 3 were “occult and unavoidably missed.” Proposed reasons for missed meniscus root tears in this cohort were postoperative scarring with obscured and altered

anatomy. For the younger cohort included in the present study, postoperative scarring with obscured and altered anatomy was not common.

Of note in the current study, we found no difference in MRI field strength between a definitive diagnosis of LMPRT and a missed or mentioned diagnosis ($P = .935$). Similar findings have previously been reported.^{2,8} Previous studies have shown that meniscus root injuries are more likely than nonroot injuries to present with joint line tenderness on initial examination.¹⁶ In one study, 96.5% of the meniscus root injury group had tenderness at their respective joint lines compared with only 58.6% of the nonroot injury group ($P < .001$).¹⁶ Within our study's limited dataset, there were no differences in preoperative physical examination findings such as joint line tenderness between a definitive diagnosis of LMPRT and a missed/mentioned diagnosis ($P = .354$).

This is the first study of its kind to investigate the accuracy of preoperative MRI diagnosis in the diagnosis of LMPRTs in a mixed pediatric and adolescent population. As has been demonstrated in the literature, neglected root tears have biomechanical implications similar to those of total meniscectomies.² Such consequences have special gravity in the pediatric and adolescent population. In regard to patient, radiographic, or other clinical factors, we found no differences between the group in which a diagnosis was made and the group in which a diagnosis was not explicitly stated.

Limitations

Limitations of this study include its retrospective nature. Additionally, because the average time from MRI to surgery was 59.12 days, this introduces the possibility that patients may have sustained a posterior root tear after obtaining the MRI. Barring a reinjury event, this may be unlikely. However, further research is needed to investigate the temporal relationship of ACL deficiency and meniscal compromise specific to the lateral meniscus root in pediatric and adolescent patients. Interestingly, one patient in this study obtained 2 preoperative MRI scans because she had a reinjury from the time of the initial preoperative evaluation to surgery. The first MRI scan was read as having a "vertical tear of the posterior horn of the lateral meniscus," whereas the second MRI scan was read as "the menisci are grossly intact." Although it is the custom and practice of the senior surgeon read all MRI scans and record findings whether in agreement or not with the radiologist, these readings were not included in this study, as not all practitioners are subspecialized in reading adolescent knee MRI scans. General practitioners and advanced practice providers may rely on the radiologist's reading, and this information we present is valuable to all those interpreting these MRI scans.

Another consideration is the increased recognition and vigilance for assessing meniscus root tears in recent years. As this study covered a 10-year period, it is possible that more root tears were missed in earlier years. However, when the MRI scans are divided into 2 time frames, those obtained between 2010 and 2015 and those obtained

between 2016 and 2020, most of the scans are from the later time frame (36/50; 72%). Additionally, a clear diagnosis was made in only 7 of 36 (19%) MRI scans from the later time frame, whereas a definitive diagnosis was made in 5 of 14 (36%) scans from the earlier time frame.

CONCLUSION

This study highlights the utility of the surgeon's scrutiny of advanced imaging, as LMPRTs are often missed even by musculoskeletal fellowship-trained radiologists. Posterior root tears may be detected via high signal disruptions at the attachments as seen on axial slices and via a "ghost sign," which indicates an absent meniscus in sagittal slices.^{9,13}

Even in the absence of a preoperative MRI diagnosis, surgeons should have a high index of suspicion, and they should carefully inspect the lateral posterior roots and be prepared to handle these unique tears. Root repairs have been found to improve clinical outcomes in a cost-effective manner.^{5,6} However, root repairs diverge from standard meniscal work. In this study, patients with a repairable root underwent transosseous suture fixation using specialized suture passing devices and retrograde drilling. Such specialty items may not always be readily available. Detection and surgical repair of these defects are linked to favorable outcomes, but preoperative identification continues to be challenging.^{11,15} As athletic participation in nonadult patients continues to increase, so do associated injuries. Given that general practitioners and advanced practitioners who often rely on MRI interpretation are at the forefront of patient referrals, we hope this study furthers interest and research on this diagnostically challenging pathology.

ACKNOWLEDGEMENT

The authors thank Rachel Davis for her assistance with the manuscript.

REFERENCES

1. Allaire R, Muriuki M, Gilbertson L, Harner CD. Biomechanical consequences of a tear of the posterior root of the medial meniscus: similar to total meniscectomy. *J Bone Joint Surg Am.* 2008;90(9):1922-1931.
2. Bhatia S, LaPrade CM, Ellman MB, LaPrade RF. Meniscal root tears: significance, diagnosis, and treatment. *Am J Sports Med.* 2014;42(12):3016-3030.
3. Chahla J, LaPrade RF. Meniscal root tears. *Arthroscopy.* 2019;35(5):1304-1305.
4. De Smet AA, Mukherjee R. Clinical, MRI, and arthroscopic findings associated with failure to diagnose a lateral meniscal tear on knee MRI. *AJR Am J Roentgenol.* 2008;190(1):22-26.
5. Faucett SC, Geisler BP, Chahla J, et al. Meniscus root repair vs meniscectomy or nonoperative management to prevent knee osteoarthritis after medial meniscus root tears: clinical and economic effectiveness. *Am J Sports Med.* 2019;47(3):762-769.
6. Feucht MJ, Izadpanah K, Lacheta L, Südkamp NP, Imhoff AB, Forkel P. Arthroscopic transtibial pullout repair for posterior meniscus root tears. *Oper Orthopädie Traumatol.* 2019;31(3):248-260.
7. Frank JM, Moatshe G, Brady AW, et al. Lateral meniscus posterior root and meniscofemoral ligaments as stabilizing structures in the

- ACL-deficient knee: a biomechanical study. *Orthop J Sports Med.* 2017;5(6):2325967117695756.
8. Krych AJ, Wu IT, Desai VS, et al. High rate of missed lateral meniscus posterior root tears on preoperative magnetic resonance imaging. *Orthop J Sports Med.* 2018;6(4):232596711876572.
 9. LaPrade CM, James EW, Cram TR, Feagin JA, Engebretsen L, LaPrade RF. Meniscal root tears: a classification system based on tear morphology. *Am J Sports Med.* 2015;43(2):363-369.
 10. LaPrade RF, Ho CP, James E, Crespo B, LaPrade CM, Matheny LM. Diagnostic accuracy of 3.0 T magnetic resonance imaging for the detection of meniscus posterior root pathology. *Knee Surg Sports Traumatol Arthrosc.* 2015;23(1):152-157.
 11. Liechti DJ, Constantinescu DS, Ridley TJ, Chahla J, Mitchell JJ, Vap AR. Meniscal repair in pediatric populations: a systematic review of outcomes. *Orthop J Sports Med.* 2019;7(5):2325967119843355.
 12. Munger AM, Gonsalves NR, Sarkisova N, Clarke E, VandenBerg CD, Pace JL. Confirming the presence of unrecognized meniscal injuries on magnetic resonance imaging in pediatric and adolescent patients with anterior cruciate ligament tears. *J Pediatr Orthop.* 2019;39(9):e661-e667.
 13. Pache S, Aman ZS, Kennedy M, et al. Meniscal root tears: current concepts review. *Arch Bone Jt Surg.* 2018;6(4):250-259.
 14. Praz C, Vieira TD, Saithna A, et al. Risk factors for lateral meniscus posterior root tears in the anterior cruciate ligament-injured knee: an epidemiological analysis of 3956 patients from the SANTI Study Group. *Am J Sports Med.* 2019;47(3):598-605.
 15. Willimon SC, Busch M, Murata A, Perkins C. Meniscal root repair in pediatric patients: minimum 2-year outcomes. Abstract. *Orthop J Sports Med.* 2021;9(10)(suppl 5):2325967121S00307.
 16. Wilson PL, Wyatt CW, Romero J, Sabatino MJ, Ellis HB. Incidence, presentation, and treatment of pediatric and adolescent meniscal root injuries. *Orthop J Sports Med.* 2018;6(11):2325967118803888.
 17. Wroble RR, Henderson RC, Champion ER, el-Khoury GY, Albright JP. Meniscectomy in children and adolescents: a long-term follow-up study. *Clin Orthop Relat Res.* 1992;279:180-189.