

Multicentric primary diffuse large B-cell lymphoma in genitourinary tract detected on ¹⁸F-fluorodeoxyglucose positron emission tomography with computed tomography: An uncommon presentation of a common malignancy

ABSTRACT

Primary extranodal lymphomas (ENLs) are lymphomas with no or minor nodal involvement and a dominant extranodal component originating from any organ. Primary ENL originating in the genitourinary tract is extremely rare. Diffuse large B-cell lymphoma (DLBCL) is the most frequent histological subtype in primary genitourinary lymphoma. Lymphomatous involvement of genitourinary system organs is common in the setting of disseminated disease. Herein, we present a unique case of primary multicentric extranodal DLBCL of the urogenital system involving ureter, seminal vesicle, and penis detected on ¹⁸F-fluoro-deoxyglucose positron emission tomography with computed tomography, and to the best of our knowledge, it is the first case report with multiorgan involvement within a single (urogenital) organ system in a patient without disseminated disease, i.e., with no other nodal or extranodal organ system involvement.

Keywords: ¹⁸F-fluorodeoxyglucose positron emission tomography with computed tomography, diffuse large B-cell lymphoma, extranodal lymphoma, primary urogenital lymphoma

INTRODUCTION

Primary extranodal lymphomas (ENLs) are lymphomas with no or minor nodal involvement and a dominant extranodal component originating from any organ.^[1] Greater predilection has been observed for gastrointestinal tract, head and neck, orbit, central nervous system, lung, bone, and skin.^[2] Primary ENL originating in the genitourinary tract is extremely rare forming <5% of all ENLs.^[3] Diffuse large B-cell lymphoma (DLBCL) is the most frequent histological subtype in Primary Genito-Urinary Lymphoma (PGUL).^[1]

We report a case of PGUL detected on ¹⁸F-18F-fluorodeoxyglucose positron emission tomography with computed tomography (¹⁸F-FDG PET-CT) involving distal left ureter, right seminal vesicle, and penis.

CASE REPORT

A 59-year-old male patient presented with abdominal discomfort for 2–3 weeks. There was no history of fever or weight loss. CT scan of kidney, ureters, and bladder (CT-KUB)

ASRA PATEL, INDIRANI MUTHUKRISHNAN, ANN KURIAN¹, JAYKANTH AMALCHANDRA, NIKITA SAMPATHIRAO, SHELLEY SIMON

Departments of Nuclear Medicine and ¹Pathology, Apollo Hospitals, Chennai, Tamil Nadu, India


Address for correspondence: Dr. Shelley Simon, Department of Nuclear Medicine, #21 Greams Lane, Off, Greams Road, Apollo Hospitals, Chennai, Tamil Nadu, India. E-mail: shelleyssimon@rediffmail.com

Submitted: 10-Apr-2020, **Revised:** 13-May-2020, **Accepted:** 23-May-2020, **Published:** 22-Aug-2020

This is an open access journal, and articles are distributed under the terms of the Creative Commons Attribution-NonCommercial-ShareAlike 4.0 License, which allows others to remix, tweak, and build upon the work non-commercially, as long as appropriate credit is given and the new creations are licensed under the identical terms.

For reprints contact: WKHLRPMedknow_reprints@wolterskluwer.com

How to cite this article: Patel A, Muthukrishnan I, Kurian A, Amalchandra J, Sampathirao N, Simon S. Multicentric primary diffuse large B-cell lymphoma in genitourinary tract detected on ¹⁸F-fluorodeoxyglucose positron emission tomography with computed tomography: An uncommon presentation of a common malignancy. World J Nucl Med 2021;20:117-20.

Access this article online	
Website: www.wjnm.org	Quick Response Code 
DOI: 10.4103/wjnm.WJNM_45_20	

showed enhancing nonnecrotic soft-tissue density lesion measuring approximately 2.8 cm × 1.5 cm in the distal left ureter with resultant left mild hydroureteronephrosis. Urine sample for cytology revealed no malignant cells. The patient underwent an ¹⁸F-FDG PET CT whole-body scan, which revealed hypermetabolic enhancing nonnecrotic lesion in the distal left ureter (SUV_{max} 19.6) causing mild left hydroureteronephrosis with delayed contrast excretion from the left kidney. Diffusely increased ¹⁸F-FDG accumulation was seen in the cortex of the left kidney with no focal lesion. Hypermetabolic lesions were also found in the right seminal vesicle (SUV_{max} 18.2) and in the shaft of the penis involving corpora cavernosa and corpus spongiosum (SUV_{max} 7.1) [Figure 1a-e]. The imaging differential diagnoses included infection, extranodal PGUL, and rare possibility of limited urogenital Wegener's granulomatosis.^[4] The diffuse FDG uptake in the left kidney could be due to (1) delayed excretion of tracer secondary to pressure effect from the left ureteric lesion and (2) lymphomatous involvement of the left kidney. There have been case reports showing diffusely increased FDG uptake in primary renal lymphoma with no lesion on CT, which is the blind spot of anatomical imaging.^[5] The patient underwent left ureteroscopy and mucosal biopsy of the left distal ureteric lesion due to easy accessibility which revealed intermediate-sized atypical mononuclear cell infiltrate [Figure 2a]. Immunohistochemistry was positive for CD20, BCL2, and MUM1 and negative for CD3, CD138, BCL6, CD23, CD5, CD10, and Cyclin D1 with high proliferation

on Ki-67 index, consistent with DLBCL, not otherwise specified, immunohistochemical subgroup nongermlinal center B-cell type [Figure 2b-h]. The patient was started on systemic chemotherapy. Additional biopsy of the left kidney was deferred as it would not result in any alteration in management, higher risk–benefit ratio, and ethical concern.

DISCUSSION

The diagnosis of ENL has prognostic implications. The prognosis of DLBCL in ENL is worse compared to nodal DLBCL. The poorer prognosis of PGUL has been accounted to the comorbidities due to obstruction or acute kidney injury in case of renal involvement.^[6]

It is hypothesized that the primary urinary tract lymphomas may arise due to the lymphoid cells attracted by recurrent urinary tract infections or silent inflammatory process. This hypothesis is supported by regression of mucosa-associated lymphoid tissue-associated lymphoma by antibiotic therapy.^[6] Hematogenous dissemination or direct extension from another occult site of disease may occur.^[3]

PGUL has varied clinical presentation depending on the site of involvement as reported in a series of forty cases by Schniederjan and Osunkoya. This includes palpable mass, hematuria, abdominopelvic pain, and voiding difficulty.^[3] In patients with ureteral involvement, typical presentation

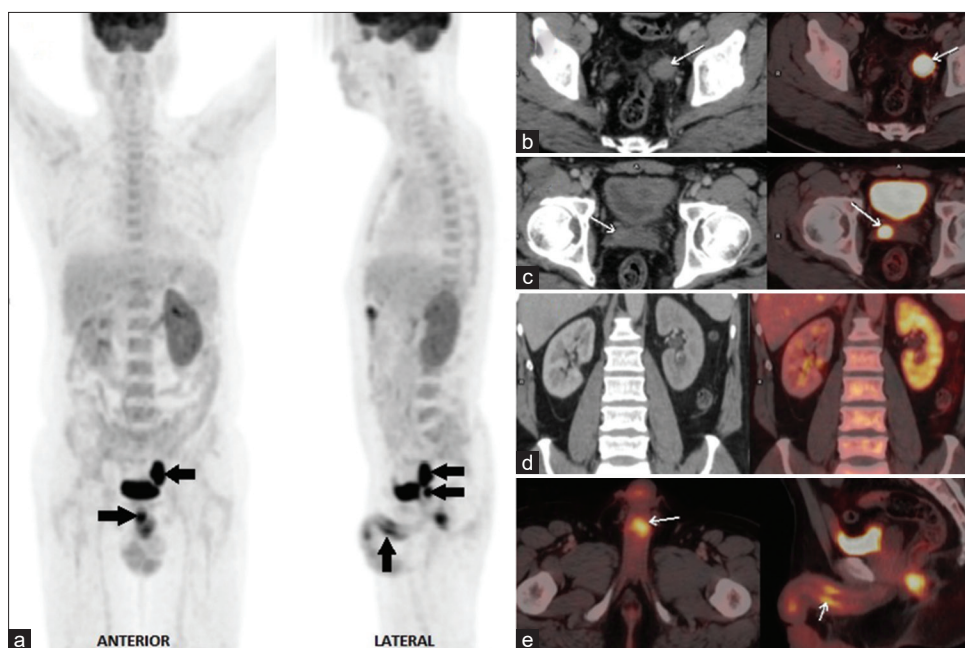


Figure 1: ¹⁸F-fluorodeoxyglucose positron emission tomography with computed tomography scan images (a) Maximum-intensity projection images, (b and c) axial computed tomography and fused positron emission tomography with computed tomography images of hypermetabolic lesion in the distal left ureter and right seminal vesicle, respectively, (d) coronal computed tomography and fused positron emission tomography with computed tomography images showing left mild hydroureteronephrosis and diffusely increased ¹⁸F-fluorodeoxyglucose uptake in the cortex of the left kidney, (e) fused positron emission tomography with computed tomography images of hypermetabolic lesion in the shaft of the penis

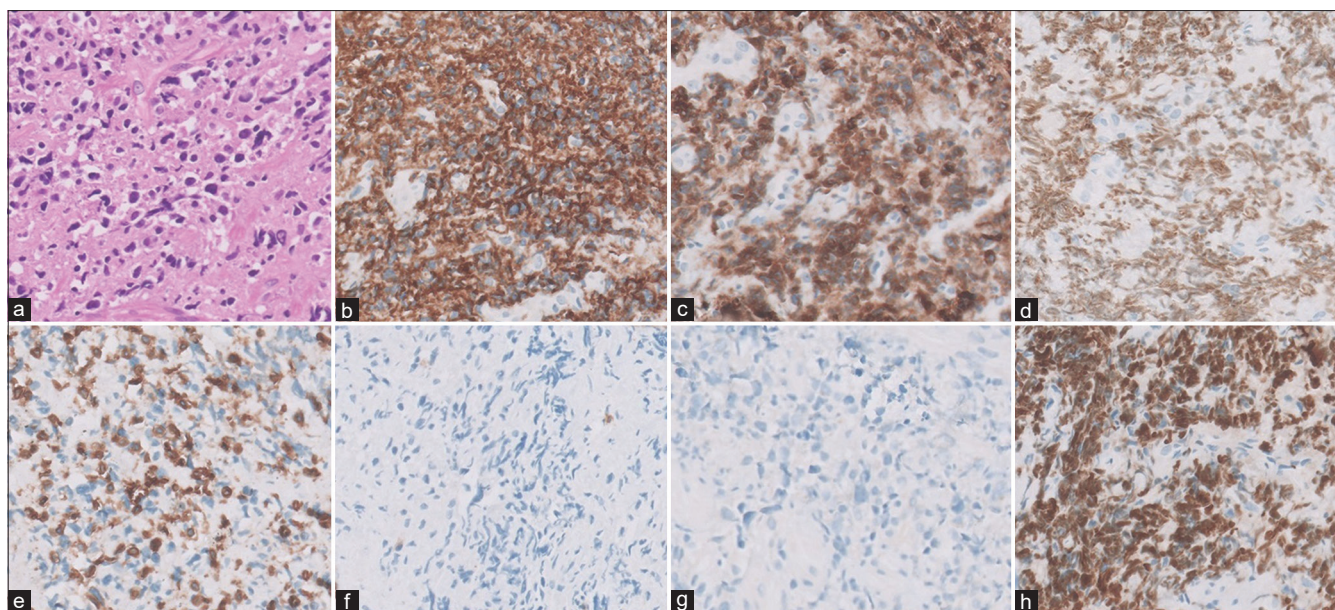


Figure 2: Histopathology and immunohistochemistry images of diffuse large B-cell lymphoma, not otherwise specified: (a) Sheets of intermediate-sized mononuclear cells (H and E, $\times 400$), Immunohistochemistry of atypical cells was diffusely positive for - (b) CD20 ($\times 400$), (c) BCL2 ($\times 400$), (d) MUM1 ($\times 400$) and negative for (e) CD3 ($\times 400$), (f) CD138 ($\times 400$), and (g) Cyclin D1 ($\times 400$), (h) high proliferation with Ki67 labeling index ($\times 400$)

is obstructive symptomatology and may subsequently develop hydronephrosis.^[3,7] In penile involvement, patients may present with a painless mass.^[8] In our case, the patient presented with obstructive symptoms, i.e., abdominal discomfort secondary to left-sided hydronephrosis.

Ureteral and penile primary lymphomas are very rare. In the case series of Schniederjan and Osunkoya,^[3] only one out of forty patients had primary ureteral lymphoma and two patients had penile lymphoma. None of the patients had involvement of seminal vesicles. There are individual case reports with primary lymphomatous involvement of seminal vesicles.^[9-11] Oral *et al.* reported a case of non-Hodgkin's lymphoma (NHL) involving the whole genitourinary system along with pulmonary and adrenal involvement.^[12]

¹⁸F-FDG is excreted by the kidneys into the urinary tract and bladder. Hence, false-positive and false-negative PET interpretations can occur in patients with lesions in these organs.^[2] Renal involvement in ENL most frequently presents as multiple nodules corresponding to increased ¹⁸F-FDG uptake and less commonly presents as diffuse involvement.^[13] As mentioned earlier, PGUL has a poor prognosis secondary to (1) obstruction and (2) acute kidney injury in case of renal involvement.^[6] In our case, the serum creatinine and urea levels of the patient were within normal limits. PET-CT scan showed diffuse ¹⁸F-FDG tracer activity in the left kidney, which could be accounted by either of the aforementioned etiologies. Additional biopsy of the left kidney was deferred as it would not alter the management, and due to higher

risk/benefit ratio and ethical concern. Hence, the patient was started on systemic chemotherapy and is due for a posttreatment follow-up PET-CT scan. The resolution of ¹⁸F-FDG uptake in the kidney in posttreatment PET-CT could result from the response of the lymphomatous involvement of the kidney *per se* or alleviation of pressure effect due to the response of the ureteric lesion. Hence, the inconclusiveness pertaining to the renal involvement in this case remains as a limitation.

It has been established that ¹⁸F-FDG PET/CT imaging plays a crucial role in the staging of ENL. PET/CT scan upstages the disease in 31% of cases of NHL and downstages in 1% of cases.^[2] It is especially beneficial in the detection of unexpected extranodal sites of disease not identified on conventional CT.^[14,15] It has been reported that ¹⁸F-FDG PET/CT imaging changes the treatment approach in 25% of patients of NHL as compared to conventional CT imaging.^[2] It is also indicated in monitoring the response to therapy, and in the detection of recurrence or restaging.

In our patient, the CT-KUB revealed only the left distal ureteric lesion. The ¹⁸F-FDG PET-CT scan identified the additional sites of involvement, thus changing the disease management from primary surgical to systemic chemotherapy.

Lymphomatous involvement of the genitourinary system organs is common in the setting of disseminated disease.^[16] Our case is unique due to the fact that there is primary lymphomatous involvement of the genitourinary system and

to the best of our knowledge, it is the first case to be reported with multicentric involvement within a single organ system without disseminated disease.

CONCLUSION

Although lymphomatous involvement of the genitourinary system organs is rare in the absence of disseminated disease, familiarity with such a presentation is crucial for accurate imaging diagnosis. Simultaneous involvement of multiple organs within a single organ system should raise the suspicion of extranodal lymphoma and should be considered as one of the differential diagnoses.

Declaration of patient consent

The authors certify that they have obtained all appropriate patient consent forms. In the form the patient(s) has/have given his/her/their consent for his/her/their images and other clinical information to be reported in the journal. The patients understand that their names and initials will not be published and due efforts will be made to conceal their identity, but anonymity cannot be guaranteed.

Financial support and sponsorship

Nil.

Conflicts of interest

There are no conflicts of interest.

REFERENCES

- Palumbo C, Mazzone E, Mistretta FA, Knipper S, Tian Z, Perotte P, *et al.* Primary lymphomas of the genitourinary tract: A population-based study. *Asian J Urol* 2019;11:1-8.
- Paes FM, Kalkanis DG, Sideras PA, Serafini AN. FDG PET/CT of extranodal involvement in non-Hodgkin lymphoma and Hodgkin disease. *Radiographics* 2010;30:269-91.
- Schniederjan SD, Osunkoya AO. Lymphoid neoplasms of the urinary tract and male genital organs: A clinicopathological study of 40 cases. *Mod Pathol* 2009;22:1057-65.
- Davenport A, Downey SE, Goel S, Maciver AG. Wegener's granulomatosis involving the urogenital tract. *Br J Urol* 1996;78:354-7.
- Navalkisoor S, Szyszko T, Gnanasegaran G, Nunan T. Diffuse FDG renal uptake in lymphoma. *Clin Nucl Med* 2010;35:813-5.
- Lontos K, Tsagianni A, Msaouel P, Appleman LJ, Nasioudis D. Primary urinary tract lymphoma: Rare but aggressive. *Anticancer Res* 2017;37:6989-95.
- Kubota Y, Kawai A, Tsuchiya T, Kozima K, Yokoi S, Deguchi T. Bilateral primary malignant lymphoma of the ureter. *Int J Clin Oncol* 2007;12:482-4.
- Wei CC, Peng CT, Chiang IP, Wu KH. Primary B cell non-Hodgkin lymphoma of the penis in a child. *J Pediatr Hematol Oncol* 2006;28:479-80.
- Handa N, Rathinam D, Singh A, Jana M. Seminal vesicle involvement: A rare extranodal manifestation of non-Hodgkin's lymphoma. *BMJ Case Rep* 2016;2016:bcr2015213554.
- Zhu J, Chen LR, Zhang X, Gong Y, Xu JH, Zheng S. Primary diffuse large B-cell lymphoma of the seminal vesicles: Ultrasonography and computed tomography findings. *Urology* 2011;78:1073-4.
- Kwag KS, Jang SJ, Yeon JW, Kwon KW, Son JH, Kim HJ. Primary diffuse large B-cell lymphoma of the seminal vesicle: A case report. *IMRI* 2016;20:259-63.
- Oral A, Yazıcı B, Ömür Ö. ¹⁸F-FDG PET/CT findings of non-Hodgkin lymphoma involving the whole genitourinary system. *Mol Imaging Radionucl Ther* 2018;27:138-40.
- Metser UR, Goor O, Lerman H, Naparstek E, Even-Sapir E. PET-CT of extranodal lymphoma. *Am J Radiol* 2004;182:1579-86.
- Even-Sapir E, Lievshitz G, Perry C, Herishanu Y, Lerman H, Metser UR. Fluorine-18 fluorodeoxyglucose PET/CT patterns of extranodal involvement in patients with non-hodgkin lymphoma and Hodgkin's disease. *Radiol Clin N Am* 2007;45:251-65.
- Moog F, Bangerter M, Diederichs C, Guhlmann A, Merkle E, Frickhofen N, *et al.* Extranodal malignant lymphoma: Detection with FDG PET versus CT. *Radiology* 1998;206:475-81.
- Zukotynski K, Lewis A, O'Regan K, Jacene H, Samuel CS, Almodovar S, *et al.* PET/CT and renal pathology: A blind spot for radiologists? Part 2 – Lymphoma, leukemia, and metastatic disease. *AJR Am J Roentgenol* 2012;199:W168-74.