

# Pancreatoduodenectomy for bile duct and ampullary cancer

Koji Yamaguchi

Published online: 15 December 2011

© The Author(s) 2011. This article is published with open access at Springerlink.com

**Abstract** Pylorus-preserving pancreatoduodenectomy has become a standard operation for distal and middle bile duct cancers. Bile duct cancer typically extends longitudinally and invades vertically. It frequently metastasizes to the lymph nodes and infiltrates the perineural spaces. The presence of residual cancer in the bile duct stump and lymph node metastases are significant prognostic factors. Negative surgical margins and D2 lymph node dissection are necessary for curative resection. The clinical course after portal vein resection for bile duct cancer with portal vein invasion is better than that of non-resectable bile duct cancer. Portal vein resection can therefore be useful. The efficacy of prophylactic portal vein resection is unclear. We describe here our methods for performing pylorus-preserving pancreatoduodenectomy for bile duct cancer.

**Keywords** Pancreatoduodenectomy · Bile duct cancer · Ampullary cancer · Lymph node dissection · Pancreaticojejunostomy

---

This article is based on studies first reported in *Highly Advanced Surgery for Hepato-Biliary-Pancreatic Field* (in Japanese). Tokyo: Igaku-Shoin, 2010.

---

**Electronic supplementary material** The online version of this article (doi:10.1007/s00534-011-0480-8) contains supplementary material, which is available to authorized users.

---

K. Yamaguchi (✉)  
Department of Surgery 1, School of Medicine, University  
of Occupational and Environmental Health, Kitakyushu, Japan  
e-mail: yamaguch@med.uoeh-u.ac.jp

## Introduction

Pancreatoduodenectomy is usually the operation of choice for pancreatoduodenal cancer [1]. Pancreatoduodenal cancer consists of duodenal cancer, distal bile duct cancer, pancreatic head cancer, and ampullary cancer according to the site of origin. Of these four cancers, the resectability of ampullary cancer or distal bile duct cancer is higher than that of pancreatic head cancer, and the clinical course of ampullary cancer or distal common bile duct cancer is better than that of pancreatic head cancer. Thus, safe and accurate pancreatoduodenectomy is important for ampullary cancer and distal bile duct cancer. In this paper, we describe our methods of pancreatoduodenectomy for bile duct cancer.

## Laparotomy

The abdomen is opened using an upper midline incision from the xyphoid process to 2–3 cm below the navel to obtain a satisfactory surgical view. The abdominal wound is covered by a ring drape to prevent wound infection. Kent retractors are applied to the bilateral costal margins to open the abdomen wide. The presence or absence of peritoneal seeding of cancer cells is evaluated macroscopically, and abdominal cavity washing is submitted for intraoperative cytology.

## Kocher's mobilization

Kocher's mobilization is begun between the posterior aspect of the pancreas head and the vena cava, then further extended into the aorta. When the para-aortic lymph node is massively swollen, a lymph node biopsy should be performed and the specimen should be submitted for

intraoperative frozen section diagnosis. If the lymph nodes examined show metastatic cancer, pancreaticoduodenectomy should not be performed.

**The mesenteric approach**

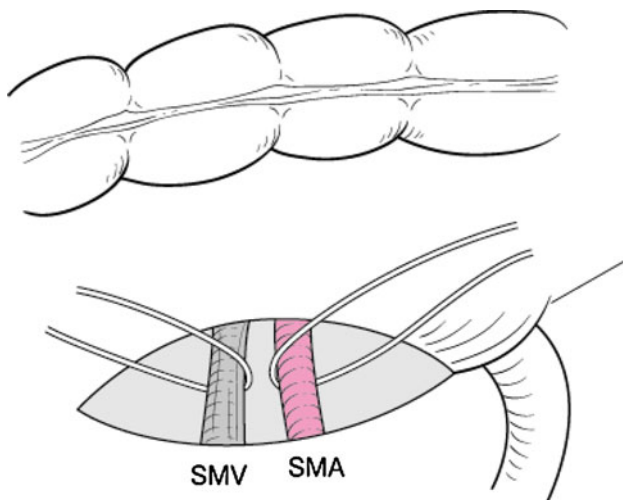
At the caudal aspect of the head of the pancreas, the superior mesenteric vein is isolated at the neck of the pancreas. Thereafter, the transverse colon is lifted to the cephalic side, and the serosal surface of the meso-transverse colon is excised to the Treitz ligament just below the pancreas. The superior mesenteric vein and artery are separately isolated and taped (Fig. 1). The middle colic artery and vein are ligated and excised at the branching point. Between the superior mesenteric vein and artery, the inferior pancreaticoduodenal artery is identified, then ligated and cut to decrease bleeding from the head of the pancreas during subsequent procedures.

**Cholecystectomy**

The serosa of the fundus of the gallbladder is excised, and the gallbladder is dissected free from the liver bed from the fundus to the neck using an ultrasonic device. At Calot’s triangle, the cystic artery is identified and doubly ligated, and then the cystic duct is also isolated.

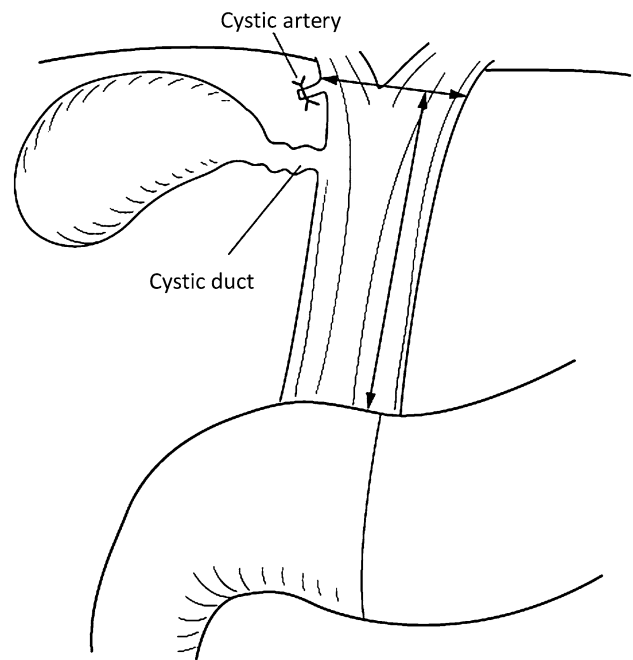
**Skeletonization of the hepatoduodenal ligament and lymph node dissection**

The serosa of the hepatoduodenal ligament is excised transversely at the hepatic hilum, and is excised along the left side of the hepatoduodenal ligament longitudinally in

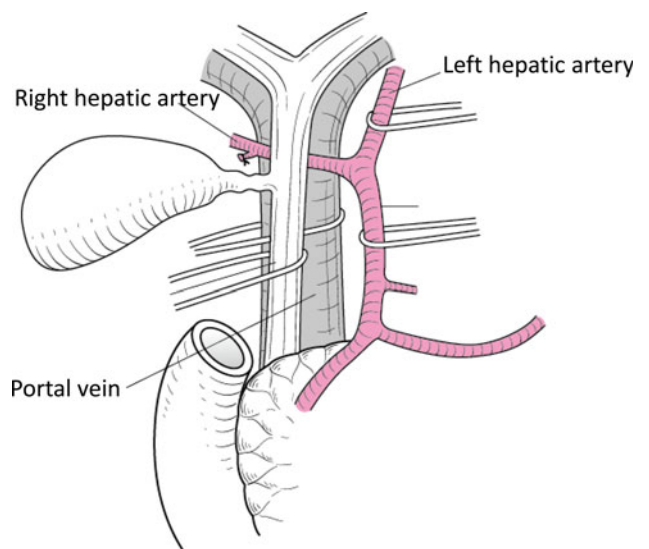


**Fig. 1** The superior vein and artery are isolated and taped

front of the hepatic artery (Fig. 2). The hepatoduodenal ligament is skeletonized, and the common hepatic, left hepatic, middle hepatic and right hepatic arteries, common bile duct and portal vein are taped (Fig. 3). The portal vein is identified from the right aspect of the hepatoduo-



**Fig. 2** The serosa of the hepatoduodenal ligament is excised transversely at the hepatic hilum, and is excised along the left side of the hepatoduodenal ligament longitudinally in front of the hepatic artery



**Fig. 3** The common hepatic and left hepatic arteries, common bile duct, and portal vein are taped

denal ligament, and the serosa of the posterior aspect of the hepatoduodenal ligament is excised.

### Dissection of the common hepatic duct

The common hepatic duct is dissected, and the cutting margin is submitted for intraoperative frozen section diagnosis. A nelaton tube is placed in the hepatic duct, and the hepatic duct is clamped using a Kyoto University Clamp (Fig. 4). Hepatic bile is drained externally. The distal cutting end of the common hepatic duct is closed using transfixing sutures. Caution should be used to ensure that there is no spillage of bile during these procedures.

### Dissection of lymph node No. 8

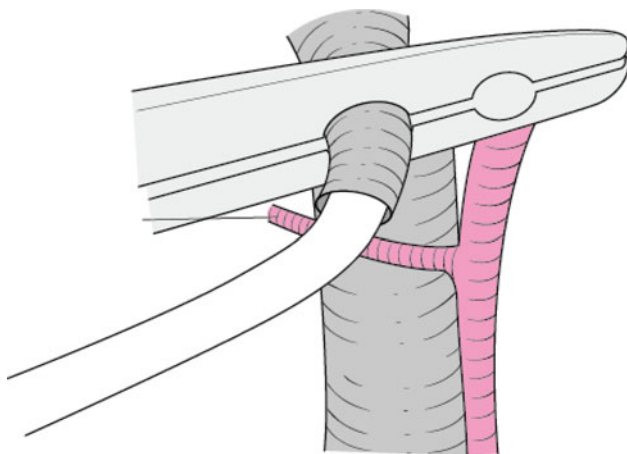
Dissection of the hepatoduodenal ligament descends to the head of the pancreas. The common hepatic artery and gastroduodenal artery are then isolated, and the right gastric artery is ligated and cut at the branching point.

### Dissection of the duodenum

Lymph nodes No. 5 and No. 6 are dissected along the lesser and greater curvatures, and the duodenum is dissected 2–3 cm anal to the pylorus ring.

### Dissection of the gastroduodenal artery

The root of the gastroduodenal artery is isolated and is dissected using double ligation. Before its ligation, the gastroduodenal artery is clamped by a Bulldog clamp, and



**Fig. 4** A nelaton tube is placed in the hepatic duct, and the hepatic duct is clamped using a Kyoto University Clamp

the blood flow in the hepatoduodenal ligament is confirmed by palpation. Once the gastroduodenal artery is dissected, the portal vein can be identified just behind it. Tunneling between the head of the pancreas and the portal vein is performed from the cephalic side.

### Tunneling of the pancreas head and dissection of the pancreas

Tunneling of the head of the pancreas is continued from the caudal side. Tunneling is completed from both the cephalic and caudal sides. The pancreas is encircled by tape. Transfixing sutures are then placed in the cephalic and caudal sides of the pancreas. Juvenile intestinal clamps are placed on the proximal and distal sides of the pancreas. The pancreas is first dissected using the blade of the scalpel, and the pancreas is dissected transversely using the back of the knife. The main pancreatic duct is identified as a white strand at the one-third cephalic side of the pancreas. The remaining pancreas stroma is dissected using an ultrasonic device. The main pancreatic duct is taped massively, and the surrounding connective tissue is dissected. Tubing is inserted into the main pancreatic duct by the cut-down method, and the proximal stump of the main pancreatic duct is ligated and dissected. The stump of the head of the pancreas is closed by running sutures.

### Dissection of the jejunum

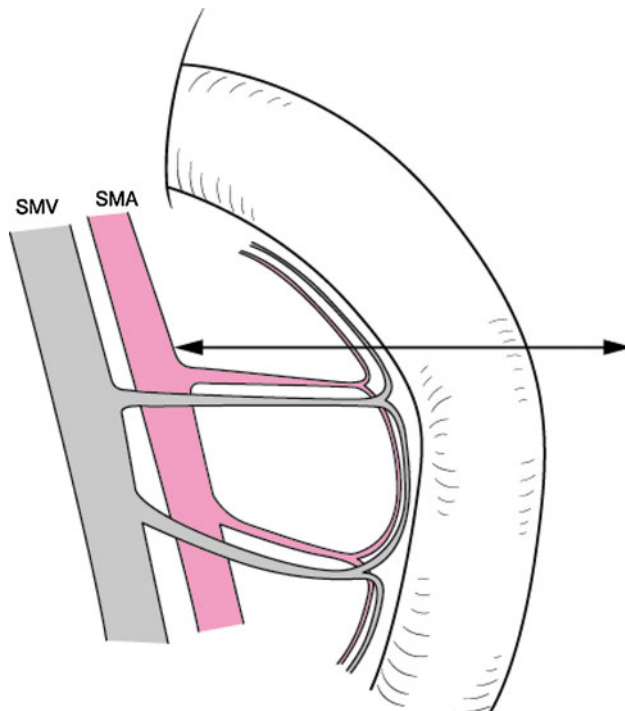
The Treitz ligament is dissected, and the 1st jejunal artery is isolated from the superior mesenteric artery. The mesojejunum is dissected along the 1st jejunal artery and vein. The jejunum is dissected 10 cm anal to the Treitz ligament (Fig. 5) and the jejunum is taken out behind the superior mesenteric artery and vein.

### Dissection of the head of the pancreas from the portal vein

The superior and inferior pancreatoduodenal veins are ligated and dissected carefully. Small veins between the portal vein and the head of the pancreas are ligated and cut carefully. When portal vein invasion is suspected, a side clamp is applied to the portal vein, and wedge resection of the portal vein is performed. Portal vein reconstruction is then performed.

### Dissection from the superior mesenteric artery

After the pancreas head is dissected free from the superior mesenteric vein, dissection of the head of the pancreas is started from the superior mesenteric artery. The tape

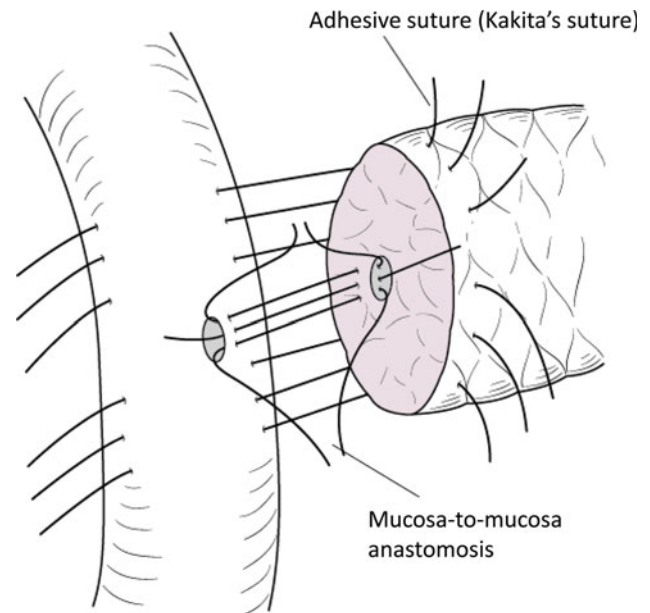


**Fig. 5** The mesojejunum is dissected along the 1st jejunal artery and vein. The jejunum is dissected 10 cm anal to the Treitz ligament

around the superior mesenteric artery and vein is run through the hole in the transverse mesocolon, the superior mesenteric vein is tracked to the left, and the superior mesenteric artery is tracked to the right. The head of the pancreas is clamped by an aortic clamp so that bleeding from the head of the pancreas is easily controlled. The right side of the superior mesenteric artery is dissected, as are the lymph nodes. The tissues around the superior mesenteric artery are ligated near the superior mesenteric artery and are dissected by an ultrasonic device. If the inferior pancreaticoduodenal artery has not already been cut during these procedures, it is cut at this time. The pylorus-preserving pancreaticoduodenectomy is completed, and the abdominal cavity is irrigated with normal saline to prevent abdominal cavity dissemination and infection.

### Pancreaticojejunostomy

The anal stump of the jejunum is lifted through the mesocolon right to the middle colic artery. The stump is closed with seromuscular transfixing sutures. The pancreaticojejunostomy is performed using a modified Kakita's method (Fig. 6). Transfixing sutures are placed through the pancreatic stump and run through the subserosal layer of the jejunum. These sutures are placed 1 cm from the cutting edge of the pancreas. A mucosa-to-mucosa anastomosis of the pancreaticojejunostomy is performed with interrupted sutures using 5-0 Prolene.



**Fig. 6** The pancreaticojejunostomy is performed using a modified Kakita's method

A pancreatic tube is placed from the jejunum to the main pancreatic duct. When performing the mucosa-to-mucosa anastomosis, Sugiyama's forceps are useful for the precise placement of the sutures. The pancreatic tube (3 mm) is put in place and is fixed by transfixing sutures.

### Hepaticojejunostomy

The hepaticojejunostomy is performed by interrupted sutures of PDS\*-II, and the biliary tube is placed from the jejunal lumen to the hepatic duct of the liver. It is fixed by transfixing sutures on the posterior wall. The biliary and pancreatic tubes are taken from the jejunal stump to the outside of the body.

### Duodenojejunostomy

A duodenojejunostomy is performed by a two-layer method (whole layer, running sutures of PDS4-0, and seromuscular layer, interrupted sutures of 4-0 black silk) and a Braun anastomosis (latero-latero jejuno-jejunostomy) is also performed using the same method.

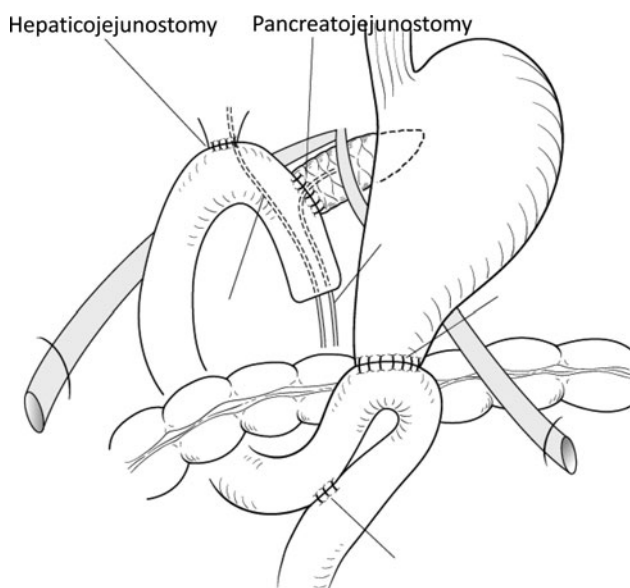
### Placement of the drainage tubes and closure of the abdominal wound

The drainage tubes are placed at the posterior aspect of the hepaticojejunostomy and at the anterior side of the

pancreaticojejunostomy (Fig. 7). They are drained to the outside of the abdomen. Biliary and pancreatic tubes are placed from the stump of the jejunum using Witzel's method. The abdominal cavity is irrigated with 5,000 ml of normal saline and is closed by a two-layer method.

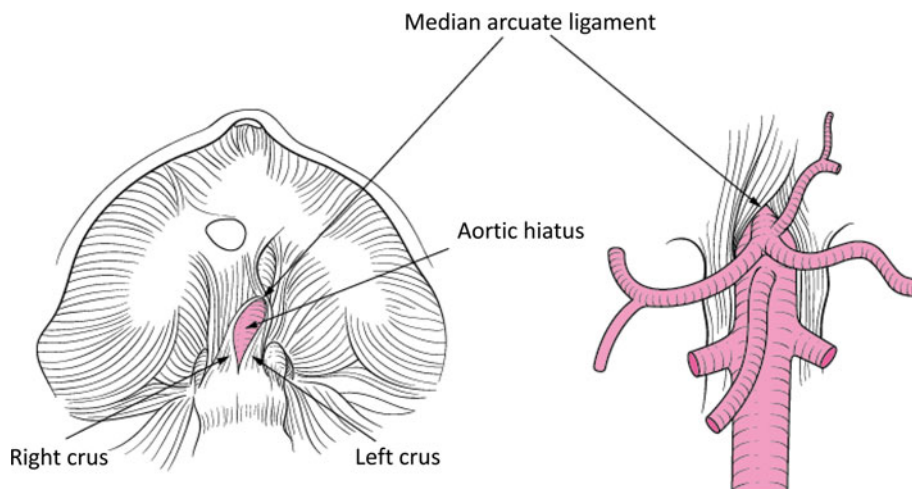
## Discussion

Complete resection is the principle of surgical treatment of cancer and is mandatory for the cure of bile duct and ampullary cancer. A negative surgical margin, especially in the stump of the bile duct, is important for a curative operation. Intraoperative frozen section diagnosis of the stump of the bile duct is necessary for bile duct cancer.



**Fig. 7** The drainage tubes are placed at the posterior aspect of the hepaticojejunostomy and at the anterior side of the pancreaticojejunostomy

**Fig. 8** The fibrosis of the ligament of the median arcuate produces compression of the celiac artery and arterial sclerotic changes of the celiac artery, which produces stenosis or obstruction of the celiac artery



When invasive carcinoma or severe dysplastic epithelium is noted at the stump, additional resection of the bile duct should be performed. In cases of bile duct cancer and ampullary cancer, D2 lymph node dissection and right hemisphere dissection of the superior mesenteric artery should be performed.

Careful hemostasis and prevention of bleeding are important during pancreatoduodenectomy. Isolation and taping of the superior mesenteric artery and vein using the mesenteric approach is useful for the procedures following pancreatoduodenectomy [1]. Using this mesenteric approach, dissection of the pancreas from the superior mesenteric vein and artery can be performed safely. Isolation of the J-1 artery and vein can be also performed safely around the Treitz ligament and the following dissection of the jejunum can be performed safely. After complete dissection of the head of the pancreas from the superior mesenteric vein, venous return to the portal is discontinued from the pancreas head. Arterial congestion of the pancreas head occurs and the pancreas head is the source of bleeding. To prevent this bleeding, the head of the pancreas should be clamped with an aortic clamp [2]. Another way to prevent bleeding is early devascularization of the arterial inflow to the pancreas head. The ligation and cutting of the gastroduodenal artery and inferior pancreaticoduodenal artery should be achieved prior to dissection of the head of the pancreas from the superior mesenteric artery in order to decrease blood loss due to venous congestion of the head of the pancreas [3]. The stumps of the gastroduodenal and inferior pancreaticoduodenal arteries should be doubly ligated to prevent postoperative bleeding.

Before ligation of the gastroduodenal artery, the artery should be clamped, and palpation of the hepatic artery should be performed to confirm preservation of the hepatic arterial flow. Fibrosis of the ligament of the median arcuate (Fig. 8) produces compression of the celiac artery and arterial sclerotic changes of the celiac artery, which

produces stenosis or obstruction of the celiac artery. The blood flow through the pancreatoduodenal arcade from the superior mesenteric artery supports the blood flow to the liver [4]. In such cases, once the gastroduodenal artery is dissected, blood flow to the liver disappears. After the operation is complete and the hepatic arterial flow has stopped, cholangitis or a liver abscess may develop postoperatively. We experienced such a case. When this occurs, dissection of the fibrous band of the median arcuate ligament, or blood flow reconstruction using a vascular graft is necessary. Preoperative assessment of the stenosis or obstruction of the root of the celiac axis should be performed by preoperative computed tomography.

Pancreatic fistula is a troublesome complication after pancreatoduodenectomy and produces intra-abdominal abscess, pseudoaneurysm of the neighboring artery (frequently the stump of the gastroduodenal artery) and further intra-abdominal hemorrhage. Pancreatic fistula frequently occurs in cases of soft pancreas and small-sized main pancreatic duct. In bile duct cancer, the pancreas is usually normal and the main pancreatic duct is normal in size. Pancreatic fistula occurs frequently. Careful anastomosis is important and intermittent negative pressure suction of the main pancreatic duct may be useful to prevent postoperative pancreatojejunostomy leakage [5].

Postoperative delayed gastric emptying often occurs and may continue for more than 6 months after pylorus-preserving pancreatoduodenectomy. It can be prevented by the linearization of the duodenojejunostomy [6] by ligation and dissection of the right gastric artery and antecolic placement of the duodenojejunostomy.

**Conflict of interest** None.

**Open Access** This article is distributed under the terms of the Creative Commons Attribution Noncommercial License which permits any noncommercial use, distribution, and reproduction in any medium, provided the original author(s) and source are credited.

## References

1. Kondo S, Takada T, Miyazaki M, et al. Guidelines for the management of biliary tract and ampullary carcinomas: surgical treatment. *J Hepatobiliary Pancreat Surg.* 2008;15(1):41–54.
2. Hirota M, Kanemitsu K, Takamori H, et al. Pancreatoduodenectomy using a no-touch isolation technique. *Am J Surg.* 2010; 199(5):e65–8.
3. Ishizaki Y, Sugo H, Yoshimoto J, Imamura H, Kawasaki S. Pancreatoduodenectomy with or without early ligation of the inferior pancreatoduodenal artery: comparison of intraoperative blood loss and short-term outcome. *World J Surg.* 2010;34(12): 2939–44.
4. Kurosaki I, Hatakeyama K, Nihei KE, Oyamatsu M. Celiac axis stenosis in pancreaticoduodenectomy. *J Hepatobiliary Pancreat Surg.* 2004;11(2):119–24.
5. Kim Z, Kim J, Min JK, et al. Negative pressure external drainage of the pancreatic duct in pancreaticoduodenectomy. *Hepatogastroenterology.* 2010;57(99–100):625–30.
6. Chijiwa K, Imamura N, Ohuchida J, et al. Prospective randomized controlled study of gastric emptying assessed by (13)C-acetate breath test after pylorus-preserving pancreaticoduodenectomy: comparison between antecolic and vertical retrocolic duodenojejunostomy. *J Hepatobiliary Pancreat Surg.* 2009;16(1):49–55.