

RESEARCH ARTICLE

Pain affect disrupted in children with posterior cerebellar tumor resection

Katie E. Silva¹, Julie Rosner¹, Nicole J. Ullrich^{2,3,4}, Christine Chordas³, Peter E. Manley^{3,4} & Eric A. Moulton¹¹Center for Pain and the Brain, Department of Anesthesiology, Critical Care and Pain Medicine, Boston Children's Hospital, Harvard Medical School, Boston, Massachusetts 02215²Department of Neurology, Boston Children's Hospital, Harvard Medical School, Boston, Massachusetts 02115³Department of Hematology/Oncology, Boston Children's Hospital, Harvard Medical School, Boston, Massachusetts 02115⁴Dana-Farber/Boston Children's Cancer and Blood Disorders Center, Boston, Massachusetts 02115**Correspondence**

Eric A. Moulton, Boston Children's Hospital, 1 Autumn Street, Center for Pain and the Brain, Boston, MA 02215. Tel: 781-216-1199; Fax: 781-216-1983; E-mail: eric.moulton@childrens.harvard.edu

Funding Information

This work was supported by a grant from the National Cancer Institute at the National Institutes of Health (grant number R21CA185870 to E. A. Moulton).

Received: 30 August 2018; Revised: 26 November 2018; Accepted: 26 November 2018

Annals of Clinical and Translational Neurology 2019; 6(2): 344–354

doi: 10.1002/acn3.709

Abstract

Objectives: Damage to the posterior cerebellum can cause affective deficits in patients. In adults, cerebellar infarcts result in thermal hyperalgesia and affect descending modulation of pain. This study evaluated the effect of resection of low-grade cerebellar tumors on pain processing in human children. **Methods:** Twelve pediatric patients treated with surgery only for low-grade gliomas (8 females, 4 males; mean age = 13.8 ± 5.6) and twelve matched controls (8 females, 4 males; mean age = 13.8 ± 5.7) were evaluated using quantitative sensory testing and fMRI. Five patients had tumors localized to posterior cerebellar hemispheres, henceforth identified as Crus Patients. **Results:** Crus Patients had significantly lower pain tolerance to a cold pressor test than controls. No significant differences were detected between subject groups for heat and cold detection thresholds (HDT, CDT), and heat and cold pain thresholds (HPT, CPT). Crus Patients also showed significantly decreased fMRI responses to painful heat in anterior insula, which has been associated with pain affect. **Interpretation:** Damage to posterior cerebellar hemispheres disrupted affective pain processing and endogenous pain modulation, resulting in decreased pain tolerance to suprathreshold noxious stimuli. This suggests that surgical resection of this region in children may increase the risk of developing pain disorders.

Introduction

Cerebellar tumor resection of posterior cerebellum can lead to affective and cognitive deficits in pediatric patients,^{1–3} but consequences of such a procedure on pain sensation and pain processing are unknown. The impact of surgical intervention in childhood is of particular interest, as it may influence sensory development into adulthood.

While classical thinking on the cerebellum highlights motor processing, evidence for its functional relevance to pain, as well as affective processing, has been steadily growing.^{4–7} In the intact brain, neuroimaging studies show that the cerebellum consistently responds to painful stimuli,^{5,8} and also may play a role in migraine.^{9,10} Transcranial cerebellar direct current stimulation can modulate pain intensity, as well as laser-evoked potentials measured

over somatosensory and anterior cingulate cortices.¹¹ Neural activity in the posterior cerebellum, particularly Crus I and II, has been observed to correlate with decreased responses to aversive stimuli in the limbic system,¹² which is associated with affective processing. Accordingly, contemporary theories of the cerebellum as a neuromodulator of affect and cognition¹³ may also extend to pain.

Deficits in affect regulation following insults to the cerebellum have been described in adults⁴ as well as children.^{1–3} Examples of affective disturbances included irritability, impulsivity, disinhibition, and lability of affect with poor behavioral modulation. Affective disturbances in these studies were attributed to damage to the cerebellar vermis. However, functional imaging studies in intact, healthy adults suggest that the posterior lateral cerebellar hemispheres may also relate to affective processing.¹² This

constellation of non-motor symptoms following cerebellar damage has been described as cerebellar cognitive affective syndrome.⁴

Specific psychophysical changes in pain perception have been reported following cerebellar infarctions in adults.¹⁴ In 30 patients with heterogeneous cerebellar lesions compared to 30 healthy controls, changes in pain sensitivity were identified, with increased pain intensity to suprathreshold heat, increased temporal summation of pain intensity to repeated mechanical punctate stimuli, as well as deficient endogenous pain inhibitory mechanisms. Radiologic assessment of CT and MRI scans described the infarcts as including the posterior inferior cerebellar artery ($n = 20$), superior cerebellar artery ($n = 7$), anterior inferior cerebellar artery ($n = 1$), and multiple ($n = 2$). Based on lesion mapping in half of patients, lesions were localized to posterior cerebellar hemispheres. However, as detailed mapping was not performed, functional modules relating to pain within the cerebellum were not assessed.

We hypothesized that the posterior cerebellar hemispheres play a modulatory role in pain perception, and that surgical resection in this area in children results in disinhibition of pain processing. We assessed pain processing using psychophysical and functional neuroimaging methods in pediatric patients with precisely mapped cerebellar lesions following resection surgery.

Materials and Methods

Subjects

Twelve patients who were treated with surgery only for a cerebellar low-grade glioma (8 females, 4 males; 13.8 ± 5.6 years old, range: 6–23 years old, Table 1) were recruited through referrals from the Dana-Farber/Boston Children's Cancer and Blood Disorders Center Pediatric Brain Tumor Program. Eleven patients had gross total resections, and one had a near total resection. Twelve age-, sex-, race- and handedness-matched Healthy Controls (8 females, 4 males; 13.8 ± 5.7 years old, range: 6–23 years old) were recruited through advertisements online and in public locations. For participants under 18 years of age ($n = 18$), participant assent and written informed parental consent was obtained prior to participation in the study. Participants over 18 years old ($n = 6$) provided written informed consent.

Patients and controls were excluded if they had any significant medical or brain-related disorders that could interfere with completion of the MRI or sensory testing and if they were on any medications that might impact central nervous system function (e.g. antidepressants, anticonvulsants). One patient had a diagnosis of attention deficit disorder, but was not prescribed any medications.

Table 1. Subject demographics.

	Crus patients	Non-Crus patients	Healthy controls
Subject totals	5	7	12
Sex	0M:5F	4M:3F	4M:8F
Age	14.0 ± 7.8	13.6 ± 4.2	13.8 ± 5.7
Handedness	4R:1L	5R:2L	10R:2L
Age at surgery (years)	10.4 ± 5.8	8.3 ± 2.5	–
Time since surgery (years)	3.6 ± 2.2	5.3 ± 3.1	–
Lesion extent (mm ³)	25.3 ± 3.5	4.9 ± 3.8	–
Racial diversity			
Non-Hispanic white	4	6	10
Hispanic/African-American	1	1	2

Mean \pm SD.

Pregnancy and recent drug use (barbiturates, benzodiazepines, cocaine, amphetamine, tetrahydrocannabinol, phencyclidine, and opioids) were ruled out by negative urine screening results (Alfa Scientific Designs and Alere).

The study was approved by the Dana-Farber Cancer Institute Institutional Review Board, and met the scientific and ethical guidelines for human pain research of the Helsinki Accord (<http://ohsr.od.nih.gov/guidelines/helsinki.html>) and the International Association for the Study of Pain.

Quantitative sensory testing

Quantitative sensory testing was performed 1 hour prior to fMRI scanning to measure HDT, CDT, HPT, CPT, and cold pressor pain tolerance. All testing was done in a dedicated research space the size of an office room.

A Medoc Thermal Sensory Analyzer (TSA-II) with a 3×3 cm² MRI-compatible contact thermode was used to deliver thermal stimuli to the hand dorsum. Testing consisted of both ascending and descending method of limits. At rest, the thermode maintained a baseline temperature of 32°C. Rate of temperature change for all threshold tests was 1°C/sec, with a return rate of 8°C/sec. A research assistant held the thermode in place, and the subject was told to use the other hand to click a button when he or she first noticed any change in temperature (HDT and CDT) or when he or she first noticed pain (HPT and CPT). Starting with the right hand, the sequence of testing was HDT, CDT, HPT, and CPT, with each repeated three times and separated by a 10 sec inter-stimulus interval. Each threshold level was calculated by the average of three trials. The left hand was tested afterwards in the same sequence.

The cold pressor task was used to determine cold pain tolerance, through the use of a Techne RU-200 Dip Cooler attached to a Techne Water Bath and FTE-10DDC

Tempette Thermoregulator (Bibby Scientific Limited, Staffordshire, UK). This system maintained water temperature at $7 \pm 0.01^\circ\text{C}$. The hand tested was the subject's most sensitive hand based on HPT, as the site of the lesion was not described in detail in the surgical notes, and also for experimental consistency with the fMRI scan protocol. Subjects were told to place their hand in the water bath for as long as they could.

Questionnaires

Psychological questionnaires were administered with the aid of the parent for participants <18 years old. These included the Fear of Pain Questionnaire in Children (FOPQ-C) to assess pain-related fears, and the Multidimensional Anxiety Scale for Children (MASC) to assess anxiety across symptom domains. Participants ≥ 18 years old completed the following questionnaires: the Fear of Pain Questionnaire III (FPQ-III), and the Multidimensional Anxiety Questionnaire (MAQ).

Imaging acquisition

Subjects were scanned in a 3T Siemens Trio MRI scanner using a 32-channel head coil. Anatomical images were obtained using a magnetization prepared rapid gradient echo (MPRAGE) sequence (160 1-mm-thick sagittal slices with an in-plane resolution of 0.78 mm [256 × 256]). Gradient echo field mapping was also acquired, consisting of 60 3-mm-thick axial slices with an in-plane resolution of 3.44 mm (64 × 64). Functional scans were collected using an echo planar imaging (EPI) sequence (TE/TR = 30/2500 msec). EPI scans consisted of 41 3.5-mm-thick axial slices with an in-plane resolution of 3.75 mm (64 × 64) and 292 volumes acquired over 12 min and 10 sec.

Evoked heat pain fMRI

During the functional scan, the TSA-II applied thermal stimuli at the subject's HPT to his or her most sensitive hand. The thermode was taped to the hand dorsum, and a rating dial was placed in the other hand. The fMRI scan consisted of a 30-sec baseline period of 35°C followed by 10 stimulus events, where the target temperature of HPT was maintained for 24 sec, the rate of temperature change was $5^\circ\text{C}/\text{sec}$, and the inter-stimulus interval was 40 sec. Patients reported their real-time pain intensity during the scan using a projected computerized VAS scale, with extremes labeled "Min" and "Max." The software package LabVIEW 5.1 (National Instruments Corp., Austin, TX) displayed the scale. VAS ratings were recorded digitally from 0 to 10, though scales did not display numbers to

the subjects. For subjects whose HPT was lower than 35°C , the baseline was changed to 32°C ($n = 1$ patient, 1 control). A functional scan from one patient was excluded due to technical difficulties with the acquisition.

fMRI – individual subject level image pre-processing

Functional image datasets were processed and analyzed with FSL 5.0.9 (FMRIB's Software Library, www.fmrib.ox.ac.uk/fsl).¹⁵ Screening of motion correction parameters ruled out gross movement (>1 voxel).

The initial two volumes were removed from each of the functional scans to allow for signal equilibration. B0 unwarping was performed using the B0 gradient echo field mapping images, using an effective EPI echo spacing of 0.44 msec, and a signal loss threshold of 10%. The skull and other non-brain areas were extracted from the anatomical and functional scans using FSL's script brain extraction tool (BET). Motion Correction using FMRIB's Linear Image Registration Tool (MCFLIRT) was performed on each functional scan. All volumes were mean-based intensity normalized by the same factor. The volumes were spatially smoothed with a 5 mm full-width at half-maximum (FWHM) filter, and a 100 sec high-pass temporal filter was applied.

First-level fMRI analysis of single subject data was performed with FMRI Expert Analysis Tool using FMRIB's Improved Linear Model (FEAT FILM) Version 6.00 with local autocorrelation correction.¹⁶ The temperature profiles recorded during the functional scan were demeaned and entered as explanatory variables (EVs), as were their temporal derivatives to account for small temporal delays. Temperature EVs were convolved with a gamma function incorporating a 3-sec standard deviation and a 6-sec hemodynamic lag. The resulting individual subject-level statistical maps from all FEAT analyses were co-registered with the subjects' anatomical images with FMRIB's Linear Image Registration Tool (FLIRT).

Group analysis fMRI

To prepare for group analysis, individual subject statistics were co-registered to the MNI152_T1_2 mm brain template using FLIRT. Group activation maps were generated by FEAT fMRIB's Local Analysis of Mixed Effects (FLAME). The patient group was split into those that had resections that involved the posterior cerebellar hemispheres in Crus I and II (Crus patients) and control patients whose resections did not involve these regions (Non-Crus Patients). Both Crus Patients and Non-Crus Patients had undergone the same surgical procedure and post-operative treatment. A one-way ANOVA was performed, including a factor for Group (Crus patients,

Non-Crus Patients, and Healthy Controls) and laterality of stimulation was used as a regressor of no-interest. Post-hoc group contrast maps were created for Healthy Controls versus Crus Patients, and Non-Crus Patients versus Crus Patients. Both contrasts had a significance threshold criterion of $Z > 3.1$ with a cluster significance threshold for multiple comparisons of $P < 0.05$.

Statistics – psychophysics, lesion extent, and questionnaires

All analyses of psychometric data were performed using GraphPad Prism software version 5 (GraphPad software Inc). Unpaired two-tailed t -test using Welch's correction was used for comparison of means for the threshold, tolerance, and lesion extent measurements. The nonparametric Mann–Whitney U Test was used for comparison of means for the MASC and FOPQ-C data.

Results

Lesion mapping

All lesions were restricted to the cerebellum only, resulting from surgical resection of a low-grade astrocytoma ($n = 11$) or ganglioglioma ($n = 1$). Of twelve resection patients (Table 1), five had lesions in our regions of interest, Crus I and II (Fig. 1, Table 2). Crus Patients lesions were localized to posterior cerebellar hemispheres and had some overlap with Non-Crus Patients lesions towards mid-line cerebellar structures, including dentate nuclei. However, Non-Crus Patients lesions also tended to be localized more anteriorly. Mean lesion extent in Crus Patients, $25.3 \pm 3.5 \text{ mm}^3$ (SE) was significantly larger than in Non-Crus Patients, $4.9 \pm 3.8 \text{ mm}^3$ (unpaired two-tailed t -test with Welch's correction, $t_5 = 5.354$, $P = 0.0031$).

Thermal thresholds

Detection thresholds for left and right hands were averaged as no significant differences were observed between hands. Respective measures (mean \pm SE) for the Crus Patients, Healthy Controls, and Non-Crus Patients (Fig. 2C) were (1) HDT: $34.2 \pm 0.7^\circ\text{C}$, $34.1 \pm 0.1^\circ\text{C}$, and $34.5 \pm 0.3^\circ\text{C}$; (2) CDT: $30.4 \pm 0.6^\circ\text{C}$, $30.6 \pm 0.3^\circ\text{C}$, and $30.7 \pm 0.1^\circ\text{C}$; (3) HPT: $38.4 \pm 1.8^\circ\text{C}$, $39.2 \pm 1.2^\circ\text{C}$, and $40.8 \pm 1.5^\circ\text{C}$; and (4) CPT: $26.0 \pm 1.8^\circ\text{C}$, $22.2 \pm 2.5^\circ\text{C}$, and $22.5 \pm 3.8^\circ\text{C}$.

No significant differences were detected between Healthy Controls and Crus Patients in HDT (unpaired two-tailed t -test with Welch's correction, $t_4 = 0.2020$, $P = 0.8498$), CDT (unpaired two-tailed t -test with Welch's correction, $t_5 = 0.2416$, $P = 0.8187$), HPT (unpaired two-tailed t -test

with Welch's correction, $t_7 = 0.3785$, $P = 0.7162$), and CPT (unpaired two-tailed t -test with Welch's correction, $t_{14} = 1.210$, $P > 0.2463$) (Fig. 2C).

Similarly, no significant differences were detected between Non-Crus Patients and Crus Patients in HDT (unpaired two-tailed t -test with Welch's correction, $t_5 = 0.4008$, $P = 0.7051$), CDT (unpaired two-tailed t -test with Welch's correction, $t_4 = 0.3609$, $P = 0.7364$), HPT (unpaired two-tailed t -test with Welch's correction, $t_8 = 1.012$, $P = 0.3411$), and CPT (unpaired two-tailed t -test with Welch's correction, $t_8 = 0.8177$, $P = 0.4372$).

Cold pain tolerance

Crus Patients had significantly reduced cold pain tolerance relative to Healthy Controls (unpaired two-tailed t -test with Welch's correction, $t_{12} = 2.379$, $P = 0.0348$) (Fig. 2A and B). In both Healthy Controls and Non-Crus Patients, at least half of each subject group could tolerate cold for longer than 60 sec, with several subjects going beyond 3 min. No Crus Patient was able to tolerate cold for longer than 31 sec. On average (\pm SE), Crus Patients were only able to tolerate submersion of their hand in a 7°C water bath for 22.6 ± 3.5 sec, while Healthy Controls could tolerate the same for 47.5 ± 14.5 sec. Non-Crus Patients could tolerate the water bath for 114.0 ± 48.4 sec, though the longer duration was not significantly different from Crus Patients due to greater variation (unpaired two-tailed t -test with Welch's correction, $t_6 = 1.883$, $P = 0.1087$).

No significant correlation was detected between cold pressor tolerance measures and lesion size when considering all cerebellar lesion patients (Spearman's $r_{s(10)} = -0.487$, $P > 0.10$). Also, no significant correlation was detected when considering only Crus Patients (Spearman's $r_{s(3)} = -0.700$, $P > 0.10$).

Questionnaires

MASC and FOPQ-C did not show any statistical difference between groups in any measure (Table 3). Given the low number of adults in Crus Patient ($n = 2$), Healthy Control ($n = 3$), and Non-Crus Patient groups ($n = 1$), the adult-focused MAQ and FPQ-III were not analyzed.

fMRI data – contrast between group responses to noxious heat

In comparison with Healthy Controls, Crus Patients showed significantly decreased fMRI responses to noxious heat in left anterior insula and dorsolateral prefrontal cortex (DLPFC) (Fig. 3, left column). Significantly decreased fMRI responses to noxious heat in left anterior insula only was also observed in Crus Patients relative to Non-Crus

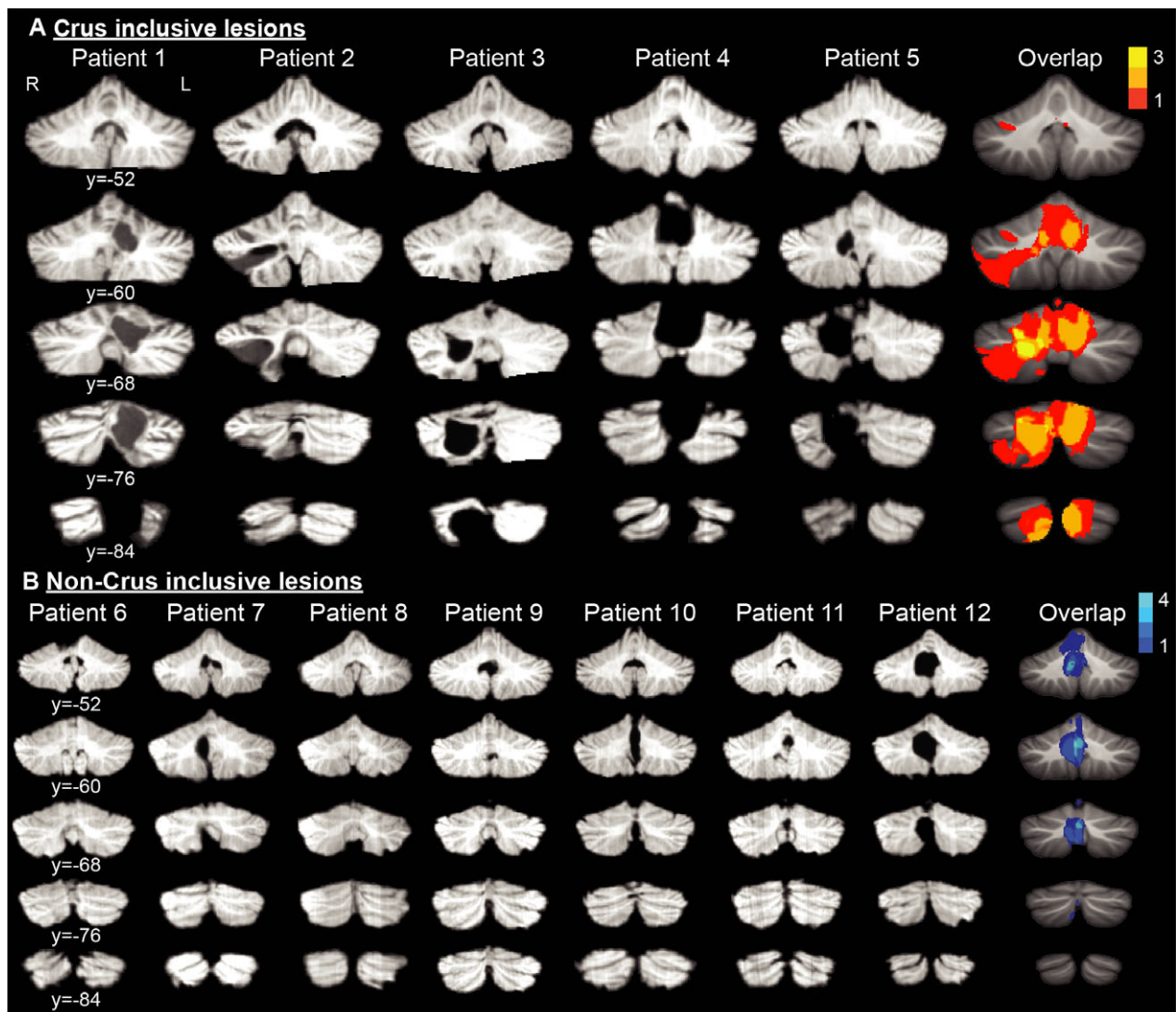


Figure 1. Anatomical localization of cerebellar lesions using magnetization prepared rapid gradient echo sequences for each patient. Patients were divided into two groups based on lesion localization: (A) Crus inclusive lesions, which included the posterior cerebellar hemispheres, and (B) Non-Crus inclusive lesions, which did not include the posterior cerebellar hemispheres. Individual patient images are structural scans that have been spatially normalized to the SUIT atlas.⁴⁴ Colored images on the right show the extent of lesion overlap across patients on the standard MNI152 atlas, ranging from 1 to 3 for Crus Patients (red-yellow) and 1–4 in Non-Crus Patients (dark blue-cyan).

Patients (Fig. 3, right column). No brain areas had increased responses in Crus Patients in either comparison. On a scale from 0 to 10, the average pain intensity evoked by HPT was 0.9 ± 1.0 (mean \pm SD) for Crus Patients, 1.4 ± 1.3 for Non-Crus Patients, and 1.0 ± 0.7 for Healthy Controls.

Discussion

In this study, cerebellar lesions have been associated with changes in pain affect based on two separate pain modalities, with evidence of (1) decreased heat pain threshold

activation in cortical structures related to pain affect and pain modulation, and (2) decreased cold pain tolerance. Resection of posterior cerebellar hemispheres was associated with decreased pain-related fMRI activity in left anterior insula and DLPFC. These patients also had significantly lower pain tolerance with a cold pressor task, but showed no differences in temperature levels for HDT, CDT, HPT, or CPT compared to controls.

These findings are consistent with our prediction that the posterior cerebellar hemispheres influence cortical processing of the affective-motivational component of pain. The anterior insula has been implicated with

affective pain processing.^{17–19} Lesions to the anterior insula decrease affective reactions to pain, including increased tolerance to the cold pressor task, without affecting pain thresholds.^{20,21}

Sensitivity to suprathreshold thermal stimuli can also be heightened with insular lesions, indicating that the insula has a complex relationship with emotional responses to pain.²² Our findings suggest that without an intact posterior cerebellum, the anterior insula abnormally responds to noxious heat.

DLPFC has been previously related to pain modulation.^{23–25} Transcranial direct current stimulation of DLPFC can increase pain tolerance.^{26,27} The pain inhibiting effect of DLPFC has been observed with cognitive-emotional

engagement,^{28,29} and the perceived ability to control pain appears to be a factor.^{30,31} Intriguingly, activation of DLPFC, cerebellum, and anterior cingulate cortex in concert has been negatively correlated with the analgesic effects of spinal cord stimulation in the treatment of chronic back pain.³² This network related to the cognitive control of pain appears to be disrupted in patients with posterior cerebellar hemispheric lesions.

Areas within the posterior cerebellar hemispheres are part of cortico-cerebellar networks that are functionally connected with anterior insula and DLPFC.^{33–35} These networks have been previously related to pain modulation and executive control, in the case of DLPFC, and pain affect and salience for anterior insula. Tract tracing studies in primates have also shown white matter anatomical connectivity between cerebellar dentate nuclei and DLPFC.^{36,37}

Differences in cold pain tolerance between patients and controls are presumed to result from damage to the posterior cerebellar hemispheres, interfering with pain affect and modulation of pain pathways. As a measure, pain tolerance is impacted by affective, motivational, and cognitive factors.^{38,39} Furthermore, significant disparities are not seen in detection and pain thresholds, indicating that the cerebellum may have a preferential impact on the affective-motivational rather than the sensory-discriminative dimension of pain.

Our findings are complemented by a study that evaluated changes in pain perception following gross cerebellar infarctions in adults.¹⁴ Although cold pain tolerance was not assessed, cerebellar lesions were associated with elevated reports of pain evoked by suprathreshold heat and

Table 2. Lesion extent.

Patient	Lesion size (mm ³)	Location
Crus patients		
1	30.7	L Vermis, Lobule VI, Crus I-II
2	29.3	R Lobule VIIb, Crus I-II
3	30.3	R Lobule VII-VIII, Crus I-II
4	24.0	R+L Lobule I-VI, Crus I-II
5	12.2	R Lobule VI, Crus I-II
Non-Crus patients		
6	6.3	R+L Vermal Lobules I-V
7	6.1	R Vermal Lobules VII-IX
8	0.4	L Lobule VI
9	1.4	L Lobule VIIb
10	7.8	Midline Vermis
11	1.1	R+L Lobule VIIIa
12	11.3	R+L Lobule IX

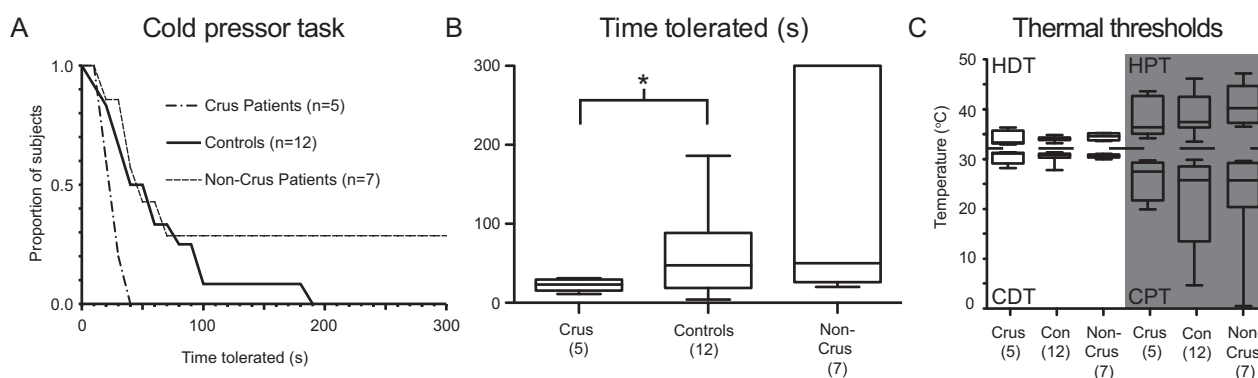


Figure 2. Decreased cold pain tolerance in Crus Patients. (A) Proportion of subjects able to tolerate hand immersion as a function of time immersed. The circulating water bath temperature was maintained at 7°C. (B) Box-plot highlighting median and distribution of tolerance across groups. The horizontal line within each box represents the median measurement, upper and bottom bounds of each box correspond to the upper and lower quartile range, and the whiskers indicate the complete range of samples. * $P < 0.05$ (unpaired two-tailed t -test with Welch's correction). (C) HDT, CDT, HPT, and CPT were not significantly different between Crus Patients, Healthy Controls, and Non-Crus Patients. Stimuli were delivered to the hand dorsum, and thresholds determined by way of ascending and descending method of limits. The dashed line indicates baseline temperature.

Table 3. Psychological survey results.

	Crus patients N = 3	Controls N = 9	Mann–Whitney U	P-value
Crus versus controls				
MASC				
Harm avoidance	46.3 ± 11.0	46.3 ± 7.6	11.00	0.7009
Tense/restless	46.7 ± 4.0	50.8 ± 5.7	11.00	0.7091
Panic	46.7 ± 7.6	51.0 ± 16.2	11.00	0.7071
Physical symptoms: total	46.3 ± 6.5	50.8 ± 11.5	11.50	0.7792
Obsessions & compulsions	41.3 ± 2.3	51.2 ± 11.4	5.00	0.1314
Performance fears	51.3 ± 11.9	50.3 ± 14.1	11.00	0.7081
Humiliation/rejection	45.3 ± 8.4	46.0 ± 8.6	12.50	0.9235
Social anxiety: total	47.3 ± 11.0	48.0 ± 11.7	13.50	0.9245
General anxiety disorder index	50.0 ± 9.5	48.3 ± 6.5	11.00	0.7091
Separation anxiety/phobias	54.0 ± 8.7	51.5 ± 9.8	9.50	0.5138
MASC 2 score	48.3 ± 11.2	49.5 ± 10.2	13.50	0.9255
FOPQ-C				
Total	35.3 ± 11.2	19.1 ± 11.7	4.00	0.1833
Fear of pain	17.3 ± 6.0	10.7 ± 6.2	3.50	0.1349
Avoidance of activities	18.3 ± 6.8	8.4 ± 7.3	5.00	0.2516
Crus versus Non-Crus				
MASC				
Harm avoidance	46.3 ± 11.0	47.0 ± 8.2	7.50	0.7865
Tense/restless	46.7 ± 4.0	49.6 ± 7.3	6.00	0.5169
Panic	46.7 ± 7.6	50.0 ± 11.6	8.50	1.0000
Physical symptoms: total	46.3 ± 6.5	50.0 ± 9.1	8.00	0.8960
Obsessions & compulsions	41.3 ± 2.3	50.2 ± 8.5	4.00	0.2373
Performance fears	51.3 ± 11.9	48.6 ± 8.7	7.00	0.6924
Humiliation/rejection	45.3 ± 8.4	44.6 ± 7.3	8.50	1.0000
Social anxiety: total	47.3 ± 11.0	45.7 ± 7.6	8.50	1.0000
General anxiety disorder index	50.0 ± 9.5	48.2 ± 9.5	7.50	0.7954
Separation anxiety/phobias	54.0 ± 8.7	52.3 ± 10.1	8.00	0.9048
MASC 2 score	48.3 ± 11.2	48.2 ± 9.7	9.00	0.8955
FOPQ-C				
Total	35.3 ± 11.2	26.8 ± 11.4	6.00	0.5169
Fear of pain	17.3 ± 6.0	13.2 ± 6.2	5.00	0.3642
Avoidance of activities	18.3 ± 6.8	13.7 ± 5.4	5.00	0.3580

MASC and FOPQ-C show no significant differences between pediatric Crus patients versus healthy controls (unpaired two-tailed Mann–Whitney Test), and Crus patients versus Non-Crus patients (unpaired two-tailed Mann–Whitney test). Mean ± SD.

repeated pinprick stimuli, but with no affect on pressure or heat pain thresholds. These changes were bilateral, but were most pronounced on the side ipsilateral to the lesion. In addition, measures relating to endogenous descending modulation of pain were decreased, including reduced offset analgesia and placebo analgesia. This suggests that a state of generalized hyperalgesia can also arise following cerebellar insult. Our findings indicate that this hyperalgesia occurs when the lesion specifically includes the posterior cerebellar hemispheres.

All patients with posterior cerebellar hemisphere lesions were female, and all had substantially more expansive cerebellar lesions than the other patients. This was not the case in the observation of lesions from cerebellar infarcts in adults, which showed a 2:1 proportion of males to females.¹⁴ This may reflect the greater incidence

of astrocytomas in this region in female patients in this pediatric population, as the female to male prevalence of pediatric cerebellar astrocytomas is approximately 1.8:1.⁴⁰ Considering that larger lesions were observed within the posterior cerebellar hemisphere than those without, the affective pain differences observed could be due to the size of the lesions just as much as it could be their localization. However, no significant correlation was detected relating lesion size to cold pressure tolerance measures. Further studies will be needed to make a more conclusive determination.

Although we observed changes in affective pain processing, we did not detect significant changes in affect as measured with the FOPQ-C and the MASC. However, previous cerebellar lesion studies in patients have demonstrated behavior deficits consistent with changes in

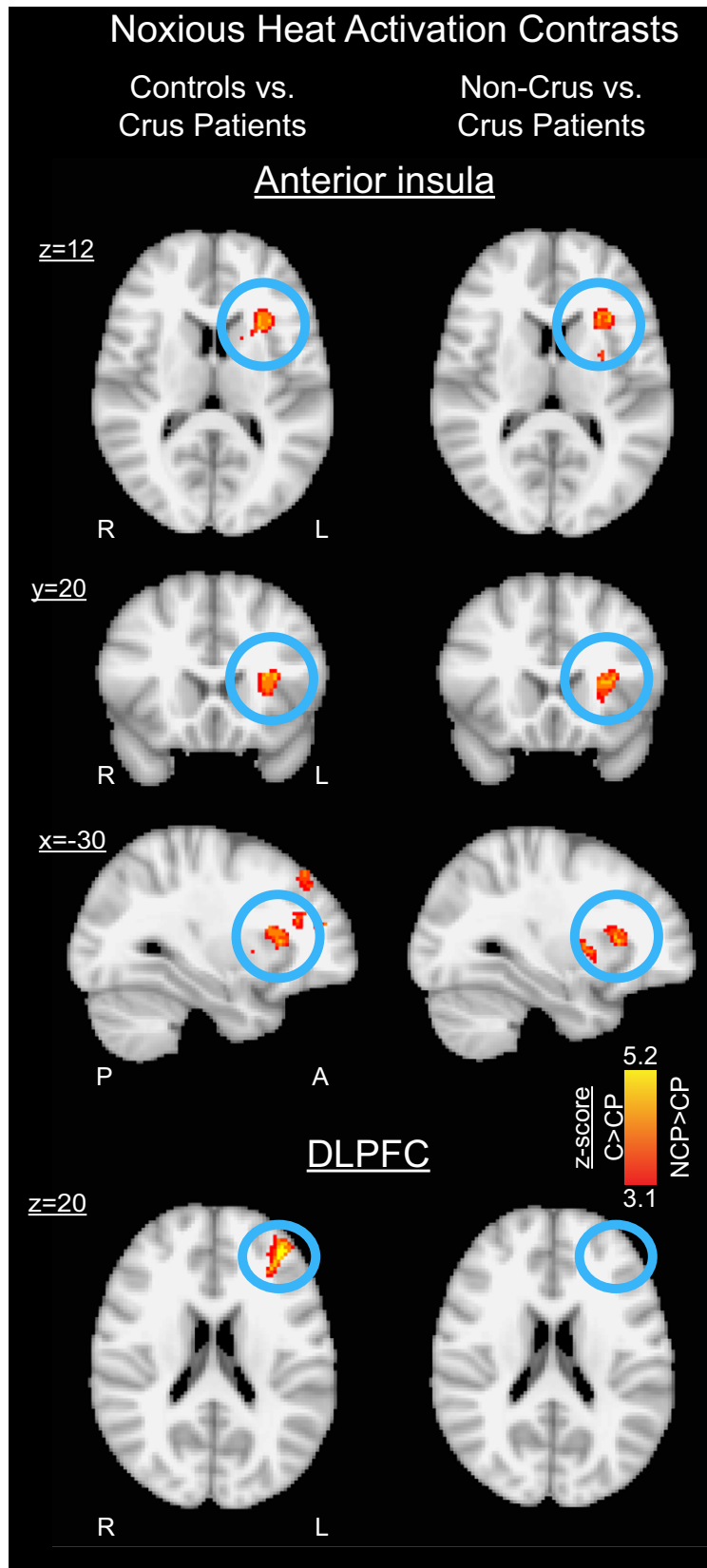


Figure 3. Contrast maps of cortical responses to noxious contact heat between Healthy Controls versus Crus Patients, and Non-Crus Patients versus Crus Patients. Thermal stimuli equivalent to each subject's HPT were delivered to the dorsum of the more sensitive hand. Crus Patients exhibited decreased activation in left anterior insula relative to Healthy Controls (35 mm³, Z-max 4.65), as well as relative to Non-Crus Patients (32 mm³, Z-max 4.73). The DLPFC had significantly decreased activation in Crus Patients relative to Healthy Controls (39 mm³, Z-max 5.26). Aside from the anterior insula and the DLPFC, no significant differences were detected in any other regions. On a scale from 0 to 10, the average pain intensity evoked by HPT was 0.9 ± 1.0 (mean \pm SD) for Crus Patients, 1.4 ± 1.3 for Non-Crus Patients, and 1.0 ± 0.7 for Healthy Controls. A = Anterior, C = Controls, CP = Crus Patients, DLPFC = dorsolateral prefrontal cortex, L = Left, NCP = Non-Crus Patients, P = Posterior, R = Right.

affect.^{1–3,41} This discrepancy may be due to insufficient sensitivity of these scales and low patient numbers to achieve significance, thus decreasing confidence in these negative observations. The pool of useable survey data was further diluted by the use of adult questionnaires for patients who were ≥ 18 at the time of their research visit, which are not directly comparable with the child versions. While no measure demonstrated significant differences, patients with Crus lesions showed a trend towards increased fear of pain, and a trend towards decreased anxiety, particularly with the obsessions subscore. The lack of significant findings with the questionnaires underscore the robust differences observed with cold pain tolerance and the fMRI results.

Several caveats regarding this study are worth bearing in mind, specifically regarding the fMRI results. Following surgical resection of portions of the cerebellum, the hemodynamic vascular coupling that connects localized neural activity with the fMRI signal measured could be disrupted in the rest of the brain. However, this likelihood is reduced given that the fMRI contrast between Crus Patients and Non-Crus Patients was similar to the contrast between Crus Patients and Healthy Controls.

In addition, stimulation during the fMRI scans produced very low pain ratings in all three groups and the most dramatic perceptual changes appear to be to suprathreshold stimuli. In most subjects, the first stimulus was rated as clearly painful, while the following stimuli were rated much lower. The decision to use HPT was based on minimizing discomfort elicited in our pediatric patients. We would anticipate that fMRI differences would be even more dramatic when using more painful stimuli. Now that we have established that cold pressor tolerance is most affected in these patients, future fMRI studies can focus on activation elicited by suprathreshold cold stimulation.

An alternative interpretation of the insular processing changes with Crus lesions could relate to alterations in the salience network rather than affective pain processing. The anterior insula is part of a multi-modal salience network, which may process attentional threat detection related to noxious stimuli.^{42,43} A resting state fMRI study has shown that the salience network is functionally coherent with parts of the cerebellum, including Crus I, Lobule VI, and the dentate nuclei.³³ Considering that pain tolerance is decreased in our lesion patients, the interpretation

that threat detection may be sensitized is provocative. While this suggests that our patients may also be sensitized to other salient stimuli, HDT, CDT, HPT, and CPT were not significantly altered in our patients. Nevertheless, more evidence is needed to determine the impact of Crus lesions on salience processing.

We believe that this project expands the perspective of the role of the cerebellum in modulating affective pain processing in children. The discovery that the cerebellum modulates pain processing could aid in the development of novel therapies to treat pain. The resulting findings may lead to enhanced diagnostics and therapeutic treatments, which could significantly improve quality of life in cancer patients suffering from pain.

Acknowledgments

This work was supported by a grant from the National Cancer Institute at the National Institutes of Health (grant number R21CA185870 to E.A.M.). We thank the patients and their families, as well as the clinicians and scientists who contributed to this project. We thank the Center for Pain and the Brain for administrative support, Lino Becerra Ph.D. for his help in configuring scanner protocols, and David Borsook M.D., Ph.D. for facilitating the introduction of the research team to the clinician team.

Conflict of Interest

The authors declare no competing financial interests.

References

- Levisohn L, Cronin-Golomb A, Schmahmann JD. Neuropsychological consequences of cerebellar tumour resection in children: cerebellar cognitive affective syndrome in a paediatric population. *Brain* 2000;123(Pt 5):1041–1050.
- Riva D, Giorgi C. The cerebellum contributes to higher functions during development: evidence from a series of children surgically treated for posterior fossa tumours. *Brain* 2000;123(Pt 5):1051–1061.
- Ullrich NJ. Neurologic sequelae of brain tumors in children. *J Child Neurol* 2009;24:1446–1454.
- Schmahmann JD, Sherman JC. The cerebellar cognitive affective syndrome. *Brain* 1998;121(Pt 4):561–579.

5. Moulton EA, Schmahmann JD, Berra L, Borsook D. The cerebellum and pain: passive integrator or active participant? *Brain Res Rev* 2010;65:14–27.
6. Baumann O, Borra RJ, Bower JM, et al. Consensus paper: the role of the cerebellum in perceptual processes. *Cerebellum* 2015;14:197–220.
7. Adamaszek M, D'Agata F, Ferrucci R, et al. Consensus paper: cerebellum and emotion. *Cerebellum* 2017;16:552–576.
8. Mehnert J, Schulte L, Timmann D, May A. Activity and connectivity of the cerebellum in trigeminal nociception. *NeuroImage* 2017;150:112–118.
9. Mehnert J, May A. Functional and structural alterations in the migraine cerebellum. *J Cereb Blood Flow Metab* 2017; <https://doi.org/10.1177/0271678X17722109>. [Epub ahead of print]
10. Kros L, Angueyra Aristizábal CA, Khodakhah K. Cerebellar involvement in migraine. *Cephalalgia* 2018;38:1782–1791.
11. Bocci T, Santarcangelo E, Vannini B, et al. Cerebellar direct current stimulation modulates pain perception in humans. *Restor Neurol Neurosci* 2015;33:597–609.
12. Moulton EA, Elman I, Pendse G, et al. Aversion-related circuitry in the cerebellum: responses to noxious heat and unpleasant images. *J Neurosci* 2011;31:3795–3804.
13. Schmahmann JD. The role of the cerebellum in cognition and emotion: personal reflections since 1982 on the dysmetria of thought hypothesis, and its historical evolution from theory to therapy. *Neuropsychol Rev* 2010;20:236–260.
14. Ruscheweyh R, Kühnel M, Filippopoulos F, et al. Altered experimental pain perception after cerebellar infarction. *Pain* 2014;155:1303–1312.
15. Smith SM, Jenkinson M, Woolrich MW, et al. Advances in functional and structural MR image analysis and implementation as FSL. *NeuroImage* 2004;23(Suppl 1):S208–S219.
16. Woolrich MW, Ripley BD, Brady M, Smith SM. Temporal autocorrelation in univariate linear modeling of FMRI data. *NeuroImage* 2001;14:1370–1386.
17. Price DD. Psychological and neural mechanisms of the affective dimension of pain. *Science* 2000;288:1769–1772.
18. Singer T, Seymour B, O'Doherty J, et al. Empathy for pain involves the affective but not sensory components of pain. *Science* 2004;303:1157–1162.
19. Apkarian AV, Bushnell MC, Treede R-D, Zubieta J-K. Human brain mechanisms of pain perception and regulation in health and disease. *Eur J Pain* 2005;9:463–484.
20. Berthier M, Starkstein S, Leiguarda R. Asymbolia for pain: a sensory-limbic disconnection syndrome. *Ann Neurol* 1988;24:41–49.
21. Greenspan J, Lee R, Lenz F. Pain sensitivity alterations as a function of lesion location in the parasyllian cortex. *Pain* 1999;81:273–282.
22. Starr C, Sawaki L, Wittenberg G, et al. Roles of the insular cortex in the modulation of pain: insights from brain lesions. *J Neurosci* 2009;29:2684–2694.
23. Lorenz J, Minoshima S, Casey KL. Keeping pain out of mind: the role of the dorsolateral prefrontal cortex in pain modulation. *Brain* 2003;126(Pt 5):1079–1091.
24. Apkarian AV, Sosa Y, Sonty S, et al. Chronic back pain is associated with decreased prefrontal and thalamic gray matter density. *J Neurosci* 2004;24:10410–10415.
25. Seminowicz DA, Moayed M. The dorsolateral prefrontal cortex in acute and chronic pain. *J Pain* 2017;18:1027–1035.
26. Graff-Guerrero A, González-Olvera J, Fresán A, et al. Repetitive transcranial magnetic stimulation of dorsolateral prefrontal cortex increases tolerance to human experimental pain. *Cogn Brain Res* 2005;25:153–160.
27. Mylius V, Jung M, Menzler K, et al. Effects of transcranial direct current stimulation on pain perception and working memory. *Eur J Pain* 2012;16:974–982.
28. Wager TD, Rilling JK, Smith EE, et al. Placebo-induced changes in FMRI in the anticipation and experience of pain. *Science* 2004;303:1162–1167.
29. Zubieta J-K, Bueller JA, Jackson LR, et al. Placebo effects mediated by endogenous opioid activity on mu-opioid receptors. *J Neurosci* 2005;25:7754–7762.
30. Wiech K, Kalisch R, Weiskopf N, et al. Anterolateral prefrontal cortex mediates the analgesic effect of expected and perceived control over pain. *J Neurosci* 2006;26:11501–11509.
31. Bräscher A-K, Becker S, Hoeppli M-E, Schweinhardt P. Different brain circuitries mediating controllable and uncontrollable pain. *J Neurosci* 2016;36:5013–5025.
32. Moens M, Sunaert S, Mariën P, et al. Spinal cord stimulation modulates cerebral function: an fMRI study. *Neuroradiology* 2012;54:1399–1407.
33. Habas C, Kamdar N, Nguyen D, et al. Distinct cerebellar contributions to intrinsic connectivity networks. *J Neurosci* 2009;29:8586–8594.
34. Buckner RL, Krienen FM, Castellanos A, et al. The organization of the human cerebellum estimated by intrinsic functional connectivity. *J Neurophysiol* 2011;106:2322–2345.
35. Diano M, D'Agata F, Cauda F, et al. Cerebellar clustering and functional connectivity during pain processing. *Cerebellum* 2015;15:343–356.
36. Middleton FA, Strick PL. Cerebellar projections to the prefrontal cortex of the primate. *J Neurosci* 2001;21:700–712.
37. Dum RP, Strick PL. An unfolded map of the cerebellar dentate nucleus and its projections to the cerebral cortex. *J Neurophysiol* 2003;89:634–639.
38. Blitz B, Dinnerstein AJ. Effects of different types of instructions on pain parameters. *J Abnorm Psychol* 1968;73:276–280.
39. Chen AC, Dworkin SF, Haug J, Gehrig J. Human pain responsivity in a tonic pain model: psychological determinants. *Pain* 1989;37:143–160.

40. Prasad KSV, Ravi D, Pallikonda V, Raman BVS. Clinicopathological study of pediatric posterior fossa tumors. *J Pediatr Neurosci* 2017;12:245–250.
41. Schmahmann JD. Disorders of the cerebellum: ataxia, dysmetria of thought, and the cerebellar cognitive affective syndrome. *J Neuropsychiatry Clin Neurosci* 2004;16:367–378.
42. Legrain V, Iannetti GD, Plaghki L, Mouraux A. The pain matrix reloaded: a salience detection system for the body. *Prog Neurobiol* 2011;93:111–124.
43. Uddin LQ. Salience processing and insular cortical function and dysfunction. *Nat Rev Neurosci* 2015;16:55–61.
44. Diedrichsen J. A spatially unbiased atlas template of the human cerebellum. *NeuroImage* 2006;33:127–138.