

Management of Gastroduodenal Artery Pseudoaneurysm Rupture With Duodenal Ulcer Complicated by Coil Migration

Dennis Chang, DO¹, Purvi Patel, MD¹, Seth Persky, MD², Joseph Ng, MD¹, and Alan Kaell, MD¹

¹Department of Internal Medicine, Internal Medicine at Northwell Health at Mather Hospital, Port Jefferson, NY

²Department of Gastroenterology, Long Island Digestive Disease Consultants, Setauket, NY

ABSTRACT

Rupture of visceral artery aneurysms or visceral artery pseudoaneurysms is an unusual cause of upper gastrointestinal bleeding. Although most visceral artery aneurysms and visceral artery pseudoaneurysms occur in the splenic artery or hepatic artery, they can rarely occur in the gastroduodenal artery. These are at high risk for rupture, with a 40%–70% mortality. We report a case of recurrent upper gastrointestinal bleeding due to gastroduodenal artery pseudoaneurysm despite endoscopic treatment and endovascular embolization complicated by coil migration into the duodenum.

INTRODUCTION

The true incidence of visceral artery aneurysms (VAAs) is difficult to determine because most are asymptomatic and incidentally discovered. The reported incidence is 0.01%–0.2%.¹ VAAs are subcategorized as either true aneurysms or pseudoaneurysms. True aneurysms occur when all 3 layers of the blood vessels are dilated. Pseudoaneurysms arise from a tear of the vessel walls that tamponades into a fibrous capsule or hematoma because of trauma, penetrating duodenal ulcer (DU), inflammation, autoimmune diseases, or connective tissue disorders.² VAAs most commonly occur in the splenic or hepatic artery. Only 1.5% of VAAs are found in the gastroduodenal artery (GDA).² Endovascular embolization using coils is an alternative modality to endoscopic hemostasis in managing upper gastrointestinal (UGI) bleeding, especially for VAA and VAAs pseudoaneurysms in hemodynamically stable patients.³ However, coil migration can occur as a complication. We report a case of refractory UGI bleed due to a ruptured GDA pseudoaneurysm from a large penetrating DU. Endovascular embolization was complicated by coil migration into the base of the ulcer.

CASE REPORT

A 71-year-old man with advanced dementia presented with vague abdominal complaints and burgundy colored stools. A large amount of bright red blood returned on placement of a nasogastric tube. He was hypotensive with a hemoglobin count of 8.2 g/dL and a Glasgow-Blatchford score of 12 on arrival. Two units of packed red blood cells were urgently transfused, and an emergent esophagogastroduodenoscopy (EGD) was performed. The EGD revealed a deep, large 4-cm ulcer in the anterior aspect of the duodenal bulb with a large clot emanating from the ulcer base (Figure 1). The DU was treated with endoscopic hemostatic powder to cover the entire ulcerated area.

He remained stable for 48 hours after treatment, but a subsequent complete blood count indicated a 2 g/dL hemoglobin loss. Celiac angiography was then performed and revealed a 1 × 1.5 cm² pseudoaneurysm in the GDA (Figure 2). Sandwich coil embolization technique was performed across the defect using Ruby microcoils. Completion angiography of the common hepatic artery showed the coil pack had partially migrated into the defect. Active extravasation into the duodenum was identified along with further hemodynamic instability (Figure 3). Another coil pack was deployed to occlude

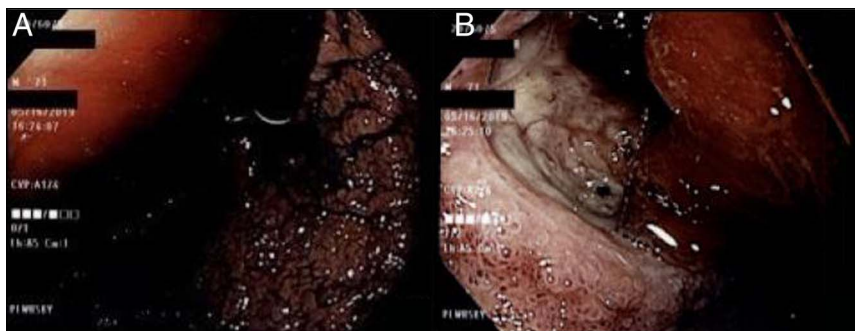


Figure 1. (A) Retroflex view of the stomach showing fresh blood. (B) Endoscopic view showing a large ulcer in the anterior aspect of duodenal bulb.

the proximal origin of the GDA from the common hepatic artery. Subsequent completion angiography confirmed hemostasis with stabilization of the patient's blood pressure. A repeat angiogram of superior mesenteric artery showed no evidence of additional extravasation and stable positioning of the coils (Figure 4). Forty-eight hours after successful embolization, the patient's hemoglobin decreased again. A repeat EGD was performed, and a coil was seen and had partially migrated through the DU into the duodenal lumen with clot noted at the base of the ulcer (Figure 5). No additional endoscopic intervention was performed. The patient remained in the intensive care unit for 4 days for close monitoring. Owing to the patient's comorbidities, hemodynamic stability, and improving hemoglobin, further surgical intervention was withheld. The patient was discharged to a long-term care facility with the coil left in the duodenum without further complications.

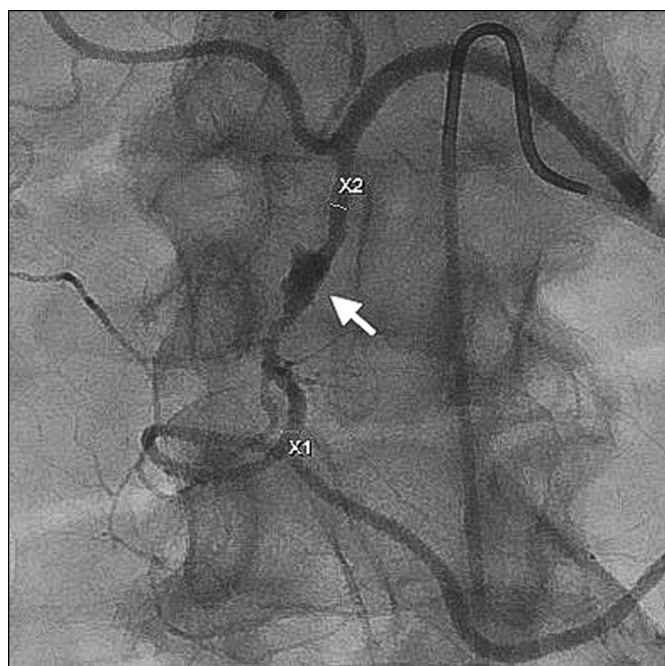


Figure 2. Angiogram showing pseudoaneurysm in the gastroduodenal artery.

DISCUSSION

Although GDA aneurysm and pseudoaneurysm rupture are a rare cause of UGI bleed, GDA aneurysm has a 21% mortality when it ruptures in the duodenum.² GDA pseudoaneurysms are commonly associated with chronic pancreatitis (47%), alcohol abuse (25%), peptic ulcer disease (17%), and cholecystectomy (3%).² In fewer cases, pseudoaneurysms are associated with Marfan syndrome, Ehlers-Danlos syndrome, cirrhosis, fibromuscular dysplasia, congenital absence of celiac axis, peripheral artery disease, or septic emboli.² The patient has no history of the diseases mentioned above. The etiology of GDA pseudoaneurysm in this patient was suspected because of untreated DU that penetrated into the adjacent vessel.

Although rare, GDA pseudoaneurysm has a 75% incidence of rupture.¹ Therefore, a GDA pseudoaneurysm should be repaired whenever possible owing to the high risk of

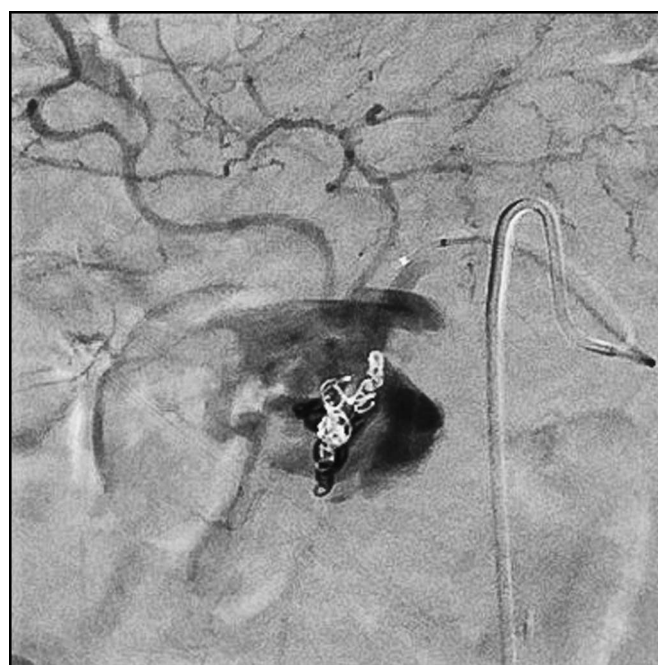

Figure 3. Extravasation of contrast and migration of coils.

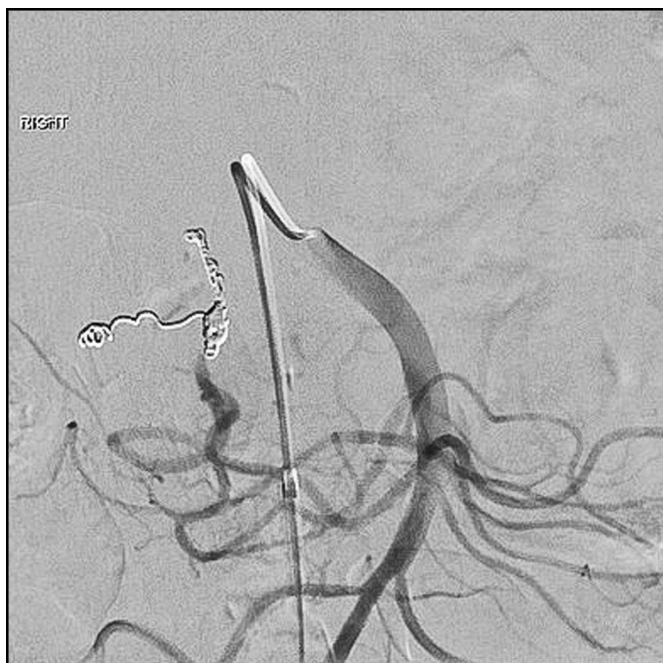


Figure 4. Superior mesenteric artery completion angiogram showing coils proximal to the pseudoaneurysm in the gastroduodenal artery with collateral blood flow without extravasation.

rupture and poor outcome. Endovascular embolization is now the treatment of choice for VAA and visceral artery pseudoaneurysms.³ In addition, endovascular stenting, percutaneous, or endoscopic ultrasound-guided thrombin injection have also been discussed to control VAA bleed.^{3,4} In hemodynamically unstable patients or in those who are refractory to the aforementioned treatments, surgical revascularization, vessel ligation, and aneurysmal sac exclusions are indicated.^{2,3} The overall complications from endovascular embolization are less than 5%, and systemic coil migration occurs in 3% of the time.⁴ At least 17 cases of UGI bleeding with coil migrating into the GI tract from GDA were reported.^{5–20} Fourteen of those cases reported the involvement of DU.^{5–9,12–19} Twelve of the cases had a DU identified on EGD before GDA coil embolization.^{5,6,8,9,12,13,15,17–19} Two of those cases identified

GDA pseudoaneurysm.^{9,18} The location of the ulcer in the duodenum was inconsistently reported in the cases. Protruding coils have been observed immediately after placement and up to 10 years later.^{16,20} Coil migration can result in GI bleeding, tissue granulation, and bowel ischemia, or it may pass through the GI tract without complications.^{10,15,19,20} In most of the cases, coil migrations were managed conservatively without sequelae.^{10,13–16,19,20} One case reports the use of thrombin injection.⁴ In other cases, coil migrations were not intervened in time and resulted in expiration from massive hemorrhage.

In conclusion, GDA pseudoaneurysms can be a source of upper GI bleed. Although endovascular embolization is the treatment of choice, coil migration can occur. We suspect that patients with impaired duodenal wall patency, such as the presence of a penetrating DU, might predispose coils to migration. More data are needed to further study the cause for coil migration and management strategy. Current literature suggests coil migrations are managed conservatively when the patient is hemodynamically stable or intervened surgically in refractory cases or in an unstable patient. Furthermore, we propose that GDA pseudoaneurysms should be considered in patients with recurrent UGI bleeding and when a large, deep DU is noted on endoscopy.

DISCLOSURES

Author contributions: D. Chang wrote the manuscript, reviewed the literature, and is the article guarantor. P. Patel, S. Persky, J. Ng, and A. Kaell edited the manuscript and revised it for intellectual content.

Financial disclosure: None to report.

Informed consent was obtained for this case report.

Received July 15, 2019; Accepted January 13, 2020

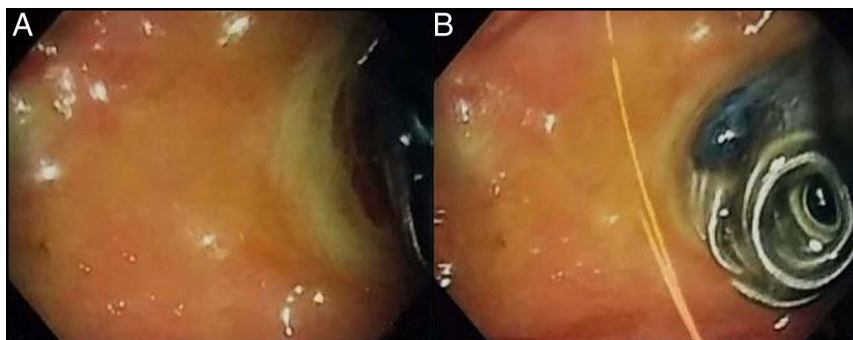


Figure 5. (A) Duodenal bulb with ulcer in sight. (B) Partially perforated coil with clot at base.

REFERENCES

1. Shawky MS, Tan J, French R. Gastroduodenal artery aneurysm: A case report and concise review of literature. *Ann Vasc Dis*. 2015;8(4):331–3.
2. Habib N, Hassan S, Abdou R, et al. Gastroduodenal artery aneurysm, diagnosis, clinical presentation and management: A concise review. *Ann Surg Innovation Res*. 2013;7(1):4.
3. Bauer JR, Ray CE. Transcatheter arterial embolization in the trauma patient: A review. *Semin Interv Radiol*. 2004;21(1):11–22.
4. Bilbao J, Martínez-Cuesta A, Urtasun F, Cosín O. Complications of embolization. *Semin Interv Radiol*. 2006;23(2):126–42.
5. Choi CJ, Lim H, Kim DS, Jeong YS, Park SY, Kim JE. Massive duodenal bleeding after the migration of endovascular coils into the small bowel. *Clin Endosc*. 2019;52(6):612–5.
6. Jaurigue MM, Snyder M, Cannon M. Recurrent upper GI bleeding secondary to coil migration in a patient with known NSAID-induced peptic ulcer disease. *Gastrointest Endosc*. 2014;79(6):1004–5.
7. Singh G, Denyer M, Patel JV. Endoscopic visualization of embolization coil in a duodenal ulcer. *Gastrointest Endosc*. 2008;67(2):351–2.
8. Tey KR, Aggarwal A, Banerjee B. Migrating coil. *BMJ Case Rep*. 2017; 2017.
9. Romana B, Mahdi A, Hammoud GM, Samiullah S. Embolization coil migration into duodenum. *Am J Gastroenterol*. 2017;112.
10. Dulskas A, Rudinskaite G, Maskelis R, Kuliesius Z, Escalante R, Samalavicius N. Duodenal ulceration following gastroduodenal artery embolization with coils. *Endoscopy*. 2015;47(Suppl 1):E488–9.
11. Dinter DJ, Rexin M, Kaehler G, Neff W. Fatal coil migration into the stomach 10 years after endovascular celiac aneurysm repair. *J Vasc Interv Radiol*. 2007;18(1):117–20.
12. Park C-H, Bae SH, Kim HY, et al. Hepatobiliary and pancreatic: Bleeding duodenal ulcer associated with coil migration after transarterial chemoembolization and radiotherapy. *J Gastroenterol Hepatol*. 2014; 29(5):897.
13. Suki M, Ovidia B, Baker FA, et al. Angiographic coil—the endoscopist point of view. *Ann Case Rep*. 2018;2018(6). doi:10.29011/2574-7754/100098.
14. Shen Y-C, Liao C-H, Shen T-C, Tu C-Y. Coil migration following transcatheter arterial embolization. *Intern Med*. 2014;53(5):519–20.
15. Vardar R, Özütemiz Ö, Parildar M. Endoscopic view of intravascular platinum coil after embolization of bleeding duodenal ulcer: Report of two cases. *Endoscopy*. 2009;41(Suppl 2).
16. Feldstein R, Devito B. Visible coil after embolization for a bleeding ulcer. *Clin Gastroenterol Hepatol*. 2008;6(7).
17. Vleggaar FP, Rutgers DR. Endovascular coil visible in a visible vessel. *Endoscopy*. 2007;39(Suppl 1):E203.
18. Nackley JJ, Brady PG, Mamel JJ, Neher J. Endoscopically visible coil after embolization for bleeding duodenal ulcer. *Gastrointest Endosc*. 2000;52(1): 79–80.
19. Chosa K, Naito A, Awai K. Extravascular submucosal coil migration after transcatheter arterial embolization for a massively bleeding duodenal ulcer. *CardioVascular Interv Radiol*. 2011;34(5):1098–101.
20. Mohandas N, Swaminathan M, Vegiraju V, et al. Endovascular coil migration and upper gastrointestinal bleed: A causal or casual relationship? *Endoscopy*. 2015;47(Suppl 1).

Copyright: © 2020 The Author(s). Published by Wolters Kluwer Health, Inc. on behalf of The American College of Gastroenterology. This is an open-access article distributed under the terms of the Creative Commons Attribution-Non Commercial-No Derivatives License 4.0 (CCBY-NC-ND), where it is permissible to download and share the work provided it is properly cited. The work cannot be changed in any way or used commercially without permission from the journal.