



OPEN ACCESS

Case report

Syncope and recurrent ventricular tachycardia with a newly identified desmosomal gene mutation

Sandeep Banga*, Nagib Chalfoun, Bohuslav Finta, Darryl Elmouchi, Musa Dahu, Alan Woelfel, Richard F McNamara, Timothy Fritz, Jennifer I Schuitema, Carly A Judson, Andre Gauri

Frederik Meijer Heart & Vascular
Institute, Michigan, USA
*Email:
sandeep.banga@spectrumhealth.org

ABSTRACT

Ventricular arrhythmias in young people most commonly occur due to the presence of hypertrophic cardiomyopathy, long QT syndrome or Wolff-Parkinson-White syndrome. We present a case in which the patient had exercise induced syncopal spells and was found to have ventricular tachycardia (VT) during both exercise stress testing and an electrophysiology study. Further genetic studies showed a previously unseen desmosomal gene mutation confirming the presence of Arrhythmogenic Right Ventricular Cardiomyopathy (ARVC).

[http://dx.doi.org/
10.5339/gcsp.2013.33](http://dx.doi.org/10.5339/gcsp.2013.33)

Submitted: 1 September 2013
Accepted: 28 September 2013
© 2013 Banga, Chalfoun, Finta,
Elmouchi, Dahu, Woelfel,
McNamara, Fritz, Schuitema,
Judson, Gauri, licensee Bloomsbury
Qatar Foundation Journals. This is
an open access article distributed
under the terms of the Creative
Commons Attribution license CC BY
3.0, which permits unrestricted use,
distribution and reproduction in any
medium, provided the original work
is properly cited.

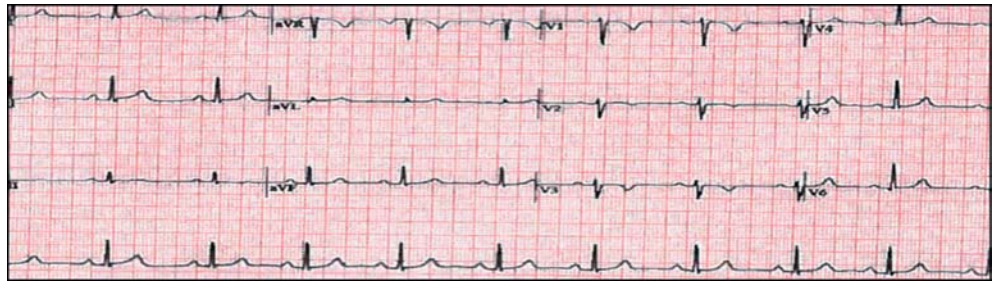


Figure 1. Baseline ECG shows T inversions in V1-V3.

CLINICAL PRESENTATION

A 19-year-old woman presented with a history multiple recurrent pre-syncope and syncope spells associated with exertion. During most of these episodes, she had lightheadedness and dizziness with palpitations prior to loss of consciousness. She was an avid runner with no prior history of syncope or exercise intolerance. She had no significant past medical history or family history of syncope or sudden death. Her physical examination was unremarkable.

INVESTIGATIONS

Her initial workup started with an electrocardiogram (ECG) (Figure 1). The tracing showed sinus bradycardia, normal QT interval with T wave inversions in V2 and V3. No epsilon wave was present. It is noted that the terminal activation duration (TAD) is 47 msec measured from the nadir of S wave to the end of QRS complex in leads V2, V3.

An echocardiogram showed normal LV size and function with no obvious RV dysfunction or dilation. An exercise treadmill test (ETT) was done which resulted in symptomatic non-sustained salvos of VT with a left bundle inferior axis (LBIA) with peak exertion and into recovery (Figure 2).

A comprehensive electrophysiology (EP) study with three-dimensional electroanatomic mapping using the CARTO system depicted baseline basic cycle length of 1005 msec, PR interval of 170 msec, QRS duration of 92 seconds, Q-T interval of 417 msec, and H-V interval of 38 msec. AV nodal Effective Refractory Period (ERP) was noted to be 600/350 msec, and RV ERP was 450/260 msec.

AV block occurred at 430 msec and VA dissociation was present with ventricular pacing. A high-density three-dimensional electroanatomic map of the right ventricle was constructed to look at myocardial voltage as well as right ventricular endocardial activation. No significant regions of scar were noted in the right ventricle with all voltages being greater than 1.5 mV in amplitude. The total endocardial activation duration (EAD) was noted to be 63 msec with the earliest activation being at the apex and the latest at the outflow tract (Figure 3).

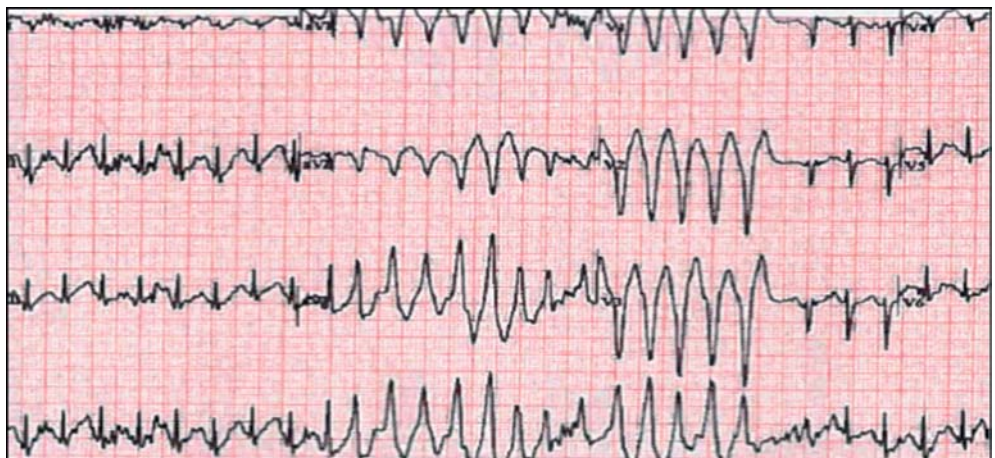


Figure 2. ECG during exercise testing.

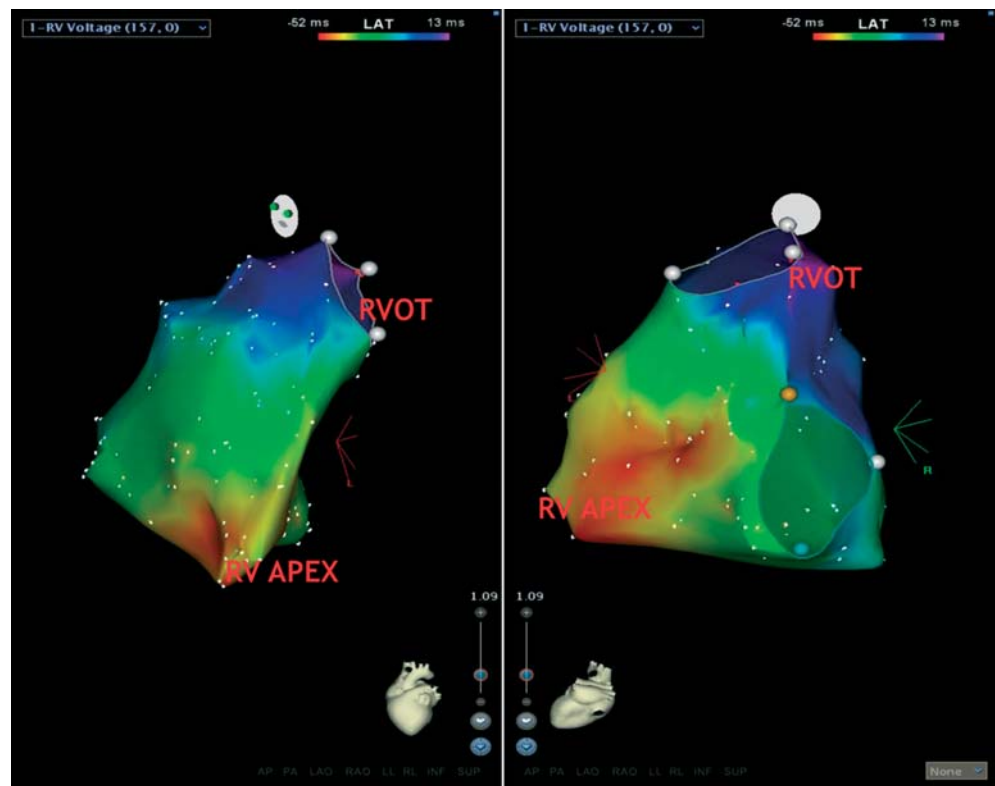


Figure 3. Endocardial activation duration map of right ventricle.

She had multiple spontaneous polymorphic premature ventricular contractions (PVCs) at baseline prior to placement of catheters which were both left bundle superior axis (LBSA) and LBSA morphologically (Figure 4). An isoproterenol infusion was started which increased her spontaneous ventricular ectopy. The isoproterenol-induced VT with LBSA pattern as shown in (Figure 5). Ventricular programmed stimulation with double and triple extra stimuli resulted in multiple runs of non-sustained ventricular tachycardia, the longest of which was 20 beats in duration.

Multiple runs of non-sustained ventricular tachycardia were induced with varying morphologies and occasional polymorphic ventricular tachycardia (Figure 6). No episodes of sustained ventricular tachycardia were recorded.

A cardiac magnetic resonance (CMR) study with delayed gadolinium enhancement was performed to look for function, morphology and tissue characterization of the heart. Findings included a mildly dilated RV, with RV diastolic volume index = 108 ml/m² (with normal range of 60–90 ml/m²). There was slight hypokinesia of the apex of the right ventricle with RVEF = 45%. The right ventricle had no evidence of fatty-infiltration.

TREATMENT

The differential diagnosis at this point consisted of ARVC or catecholaminergic polymorphic ventricular tachycardia (CPVT). The patient was initially sent home with a wearable external defibrillator and instructed not to exercise. A few weeks later she returned for implantation of a single chamber cardioverter-defibrillator. The lead parameters included R wave of 9mv with a pacing threshold of 0.5V at 0.5 msec and lead impedance of 585 ohms.

Genetic Testing of the patient ultimately confirmed the diagnosis of ARVC several weeks after her initial presentation. The test was positive for the probable deleterious splice mutation PKP2 IVS-2A > G, a class I variant (Figure 7). A class I variant of this mutation suggests that it is strongly associated with development of cardiomyopathy. Genetic testing in all first degree relatives identified only the patient's mother as having this same mutation.

One month after implantation, the patient had a documented episode of sustained ventricular tachycardia while running, which was converted to sinus rhythm with a single shock of

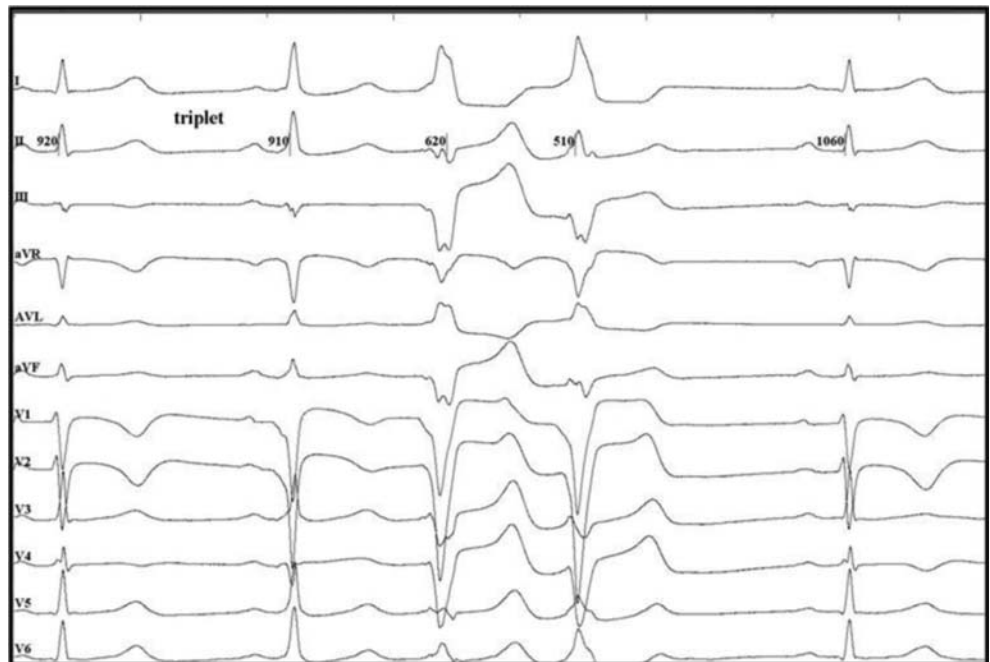


Figure 4. Spontaneous triplet PVCs with first fusion beat. Note: V₃ and V₄ were inadvertently reversed during the study.

20 joules (Figure 8). Given the catecholamine induced ventricular ectopy, she was started on beta blockade with oral nadolol. During subsequent follow up, a repeat exercise stress test was performed while on beta blockers and only rare isolated PVCs were noted, in contrast to her initial study where salvos of VT were present with exertion. The patient has not had any additional episodes of sustained ventricular tachycardia while on beta blockade. She was instructed to not to participate in high intensity exercise, but she does continue to jog on a regular basis without difficulty.

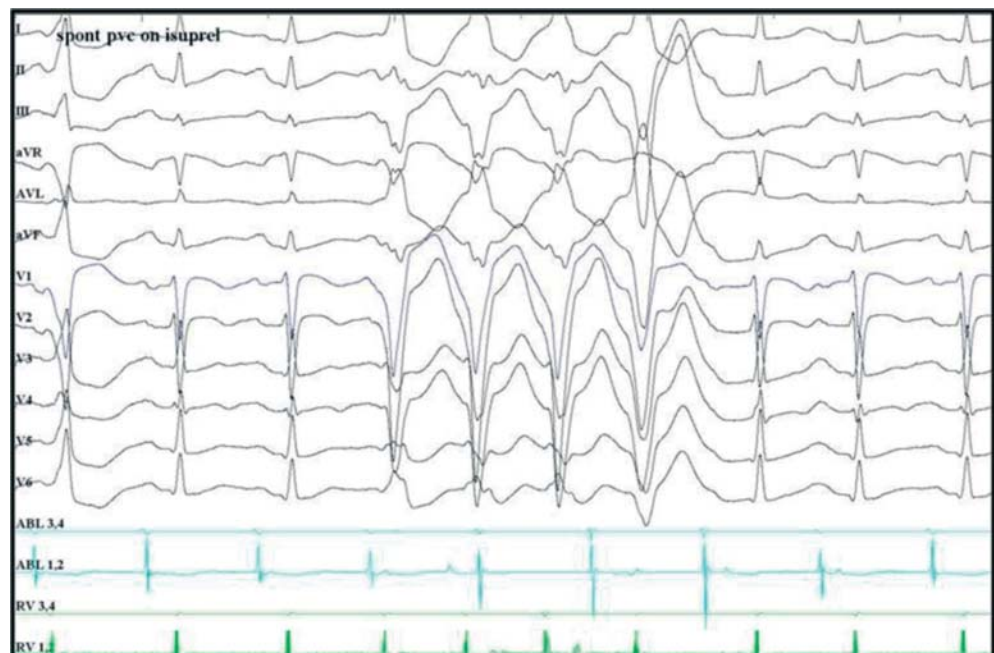

Figure 5. Spontaneous VT on isoproterenol infusion.

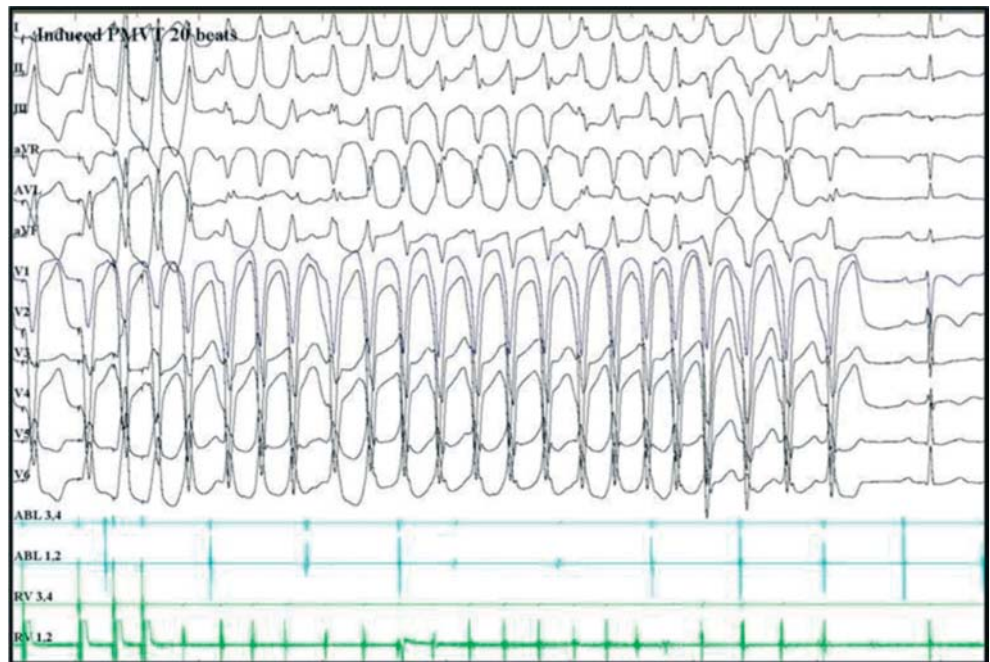

Figure 6. Induction of polymorphic VT on ventricular stimulation on isoproterenol.

DISCUSSION

The Revised 2010 Task Force Criteria¹ for the diagnosis of ARVC assign six categories, as follows:

- (1) Global and regional myocardial dysfunction and structural abnormalities.
- (2) Histological characterization.
- (3) Depolarization abnormalities.
- (4) Repolarization abnormalities.
- (5) Ventricular-arrhythmias inducible with catecholamine or with exercise
- (6) Family history and genetic testing.

Definitive diagnosis requires two major criteria, one major and two minor criteria, or four minor criteria from different categories. ARVC is considered borderline, if one major and one minor criteria, or one minor criterion are present. ARVC is possible, if one major criterion or 2 minor criteria are present.

In our patient presented, ARVC was diagnosed on the basis of:

1. The inverted T waves in V₁, V₂ and V₃ surface ECG (major criterion).
2. Recorded arrhythmias whether spontaneous and/or the isoproterenol-induced of LBSA pattern (major criterion).

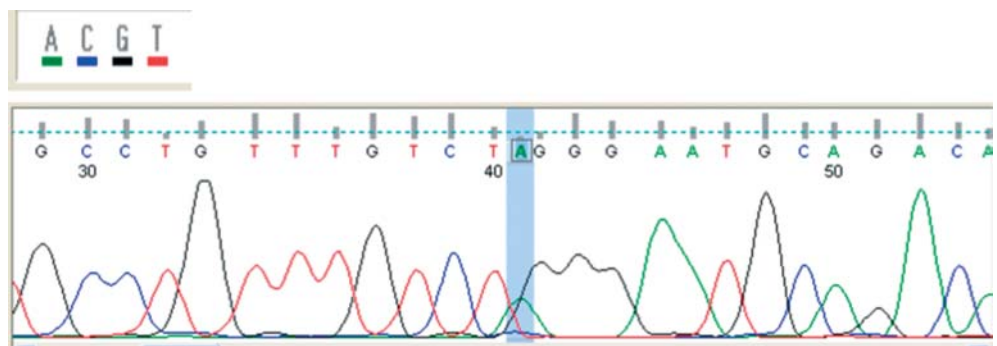


Figure 7. Electropherogram showing: Mutation; PKP2 IVS3-2A > (Also known as c.1035-2A > T, genomic position chr12:33021998).

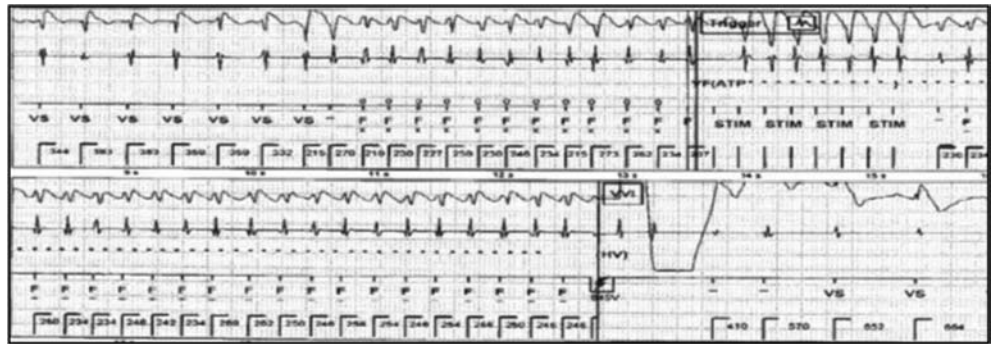


Figure 8. Electrogram showing VT treated with an attempt of Anti-Tachycardia Therapy(ATP) followed by Shock Therapy.

3. The genetic mutation in the patient and the mother (a major criterion).
4. The exercise-induced arrhythmias of LBIA pattern (a minor criterion).

Given the presence of three major and one minor criteria, this is a definite case of ARVC based on the recent task force criteria.

Despite advances in the research in the field of Arrhythmogenic Right Ventricular Cardiomyopathy (ARVC), sudden cardiac death often occurs. The diagnosis of this disease is typically challenging due to minimal symptoms and the often only subtle abnormalities on diagnostic tests. Ventricular arrhythmias and sudden death are often the first presentation of the disease. In this case, a suspicion of ARVC or CPVT started from the history of exercise induced ventricular arrhythmias. Exercise precipitating arrhythmias in ARVC has been shown in the literature. Sudden cardiac death was reported more in athletes than non-athletes with ARVC in Italy.² There is evidence that heavy exercise increases the risk of arrhythmic episodes in ARVC patients with desmosomal mutations, so strenuous exercise restriction is warranted in this population.³ The Bethesda Guidelines^{4,5} recommended exclusion of these subjects from most competitive sports with possible exception of those with low intensity (class IA). They considered that the risk of sports participation in athletes with ARVC and having an ICD is unacceptably high but recommended to allow athletes to engage in class IA competitive sports if they did not have any episode of ventricular arrhythmia in last six months. They also opposed the use of ICD in athletes who desire to be in competitive sports as a primary prevention. The excess risk of a ventricular arrhythmia with competitive athletic activity is well known. However, recent data has been shown that endurance exercise increases the risk of VT and development of ARVC in desmosomal mutation carriers, which further support exercise restrictions in these patients.³

The initial ECG in this patient was abnormal with T wave inversions beyond lead V₂ is suggestive of ARVC as it is taken as a major criterion according to recent Task Force changes.¹ Terminal activation duration ≥ 55 msec is another minor criterion for ARVC, but in our case the TAD = 47 msec. The echocardiographic findings were not remarkable in this case. In one study, it was found that patients with ARVC have significant RA and RV enlargement and decreased RV function, which can be easily assessed on standard echocardiography.⁶ It was noted that at least one RV morphologic abnormality occurred in 62% and two or more RV morphologic abnormalities were present in 38%. The most frequent morphologic abnormality was trabecular derangement seen in 54%.

In our patient, there was documented non-sustained ventricular tachycardia at peak exercise and recovery signifying exercise being the precipitating factor. In a study by Kottarthil et al., it was concluded that ETT is safe in ARVC and sustained VT during ETT is not common and does not differentiate ARVC from idiopathic VT. Since idiopathic VT is usually LBIA morphology, the presence of LBSA ectopy favors ARVC as the diagnosis.⁷ It was also observed that decreased exercise capacity in ARVC predicts development of symptomatic heart failure in future.

The CMR results were not markedly abnormal, however the dilated RV with an increased RV end-diastolic volume is consistent with ARVC. Tandri et al., showed qualitative parametric assessment including fat infiltration of RV was less specific than RV kinetic abnormalities, such as RV dilatation and regional RV dysfunction.⁸

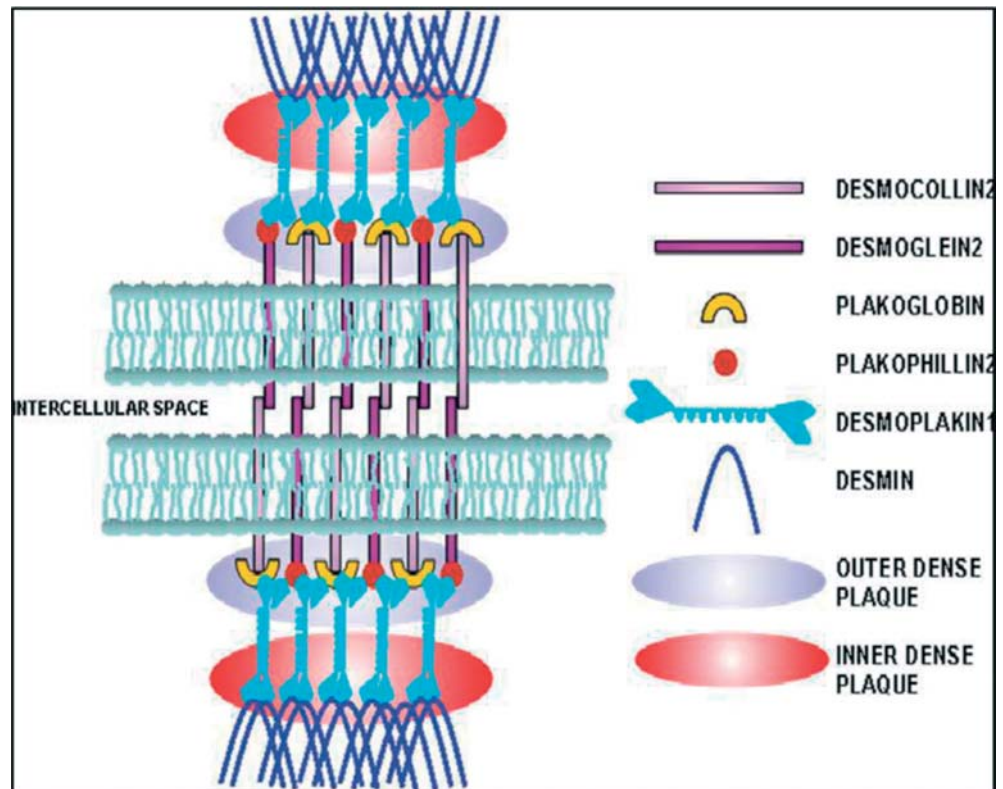


Figure 9. The desmosome consists of three families of proteins: the desmosomal cadherins, desmocollin and desmoglein, members of the armadillo family of proteins, plakoglobin and plakophilin, and the plakins. Binding of these proteins tethers desmin intermediate filaments to the plasma membrane in cardiac myocytes and adheres adjacent myocytes together.¹⁰

In regard to electrophysiological study, our patient did show upper normal range of endocardial activation duration (EAD) of 63 msec, with the earliest activation being at the apex and the latest at the outflow tract. This is supported by the work of Tandri et al.⁹ who showed total right ventricular EAD to be significantly prolonged (more than 65 msec) in ARVC compared with idiopathic VT. Consistent with the CMR results, there were no areas of scar on the endocardial voltage map.

PKP2 gene (plakophilin-2) is a desmosomal gene which encodes for PKP2 protein¹⁰ (Figure 9). The most common form of ARVC, or Type 9, is caused by a mutation in this gene. A study by Gerull et al.¹¹ showed either alterations or absence of the PKP2 structure in the desmosomes of myocytes impair their interaction among themselves leading to myocardial disruption, more commonly during myocardial stress, therefore predisposing affected individuals to ventricular arrhythmias during exercise.

This mutation is a class I variant, meaning it is strongly expected to predispose to cardiomyopathy, like ARVC. This mutation alters a canonical intronic splice site and is therefore predicted to disrupt normal protein generation. To date, this mutation has not been seen in healthy individuals. Moreover, the same gene mutation was found in the mother showing genetic transmission which is a major criterion.¹ PKP2 IVS3-2A > G has not been associated with disease in the literature to date. This unusual mutation variant would be the first of its kind associated with ARVC supported by ECG changes, mild MRI abnormalities, non-sustained VT during exercise stress test originating from the right ventricle, and appropriate ICD discharge for sustained VT.

CONCLUSIONS

PKP2IVS3-2A > G, splice mutation is a newly identified mutation causing ARVC that has not been previously seen in 1000 genomes or dbSNP (database of single nucleotide polymorphism). This mutation predisposes patients to ventricular arrhythmias that appear to be catecholamine sensitive.

REFERENCES

- [1] Marcus FI, McKenna WJ, Sherrill D, Basso C, Bauce B, Bluemke DA, Calkins H, Corrado D, Cox MG, Daubert JP, Fontaine G, Gear K, Hauer R, Nava A, Picard MH, Protonotarios N, Saffitz JE, Sanborn DM, Steinberg JS, Tandri H, Thiene G, Towbin JA, Tsatsopoulou A, Wichter T, Zareba W. Diagnosis of arrhythmogenic right ventricular cardiomyopathy/dysplasia: proposed modification of the task force criteria. *EurHeart J*. 2010;31:806–814.
- [2] Corrado D, Basso C, Rizzoli G, Schiavon M, Thiene G. Does sports activity enhance the risk of sudden death in adolescents and young adults? *J Am Coll Cardiol*. 2003;42:1959–1963.
- [3] James CA, Bhonsale A, Tichnell C, Murray B, Russell SD, Tandri H, Tedford RJ, Judge DP, Calkins H. Exercise increases age-related penetrance and arrhythmic risk in arrhythmogenic right ventricular dysplasia/cardiomyopathy-associated desmosomal mutation carriers. *J Am Coll Cardiol*. 2013;62(14):1290–1297.
- [4] Maron BJ, Zipes DP, et al., 36th Bethesda Conference:eligibility recommendations for competitive athletes with cardiovascular abnormalities. *J Am Coll Cardiol*. 2005;45(8):1318–1321.
- [5] Maron BJ, Ackerman MJ, Nishimura RA, Pyeritz RE, Towbin JA, Udelson JE. Task Force 4: HCM and other cardiomyopathies, mitral valve prolapse, myocarditis, and marfan syndrome. *J Am Coll Cardiol*. 2005;45(8):1340–1345.
- [6] Yoerger DM, Marcus F, Sherrill D, Calkins H, Towbin JA, Zareba W, Picard MH, Multidisciplinary Study of Right Ventricular Dysplasia Investigators. Echocardiographic findings in patients meeting task force criteria for arrhythmogenic right ventricular dysplasia: new insights from the multidisciplinary study of right ventricular dysplasia. *J Am Coll Cardiol*. 2005;45(6):860–865.
- [7] Kottarathil J, Panuganti P, Jain A, Dalal D, Russell SD, Judge D, Calkins H, Tandri H. Role of Exercise Stress Testing in Arrhythmogenic Right Ventricular Dysplasia. *Circulation*. 2010;122:A12355.
- [8] Tandri H, Castillo E, Ferrari VA, Nasir K, Dalal D, Bomma C, Calkins H, Bluemke DA. Magnetic resonance imaging of arrhythmogenic right ventricular dysplasia: sensitivity, specificity, and observer variability of fat detection versus functional analysis of the right ventricle. *J Am Coll Cardiol*. 2006;48(11):2277–2284.
- [9] Tandri H, Asimaki A, Abraham T, Dalal D, Tops L, Jain R, Saffitz JE, Judge DP, Russell SD, Halushka M, Bluemke DA, Kass DA, Calkins H. Prolonged RV endocardial activation duration: a novel marker of arrhythmogenic right ventricular dysplasia/cardiomyopathy. *Heart Rhythm*. 2009 June;6(6):769–775.
- [10] ElMaghawry M, Migliore F, Mohammed N, Sanoudou D, Alhashe M. Science and practice of arrhythmogenic cardiomyopathy: a paradigm shift. *GCSP*. 2013;8. <http://dx.doi.org/10.5339/gcsp.2013.8>
- [11] Gerull B, Heuser A, Wichter T, Paul M, Basson CT, McDermott DA, Lerman BB, Markowitz SM. Mutations in the desmosomal protein plakophilin-2 are common in arrhythmogenic right ventricular cardiomyopathy. *Nat Genet*. 2004 Nov;36(11):1162–1164, Epub 2004 Oct 17. Erratum in: *Nat Genet*. 2005 Jan;37(1):106.