

Reliability of preoperative CT and intraoperative manual tests in syndesmosis injury

 Emre Kaya,¹  Zeki Tasdemir,²  Ozgur Erdogan,³  Furkan Akbas⁴

¹Department of Orthopaedics and Traumatology, Cakmak Erdem Hospital, Istanbul, Turkiye

²Department of Orthopaedics and Traumatology, Servergazi State Hospital, Denizli, Turkiye

³Department of Orthopaedics and Traumatology, Haydarpasa Numune Training and Research Hospital, Istanbul, Turkiye

⁴Department of Orthopaedics and Traumatology, Basaksehir Cam and Sakura City Hospital, Istanbul, Turkiye

ABSTRACT

OBJECTIVE: We always confirm the diagnosis of syndesmotoc injury with a Hook test for all ankle fractures and fixed if necessary. Then, we noticed a discrepancy between preoperative radiology and the Hook test. Moreover, we want to report the reliability of syndesmotoc fixation decisions with Hook test and preoperative radiology.

METHODS: A total of 37 surgically treated patients with isolated Weber type C ankle fractures were included in the study. In all patients, the syndesmosis joint was injured in preoperative computed tomography and X-ray imaging. However, only patients with (+) Hook tests had undergone a syndesmosis fixation. Patients were divided into two groups: Group A: Hook tests (+) and Group B: Hook test (–). Also, the groups were compared according to clinical outcomes with the Visual Analog Scale (VAS), American Orthopedic Foot and Ankle Society (AOFAS), and foot and ankle disability index (FADI) scores.

RESULTS: The mean participant age was 39 (19–80) years, and the mean follow-up period was 47.27 (22–68) months. Groups A and B consisted of 17 (45.9%) and 20 (54.1%) patients, respectively. The mean VAS, AOFAS, and FADI scores were 17.7±14.3, 90.32±8.06, and 92.9±6.88, respectively. “Excellent” and “good” results were found in 34 (%91.8) patients according to AOFAS nad FADI. The malreduction rate was 8.1% in all patients, 5% in group A, and 11.8% in group B. No statistically significant differences in final functional scores were found between groups A and B.

CONCLUSION: Hook test is reliable and adequate for evaluating the stability and quality of syndesmosis reduction. Weber type C lateral malleolar fractures in the decision of syndesmosis fixation; although syndesmosis injury is diagnosed in preoperative radiology, we recommend that the diagnosis be confirmed with the Hook test.

Keywords: Ankle; CT; fracture; Hook test; syndesmosis.

Cite this article as: Kaya E, Tasdemir Z, Erdogan O, Akbas F. Reliability of preoperative CT and intraoperative manual tests in syndesmosis injury. *North Clin Istanbul* 2024;11(1):52–59.

The classic presentation of syndesmotoc injury usually occurs with the Danis-Weber type C ankle fractures [1, 2]. Tibiofibular joint malreduction with syndesmotoc injury has been shown to impair ankle function and lead to early osteoarthritis (OA) [3, 4]. For this reason, the stabilization of syndesmosis is mandatory during bone fixation [4, 5]. Preoperative and intraoperative methods

have been used for diagnosing this injury. However, the reliability of these methods remains controversial.

Weber type C lateral malleolar fractures extend to the syndesmotoc joint, and if the fracture is displaced, computed tomography (CT) shows unreduced syndesmosis. Preoperative radiology and Hook test after fracture stabilization of the fracture may not be compatible with



Received: September 27, 2022 *Accepted:* May 10, 2023 *Online:* January 26, 2024

Correspondence: Emre KAYA, MD. Cakmak Erdem Hastanesi, Ortopedi ve Travmatoloji Klinigi, Istanbul, Turkiye.

Tel: +0850 222 04948 e-mail: emrekaya0034@gmail.com

© Copyright 2024 by Istanbul Provincial Directorate of Health - Available online at www.northclinist.com

each other. In this study, we reported the mid-term functional and radiological results of the cases in which we decided to have syndesmosis surgery with the Hook test.

The outcomes of cases with Hook test (–) would be an important factor for us. Because cases with Hook test (–) would have corrected the wrong diagnosis of syndesmosis (+) in preoperative radiology. Our hypothesis is that the results of the hook test (–) cases show us the superiority of the hook test over preoperative radiology, while the hook test (+) and (–) results of both groups show us the accuracy of the hook test. Therefore, the cases were grouped as hook (+) and hook (–) according to Hook test, and the radiological and clinical outcomes of the groups were wanted to be reported.

Our hypothesis stated that Hook test is efficient in the decision of the syndesmosis injury in Weber type C fractures and prevents misdiagnoses caused by preoperative CT. Our main goal was to inform the validity and reliability of the intraoperative Hook test in the decision of the syndesmosis fixation.

MATERIALS AND METHODS

The study was performed following the ethical standards of the Declaration of Helsinki. All patients provided informed consent before inclusion in the study. Institutional Review Board (IRB) approval (Date: June 26, 2019, Number: 2019/514/156/6) was obtained. After IRB approval was obtained, 69 patients with fibula distal fractures between April 2014 and February 2018 were retrospectively examined. Patients who were older than 16 years and had single Weber type C fractures with syndesmotom injury based on CT were included. The exclusion criteria included open (1 patient), previous ankle fractures (3 patients) and concomitant fractures (8 patients), diabetic or other neuropathies (2 patients), a delay to trauma to surgery more than 7 days (4 patients), and inadequate ability of the patient to cooperate (2 patients). Furthermore, patients with <2 years of follow-up were excluded from the study. Further, 49 patients were found to be suitable for inclusion and were followed up. Seven patients in group A and five patients in group B had <2 years of follow-up. The remaining 37 patients were included in the study. Patients were divided into two groups: Group A: Hook test (+) and group B: Hook test (–). In these two groups, preoperative and postoperative radiological findings and clinical outcomes were compared. Radiologic evaluations were performed using preoperative CT and bilateral postoperative ankle CT.

Highlight key points

- Ankle CT has no role in the evaluation of syndesmosis injury in ankle fractures.
- In the surgical treatment of ankle fractures, preoperative CT of ankle may make false diagnosis of syndesmosis injury.
- Intraoperative unique manual tests are very successful in the diagnosis of syndesmosis injury and should be used in the decision of syndesmosis fixation.
- Functional results are very poor in malreduction of the syndesmosis joint.

Preoperative CT evaluations were obtained based on the technique described by Yeung et al. [6] Measurements were made in 1-mm-thick slices using a bone window, and PACS was used for measurements. The morphology width and volume of the syndesmosis were measured on the axial images. Anterior, middle, posterior, and maximal (aTFD, mTFD, pTFD, and maxTFD, respectively) tibiofibular distances were obtained from axial CT images at 10 mm proximal to the tibial plafond as described in previous studies [6]. Postoperative radiological evaluations; syndesmosis reduction was controlled with postoperative bilateral weight-bearing ankle AP radiography and bilateral axial CT (compared measurements with the uninjured side) at the last follow-up time of the patients. The reduction of the distal tibiofibular joint was assessed by measuring the width of the syndesmosis from both ankles in the anterior (anterior widening [AW]) and posterior (posterior widening [PW]) borders in axial CT scans approximately 1 cm proximal from the tibial plafond. The mean width of the syndesmosis was calculated as described by Mukhopadhyay et al. [7] ($[AW \text{ injured ankle} - AW \text{ normal side}] + [PW \text{ injured ankle} - PW \text{ normal side}]/2$). Malreduction was defined as >2 mm side-to-side difference, in accordance with the literature [7–9]. As an example of this technique, CT images of a case with malreduction are shown in Figure 1. All patients underwent open reduction plate and screw fixation for the fibula fracture. The fixation was done according to the Arbeitsgemeinschaft für Osteosynthesefragen fixation principles with anatomical distal fibula plates [10]. After bone fixation, the Hook test was performed intraoperatively by applying a lateral force to the fibula with a bone hook clamp. Lateral displacement causing tibiofibular widening is considered a pathological sign and an indication for syndesmotom fixation. Syndesmosis was fixed only in patients in whom intraoperative tibiofibular widening was observed. All surgeries were

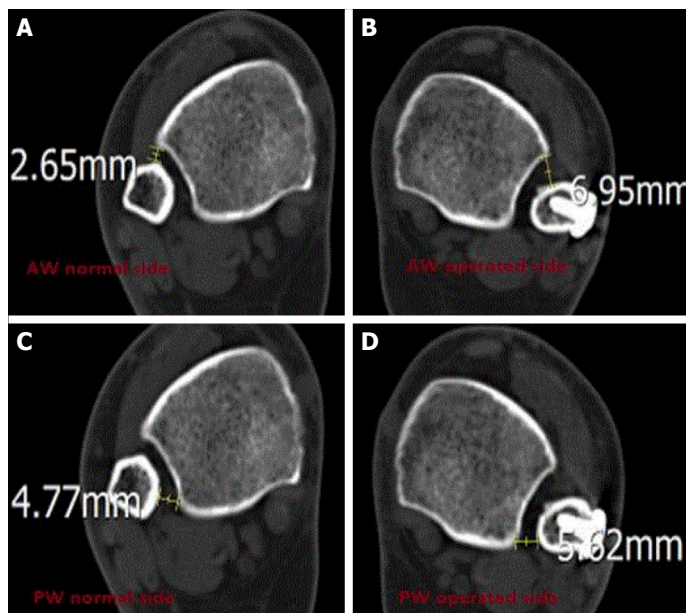


FIGURE 1. An example of evaluating a case of malreduction on CT by Mukhopadhyay method [7]: normal side (**A, B**) and operated (**C, D**). (**A**) AW normal side, (**B**) AW operated side, (**C**) PW normal side, and (**D**) PW operated side. Mean width of the syndesmosis: $[(\text{AW operated ankle} - \text{AW normal side}) + \text{PW operated ankle} - \text{PW normal side}]/2$, showing more than 2-mm side-to-side difference signifying malreduced syndesmosis $[(6.95 - 2.65) + (5.62 - 4.77)]/2 = 2.4 \text{ mm}$. AW: Anterior widening of tibiofibular borders; PW: Posterior widening of tibiofibular borders.

performed by two surgeons who were interested in foot and ankle surgery. Fixation of the syndesmosis was done with a 3.5-mm full-thread cortical screw from the fibula to the tibia and parallel to the joint line when the ankle joint was in a neutral position. The screw was placed 1.5–2 cm above the joint line, and three cortices were passed in all patients. No washer was used. After syndesmosis fixation, the reduction of the distal tibiofibular joint was checked using fluoroscopy.

In all patients in group A, Hook test was (+) performed. After applying plate screw osteosynthesis for fracture reduction, Hook test (+) was used to determine whether to perform syndesmosis fixation.

In all patients, the ankle was immobilized for 6 weeks in a below-knee cast in a neutral position allowing for partial weight-bearing. After the cast removal, the ankle was examined, and a research physiotherapist instructed the patient on the rehabilitation protocol. No additional bracing was used, and weight-bearing was allowed as tolerated. Patients visited the outpatient clinic after 3, 6,

and 12 weeks. Joint congruity and fracture healing were assessed using X-rays. Additional visits were scheduled if necessary. Syndesmosis screws were removed 12 weeks after surgery in all group A patients.

Visual Analog Scale (VAS), American Orthopedic Foot and Ankle Society (AOFAS), and Foot and Ankle Disability Index (FADI) scores were calculated for all patients at the final follow-up time. According to AOFAS and FADI scores, 90–100 points were accepted as “excellent” results, 80–90 points were accepted as “good” results and <80 points were accepted “poor” results. At the final follow-up period, syndesmosis reduction was evaluated with bilateral CT axial slides in all patients. Radiation exposure was minimized by taking one CT image at a time of both ankles. All patients were informed of this procedure beforehand.

OA was assessed with CT following the classification of Morrey and Wiedeman (grade 0=no signs of OA; grade I: minimal narrowing of the joint space and the formation of osteophytes; grade II: Marked narrowing of the joint space and the formation of osteophytes; and grade III: Total degeneration of the joint and gross deformity or ankylosis) [11, 12]. The Brooker classification system was used for heterotopic ossification (HO). The radiologist assessing preoperative and follow-up CT scans was blinded to functional results.

In five patients, implant removal was required due to plate and screw protrusion. Two of our patients had superficial wound infections and were treated with oral antibiotherapy. One patient developed ankle stiffness, and the range of motion was regained with physical therapy in 6 months. Our patient with uncontrolled diabetes mellitus underwent plate and screw removal, and several debridements were performed because of deep infection and osteomyelitis. Thus, this patient was excluded from the study. Reflex sympathetic dystrophy developed in three patients. All of them recovered with oral bisphosphonates and physical therapy.

Statistical Analysis

The consistency of continuous variables to normal distribution was tested with the Shapiro–Wilk test. Descriptive statistics were used to define the average of continuous variables, standard deviation, minimum, median, and maximum). Comparisons of two variables not suitable for independent and normal distributions were made using the Mann–Whitney U test. The Chi-square test (or Fisher’s exact test where appropriate) was used to ex-

TABLE 1. Range of parameters for groups A and B. Group A: Hook test (+) and fixed syndesmosis. Group B: Hook test (-) and not fixed syndesmosis

	Group A Mean±SD, Median (Min–Max)	Group B Mean±SD, Median (Min–Max)	p
Follow-up (month)	44±15, 43 (24–66)	50±13, 51 (24–68)	0.232
Age	38±11, 39 (19–52)	40±14, 39 (20–80)	0.892
VAS score	18±15, 20 (0–40)	18±14, 21 (0–35)	1.000
FAOS score	90±9, 88 (75–100)	91±8, 89 (77–100)	0.964
FADI score	92.4±7.7, 92 (75–100)	93.4±6.3, 94.2 (78.8–100)	0.775
Sex, %			1.000
Male	64.7	60	
Female	35.3	40	
Osteoarthritis (Morrey-Wiedeman classification)			0.305
Grade 0	70.6	90	
Grade 1	17.6	10	
Grade 2	11.8	0	
Malreduction			0.584
(+)	11.8	5	
(-)	88.2	95	

SD: Standard deviation; Min: Minimum; Max: Maximum; VAS: Visual analog score; FAOS: Foot and ankle outcome score; FADI: Foot and ankle disability score.

TABLE 2. Effect of functional scores of malreduction

	Malreduction (+) Mean±SD, Median (Min–Max)	Malreduction (-) Mean±SD, Median (Min–Max)
Follow-up (month)	42±21, 32 (27–66)	48±14, 50 (24–68)
Age	35±10, 32 (26–46)	39±13, 39 (19–80)
VAS score	30±10, 30 (20–40)	17±14, 20 (0–40)
FAOS score	82±6, 84 (75–87)	91±8, 89 (75–100)
FADI score	87.2±10.6, 92.3 (75–94.2)	93.4±6.5, 94.2 (78.8–100)

SD: Standard deviation; Min: Minimum; Max: Maximum; VAS: Visual analog score; FAOS: Foot and ankle outcome score; FADI: foot and ankle disability score.

amine the relationship between categorical variables. The statistically significant level was set at 0.05. The analyses were performed using the MedCalc Statistical Software version 12.7.7 Program (MedCalc Software bvba, Ostend, Belgium; <http://www.medcalc.org>; 2013).

RESULTS

The mean age was 39 (19–80) years. Twenty-three (62.2%) patients were men, and 14 (37.8%) were women. The mean follow-up period was 47.27 (24–68)

months. The mean VAS, AOFAS, and FADI scores were 17.7±14.3, 90.32±8.06, and 92.9±6.88, respectively ($p=1.000$, 0.964, and 0.775, respectively). “Excellent” and “good” results were found in 34 (91.8%) patients, poor results were found in 3 patients (8.1%) according to AOFAS and FADI scores.

The distribution of these radiologic and functional parameters according to groups A and B are shown in Table 1. No statistically significant differences in final functional scores were found between groups A and B (Table 1, 2). Group A comprised 17 (45.9%) patients,

TABLE 3. Demographic parameters for the study

	Mean±SD	Median (Min–Max)
Follow-up (month)	47.27±14.06	50 (24–68)
Age	38.68±12.4	39 (19–80)
VAS score	17.78±14.3	20 (0–40)
FAOS score	90.32±8.06	88 (25–75)
FADI score	92.9±6.88	94.2 (25–75)
Age (n=37), %		
Male		62.2
Female		37.8
Syndesmosis screw, %		
Yes		45.9
No		54.1
Osteoarthritis (Morrey-Wiedeman classification), %		
Grade 0		81.1
Grade 1		13.5
Grade 2		5.4
Heterotopic ossification (syndesmotic), %		
Yes		8.1
No		91.9
Malreduction		
Yes		8.1
No		91.9

SD: Standard deviation; SD: Standard deviation; Min: Minimum; Max: Maximum; VAS: Visual analog score; FAOS: Foot and ankle outcome score; FADI: Foot and ankle disability score.

while group B comprised 20 (54.1%). According to the Morrey–Wiedeman classification, five (13.3%) patients had grade I and two (5.4%) patients had grade II OA. No grade III patients participated in our study. The HO rate was 8% (3/37). All lesions were around the syndesmosis joint, and all patients were in group A. The mean VAS, AOFAS, and FADI scores in patients with HO were 26, 90.6, and 87.3, respectively.

The malreduction was detected in three patients (8.1%). Two of them belonged to group A, and the remaining one belonged to group B (Table 3). One of the patients who was diagnosed malreduction in group A, malreduction was diagnosed at the first postoperative day and had revision surgery on the 2th postoperative day in the early period. The reduction was achieved for this patient with an additional syndesmosis screw and a second surgical intervention. The VAS, AOFAS, and FADI

scores of this patient were 20, 87, and 94, respectively, at the final visit. No evidence of OA was detected in this patient. The other two patients with malreduction did not accept a second intervention. In these two patients, VAS, AOFAS, and FADI mean scores were 35, 80, and 82, respectively, at the final visit. Furthermore, grade 1 OA was detected in both of them.

In patients with OA, the VAS, AOFAS, and FADI scores were 23, 88, and 89, respectively, at the final visit. Although no significant differences were found, the functional results were slightly lower in patients with grade II OA.

DISCUSSION

Syndesmosis reduction is crucial to restoring ankle joint anatomy and function, preventing the development of ankle arthritis in ankle fractures [4, 5]. Assessments of syndesmosis diagnosis can be divided into preoperative and intraoperative methods. The former is based on the analysis of the preoperative X-rays. Radiography demonstrated an obvious injury with a clear widening of the syndesmosis. However, more recent studies showed that preoperative radiography was poor at predicting subtle syndesmotic injuries. It seemed that radiography alone was not enough to determine the need for a trans-syndesmotic fixation. Some authors supported that magnetic resonance imaging (MRI) might clarify the complex syndesmotic injuries [13]. However, MRI is expensive and less accessible to patients and requires an experienced operator. Although arthrogram may provide more information, it is an invasive method and needs an experienced operator [14]. Some authors reported the use of ankle arthroscopy in diagnosing syndesmotic injury [13, 15]. However, the addition of an arthroscopic procedure may prolong the surgical time and increase the costs. Some intraoperative manual tests, such as Hook and Chertsey tests, have been described. The latter needs radiopaque material and an experienced operator.

Preoperative CT has been reported to be effective in the diagnosis of syndesmotic injury in ankle fractures [16, 17]. Tibio-fibular distance measurements on axial CT images predict syndesmotic instability [6].

Dissociation caused by fracture displacement should always be considered. It is important to distinguish between syndesmosis diastasis and ankle instability according to CT findings. In our study, the tests were checked

under fluoroscopy before and after bone reduction and also after syndesmotic reduction. This process might have reduced misdiagnosis in our series.

Kocadal et al. [18] reported a mean AOFAS score of 86.1 in ankle fractures with syndesmotic injury. However, in a meta-analysis, the mean AOFAS score was found to be 91.3 [19]. Colcuc et al. [20] reported a mean FADI score of 94.0 in their series. In our study, the mean AOFAS, FADI, and VAS scores were 90.3, 92.9, and 17.7, respectively. However, no statistically significant difference in functional scores was found between groups A and B. Our results were similar to those in the literature.

Several studies showed that the loss of syndesmotic joint reduction is an important predictor of functional outcomes in patients with syndesmotic injury [7, 21]. In our study, the functional results of the patients with malreduction were also poor. Thus, anatomical reduction of the bone might provide more syndesmosis stability and better functional outcomes in ankle fractures associated with a syndesmotic injury. In a recent meta-analysis comparing the suture button and syndesmotic screw fixation types of syndesmotic injury, the mean malreduction rate was reported as 6.1% [22]. In our study, the malreduction rate was similar to that in the literature (8.1%).

In a prospective study, syndesmotic injury fixation was checked by intraoperative CT and fluoroscopy in 36 patients, and postoperative reduction success rates were compared with postoperative axial CT. In this study, malreduction rates with intraoperative CT (6%) were significantly lower than malreduction rates based on intraoperative fluoroscopy (40%). After this study, intraoperative radiography was found to be unsuccessful in diagnosis [23]. On the contrary, we found that we were successful (8.1% malreduction rate) in diagnosis with fluoroscopy obtained by intraoperative Hook tests in our patient group with a similar number (37 patients). Facilities in every operating room, such as intraoperative CT, do not always exist. Furthermore, intraoperative CT has disadvantages such as mobilization of anesthetized patients and extension of surgical times.

In a study, preoperative CT in the diagnosis of the syndesmosis was compared with the Chertsey test (a radiographic dye method for intraoperative evaluation of syndesmotic injuries), which is one of the intraoperative tests for diagnosing syndesmotic injuries [24]. The Chertsey test was found positive in 13 (33.3%) of 39 patients diagnosed syndesmotic injury in preopera-

tive CT, which was found valuable in diagnosing syndesmosis. In our study, 17 (45.9%) of 37 patients with syndesmotic injury on preoperative CT were Hook test (+). The aforementioned study and our study had quite similar points: similar patient numbers (37 in our study and 39 in this study) and both intraoperative tests and preoperative CT evaluation of syndesmosis were compared. However, in this study, the syndesmotic injury was accepted as a completely correct diagnosis in preoperative CT, whereas we compared the superiority of these two diagnostic methods over each other by controlling them with postoperative intact ankle using comparative compression ankle radiographs and comparative bilateral ankle CT. This was because our study also reported preoperative CT overdiagnosis. This was the highlight of our study.

In the aforementioned study, the authors reported that a fracture with syndesmotic injury resulted in greater pain and reduced function [23]. In our study, the mean functional results of both groups were good. This difference might be due to more successful diagnoses and prevention of overtreatment.

In general, functional results of patients with ankle OA are similar to those of patients who have no OA findings as reported in the literature [9]. In our study, the functional results were also similar between the patients without OA. The classical knowledge establishes that OA develops after 2 years in ill-consolidated ankle fractures. The limitation of this study was that our patients had a short follow-up period (mean 47.7 months). Therefore, perhaps, in the worst-case scenario, nowadays they are normal, but they may develop pan-OA in the future. Hence, more detailed follow-ups are required. We want to provide information on the early stages because we think that OA develops early if severe malreduction of syndesmosis occurs.

Preoperative axial ankle CT has been reported as a successful method for diagnosing syndesmotic injury [6, 17]. However, in our study, the Hook test showed no injury in 54.1% of the patients with a (+) preoperative CT diagnosis. Furthermore, the functional scores and radiological results were excellent in these patients. Therefore, we think that preoperative CT scans without other tests may cause misdiagnosis in assessing syndesmosis and Hook test is highly efficient in the diagnosing of syndesmotic injuries.

In another study, the authors reported that syndesmosis was reduced spontaneously in malreduction

cases after the syndesmosis screw was removed [25]. They reported a malreduction rate of 36% and a spontaneous reduction rate of 89% after screw removal. The authors concluded that syndesmotic screw removal might provide anatomic reduction of malreduced syndesmosis. We think that this malreduction rate is probably due to unnecessary fixation of an intact syndesmosis joint.

HO is a well-documented long-term complication of syndesmotic injury [26–28]. In our study, three patients (8.1%) with HO were found. No severe cases or synostoses were encountered in our study. We could not make any comment about this complication because of the low patient number and short follow-up time. However, in patients with HO, we found that the tibiofibular area had narrowed in the axial CT. We think that excessive rigid fixation of the syndesmosis with a screw may cause HO. Furthermore, the fixation of a noninjured syndesmosis may cause additional complications, such as HO, due to overtreatment.

The limitations of this study were as follows: (1) small size sample in the two groups and (2) a relative short postoperative follow-up period to detect OA changes. The other limitations were the retrospective nature of the study; a prospective study might have provided more information. With a prospective model, preoperative and postoperative CT scans can be compared after fracture fixation. The strengths of our study comprised investigating isolated Weber type C lateral malleolar fractures without syndesmotic injury. Furthermore, all surgeries were performed by two experienced foot and ankle surgeons, controlling for the reduction on the normal side using bilateral CT scans.

Conclusion

We suggest using the Hook test to determine the distinction between syndesmotic ligament disruption and real syndesmotic instability. Hook test after the fixation of bones provide practical, rapid, and safe determinations without additional radiation and costs. These tests are reliable and adequate for evaluating the stability and quality of the syndesmosis reduction. In addition, preoperative CT may lead to a false positive diagnosis of syndesmosis injury, and also, unnecessary fixation of syndesmosis may cause malreduction and HO.

Ethics Committee Approval: The Kartal Lutfi Kirdar Training and Research Hospital Clinical Research Ethics Committee granted approval for this study (date: 26.06.2019, number: 2019/514/156/6).

Authorship Contributions: Concept – EK, ZT; Design – EK, ZT; Supervision – EK; Fundings – EK; Materials – EK, FA; Data collection and/or processing – EK; Analysis and/or interpretation – EK; Literature review – EK; Writing – EK; Critical review – EK, OE.

Conflict of Interest: No conflict of interest was declared by the authors.

Use of AI for Writing Assistance: No.

Financial Disclosure: The authors declared that this study has received no financial support.

Peer-review: Externally peer-reviewed.

REFERENCES

1. Lauge-Hansen N. Fractures of the ankle. II. Combined experimental-surgical and experimental-roentgenologic investigations. *Arch Surg* (1920) 1950;60:957–85. [CrossRef]
2. Weber BG. Die verletzungen des oberen sprunggelenkes. In: Aktuelle probleme in Der Chirurgie. 2nd ed. Vienna: Verlag Hans Ruber; 1972. p. 51–65.
3. Pettrone FA, Gail M, Pee D, Fitzpatrick T, Vaan Herpe LB. Quantitative criteria for prediction of the results after displaced fracture of the ankle. *J Bone Joint Surg Am* 1983;65:667–77. [CrossRef]
4. Leeds HC, Ehrlich MG. Instability of the distal tibiofibular syndesmosis after bimalleolar and trimalleolar ankle fractures. *J Bone Joint Surg Am* 1984;66:490–503. [CrossRef]
5. Lindsjö U. Operative treatment of ankle fracture-dislocations. A follow-up study of 306/321 consecutive cases. *Clin Orthop Relat Res* 1985;199:28–38. [CrossRef]
6. Yeung TW, Chan CY, Chan WC, Yeung YN, Yuen MK. Can pre-operative axial CT imaging predict syndesmosis instability in patients sustaining ankle fractures? Seven years' experience in a tertiary trauma center. *Skeletal Radiol* 2015;44:823–9. [CrossRef]
7. Mukhopadhyay S, Metcalfe A, Guha AR, Mohanty K, Hemmati S, Lyons K, et al. Malreduction of syndesmosis--are we considering the anatomical variation? *Injury* 2011;42:1073–6. [CrossRef]
8. Naqvi GA, Cunningham P, Lynch B, Galvin R, Awan N. Fixation of ankle syndesmotic injuries: comparison of TightRope fixation and syndesmotic screw fixation for accuracy of syndesmotic reduction. *Am J Sports Med* 2012;40:2828–35. [CrossRef]
9. Kortekangas T, Savola O, Flinkkilä T, Lepojärvi S, Nortunen S, Ohtonen P, et al. A prospective randomised study comparing TightRope and syndesmotic screw fixation for accuracy and maintenance of syndesmotic reduction assessed with bilateral computed tomography. *Injury* 2015;46:1119–26. [CrossRef]
10. Ruedi TP, Buckley RE, Moran CG. *AO Principles of Fracture Management*. Second expanded edition. Vol. 2. Switzerland: AO Publishing; 2007. p. 871–97.
11. Morrey BF, Wiedeman GP Jr. Complications and long-term results of ankle arthrodeses following trauma. *J Bone Joint Surg Am* 1980;62:777–84. [CrossRef]
12. Pagenstert GI, Barg A, Leumann AG, Rasch H, Müller-Brand J, Hintermann B, et al. SPECT-CT imaging in degenerative joint disease of the foot and ankle. *J Bone Joint Surg Br* 2009;91:1191–6. [CrossRef]
13. Oae K, Takao M, Naito K, Uchio Y, Kono T, Ishida J, et al. Injury of the tibiofibular syndesmosis: value of MR imaging for diagnosis. *Radiology* 2003;227:155–61. [CrossRef]

14. Muratli HH, Biçimoğlu A, Celebi L, Boyacigil S, Damgaci L, Tabak AY. Magnetic resonance arthrographic evaluation of syndesmotic diastasis in ankle fractures. *Arch Orthop Trauma Surg* 2005;125:222–7.
15. Summers HD, Sinclair MK, Stover MD. A reliable method for intraoperative evaluation of syndesmotic reduction. *J Orthop Trauma* 2013;27:196–200. [\[CrossRef\]](#)
16. Dikos GD, Heisler J, Choplin RH, Weber TG. Normal tibiofibular relationships at the syndesmosis on axial CT imaging. *J Orthop Trauma* 2012;26:433–8. [\[CrossRef\]](#)
17. Carrozzo M, Vicenti G, Pesce V, Solarino G, Rifino F, Spinarelli A, et al. Beyond the pillars of the ankle: A prospective randomized CT analysis of syndesmosis' injuries in Weber B and C type fractures. *Injury* 2018;49 Suppl 3:S54–60. [\[CrossRef\]](#)
18. Kocadal O, Yuçel M, Pepe M, Aksahin E, Aktekin CN. Evaluation of reduction accuracy of suture-button and screw fixation techniques for syndesmotic injuries. *Foot Ankle Int* 2016;37:1317–25. [\[CrossRef\]](#)
19. Onggo JR, Nambiar M, Phan K, Hickey B, Ambikaipalan A, Hau R, et al. Suture button versus syndesmosis screw constructs for acute ankle diastasis injuries: a meta-analysis and systematic review of randomised controlled trials. *Foot Ankle Surg* 2020;26:54–60. [\[CrossRef\]](#)
20. Colcuc C, Blank M, Stein T, Raimann F, Weber-Spickschen S, Fischer S, et al. Lower complication rate and faster return to sports in patient with acute syndesmotic rupture treated with a new knotless suture button device. *Knee Surg Sports Traumatol Arthrosc* 2018;26:3156–64.
21. Sagi HC, Shah AR, Sanders RW. The functional consequence of syndesmotic joint malreduction at a minimum 2-year follow-up. *J Orthop Trauma* 2012;26:439–43. [\[CrossRef\]](#)
22. Shimozono Y, Hurley ET, Myerson CL, Murawski CD, Kennedy JG. Suture button versus syndesmotic screw for syndesmosis injuries: a meta-analysis of randomized controlled trials. *Am J Sports Med* 2019;47:2764–71. [\[CrossRef\]](#)
23. Davidovitch RI, Weil Y, Karia R, Forman J, Looze C, Liebergall M, et al. Intraoperative syndesmotic reduction: three-dimensional versus standard fluoroscopic imaging. *J Bone Joint Surg Am* 2013;95:1838–43.
24. Pepe M, Kocadal O, Gunes Z, Calisal E, Ceritoglu K, Aktekin CN. A radiographic dye method for intraoperative evaluation of syndesmotic injuries. *Foot Ankle Int* 2017;38:1380–6. [\[CrossRef\]](#)
25. Song DJ, Lanzi JT, Groth AT, Drake M, Orchowski JR, Shaha SH, et al. The effect of syndesmosis screw removal on the reduction of the distal tibiofibular joint: a prospective radiographic study. *Foot Ankle Int* 2014;35:543–8. [\[CrossRef\]](#)
26. Kennedy MA, Sama AE, Sigman M. Tibiofibular syndesmosis and ossification. Case report: sequelae of ankle sprain in an adolescent football player. *J Emerg Med* 2000;18:223–40. [\[CrossRef\]](#)
27. Boytim MJ, Fisher DA, Neumann L. Syndesmotic ankle sprains. *Am J Sports Med* 1991;19:294–8. [\[CrossRef\]](#)
28. Hopkinson WJ, St Pierre P, Ryan JB, Wheeler JH. Syndesmosis sprains of the ankle. *Foot Ankle* 1990;10:325–30. [\[CrossRef\]](#)