

# Chinese normative values of C1 sagittal canal diameter and definition of C1 hypoplasia

Yang Wang<sup>1</sup>, Yan An<sup>2</sup>, Wei Tian<sup>2</sup>, Yi-Min Ma<sup>3</sup>

<sup>1</sup>Department of Hand Surgery, Beijing Jishuitan Hospital, Peking University Fourth School of Clinical Medicine, Beijing 100035, China;

<sup>2</sup>Department of Spine Surgery, Beijing Jishuitan Hospital, Peking University Fourth School of Clinical Medicine, Beijing 100035, China;

<sup>3</sup>Department of Radiology, Beijing Jishuitan Hospital, Peking University Fourth School of Clinical Medicine, Beijing 100035, China.

Measuring the sagittal canal diameter (SCD) is crucial for cervical spine assessment. A small SCD predisposes patients to myelopathy.<sup>[1]</sup> Stenosis is less common at the C1 level than at the levels below C2.<sup>[2,3]</sup> The existing literature regarding hypoplastic stenosis at the C1 level includes a few case reports; based on the literature, C1 hypoplasia seems to be more common in Chinese populations.<sup>[3,4]</sup> Normative values of C1 SCD may help in the evaluation of potential cervical stenosis in a given clinical situation; they were reported as adequately powered for defining pure C1 hypoplasia.<sup>[2,5]</sup> However, there is a paucity of data on C1 SCD in Chinese populations compared with those in other populations [Supplemental Table 1, <http://links.lww.com/CM9/A538>]. Among several measurement methods, *in vivo* computed tomography (CT)-based measurements have been validated and found to be as accurate as measurements in cadaver studies.<sup>[1]</sup> Thus, we aimed to use CT-based measurements to establish normative values for C1 SCD in Chinese adults and to define C1 hypoplasia.

This cross-sectional observational study protocol was approved by our Institutional Review Board, and the need for informed consent was waived. Patients were selected from among 816 emergency patients who underwent fine-cut (0.625-mm slices) maxillofacial CT (Aquilion PRIME ESX-302A, TOSHIBA Inc., Japan) for suspected nasal fractures between April 2005 and August 2019. Individuals with a medical history of neck pain, neurologic deficit, prior surgery, and known syndromic diagnoses were excluded based on chart review and CT evaluation. Measurements were performed by two independent researchers with tools available in the picture archiving and communication system 11.0 (Carestream Health, Inc., Rochester, NY, USA).

The C1 SCD was measured from the posterior-most portion of the fovea dentis to the anterior-most portion of the C1 posterior arch.<sup>[2]</sup> The dens sagittal diameter was measured as the outer diameter at the widest point. The space available for the cord (SAC) at C1 and C2 was measured from the posterior edge of the axis to the posterior-most portion of the ventral lamina [Figure 1A and 1B]. C1 hypoplasia was defined as a C1 SCD less than or equal to the lowest 2.5% of the measurements (1.96 standard deviations below the mean).<sup>[2,5]</sup>

Parameters (age, C1 SCD, dens sagittal diameter, C1 SAC, and C2 SAC) were calculated as the means  $\pm$  standard deviations. Unpaired two-sample *t*-tests were used to determine sex differences and to compare C1 SAC with C2 SAC. The Shapiro-Wilk test was used to examine the normality of C1 SCD measurements; histograms were plotted. After defining C1 hypoplasia, parameters were compared between patients with and without C1 hypoplasia. The ratio of dens sagittal diameter to C1 SCD (the ratio of dens/canal) was also compared. All statistical analyses were performed using SPSS version 24.0 (IBM Corp., Armonk, NY, USA); *P* values < 0.05 were considered significant.

We included 567 patients (345 men; 222 women): 328, nasal fractures; 239, no fracture. The average age was  $29.63 \pm 6.92$  (range, 18–45) years. No significant difference was observed between the sexes in age (*P* = 0.167). The following average values were noted: C1 SCD  $29.96 \pm 1.99$  (range, 24.60–35.28) mm; dens sagittal diameter  $10.94 \pm 0.53$  (range, 10.01–11.87) mm; C1 SAC  $18.08 \pm 1.49$  (range, 13.38–22.56) mm; and C2 SAC was  $18.22 \pm 1.20$  (range, 14.35–22.18) mm. Men had a larger C1 SCD, dens sagittal diameter, C1 SAC, and C2 SAC than women (*P* < 0.001). No significant difference was found between C1 SAC and C2 SAC (*P* > 0.05) [Supplemental Table 2, <http://links.lww.com/CM9/A538>].

Access this article online

Quick Response Code:



Website:  
[www.cmj.org](http://www.cmj.org)

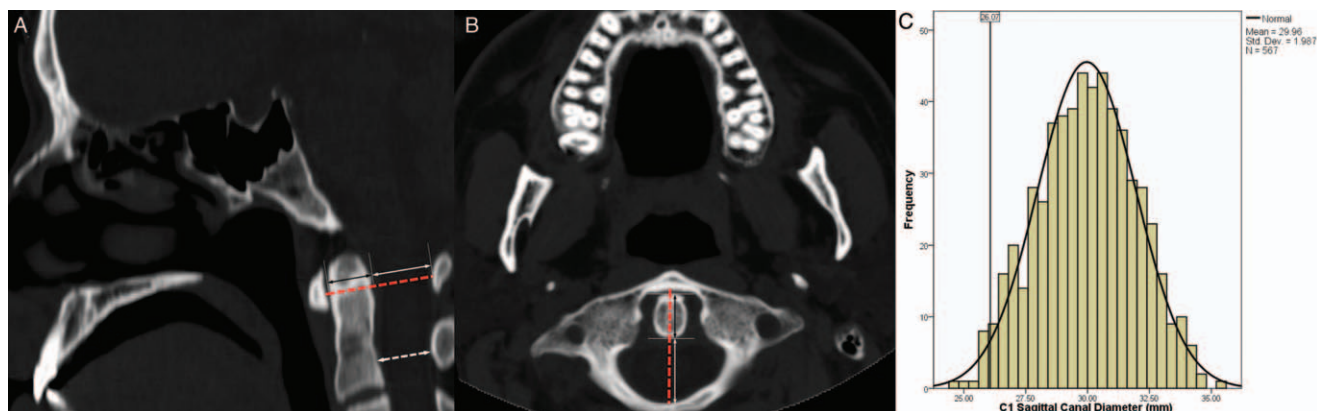
DOI:  
10.1097/CM9.0000000000001497

**Correspondence to:** Dr. Wei Tian, Department of Spine Surgery, Beijing Jishuitan Hospital, Peking University Fourth School of Clinical Medicine, Beijing 100035, China  
E-Mail: [tianwei\\_frsc\\_jst@163.com](mailto:tianwei_frsc_jst@163.com)

Copyright © 2021 The Chinese Medical Association, produced by Wolters Kluwer, Inc. under the CC-BY-NC-ND license. This is an open access article distributed under the terms of the Creative Commons Attribution-Non Commercial-No Derivatives License 4.0 (CCBY-NC-ND), where it is permissible to download and share the work provided it is properly cited. The work cannot be changed in any way or used commercially without permission from the journal.

Chinese Medical Journal 2021;134(11)

Received: 28-08-2020 Edited by: Ning-Ning Wang



**Figure 1:** Midsagittal (A) and axial (B) CT images showed the C1 SCD (red dashed line), dens sagittal diameter (black double arrow), the C1 SAC (white, solid double arrow), and the C2 SAC (white, dashed double arrow). (C) Histogram plot of C1 SCD measurements with a normal distribution curve. C1 hypoplasia was defined as the lowest 2.5% (C1 SCD  $\leq 26.07$  mm). CT: Computed tomography; SAC: Space available for the cord; SCD: Sagittal canal diameter.

The normal distribution of C1 SCD measurements was verified ( $P = 0.059$ ). Given that the 95% confidence interval of C1 SCD measurements was 26.07 to 33.85 mm, C1 hypoplasia was defined as an SCD of  $\leq 26.07$  mm [Figure 1C]. Among all parameters, C1 SAC showed a significant difference between patients with and without C1 hypoplasia ( $14.50 \pm 0.88$  mm *vs.*  $18.16 \pm 1.40$  mm,  $P < 0.001$ ), and inter-group differences in C1 SAC were found according to sex ( $P < 0.05$ ) [Supplemental Table 3, <http://links.lww.com/CM9/A538>]. A significant difference was also noted in the dens/canal ratio ( $36.5\%$  *vs.*  $41.4\%$ ,  $P < 0.001$ ).

We undertook this CT-based study to establish normative values for C1 SCD. To our knowledge, few studies have reported similar data in Chinese populations. An SCD threshold for C1 hypoplasia can be defined as the lowest 2.5% of normative values. It was first proposed by Musha and Mizutani,<sup>[5]</sup> who defined C1 hypoplasia by measuring the C1 SCD of 300 Japanese adults based on plain radiographs. However, radiographic measurements were unreliable due to radiographic magnification.<sup>[1]</sup> Subsequently, Kelly *et al*<sup>[2]</sup> defined C1 hypoplasia via a cadaveric study of 543 Caucasian and African American skeletons. The threshold was 26.1 mm, close to that in our study (26.07 mm). In the C1 hypoplasia group, the dens sagittal diameter remained relatively normal; thus, C1 SAC markedly decreased [Supplemental Table 3, <http://links.lww.com/CM9/A538>]. Cord compression occurred in those with a C1 SAC  $< 12$  mm.<sup>[1]</sup> If we consider other structural diameters at the C1 level, such as the atlantodental interval ( $< 3$  mm), dens thickness (10–11 mm), and transverse ligament thickness (2 mm), an asymptomatic individual should have a C1 SCD of approximately  $\geq 26$  mm.<sup>[2]</sup> According to Steel's rule of thirds, the dens, spinal cord, and remaining space occupy one-third of the C1 SCD each; however, individuals with C1 hypoplasia may have a dens occupying  $> 40\%$  of the C1 SCD, thus deviating from Steel's rule.<sup>[2]</sup> Our study confirms these observations. The dens/canal ratio showed a marked increase from 36.5% to 41.4%. Although individuals without C1 hypoplasia can develop myelopathy due to atlantoaxial instability while those with C1

hypoplasia may remain asymptomatic, clinicians still need a threshold for reference. A threshold based on normative estimates for an asymptomatic population is important as a measure for detecting disease.

Our study has several limitations. First, magnetic resonance imaging may be more suitable for evaluating patients with spinal cord compression. However, recruiting healthy asymptomatic volunteers was difficult. Second, we did not conduct long-term follow-up to evaluate the frequency of cervical spondylotic myelopathy and spinal cord injury in patients with C1 hypoplasia. Additionally, we were unable to recruit enough symptomatic C1 stenosis patients to validate the threshold for C1 hypoplasia. Further studies are needed to confirm our results to foster the development of a diagnostic test.

### Acknowledgement

The authors thank Dr. Yi-Xi Yu for providing the photos and technical support.

### References

- Lee MJ, Cassinelli EH, Riew KD. Prevalence of cervical spine stenosis: anatomic study in cadavers. *J Bone Joint Surg Am* 2007;89:376–380. doi: 10.2106/JBJS.F.00437.
- Kelly MP, Oshima Y, Yeom JS, Agarwal R, Bajwa NS, Riew KD. Defining hypoplasia of the atlas: a cadaveric study. *Spine* 2014;39:E1243–E1247. doi: 10.1097/BRS.0000000000000516.
- Phan N, Marras C, Midha R, Rowed D. Cervical myelopathy caused by hypoplasia of the atlas: two case reports and review of the literature. *Neurosurgery* 1998;43:629–633. doi: 10.1097/00006123-199809000-00140.
- Hsu YH, Huang WC, Liou KD, Shih YH, Lee LS, Cheng H. Cervical spinal stenosis and myelopathy due to atlas hypoplasia. *J Chin Med Assoc* 2007;70:339–344. doi: 10.1016/S1726-4901(08)70015-7.
- Musha Y, Mizutani K. Cervical myelopathy accompanied with hypoplasia of the posterior arch of the atlas: case report. *J Spinal Disord Tech* 2009;22:228–232. doi: 10.1097/BSD.0b013e3181778181.

**How to cite this article:** Wang Y, An Y, Tian W, Ma YM. Chinese normative values of C1 sagittal canal diameter and definition of C1 hypoplasia. *Chin Med J* 2021;134:1362–1363. doi: 10.1097/CM9.0000000000001497