



Off-label intravitreal brolocizumab for recalcitrant diabetic macular edema: A real-world case series

Debdulal Chakraborty^{a,*}, Jay U. Sheth^b, Subhendu Boral^a, Tushar K. Sinha^a

^a Department of Vitreoretinal Services, Disha Eye Hospitals, Kolkata, India

^b Department of Vitreoretinal Services, Surya Eye Institute and Research Center, Mumbai, India

ARTICLE INFO

Keywords:

Brolucizumab
Diabetic macular edema
Anti-vascular endothelial growth factor

ABSTRACT

Purpose: To report the efficacy of intravitreal injection (IVI) of brolocizumab for recalcitrant diabetic macular edema (DME) in a real-world setting.

Observations: This was a single-center, prospective uncontrolled non-randomized case series. Three eyes with recalcitrant DME, who have received a minimum of ten intravitreal anti-vascular endothelial growth factor (anti-VEGF) injections, underwent IVI brolocizumab and were followed-up for minimum of 16 weeks. Patients underwent best-corrected visual acuity (BCVA) testing, ophthalmic examination, and optical coherence tomography at baseline and all the scheduled follow-up visits (Weeks 4, 8, 12, and 16). All three patients demonstrated notable improvement in BCVA and reduction in the fluid on SD-OCT lasting up to week 12. At week 16, all three eyes maintained the visual acuity gains. However, early increase in fluid was noted in all the three cases, for which second dose of IVI brolocizumab was planned. No ocular or systemic adverse events were noted in any of the cases.

Conclusions and Importance: In this real-world case series, treatment with IVI brolocizumab exhibited excellent visual acuity outcomes lasting up to 16 weeks for the treatment of recalcitrant DME. Single dose IVI brolocizumab achieves good anatomical improvement based on SD-OCT persisting up to 12 weeks, followed by early recurrence of fluid at week 16. The results did not show any ocular or systemic safety concerns for IVI brolocizumab.

1. Introduction

Intravitreal anti-vascular endothelial growth factor (anti-VEGF) injections remain the gold standard for management of chorioretinal vascular diseases, including age-related macular degeneration (AMD), diabetic macular edema (DME), and retinal vein occlusion (RVO).¹ Four anti-VEGF molecules have been approved by the US Food and Drug Administration (FDA) for intraocular use, including pegaptanib sodium (Macugen®, Eyetech/OSI Pharmaceuticals, New York, NY, USA), ranibizumab (Lucentis®; Genentech, S. San Francisco, CA/Roche, Basel, Switzerland), aflibercept (Eylea®, Regeneron, Tarrytown, NY), and brolocizumab (Beovu®; Novartis, Basel, Switzerland).^{2–4} Of these agents, Brolocizumab is the latest to receive approval in 2019 for the treatment of neovascular age-related macular degeneration (nAMD). In India, the drug was recently launched in October 2020 as Pagenax® (Novartis India Ltd, Mumbai, India).

The 96-week results from the phase 3 clinical trials, HAWK and HARRIER, have demonstrated the non-inferiority of brolocizumab to aflibercept in visual outcomes while achieving superior anatomical outcomes with quarterly (q12-week) dosing in the management of nAMD.⁵ Likewise, two phase 3 clinical trials, KESTREL and KITE, are underway at 200 sites in 36 countries to evaluate the non-inferiority of Brolocizumab 6 mg to Aflibercept 2 mg in terms of functional and morphological improvement for management of DME over 2 years.⁶ The interim results of these trials have shown encouraging visual acuity and anatomical outcomes at the end of one year.^{7,8}

Here we describe the safety and efficacy of IVI brolocizumab in four eyes with recalcitrant DME over 16 weeks in a real-world scenario. It was a prospective uncontrolled non-randomized case series of three eyes of three patients with recalcitrant DME, having undergone a minimum of 10 intravitreal injections (IVI) of anti-VEGF, who were switched to IVI brolocizumab. Recalcitrant DME was defined as central macular

* Corresponding author.

E-mail addresses: devdc@rediffmail.com (D. Chakraborty), drjay009@gmail.com (J.U. Sheth), drsubhendu@yahoo.co.uk (S. Boral), drtusharsinha@gmail.com (T.K. Sinha).

<https://doi.org/10.1016/j.ajoc.2021.101197>

Received 11 April 2021; Received in revised form 16 June 2021; Accepted 30 August 2021

Available online 1 September 2021

2451-9936/© 2021 The Authors.

Published by Elsevier Inc.

This is an open access article under the CC BY-NC-ND license

(<http://creativecommons.org/licenses/by-nc-nd/4.0/>).

thickness (CMT) of $>350\mu\text{m}$, with $\leq 15\%$ change in CMT over the past 6 months despite receiving at least 3 IVI anti-VEGF.^{9,10} All patients receiving focal laser within the past six months were excluded. The study was conducted in accordance with the tenets of the Declaration of Helsinki and was approved by the Institutional Review Board and the Ethical Committee of Disha Eye Hospitals in Kolkata, India. Written informed consent was obtained from each patient. Treatment with all available anti-VEGF drugs was offered and eligible patients freely chose to receive IVI brolucizumab (6 mg in 0.05 mL). All injections were performed in an operating theater under sterile technique. Povidone-iodine 5% was applied to eyes both immediately before and after each injection, pre-operative antibiotic eye drops were not given, but topical moxifloxacin 0.5% was administered post-operatively for one week. The patients were followed-up on the second day after injection, and at weeks 4, 8, 12, and 16, respectively. At all visits, a detailed history was taken by the treating physician regarding the occurrence of any ocular and systemic adverse event. Additionally, at each follow-up visit, the patients underwent a detailed clinical examination by a retina specialist (DC) including best-corrected visual acuity (BCVA) assessment using the Snellen's visual acuity chart, intraocular pressure (IOP) measurement by Goldmann applanation tonometer, anterior segment evaluation using slit-lamp biomicroscopy and fundus examination with both slit-lamp biomicroscopy (+90D lens) and indirect ophthalmoscopy (+20D lens). Spectral-domain optical coherence tomography (SD-OCT) was performed at all visits from week 4 to week 16. Repeat IVI Brolucizumab was offered based on pro-re-nata [PRN] regimen.

2. Findings

2.1. Case 1

A 56-year-old female with a history of non-insulin dependent diabetes mellitus (NIDDM) since 18 years, had both eyes (OU) moderate non-proliferative diabetic retinopathy (NPDR) with recalcitrant DME in the right eye (OD). Her serum HbA1c levels were 6.8 mg/dl. She had undergone 25 intravitreal anti-VEGF injections (20 IVI Ranibizumab, 3 IVI Bevacizumab, 2 IVI Aflibercept) and one dose of intravitreal triamcinolone (IVTA) over 8 years. Raised intraocular pressure (IOP) was noted after the IVTA injection, which was controlled with topical anti-glaucoma medications (AGM). Her last injection (IV Aflibercept) was given in August 2020 with minimal response. Her BCVA was 20/60 with a CMT of $621\mu\text{m}$ on SD-OCT (Fig. 1a). In October 2020, she received IVI Brolucizumab. Subsequently, her BCVA improved to 20/40 at week 4, and 20/25 at weeks 8, 12, and 16, respectively. The SD-OCT showed significant reduction in the intraretinal fluid (IRF) till week 12 (Fig. 1b-d). However, at 16 weeks, although the BCVA was maintained at 20/25, there was an increase in the IRF (Fig. 1e) for which the patient received second dose of IVI Brolucizumab. The intraocular pressure (IOP) was normal at all visits with absence of any side adverse reaction.

2.2. Case 2

A 37-year-old male had insulin-dependent diabetes mellitus (IDDM) for 12 years and was on insulin therapy for the same. He had moderate NPDR in OU with OS DME for which he received 11 IVI Ranibizumab over 6 years, with last injection given in August 2020. His serum HbA1c levels were 6.7 mg/dl. There was minimal response to the eleventh dose of IVI Ranibizumab, with his BCVA being 20/40 and CMT $645\mu\text{m}$ on SD-OCT (Fig. 2a). The SD-OCT showed presence of both sub-retinal fluid (SRF) and IRF (Fig. 2a). The patient was promptly shifted to IVI Brolucizumab in October 2020. Consecutively, his BCVA improved and was maintained at 20/25 over 16 weeks. Simultaneously, we noted complete resolution of SRF and significant reduction in IRF at all the visit through 12 weeks with a notable reduction in the CMT (Fig. 2b-e). Early recurrence of IRF was seen at week 16 for which the patient is scheduled for

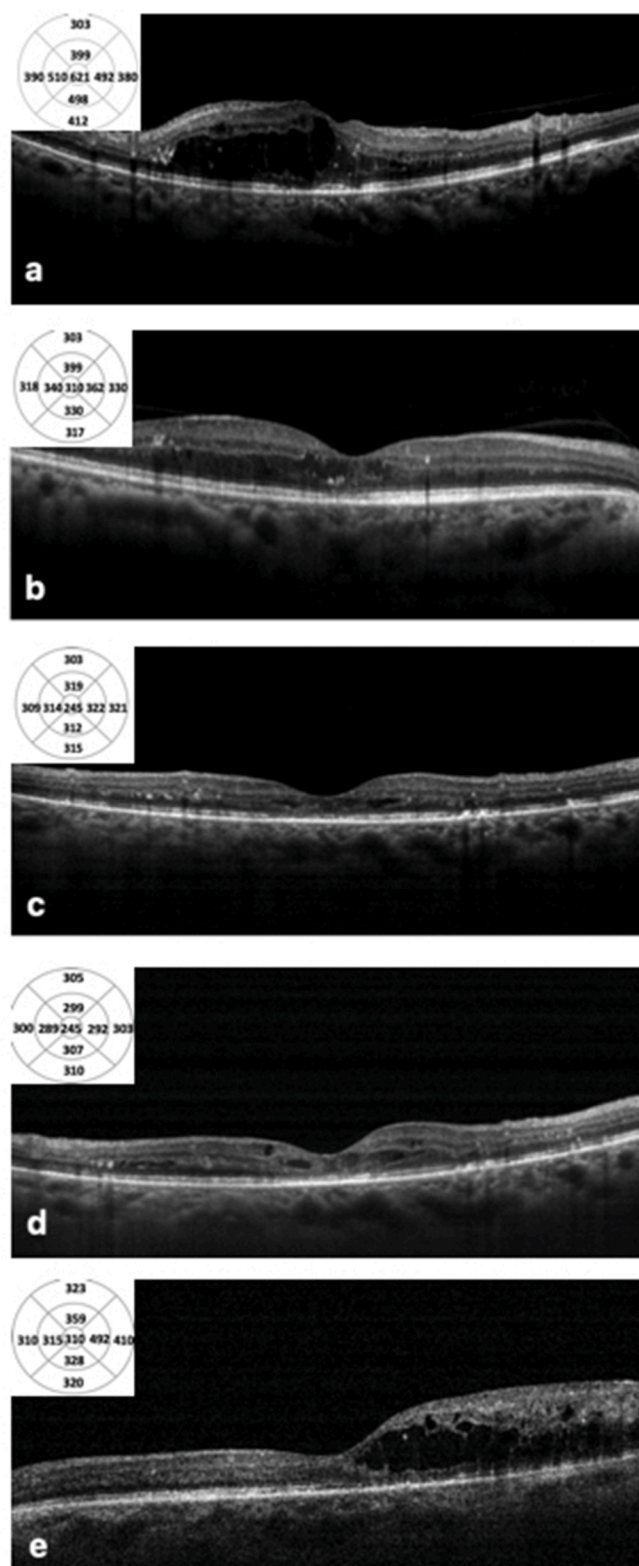


Fig. 1. Case 1 - a. Spectral domain optical coherence tomography (SD-OCT) image at baseline showing significant intraretinal fluid (IRF). After undergoing intravitreal injection (IVI) Brolucizumab treatment, the patient demonstrated considerable reduction in IRF and central macular thickness (CMT) on SD-OCT at week 4 (b), week 8 (c) and week 12 (d). However, at week 16 post IVI Brolucizumab (e), there was a recurrence of IRF on SD-OCT.

second dose of IVI Brolucizumab. No safety concerns were observed with the brolucizumab injection at all visits.

2.3. Case 3

A 49-year-old male was a case of OU severe NPDR with OD recalcitrant DME. He had non-insulin dependent diabetes mellitus (NIDDM) for 15 years which was well-controlled by oral hypoglycaemic agents (OHA), with the serum HbA1c levels maintained at 6.6 mg/dl. For the OD/OS DME, the patient received 13 IVI Ranibizumab and 2 IVI dexamethasone implant (Ozurdex) during 7 years of follow-up. The patient developed raised IOP after second dose of ozurdex which was successfully managed with topical AGM. There was minimal response noted on SD-OCT and BCVA after the 13th dose of IVI ranibizumab given in July

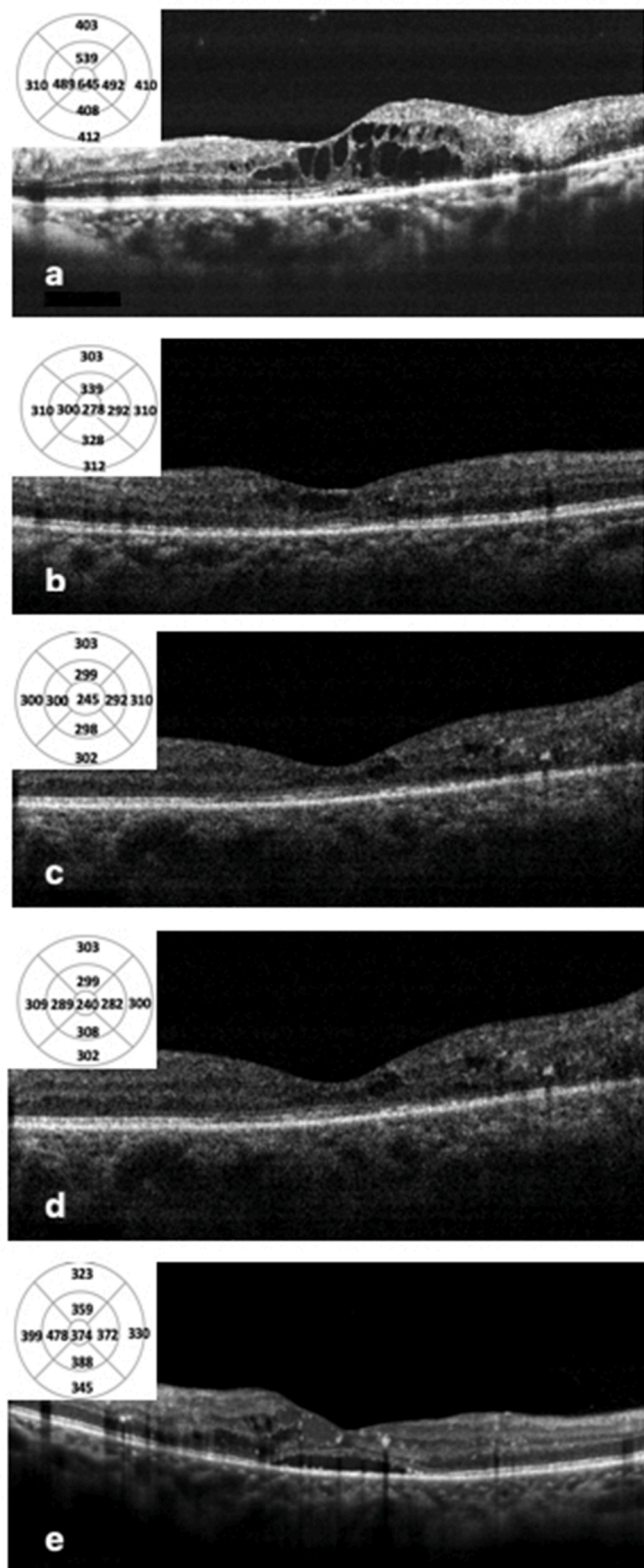


Fig. 2. Case 2 - a. Spectral domain optical coherence tomography (SD-OCT) image at baseline showing significant intraretinal fluid (IRF) with subretinal fluid (SRF). After undergoing intravitreal injection (IVI) Brolucizumab treatment, there was complete resolution of SRF with notable reduction in IRF on SD-OCT at week 4 (b), week 8 (c) and week 12 (d). At week 16, the SD-OCT showed early recurrence of SRF with minimal increase in IRF (e).

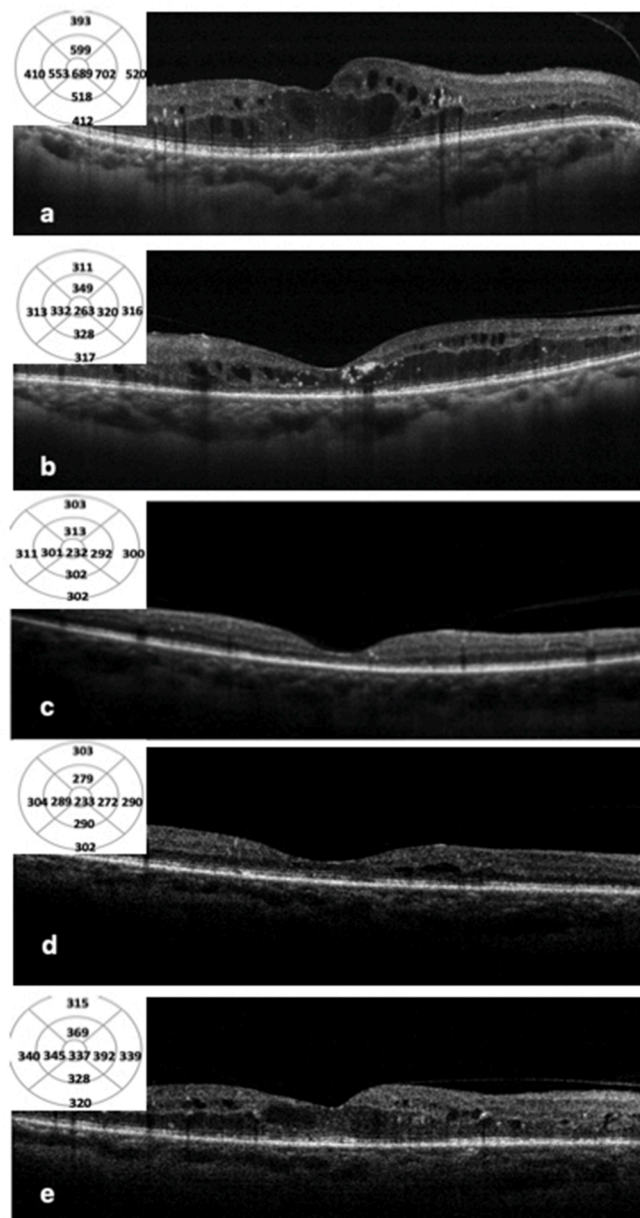


Fig. 3. Case 3 - a. Spectral domain optical coherence tomography (SD-OCT) image at baseline showing significant intraretinal fluid (IRF). The patient had considerable reduction in IRF and central macular thickness (CMT) on SD-OCT at week 4 (b), week 8 (c) and week 12 (d) post-intravitreal injection (IVI) Brolucizumab. Early increase in IRF and CMT was noted on SD-OCT (e) at 16 weeks post IVI Brolucizumab.

2020 (Fig. 3a). The patient responded considerably after switching to IVI Brolucizumab, with the BCVA improving from 20/40 to 20/25 at all the subsequent visits through week 16. On SD-OCT, the SRF resolved completely through weeks 12, only to recur at week 16 (Fig. 3b-e). Simultaneously, the IRF too showed considerable response to IVI brolucizumab till week 16 (Fig. 3b-e). The patient did not have any ocular or systemic adverse events. He is scheduled for the second dose of IVI Brolucizumab.

3. Discussion

In our real-world case series, we demonstrate that IVI brolucizumab is efficacious in improving and maintaining the visual acuity through week 16 for recalcitrant DME. Excellent anatomical response was noted on SD-OCT lasting up to 12 weeks with a single dose of brolucizumab in all three cases. However, early recurrence of fluid was seen at week 16 in all the three eyes for which the second dose of injection was planned. We did not note any ocular or systemic adverse events in our series.

DME is one of the leading causes of visual impairment and blindness throughout the world.¹¹ Over the past 16 years, the management of DME has been revolutionized by widespread adoption of IVI of anti-VEGF agents.¹² However, despite aggressive treatment with these anti-VEGF agents, a subset of DME patients continue to exhibit suboptimal visual and anatomical response.¹³ Such non-responders having recalcitrant DME may benefit by switching to an alternative anti-VEGF agent or corticosteroids.¹³ Akincioğlu D et al. have shown the dexamethasone implant to be efficacious for 4 months in recalcitrant DME.¹⁴ However, 50% of the eyes had cataract progression and 28% of the eyes had elevated IOP in their study.¹⁴ Hence, they concluded that although steroids are effective, it is hard to displace anti-VEGF agents as first-line therapy for recalcitrant DME due to the steroid-related complications.¹⁴ Kline et al. have demonstrated more than 25% reduction in central retinal thickness in 81% eyes and visual acuity improvement in 63% eyes with recalcitrant DME after switching to IVI aflibercept.¹³ Similarly, Rahimy et al. have shown that after switching to aflibercept for persistent DME, there was significant anatomical improvement with a trend towards improvement in visual acuity.¹⁵ The efficacy of aflibercept after switching from other anti-VEGF agent could be due to the different molecular targets (Aflibercept binds to VEGF-A, VEGF-B and placental growth factor [PlGF] while Ranibizumab binds to only VEGF-A) or presence of autoantibodies to the prior anti-VEGF agent.⁹ The newer anti-VEGF agent brolucizumab is yet to be evaluated for non-responsive cases of DME, but data from the literature has supported its role as an effective anti-VEGF agent for poorly responsive nAMD agents.^{16,17} A possible reason for this could be related to the autoantibodies developed to the prior anti-VEGF agent, its higher molar dose, and/or causing inhibition of both VEGFR1 and VEGFR2 (Ranibizumab causes inhibition of only VEGFR2).^{16,17} Based on these factors and its evolving role as an effective agent for switching anti-VEGF therapy in non-responsive nAMD, we utilized and performed an initial analysis of the role of IVI Brolucizumab in recalcitrant DME.

Brolucizumab is a humanized single chain antibody fragment weighing just 26kDa.¹⁸ Due to its smaller size, it binds to VEGF-A in 2:1 ratio initially, which may reduce to 1:1 with decreased concentration of the drug.¹⁸ However, even at 1:1 ratio, a complete blockage of VEGF-A is maintained by brolucizumab.¹⁸ Additionally, with a low molecular weight of brolucizumab, that is 4 times lower than aflibercept and 1.8 times lower than ranibizumab, it is possible to deliver a 12-fold higher molar dose as compared to aflibercept and 22-fold higher molar dose as compared with ranibizumab.^{18,19} With these molecular characteristics, brolucizumab has been shown to have longer durability in the initial trials on nAMD. The first trial in humans, SEE study, the median time for repeat injection was 30 days longer with 3mg and 6mg of brolucizumab as compared to ranibizumab.²⁰ In the phase II OSPREY trial, approximately 50% of eyes treated with brolucizumab maintained stable visual acuity with q12w dosing schedule.²¹ Likewise, in the phase 3 HAWK and

HARRIER trials, around 50% of patients were maintained on q12w dosing up to 48 weeks.¹⁹ Of these eyes, around 75% continued successfully on q12w injection interval up to 96 weeks.⁵ Although a 12-weekly regimen of IVI brolucizumab would have been ideal in our series, the patients were offered PRN regimen considering their socio-economic profile and affordability.

Based on the promising results of the phase 3 trials evaluating IVI brolucizumab in the treatment of nAMD,¹⁹ prospective phase 3 studies (KITE and KESTREL) are underway to assess its role in the management of DME.⁶ The interim results of KITE and KESTREL study released in the end of 2020 confirmed non-inferiority of brolucizumab to aflibercept in mean change in visual acuity at one year.^{7,8} Moreover, patients in KESTREL study showed significant improvement in central subfield thickness (CST) from baseline over the period of week 40 through 52 with brolucizumab, while in the KITE study, it demonstrated superior improvement in CST over aflibercept from week 40 through week 52.^{7,8} Both studies did not reveal any additional safety concerns with brolucizumab over aflibercept.^{7,8} Our results in all three cases are consistent with these trials. All three cases demonstrated encouraging visual acuity improvement that was maintained up to 16 weeks after a single dose of IVI brolucizumab. In addition, reduction in the CMT and fluid was observed in all the three cases which was consistent over 12 weeks. Although early recurrence was noted in all cases at week 16, the lack of concurrent drop in visual acuity was noteworthy. The significant anatomical and tomographic response of these recalcitrant DME eyes to a single dose of IVI brolucizumab could be multitudinal: distinct pharmacokinetics and pharmacodynamics of the brolucizumab molecule and tachyphylaxis to the previous molecule due to neutralizing antibodies, altered surface receptor expression, macrophage mediated up-regulation of VEGF and/or altered pharmacokinetics.^{9,15} Further molecular and immunological studies are warranted to rationalize the mechanism of action and validate the encouraging therapeutic response seen after switching to IVI brolucizumab in recalcitrant DME.

IVI brolucizumab has been associated with intraocular inflammation (IOI). The incidence of IOI in the HAWK and HARRIER studies was 4% for brolucizumab as compare to 1% for aflibercept.⁵ The American Society of Retinal Specialists (ASRS) had issued an alert in February 2020 after 14 cases of retinal vasculitis, of which 11 were occlusive vasculitis, were reported after use of IVI brolucizumab.²² The incidence of Retinal vasculitis +/-retinal vascular occlusion in the post-marketing surveillance was 15.31 per 10,000 injections (till February 12, 2021).²³ However, in our series, we did not any incident of anterior or posterior segment inflammation during the 16 weeks follow-up period. Additionally, no patients reported any systemic adverse event. However, our series is too small with a short follow-up of 16 weeks. Hence, it is insufficiently powered to determine the risks of systemic adverse events.

The major limitations of this study include the relatively small number of cases and brief follow-up period. Moreover, the molecule was evaluated in eyes with recalcitrant DME. Hence, based on our results it is not feasible to decipher regarding its role in treatment-naïve DME. Further studies with large sample size and long-term follow-up are needed to better understand the safety and efficacy of brolucizumab in treatment-naïve and recalcitrant DME.

4. Conclusion

In our real-world case series, we noted an improvement in visual acuity without any safety concerns amongst all three eyes up to 16 weeks. The concurrent anatomical improvement persists up to 12 weeks after a single dose, with early recurrence of fluid noted at 16 weeks. The long-term results of the phase 3 trials, KITE and KESTREL,⁶ will provide us with a better insight into the role of brolucizumab in the treatment of DME.

Patient consent

Written informed consent was obtained from patients for publication of these case reports and any accompanying images.

Funding

No funding or grant support

Authorship

All authors attest that they meet the current ICMJE criteria for Authorship.

Funding

No funding was received by any of the authors for this study.

Declaration of competing interest

The following authors have no financial disclosures: DC, JS, SB, TS.

Acknowledgements

None.

References

- Yorston D. Anti-VEGF drugs in the prevention of blindness. *Community Eye Health*. 2014;27(87):44–46.
- Li E, Donati S, Lindsley KB, Krzystolik MG, Virgili G. Treatment regimens for administration of anti-vascular endothelial growth factor agents for neovascular age-related macular degeneration. *Cochrane Database Syst Rev*. 2020;5(5). <https://doi.org/10.1002/14651858.CD012208.pub2>. CD012208. Published 2020 May 5.
- Campa C, Alivernini G, Bolletta E, Parodi MB, Perri P. Anti-VEGF therapy for retinal vein occlusions. *Curr Drug Targets*. 2016;17(3):328–336.
- Mansour SE, Browning DJ, Wong K, Flynn Jr HW, Bhavsar AR. The evolving treatment of diabetic retinopathy. *Clin Ophthalmol*. 2020;14:653–678.
- Dugel PU, Singh RP, Koh A, et al. HAWK and HARRIER: ninety-six-week outcomes from the phase 3 trials of brolucizumab for neovascular age-related macular degeneration. *Ophthalmology*. 2021;128(1):89–99.
- Garweg JG. A randomized, double-masked, multicenter, phase III study assessing the efficacy and safety of brolucizumab versus aflibercept in patients with visual impairment due to diabetic macular edema (KITE). *Klin Monbl Augenheilkd*. 2020; 237(4):450–453.
- Beovu meets endpoints in phase 3 DME study. Accessed on 03/13/2021. Available at: <https://www.healio.com/news/ophthalmology/20200914/beovu-meets-endpoints-in-phase-3-dme-study>.
- Second phase 3 study shows good results for Beovu in DME treatment. Accessed on 03/13/2021. Available at: <https://www.healio.com/news/ophthalmology/20201215/second-phase-3-study-shows-good-results-for-beovu-in-dme-treatment>.
- McCloskey CF, Mongan AM, Chetty S, McAteer DMJ, Quinn SM. Aflibercept in diabetic macular oedema previously refractory to standard intravitreal therapy: an Irish retrospective study. *Ophthalmol Ther*. 2018 Jun;7(1):173–183.
- Laiginhas R, Silva MI, Rosas V, et al. Aflibercept in diabetic macular edema refractory to previous bevacizumab: outcomes and predictors of success. *Graefes Arch Clin Exp Ophthalmol*. 2018 Jan;256(1):83–89.
- Prokofyeva E, Zrenner E. Epidemiology of major eye diseases leading to blindness in Europe: a literature review. *Ophthalmic Res*. 2012;47(4):171–188.
- Yorston D. Anti-VEGF drugs in the prevention of blindness. *Community Eye Health*. 2014;27(87):44–46.
- Klein KA, Cleary TS, Reichel E. Effect of intravitreal aflibercept on recalcitrant diabetic macular edema. *Int J Retina Vitreous*. 2017;3:16.
- Akincioglu D, Küçükcilioğlu M, Durukan AH, Aykaş S, Ayyıldız Ö, Erdurman FC. Outcomes of intravitreal dexamethasone implant in the treatment of recalcitrant diabetic macular edema. *Turk J Ophthalmol*. 2017;47(5):274–278.
- Rahimy E, Shahlake A, Khan MA, et al. Conversion to aflibercept after prior anti-VEGF therapy for persistent diabetic macular edema. *Am J Ophthalmol*. 2016;164, 118–27.e2.
- Bulirsch LM, Saßmannshausen M, Nadal J, Liegl R, Thiele S, Holz FG. Short-term real-world outcomes following intravitreal brolucizumab for neovascular AMD: SHIFT study. *Br J Ophthalmol*. 2021 Apr 12 <https://doi.org/10.1136/bjophthalmol-2020-318672>. <https://doi.org/10.1136/bjophthalmol-2020-318672>. Epub ahead of print. PMID: 33846161.
- Avaylon J, Lee S, Gallemore RP. Case series on initial responses to intravitreal brolucizumab in patients with recalcitrant chronic wet age-related macular degeneration. *Int Med Case Rep J*. 2020 May 11;13:145–152.
- Tadayoni R, Sararols L, Weissgerber G, Verma R, Clemens A, Holz FG. Brolucizumab: a newly developed anti-VEGF molecule for the treatment of neovascular age-related macular degeneration. *Ophthalmologica*. 2021;244(2):93–101. <https://doi.org/10.1159/000513048>. Epub 2020 Nov 16. PMID: 33197916.
- Dugel PU, Koh A, Ogura Y, et al. HAWK and HARRIER Study Investigators. HAWK and HARRIER: phase 3, multicenter, randomized, double-masked trials of brolucizumab for neovascular age-related macular degeneration. *Ophthalmology*. 2020 Jan;127(1):72–84.
- Holz FG, Dugel PU, Weissgerber G, et al. Single-chain antibody fragment VEGF inhibitor RTH258 for neovascular age-related macular degeneration: a randomized controlled study. *Ophthalmology*. 2016;123(5):1080–1089.
- Dugel PU, Jaffe GJ, Sallstig P, et al. Brolucizumab versus aflibercept in participants with neovascular age-related macular degeneration: a randomized trial. *Ophthalmology*. 2017;124(9):1296–1304.
- Sharma A, Kumar N, Parachuri N, et al. Brolucizumab and immunogenicity. *Eye*. 2020 Oct;34(10):1726–1728.
- Post-marketing data. Accessed on 03/13/2021. Available at: <https://www.brolucizumab.info/post-marketing-data>.