



OPEN ACCESS

# Appendicular tuberculosis: a less encountered clinical entity

Sachin Ambekar,<sup>1</sup> Mohit Bhatia <sup>2</sup>

<sup>1</sup>General & Laparoscopic Surgery, Moolchand Medcity South Delhi, New Delhi, India  
<sup>2</sup>General Surgery, PRUH, Kings College & Hospital Trust, London, UK

## Correspondence to

Dr Mohit Bhatia;  
 drbhatia711@gmail.com

Accepted 20 January 2021

## SUMMARY

A 21-year-old female patient presented with vague lower abdominal pain associated with nausea since 2 days. On examination, she was tender in the right iliac fossa. Based on clinical presentation and radiological test finding, she was diagnosed as appendicitis and was subjected for diagnostic laparoscopy and appendectomy. Histopathology proved it to be a tubercular appendix, which is a rarely encountered entity. However, in a country like India, tuberculosis (TB) is highly prevalent; however, TB of appendix is rare and less known.

## BACKGROUND

In developing countries, tuberculosis (TB) has been one of the notorious diseases since ages. It has been associated with high morbidity and mortality.<sup>1</sup> Gastrointestinal TB accounts for 3% of extrapulmonary TB, the most common site of involvement being the ileocaecal region. Appendix lies in close proximity to the ileocaecal region; despite this, incidence of TB of appendix is rarely reported.<sup>2</sup>

There are no pathognomic signs and symptoms to prompt preoperative diagnosis of tubercular appendicitis. Diagnosis is usually made after histology reports of the appendix specimen.

Incidence of appendicular TB in all appendectomies has been reported varying from 0.1% to 3%.<sup>3</sup>

However, some studies in the past have reported involvement of appendix in intestinal TB ranging between 46% and 70%.<sup>4</sup> It is believed, due to the hematogenous spread from the affected intestines, closely lying appendix gets affected. Some authors have postulated the spread to be due to peritoneal spread or from the affected genitourinary system.<sup>5</sup> The most common affected site is the ileocaecal region. Appendicular TB can be either primary or secondary, the latter form being common in which there is an infection spread from already existing infection within the abdomen.<sup>2</sup>

## CASE PRESENTATION

A fit 21-year-old female patient presented with abdominal pain since 2 days, severe in intensity more localised in the right lower abdomen. She mentioned similar nature of pain since 7 months; however, it was mild in nature and never 'concerned' her much. She also complained of nausea. She had regular bowel habits. There was no change to her appetite or weight.

Her medical history was not significant with non-significant family history.

Her menstrual history was normal.

On examination, her blood pressure was 134/88 mmHg, heart rate was 90/m, and she was fully alert and oriented.

With due consent, she was examined. Her abdomen was tender in the right iliac fossa with rebound tenderness. There was no palpable lump. There was no guarding/rigidity. General examination was unremarkable.

## INVESTIGATIONS

Blood tests revealed white cell count of 16 (normal range 3.6–11.0×10<sup>9</sup>/L) and C- Reactive protein (CRP) of 84 (normal range <5 mg/L). The rest of the blood investigations were normal.

Based on her clinical findings and laboratory values, she underwent CT scan of abdomen/pelvis which showed inflamed and thickened appendix with inflammatory mass around (figure 1).

Based on the clinical presentation and CT findings, diagnosis of appendicitis was confirmed and the patient was consented for diagnostic laparoscopy and proceed with appendectomy.

## DIFFERENTIAL DIAGNOSIS

After the discussion with the radiology department, and considering the clinical presentation, the final diagnosis of appendicitis was confirmed. However, owing to the chronic nature of her symptoms and also due to suspected mass around the appendix, provisional or other probable diagnosis was considered to be an infective pathology. However, the primary diagnosis was kept as appendicitis and the patient was planned to have a diagnostic laparoscopy and proceed as planned.

## TREATMENT

After the due informed consent, the patient was subjected to diagnostic laparoscopy with conventional three ports placement. Intraoperative

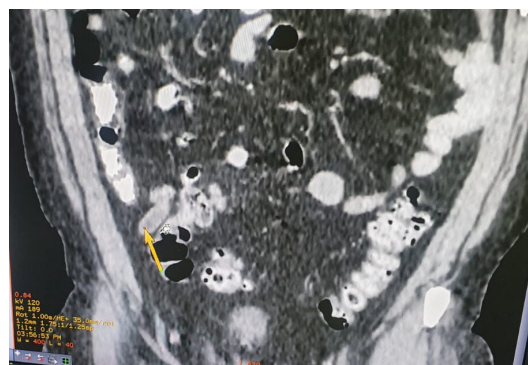
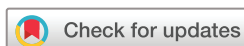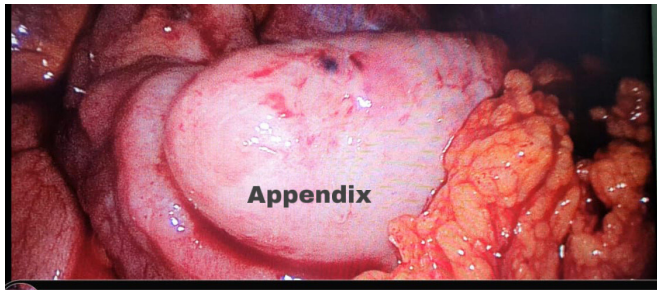


Figure 1 CT image showing a thickened appendix.



© BMJ Publishing Group Limited 2021. Re-use permitted under CC BY-NC. No commercial re-use. See rights and permissions. Published by BMJ.

**To cite:** Ambekar S, Bhatia M. *BMJ Case Rep* 2021;**14**:e237718. doi:10.1136/bcr-2020-237718



**Figure 2** Intraoperative finding of oedematous, thickened appendix after being released from adhesions.

findings were an inflamed and thickened appendix with omental adhesions around forming a mass. Appendix was released from adhesions and a clear view was seen (figure 2). Conventional laparoscopic appendectomy was done, its base was healthy and was secured with two endoloops. There was no intraoperative contamination and the appendix was removed in-toto in a bag. The rest of the bowel and pelvis was grossly normal. The patient received pre-post operative antibiotics (metronidazole 500 mg intravenous three times a day, amoxicillin 1 g) for 3 days with good analgesia and supportive care. The appendix specimen was sent for histopathology.

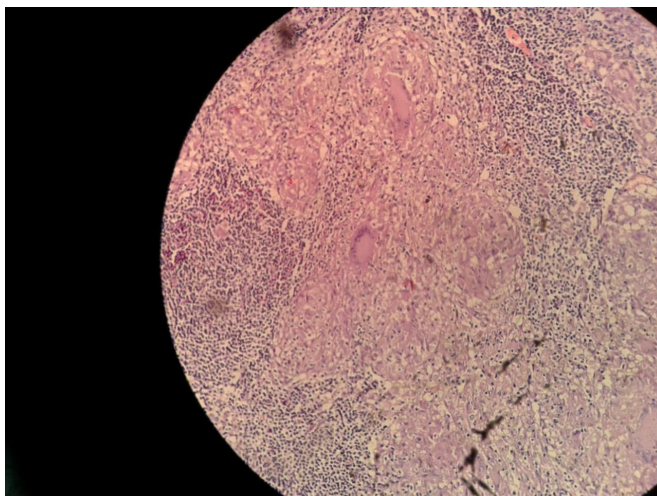
#### OUTCOME AND FOLLOW-UP

The patient recovered well in postoperative period, she was started on oral feeds same day after the surgery and she tolerated it well. On postoperative day 3, she was discharged from hospital after being satisfactorily recovered.

She was seen in follow-up after 7 days, her clinical condition was well and skin clips were taken out.

However, histopathology of the appendix specimen had shown caseating epithelioid granulomas and lumen filled with neutrophilic infiltrates suggestive of tubercular appendix (figure 3). Chest X-ray and colonoscopy were done in postoperative period and both were normal.

The patient was started on conventional antitubercular regime for 6 months and would be followed up appropriately.



**Figure 3** Histology slide showing the caseating granulomas with neutrophilic infiltrates suggestive of tuberculous.

#### DISCUSSION

Appendicular TB is a less known entity due to less incidence and is less reported in the literature. In 1873, Corbin had mentioned first about it.<sup>6</sup> In developing countries like India, gastrointestinal TB is common. However, primary appendicular TB is relatively rare, accounting for 0.1%–3% incidence of all appendectomies worldwide.<sup>3</sup>

Primary form includes the infection of the mucosa directly by *Mycobacterium tuberculosis*, secondary involves spread of infection from existing infective foci. The appendix is believed to be less affected due to minimal contact of its mucosa with intestinal contents. However, infection may spread via local extension from the ileocaecal region, genital TB, haematogenous spread from a distant foci.<sup>5</sup>

There are no distinctive clinical or radiological features to suggest tubercular appendix preoperatively therefore making its diagnosis after the histology reports or as a diagnosis of exclusion.

In the past, many authors have suggested co-relation of tuberculous salpingitis with appendicular TB.<sup>7</sup>

Appendicular TB is believed to be more commonly presenting as a chronic form with acute flare up of appendicitis secondary to TB. It most commonly presents with mild-moderate abdominal pain. Chronic form can present with some features suggestive, but many authors have believed these features have little reliability and may present some other existing systemic illnesses.<sup>8</sup>

Maharajan *et al* reported that signs and symptoms of patients with TB appendicitis were consistent with acute appendicitis, hence making the diagnosis unconfirmed until the histology reports.<sup>9</sup>

#### Patient's perspective

I have always been a healthy individual and I have never been to a hospital for any major illness till this pain started. I had believed it to be something minor issue, however when I was told I need surgery I was a bit skeptical. But after my surgery I was feeling well within myself and was confident with the care that I got. I was very happy to go home early after the surgery, but during my next visit when I was told about the histology results and confirmed diagnosis of tuberculosis, I got really scared and even my family was very upset. But my treating doctors educated me about the disease and re-assured me about the treatment plan further and guided me about the do's and don't's.

#### Learning points

- ▶ All right iliac fossa pain are not appendicitis; progression of symptoms and patients' clinical picture should prompt other differential diagnosis to be excluded.
- ▶ All possibilities should be considered and evaluated while treating an acute abdomen.
- ▶ Histology results should always be checked and recorded as there could be some rare presentations and should not be missed.
- ▶ Proper history, clinical examination, surgical acumen and using radiological investigations can help in deciding the surgical plan in an efficient way.

Histological confirmation of tubercular appendicitis is most of the times an incidental finding coming as a surprise to the surgeon and the patient. On histology, ulcerative type of appendicular appendicitis is the most common form. Other diseases like ulcerative colitis, sarcoidosis and parasitic diseases can also be associated with appendix showing granulomatous changes.<sup>10</sup>

Although appendicitis is a commonly encountered and managed disease by majority of the clinicians, findings like enlarged mesenteric nodes, ascites and pelvic fluid should prompt the treating clinician to consider other pathologies, and thus, abdomen has been rightly referred to as ‘Pandora’s box’.

**Contributors** I am (MB) the corresponding author of this case, and it has been approved by the other author involved (SA). Both authors have been involved in data collection, manuscript formation and editing of the manuscript. This case report is an original work and has not been published elsewhere. I am not related to the owner of the institution for using the code. I work with Kings’s College as a Clinical fellow, hence I have used the institution code since I have prepared this case while working here and currently I am working here too.

**Funding** The authors have not declared a specific grant for this research from any funding agency in the public, commercial or not-for-profit sectors.

**Competing interests** None declared.

**Patient consent for publication** Obtained.

**Provenance and peer review** Not commissioned; externally peer reviewed.

**Open access** This is an open access article distributed in accordance with the Creative Commons Attribution Non Commercial (CC BY-NC 4.0) license, which permits others to distribute, remix, adapt, build upon this work non-commercially, and license their derivative works on different terms, provided the original work is properly cited and the use is non-commercial. See: <http://creativecommons.org/licenses/by-nc/4.0/>.

#### ORCID iD

Mohit Bhatia <http://orcid.org/0000-0002-4179-878X>

#### REFERENCES

- 1 Jameson JL, Kasper D, Hauser S. Chapter 158. In: *Harrison principles of internal medicine*. New York: McGraw-Hill, 2008.
- 2 Singh MK, Kapoor VK, Arunabh. Tuberculosis of the appendix--a report of 17 cases and a suggested aetiopathological classification. *Postgrad Med J* 1987;63:855–7.
- 3 Nuwal P, Dixit R, Jain S. Isolated appendicular tuberculosis- a case report. *Ind J Tub* 2000;47:241–2.
- 4 Braastad FW, Dockerty MB, Waugh JM. Tuberculous appendicitis. *Surgery* 1950;27:790–802.
- 5 Bobrow ML, Friedman S. Tuberculous appendicitis. *Am J Surg* 1956;91:389–93.
- 6 Scott JR. Tuberculosis of the appendix. *Ann Surg* 1917;66:648–53.
- 7 Sinha S, Sarin YK. Tuberculous appendicitis. *Indian J Pediatr* 2005;72:712.
- 8 Shah RC, Mehta KN, Jalunhwala JM. Tuberculosis of the appendix. *J Ind Med Assoc* 1967;49:138–40.
- 9 Maharjan S. An uncommon case of chronic tubercular appendicitis. *Case Rep Pathol* 2015;2015:1–4.
- 10 Gupta SC, Gupta AK, Keswani NK, et al. Pathology of tropical appendicitis. *J Clin Pathol* 1989;42:1169–72.

Copyright 2021 BMJ Publishing Group. All rights reserved. For permission to reuse any of this content visit <https://www.bmj.com/company/products-services/rights-and-licensing/permissions/>  
BMJ Case Report Fellows may re-use this article for personal use and teaching without any further permission.

Become a Fellow of BMJ Case Reports today and you can:

- ▶ Submit as many cases as you like
- ▶ Enjoy fast sympathetic peer review and rapid publication of accepted articles
- ▶ Access all the published articles
- ▶ Re-use any of the published material for personal use and teaching without further permission

#### Customer Service

If you have any further queries about your subscription, please contact our customer services team on +44 (0) 207111 1105 or via email at [support@bmj.com](mailto:support@bmj.com).

Visit [casereports.bmj.com](http://casereports.bmj.com) for more articles like this and to become a Fellow