

Management of multiple impacted teeth

NIDHI BANSAL, ASHIMA VALIATHAN¹, KSHITIJ BANSAL², FARHAN PARKAR¹

Abstract

An impacted or missing permanent tooth can add significant complications to an otherwise straightforward case. When multiple impacted teeth are present, the case complexity increases further. Developing a treatment sequence, determining appropriate anchorage, and planning and executing sound biomechanics can be a challenge. The following case report illustrates a patient with three retained primary teeth and three impacted permanent canines. After careful treatment planning and extraction of multiple primary teeth, followed by attempted guided eruption of impacted teeth, the patient finished with a significantly improved functional and aesthetic result.

Keywords: Biomechanics, diagnosis and treatment planning, guided eruption, impaction, periodontal condition

Introduction

Impaction refers to a failure of a tooth to emerge into the dental arch, usually due to either space deficiencies or the presence of an entity blocking its path of eruption.^[1] Primarily because of their eruption pattern and sequence, canines are prone to impaction, and the maxillary canines are affected more frequently than mandibular canines.^[2,3] Valiathan *et al.* reported a 3.9% prevalence of canine impaction with male to female ratio of 1:1.78 and buccal to palatal ratio of 1:1.46.^[4]

The etiology of impaction is multifactorial. Some of the causes are genetic predisposition, anomalies in maxillary lateral incisors, and inadequate arch space.^[2,3]

One palatally impacted canine can significantly lengthen the overall treatment time; multiple impactions compound the problem. Age at the start of treatment, palatal vs buccal positioning, and the distance of the tooth from the occlusal plane are factors influencing treatment complexity.^[5]

Departments of Orthodontics, ²Conservative Dentistry and Endodontics, Bhojia Dental College and Hospital, Baddi, Himachal Pradesh, ¹Orthodontics, Manipal College of Dental Sciences, Manipal, Karnataka, India

Correspondence: Dr. Nidhi Bansal, H No. 1120, 1st Floor, Sector 11, Panchkula – 134 109, Haryana. Department of Orthodontics, Bhojia Dental College and Hospital, Village Budh, Baddi; District Nalagarh, Himachal Pradesh, India.
E-mail: drnid01@gmail.com

Access this article online	
Quick Response Code: 	Website: www.contempclindent.org
	DOI: 10.4103/0976-237X.94564

Patients with multiple impactions need meticulous management to guide eruption of as many teeth as possible. The following case is of a young girl, who had three permanent impacted teeth with retained deciduous teeth.

Case report

The patient was a 20-year-old female, referred from her endodontist. She was seeking root canal treatment of her lower left tooth. Review of the medical history revealed no allergies or medical problems. No signs or symptoms of temporomandibular dysfunction were noted, with no history of trauma to teeth, lips, or jaws. She had a straight profile with normal muscular activity [Figure 1].

Intraoral clinical examination revealed a Class I molar relationship with retained primary canine teeth in second, third, and fourth quadrants [Figure 2a and b]. The lower left first molar, 36, was grossly decayed. The lower left second molar was mesially tipped and a temporary restoration was present in relation to the lower left first permanent molar. All teeth except 23, 33, 34, and the third molars were present. A lingual crossbite in relation to 25 and 35 was present. A midline diastema with 30% overbite was present. The curve of Spee was 1.0 mm. The maxillary tooth-to-lip relationship was normal. No mucosal bulge could be palpated. The gingiva appeared healthy. Panoramic radiograph revealed [Figure 3] a missing mandibular right third molar while the other three third molar

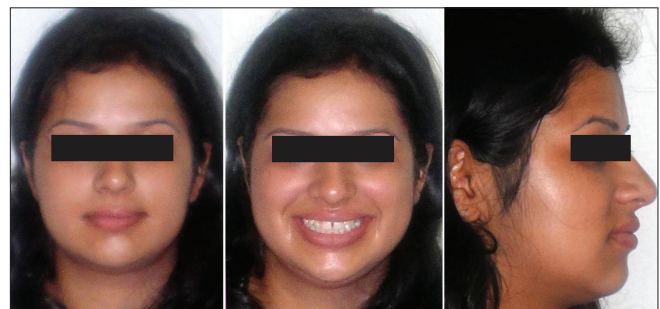

Figure 1: Pretreatment extra-oral photographs

were bulbous and anomalous in shape. The mandibular left and right canines and the left maxillary canine were impacted. Both mandibular canines were 90° rotated mesiolingually. The retained deciduous canines were moderately resorbed. The mandibular left second molar buccal cusp was locked under the distal aspect of the lower left first molar. Periapical and occlusal views [Figures 4 and 5] confirmed the diagnosis of buccally impacted left maxillary and mandibular right canine (tube shift method) and intra-alveolarly impacted left mandibular canine. Lateral cephalometric analysis [Table 1] revealed a normal skeletal relationship, with acceptable incisal and skeletal relationships. Model analysis showed adequate space in the upper arch for alignment of the maxillary canine. As the lower canines were rotated mesiolingually, an average mesiodistal size of mandibular canine was taken to calculate the space requirement in the lower arch. A 3.5-mm arch perimeter deficiency was calculated in the lower arch with 1.04 mm of anterior mandibular excess.

Treatment objectives

The main treatment objective was guided eruption of the impacted teeth to obtain a functional occlusion with minimal impact on the soft tissue profile. However, it was also important to control the active carious lesions and to educate the patient about caries control regimen. A sodium fluoride mouthwash and fluoridated toothpaste were advised. As the retained primary canines served good space maintainers and she had a harmonious soft tissues balance, extraction of only the retained deciduous canine was planned.

Treatment progress

The endodontic treatment of 36, 37 was completed followed by permanent composite restorations. Crown placement was postponed until the completion of the orthodontic

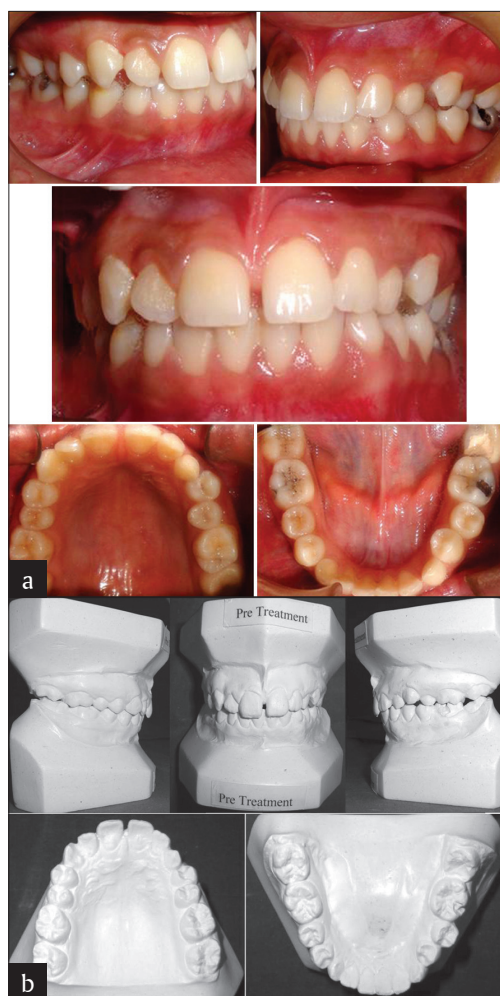


Figure 2: (a) Pretreatment intra-oral photographs. Note the retained primary teeth and the clinical absence of the permanent teeth (b) Pretreatment study models

Table 1: Cephalometric values

	Indian norms ^(9,10)	Pre treatment	Post treatment
Facial angle	76.5–91.0°	89°	89°
Angle of convexity	0–17°	9°	9°
AB-NPog	-5 to -11°	-4°	-4°
Y axis	56–69.5°	57°	57°
Upper incisor-APog	2.5–12mm	8 mm	7 mm
FMA	13.5 to 33°	25°	25°
IMPA	88 to 129.5°	99°	100°
FMIA	62.5 to 66.5°	56°	55°
SNA	72–90.5°	84°	83°
SNB	73.5–84.5°	80°	79°
ANB	2–8°	4°	4°
Upper incisor-NA	5–12 mm, 71–80°	6 mm, 26°	5 mm, 24°
Lower incisor—NB	4–14 mm,	7 mm, 33°	8 mm, 34°
NB-Pog	2.25 mm	-2 mm	0 mm
Inter-incisal angle	91–144°	117°	118°
GoGn-SN	20–40°	31°	31°
OP—SN	4.5–22°	10°	12°
H angle	7–15°	18°	18°

FMA: Frankfort mandibular plane angle, IMPA: Incisor mandibular plane angle, FMIA: Frankfort plane mandibular incisor angle, SNA: Sella-nasion- pt A angle, SNB: Sella-nasion- Pt B angle, ANB: Pt A-Nasion-Pt B angle, NA: Nasion-pt A line, NB: Nasion -Pt B line, OP: Occlusal plane, SN: Sella-nasion line

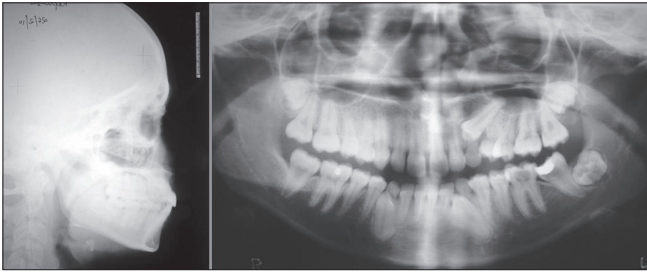


Figure 3: Pretreatment radiographs including the lateral cephalometric and panoramic films

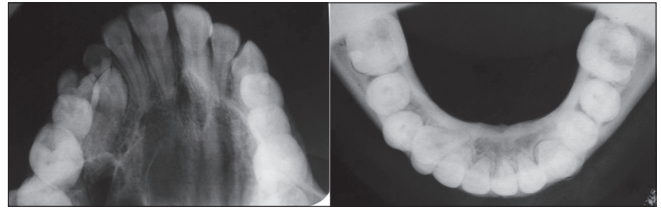


Figure 4: Pretreatment upper and lower occlusal views

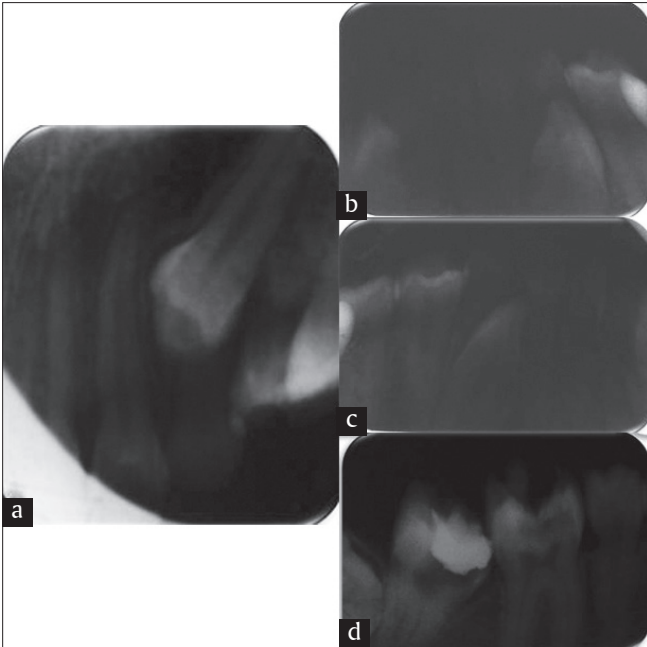


Figure 5: Pretreatment periapical view (a) 22, 23 (b) 43, 44 (c) 34, 35 (d) 36, 37

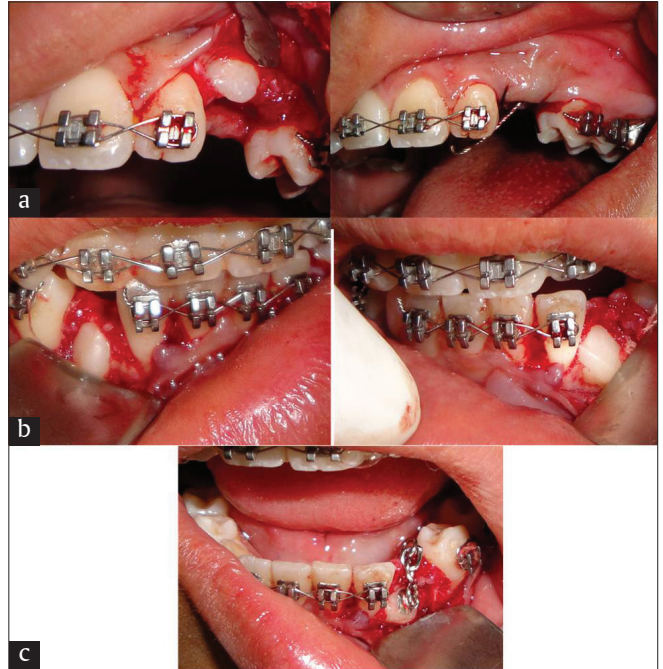


Figure 6: Surgical exposure and bonding of attachment on the (a) 23 (b) 33 (c) 43

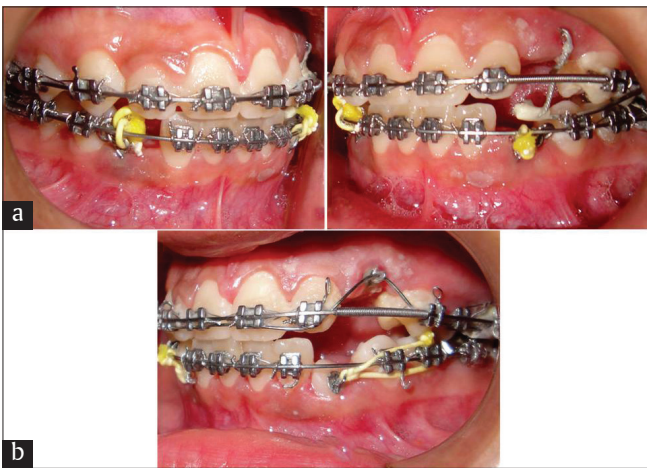

Figure 7: Traction forces applied using (a) auxiliary cantilever and power thread (b) after 4 months

treatment. A 0.022 x 0.028-inch Roth appliance was bonded to the available teeth, and light continuous arch wires were

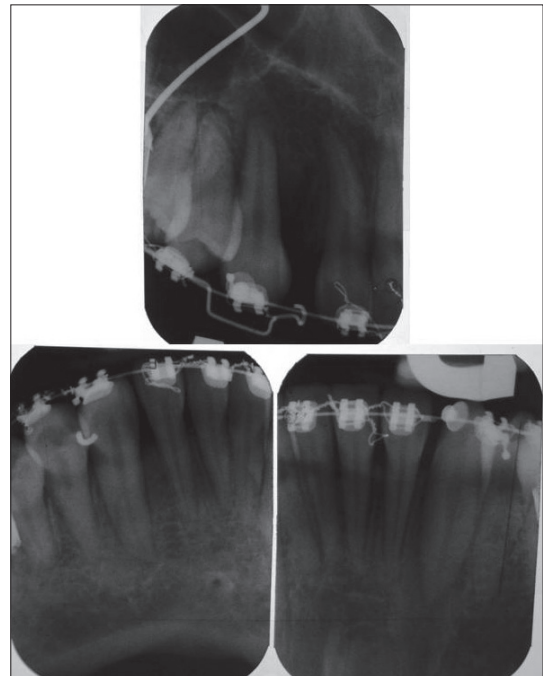


Figure 8: Progress periapical views

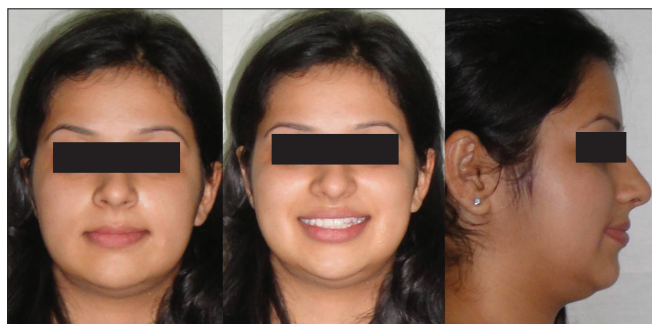

Figure 9: Post treatment extra-oral photographs

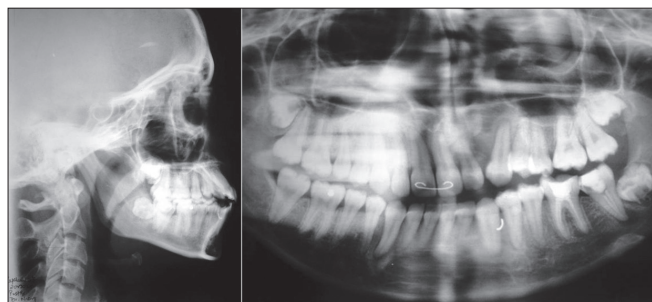


Figure 11: Post-treatment radiographs including the lateral cephalometric and panoramic films

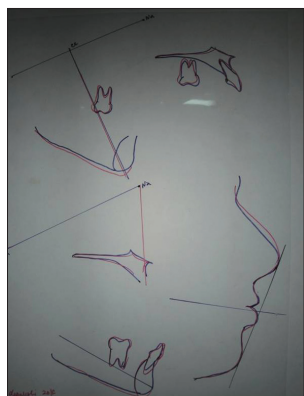


Figure 13: Superimpositions using Ricketts 5-point analysis

placed progressing from 0.016" NiTi, 0.018" NiTi, 0.16 X 0.22" NiTi and finally to 0.019 X 0.025" NiTi. Sufficient space was created for the permanent canines by compressing open coils.

After 5 months with continuous arch wires, the patient was referred to the oral surgeon for extraction of the retained primary canine teeth, followed by sequential exposure of upper and lower canines and bonding of the attachment.

A full mucoperiosteal flap was reflected. The connective tissue and bone was removed beyond the height of contour of the crown. After good hemostatic control, simple eyelets with traction chain were bonded on the canines labially [Figure 6]. The flap was re-approximated and sutured back. A 0.017 x 0.025-inch TMA wire segment was fabricated into a cantilever spring to erupt tooth 23 occlusally [Figure 7a].

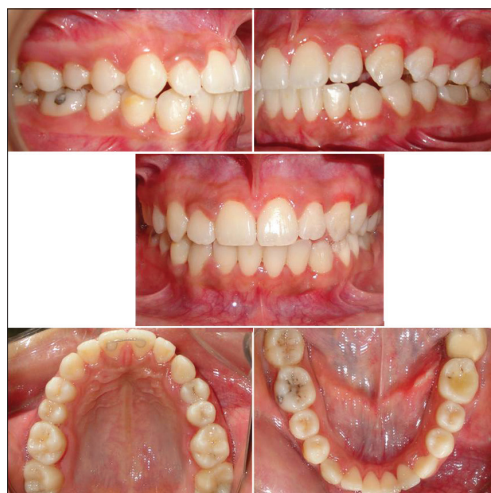

Figure 10: Post-treatment intra-oral photographs

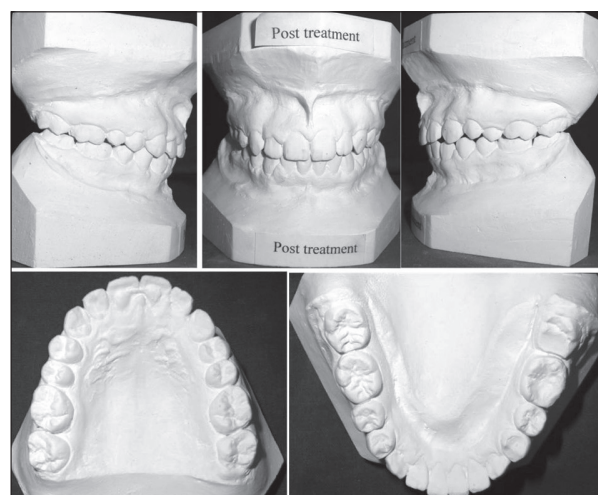


Figure 12: Post-treatment study models

In the lower arch, light traction forces, using power thread from each chain to the arch wire above the impacted tooth, were applied. After 3 months, a change in the direction of the traction forces, to separate the lower left canine from the lower lateral incisor root, were done. Five months after exposure, brackets were in place on all the previously impacted teeth. NiTi overlay wires were tied into the brackets [Figures 7b and 8]. The last 3 months of treatment focused on finishing with a well-interdigitated posterior occlusion. The entire treatment was completed in 12 months. After de-bonding, upper and lower Hawley retainers, with a fixed lingual retainer on upper two central incisors only, were given. Post-treatment records were obtained [Figures 9-13].

Treatment results

The patient was pleased with the results and requested removal of the appliances. Cephalometric superimposition [Figure 13] revealed mild flaring of the lower incisors, which had minimal effect on the patient's soft tissue profile. The mandibular midline was deviated to the left of the maxillary

midline by less than 1 mm. Review of the panoramic radiograph [Figure 11] revealed satisfactory inclination of 23, 34, and 44; significantly uprighted 37. The tooth 22 could have benefited from slight distal root tipping. The extraction of the third molars was postponed by the oral surgeon until it is favorable for extraction.

Discussion

A close eruption technique was followed as tooth can be erupted through the attached gingiva, maintaining the width of the attached gingiva, with good periodontal attachment^[6] with less chances of vertical relapse.

Power thread provides light eruptive forces but has a high decay rate. After the permanent canines erupted in the mouth, NiTi overlay wires were tied on to the main base archwire to maintain the rigidity of the anchorage units.^[7] Auxiliary cantilevers and vertical interarch elastics from an impacted maxillary tooth to an impacted mandibular tooth can work too. However, the latter depends immensely on good patient compliance. The auxiliary cantilevers apply well-defined forces and couples to effect controlled tooth movement during treatment.^[8]

Conclusion

Treatment of impacted teeth requires thorough analysis of

patients' records, correct diagnosis, and a treatment plan with good interdisciplinary efforts that can cater maximal benefit to the patient.

References

1. Daskalogiannakis J. Glossary of Orthodontic Terms. 1st ed. Berlin, Germany: Quintessence Publishing; 2000. p. 142.
2. Becker A. The orthodontic treatment of impacted teeth. 2nd ed. Abingdon: Informa Healthcare; 2007.
3. Proffit WR, Fields HW, Ackerman JL. Contemporary orthodontics. 3rd ed. St. Louis, MO: Mosby-Year Book; 2000. p. 616-30.
4. Verma N, Valiathan A. Master's Thesis 2005. Submitted to Manipal University.
5. Pitt S, Hamdan A, Rock P. A treatment difficulty index for unerupted maxillary canines. *Eur J Orthod* 2006;28:141-4.
6. Vermette ME, Kokich VG, Kennedy DB. Uncovering labially impacted teeth apically positioned flap and closed eruption techniques. *Angle Orthod* 1995;65:23-32.
7. Vanarsdall RL Jr. Efficient management of unerupted teeth: A time-tested treatment modality. *Semin Orthod* 2010;16:212-21.
8. Lindauer SJ, Isaacson RJ. One-couple orthodontic appliance systems. *Semin Orthod* 1995;1:12-24.
9. Valiathan A. Downs' cephalometric analysis on Adults from India. *J Indian Dent Assoc* 1974;46:437-41.
10. Valiathan A. Steiner's cephalometric analysis on adults from India. *Kerala Dent J* 1979;3:18-9.

How to cite this article: Bansal N, Valiathan A, Bansal K, Parkar F. Management of multiple impacted teeth. *Contemp Clin Dent* 2012;3:129-33.

Source of Support: Nil. **Conflict of Interest:** None declared.