



Contents lists available at ScienceDirect

International Journal of Surgery Case Reports

journal homepage: www.casereports.com

Giant saccular aneurysm of the internal carotid artery with adhesion to the vagus nerve: A Case Report

Safwan Omran*, Ben Heinrich Raude, Verena Müller, Andreas Greiner

Charité – Universitätsmedizin Berlin, corporate member of Freie Universität Berlin and Humboldt-Universität zu Berlin, Department of vascular surgery, Berlin, Germany

ARTICLE INFO

Article history:

Received 11 March 2021

Received in revised form 24 March 2021

Accepted 24 March 2021

Available online 27 March 2021

Keywords:

Case report

Internal carotid artery aneurysm

Paralysis of the vagus nerve

Dysphagia

Dysphonia

ABSTRACT

INTRODUCTION AND IMPORTANCE: Aneurysms of the carotid artery are rare and potentially a risk factor for developing neurological events. This case report describes the treatment of a giant saccular aneurysm of the right extracranial internal carotid artery (ICA) with adhesion to the vagus nerve.

CASE PRESENTATION: An 85-year-old female presented with an asymptomatic pulsating mass on the right neck. Ultrasonography and MR angiography revealed a giant aneurysm of the right internal carotid artery with a massive tortuosity. Intraoperatively, a massive adhesion of the vagus nerve to the aneurysm was found. A resection of the aneurysm followed by a spatulated end-to-end anastomosis was performed. Postprocedural neurological symptoms included a transient paralysis of the vagus nerve that recovered within six weeks.

CLINICAL DISCUSSION: The treatment options of ICA aneurysms include open surgical and endovascular interventions. Endovascular treatment may be a good option for aneurysms with a particular morphology. However, open surgery is the favorable option for immense ICA aneurysms with a tortuous anatomical path.

CONCLUSION: Aneurysm resection with end-to-end anastomosis is a possible surgical option in the case of tortuous extracranial ICA aneurysms. Leaving parts of the aneurysmal wall prevented occurring persisting damage of the adhesive vagus nerve.

© 2021 Published by Elsevier Ltd on behalf of IJS Publishing Group Ltd. This is an open access article under the CC BY-NC-ND license (<http://creativecommons.org/licenses/by-nc-nd/4.0/>).

1. Introduction

Aneurysms of the extracranial internal carotid artery (ICA) are rare and accountable for about 1% of all cerebral aneurysms [1]. Patients may present with a pulsating mass in the neck, cerebral ischemic event, cranial nerve deficit, dysphagia, bruit, or infection [2]. Treatment options include open surgery and endovascular repair. Based on the current literature, open surgery seems to achieve satisfactory early and long-term results, while endovascular treatment may be an excellent alternative option in selected patients [3–5].

We report on a rare case of saccular aneurysm of the intracranial carotid artery treated with open surgery.

The work has been reported in line with the SCARE guidelines 2020 [6].

2. Case presentation

An 85-year-old female was admitted with a pulsating mass on the right neck. The medical history included diabetes mellitus type II, hypertension, and 25 years status post partial thyroidectomy due to a thyroid cyst. The patient does not have any relevant genetic history. She is a non-smoker. Her medications consist of antihypertensives (carvedilol 25 mg/day, ramipril 5 mg/day, Nitrendipin 10 mg/day), metformin 500 mg/day, and acetylsalicylsäure 100 mg/day. At presentation, the patient was in a stable cardiopulmonary condition and had no history of cerebrovascular symptoms. Laboratory data of the peripheral blood revealed no sign of inflammation. The carotid artery's complementary duplex ultrasound revealed a giant aneurysm of the carotid artery with a thrombosed wall.

The head and neck's magnetic resonance angiography demonstrated a saccular aneurysm of the ICA with a patent lumen and aneurysm sac thrombosis. The aneurysm measured 3,4 × 4,7 × 4,5 cm and showed an anatomical tortuous path Fig. 1. The preoperative neurological examination and evaluation of the vagus nerve revealed no significant findings. Following multidisciplinary team discussion and consultation with the patient, we carried out an open surgical procedure to reduce stroke and rupture risk. Surgery was performed with general endotracheal anesthesia and

* Corresponding author at: Clinic of Vascular Surgery, Campus Charité Benjamin Franklin, Hindenburgdamm 30, 12203, Berlin, Germany.

E-mail addresses:

safwan.omran@charite.de (S. Omran), ben-heinrich.raude@charite.de (B.H. Raude), verena.mueller@charite.de (V. Müller), andreas.greiner@charite.de (A. Greiner).

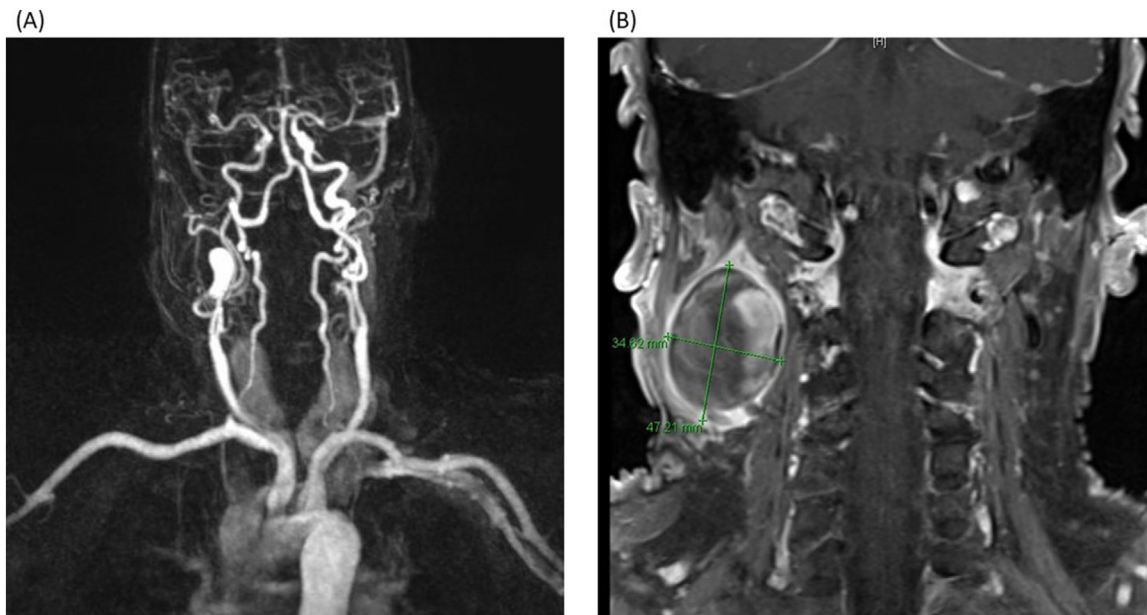


Fig. 1. (A, B) Magnetic resonance angiography of the head and neck shows a giant thrombosed aneurysm of the extracranial internal carotid artery.

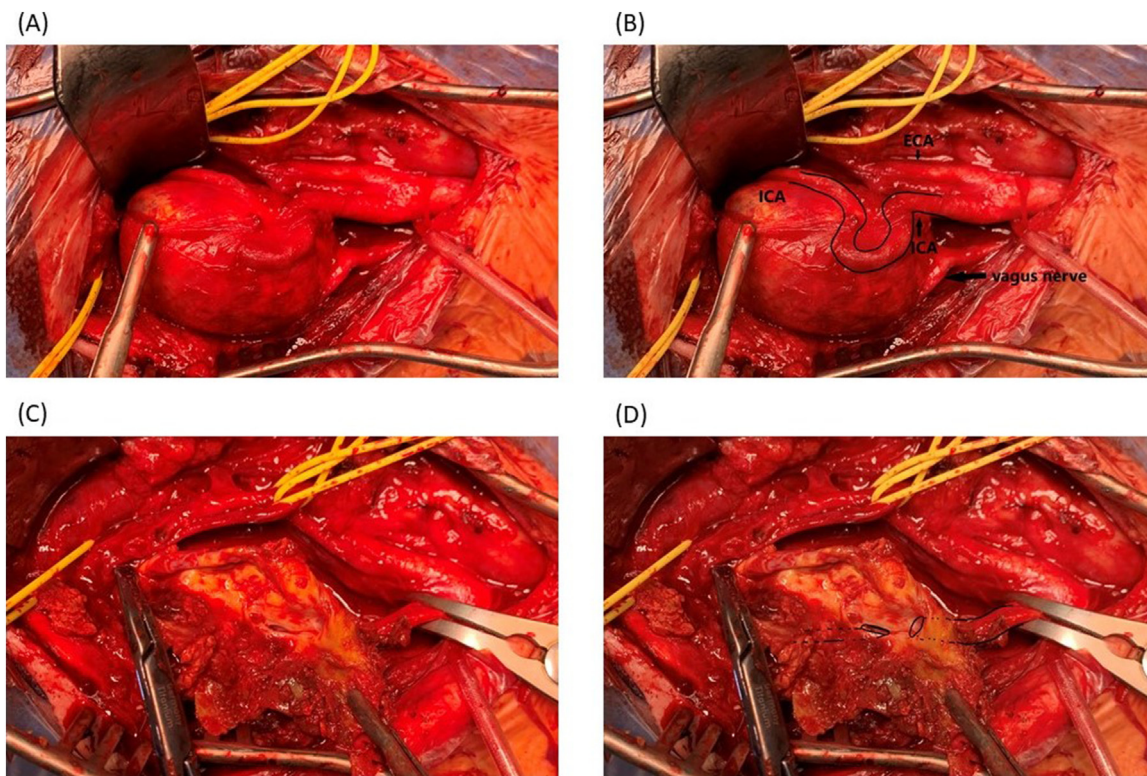


Fig. 2. (A, B) Operative photograph demonstrating a giant aneurysm with a thrombosed wall and tortuous path of the right internal carotid artery and adhesion of the vagus nerve to the wall of the aneurysm; (C, D) show the aneurysm from inside.

intraoperative neurophysiological monitoring with somatosensory evoked potential (SSEP). After dissecting the carotid artery with the aneurysm, we found a giant saccular aneurysm of the ICA with a massive adhesion to the vagus nerve Fig. 2. Therefore, we decided to resect the aneurysm and leave parts of the aneurysmal wall to avoid the vagus nerve's injury Fig. 3.

The resection of the aneurysm was then done. The ICA ends were spatulated and beveled to the appropriate length and anastomosed in an end-to-end fashion with a running 6-0 Prolene suture.

Throughout surgery, the systolic blood pressure was maintained between 140 and 160 mmHg. Intraoperative SSEP monitoring revealed no abnormalities and remained stable during the clamping time of 50 min and throughout the procedure. The intraoperative angiography revealed mild calcification beyond the anastomosis with no evidence of any hemodynamically significant stenosis of the reconstruction and intracranial carotid artery Fig. 3.

Postoperatively, the patient developed a transient paralysis of the vagus nerve with dysphagia and dysphonia due to the nerve's

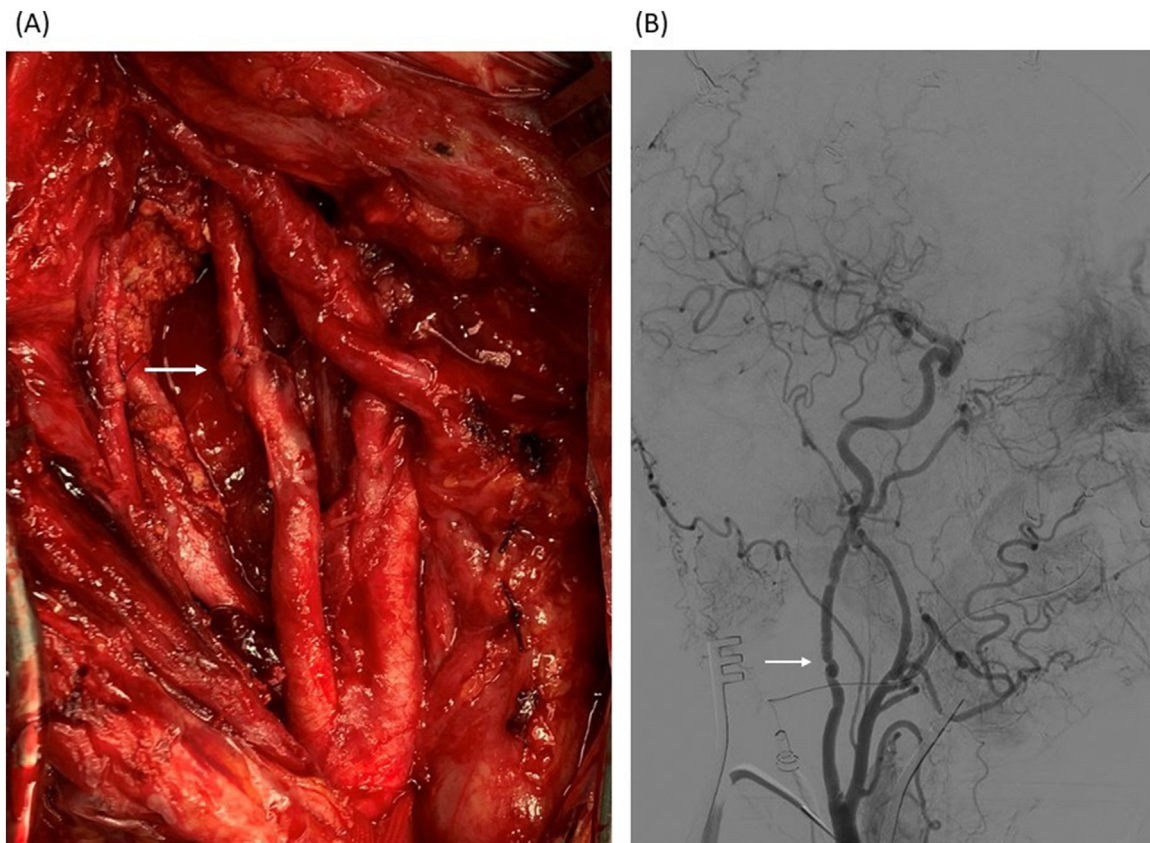


Fig. 3. (A) Operative photograph demonstrating end-to-end anastomosis after excision of the ICA aneurysm; (B) Intraoperative Digital Subtraction Angiography (DSA) showing a good flow through the anastomosis.

surgical manipulation and preparation. The postoperative carotid duplex ultrasound surveillance revealed normal findings. We initialized immediate treatment with a single dose of intravenous cortisone 250 mg to improve the nerve function and reduce edema. The patient started with parenteral nutrition as well as intensive speech therapy. The symptoms improved on the 6th postoperative day. The patient was able to swallow and could start again with an oral diet. Antiplatelet therapy with aspirin was begun on the first postoperative day. The patient was discharged to home on the 8th postoperative day on antiplatelet and antihypertensive medications with a follow-up appointment in 3 and 6 weeks. The postoperative period was uneventful, and the patient's dysphagia and dysphonia gradually recovered within the first six weeks after surgery. After three months, the patient had completely recovered, and she still has an uneventful course after one year of follow-up.

3. Discussion

The most common cause of extracranial internal carotid aneurysms is atherosclerosis. Other causes include trauma, fibromuscular dysplasia, prior surgery, infection, and radiation [4,5,7]. Despite its rarity, carotid aneurysms can cause devastating cerebrovascular complications due to thromboembolism or local compression of the recurrent laryngeal nerve, vagus nerve, or facial nerve.

The treatment of ICA aneurysms comprises either open surgical or endovascular interventions [8,9]. Treatment options depend primarily on the local aneurysm anatomy and morphology. Resection of the aneurysm and reconstruction with venous graft may be the most used treatment. However, patchplasty or end-to-end anastomosis can be used in saccular aneurysms [2,7,9,10]. Other surgical

options, such as the carotid artery's ligation, are primarily reserved for emergencies as a bailout procedure [2].

The endovascular approach of the ICA aneurysms has become more popular and was shown to be an effective treatment. Both covered and bare-metal stents have been reported [11]. Arterial embolism, recurrent stenosis, or occlusion are possible post-interventional complications.

In our case, we decided on open surgery due to the immense size of the aneurysm and the tortuous anatomical path of the internal carotid artery, making the implantation of a stent-graft a challenging and precarious procedure.

4. Conclusion

We reported a rare case of saccular aneurysm of the internal carotid artery treated with complete surgical resection and end-to-end anastomosis. Despite the precise surgical preparation, transient vagus nerve damage occurred due to the tight adhesion to the aneurysm. The injury of the vagus nerve recovered gradually six weeks after surgery.

Declaration of Competing Interest

The authors report no declarations of interest.

Funding

German Research Foundation (DFG) and the Open Access Publication Funds of Charité – Universitätsmedizin Berlin will cover the fees for journal articles (Article Processing Charges (APCS) or publication fees) under the following conditions:

Total publication costs including VAT do not exceed €2000 per article. Partial (or shared) payment is not possible.

The article should be published under a Creative Commons License (CC BY is preferred).

Ethical approval

Our institution does not require ethics approval for case reports.

Consent

We have obtained written and signed consent to publish this case report from the patient.

Author contribution

Study design: Safwan Omran, Andreas Greiner.

Surgical procedure: Safwan Omran, Ben Heinrich Raude, Verena Müller.

Writing the paper: Safwan Omran, Ben Heinrich Raude, Verena Müller, Andreas Greiner.

Data Collection: Safwan Omran, Ben Heinrich Raude, Verena Müller.

Data analysis: Safwan Omran, Ben Heinrich Raude, Verena Müller, Andreas Greiner.

Supervision: Safwan Omran, Andreas Greiner.

Registration of research studies

Not applicable.

Guarantor

Safwan Omran.

Provenance and peer review

Not commissioned, externally peer-reviewed.

Acknowledgment

We acknowledge support from the German Research Foundation (DFG) and the Open Access Publication Funds of Charité – Universitätsmedizin Berlin.

References

- [1] D. Mukherjee, D.T. Collins, L. Adams, Resection of internal carotid artery aneurysm under neuroprotection with flow reversal technique, *Vasc. Endovasc. Surg.* 54 (4) (2020) 378–381, <http://dx.doi.org/10.1177/1538574420911510>.
- [2] C.J.K. Kraemer, W. Zhou, Carotid aneurysm review, *Int. J. Angiol.* 28 (1) (2019) 17–19, <http://dx.doi.org/10.1055/s-0039-1677675>.
- [3] R. Pulli, W. Dorigo, A. Alessi Innocenti, G. Pratesi, A. Fargion, C. Pratesi, A 20-year experience with surgical management of true and false internal carotid artery aneurysms, *Eur. J. Vasc. Endovasc. Surg.* 45 (1) (2013) 1–6, <http://dx.doi.org/10.1016/j.ejvs.2012.10.011>.
- [4] E. Rosset, J.N. Albertini, P.E. Magnan, B. Ede, J.M. Thomassin, A. Branchereau, Surgical treatment of extracranial internal carotid artery aneurysms, *J. Vasc. Surg.* 31 (4) (2000) 713–723, <http://dx.doi.org/10.1067/mva.2000.104102>.
- [5] Z. Li, G. Chang, C. Yao, et al., Endovascular stenting of extracranial carotid artery aneurysm: a systematic review, *Eur. J. Vasc. Endovasc. Surg.* 42 (4) (2011) 419–426, <http://dx.doi.org/10.1016/j.ejvs.2011.05.008>.
- [6] Riaz A. Agha, Thomas Franchi, Catrin Sohrabi, et al., The SCARE 2020 guideline: updating consensus surgical CAse REport (SCARE) guidelines, *Int. J. Surg.* 84 (2020) 226–230, <http://dx.doi.org/10.1016/j.ijsu.2020.10.034>.
- [7] A.K. Dhillon, T. Rowlands, G. McMahon, Carotid artery aneurysm: last among equals, *BMJ Case Rep.* 2016 (2016), <http://dx.doi.org/10.1136/bcr-2016-215194>.
- [8] J.C. Welleweerd, H.M. den Ruijter, B.G.L. Nelissen, et al., Management of extracranial carotid artery aneurysm, *Eur. J. Vasc. Endovasc. Surg.* 50 (2) (2015) 141–147, <http://dx.doi.org/10.1016/j.ejvs.2015.05.002>.
- [9] G.T. Fankhauser, W.M. Stone, R.J. Fowl, et al., Surgical and medical management of extracranial carotid artery aneurysms, *J. Vasc. Surg.* 61 (2) (2015) 389–393, <http://dx.doi.org/10.1016/j.jvs.2014.07.092>.
- [10] N.R. Rana, K.J. Hodgson, D. Ramsey, C.M. Johnson, Management approach to an extracranial internal carotid artery aneurysm, *J. Vasc. Surg.* 57 (2) (2013) 526, <http://dx.doi.org/10.1016/j.jvs.2011.11.101>.
- [11] Z. Chen, L. Chen, J. Zhang, et al., Management of extracranial carotid artery aneurysms: a 6-year case series, *Med. Sci. Monit.* 25 (2019) 4933–4940, <http://dx.doi.org/10.12659/MSM.914374>.

Open Access

This article is published Open Access at [sciencedirect.com](https://www.sciencedirect.com). It is distributed under the [IJSCR Supplemental terms and conditions](#), which permits unrestricted non commercial use, distribution, and reproduction in any medium, provided the original authors and source are credited.