



Rare presentation of Waldenström macroglobulinemia post shoulder replacement and dynamic hip screw procedures



Taha Almufti, MbChB, MRCPi^{*}, Franz Eversheim, MD, FRACP, AFRACMA, Gabriel Akra, MBBS, FRCS, FACEM, Augustus Kigotho, MbChB, FACEM

Albury Wodonga Health, Wodonga, VIC, Australia

ARTICLE INFO

Keywords:

Waldenström macroglobulinemia
Heterotopic ossification
Acute kidney injury
Case report
total shoulder replacement
dynamic hips screws

Waldenström macroglobulinemia (WM) is a distinct clinicopathologic entity demonstrating lymphoplasmacytic lymphoma in the bone marrow, with an IgM monoclonal gammopathy in the blood. Patients may present with symptoms related to the infiltration of the hematopoietic tissues or the effects of monoclonal IgM in the blood.²

The etiology of WM is unknown. No obvious causative or predisposing factor has been identified; however, certain autoimmune and infectious conditions are associated with increased risks of subtypes of non-Hodgkin lymphoma. A few previous studies suggest that chronic inflammation may particularly elevate the risk of the distinct non-Hodgkin lymphoma subtype, Waldenström macroglobulinemia. In the largest investigation of WM risk factors to date, a 2- to 3-fold elevated risk of WM in persons with a history of autoimmune diseases with autoantibodies and notably elevated risks associated with hepatitis, human immunodeficiency virus, and rickettsiosis were found.^{7,8} We report a case of WM coinciding with the development of heterotopic ossification (HO) in a reverse total shoulder replacement and dynamic hip screw implant for the treatment of femoral neck fractures. With acute kidney injury and hypercalcemia signaling the manifestation of WM shortly after these major surgeries, this is a rare presentation of a rare hematologic disease.

Case presentation

We present a 79-year-old white man who was independent in all daily living activities, active and fit.

He presented to the emergency department after a fall from a push bike onto his right side. A radiograph confirmed fractures of the right head of the humerus and right neck of the femur.

The patient had a medical history of coronary artery bypass graft in 2002 as well as hypertension. He was on olmesartan 40 mg once daily and acetylsalicylic acid (Aspirin) 100 mg daily, with normal baseline renal function, hemoglobin, and serum electrolytes.

On the next day, the patient underwent a dynamic hip screw procedure as an elective surgery for the right femoral neck fracture. Ten days later, he underwent a reverse total shoulder replacement. The patient recovered well from the surgeries, and 2 weeks post-admission, he transferred from the surgical ward to a rehabilitation ward, where he was found to have hypercalcemia (corrected calcium: 3.33 mmol/L, normal range [NR] 2.15–2.65); a phosphate level of 1.18 mmol/L (NR 0.75–1.50); a parathyroid hormone level of 1.6 pmol/L (NR 2.0–8.5 pmol/L); renal function: estimated glomerular filtration rate, 70 mL/min/1.73 m², and creatinine, 90 μmol/L (NR 60–110); and a hemoglobin level of 9.8 g/dL.

On presentation, the corrected calcium level was within normal limits (2.44 mmol/L, NR 2.15–2.65). We encouraged oral hydration and monitored the calcium levels and parathyroid hormone levels over the following days; observation showed a gradual decline of the calcium level to 2.9 mmol/L (NR 2.15–2.65) with near normalization of the parathyroid hormone level 1.9 pmol/L (NR 2.0–8.5).

The patient continued his rehabilitation program, with a recommendation from the orthopedic surgeon to continue non-weight-bearing for the right lower limb for at least 6 weeks.

Five weeks postsurgery, on a routine follow-up, a sudden decline in renal function was detected (estimated glomerular filtration rate 22 mL/min/1.73 m² and creatinine 238 μmol/L). An urgent ultrasonograph ruled out obstructive uropathy with normal

^{*} Corresponding author: Taha Almufti, MbChB, MRCPi, Wodonga Hospital, 83 Vermont St, Wodonga, 3690 VIC, Australia.

E-mail address: taha.almufti@gmail.com (T. Almufti).

INVESTIGATIONS RESULTS

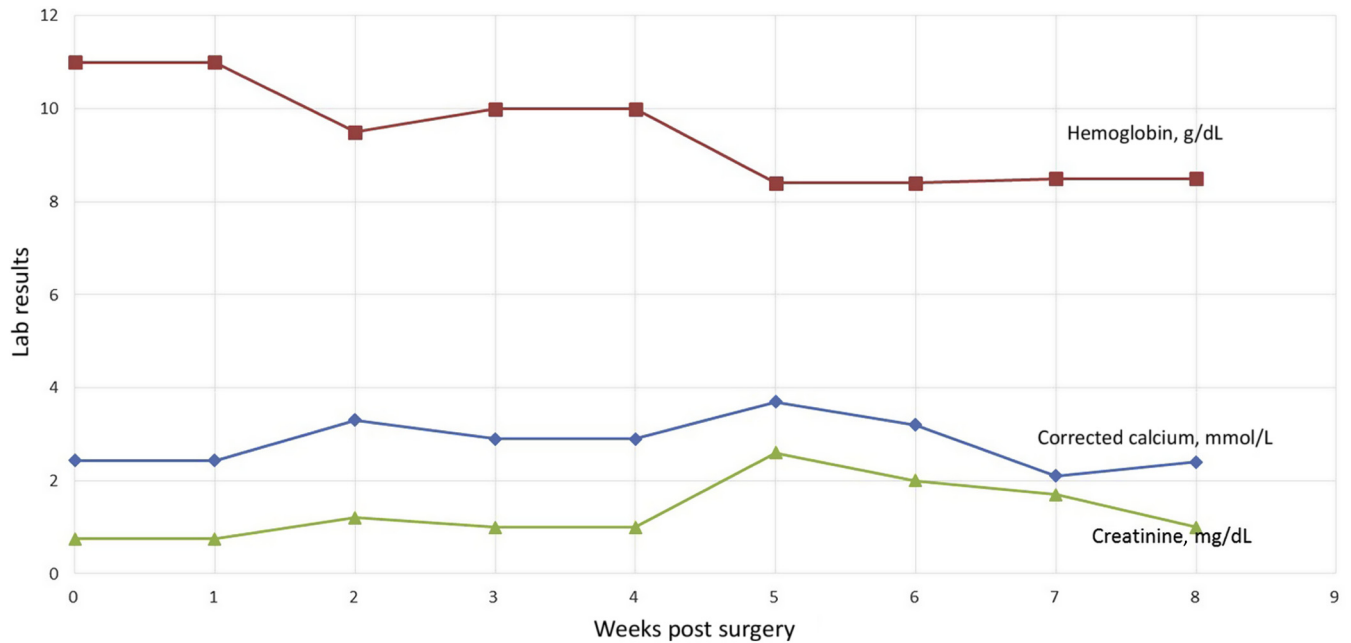


Figure 1 Investigations results.

renal parenchymal differentiation, and there was no offending drug use to blame for the renal dysfunction. However, the patient's corrected calcium increased again to 3.7 mmol/L, and his hemoglobin dropped to 8.4 g/dL from a baseline of 11 g/dL.

The triad of hypercalcemia, anemia, and renal dysfunction prompted the workup for multiple myeloma, supported by the result of the albumin/globulin inverse ratio on the day of presentation to the emergency department (31/39 g/L).

The patient's renal function normalized with the use of hydration and calcitonin for the first 48 hours, followed by denosumab (Fig. 1). While awaiting serum protein electrophoresis, we obtained the following results: erythrocyte sedimentation rate 112 mm/h, beta 2 microglobulin 8 g/L, plasma viscosity 1.43 mPa·s (NR 1.10–1.38). The radiographic skeletal survey did not show any significant abnormalities. Additionally, no abnormality was detected on a computed tomography of the brain, neck, chest, abdomen, and pelvis; there was no bone lesion or lymph node enlargement.

The serum protein electrophoresis result showed an IgM kappa spike at 20 g/L, and a whole body sestamibi study showed widespread, although relatively mild, abnormal sestamibi uptake throughout the axial skeleton and long bones. The most prominent sites of involvement were in the left humeral head and left parietal region. The pattern was consistent with a diffuse infiltrative process.

A bone marrow aspirate and trephine biopsy showed a markedly hypercellular marrow with a marked lymphoid infiltrate. Immunohistochemistry showed marked CD20+ nodular B-cell infiltrates, a mild reactive increase in CD3+ T cells, a pattern of CD5 distribution similar to CD3, and CYCLIN D1-negativity, and CD138 showed a mild increase in plasma cells. Plasma cells appeared as single scattered cells in small collections. The total plasma burden was approximately 5%–8%. In conjunction with the presence of serum paraprotein (IgM 20 g/L), the morphologic features were consistent with a diagnosis of lymphoplasmacytic lymphoma.

Additionally, 5 weeks post reverse total shoulder replacement, the patient developed pain and stiffness in his shoulder, with limitation in the range of motion. A follow-up radiograph showed quite extensive HO (Fig. 2). It is worth mentioning that the serum cobalt level was nondetectable, and the hepatitis screen was negative as well, bearing in mind that hepatitis C virus could be a triggering etiologic factor for WM.

This case was discussed at our Oncology Multi-disciplinary Meeting, and we were recommended to treat the patient with a combination targeted therapy of rituximab and bendamustine. Before that, the patient had commenced weekly treatments of 20 mg of dexamethasone.

The patient achieved a dramatic improvement with weekly treatments of 20 mg of dexamethasone. The patient was able to mobilize independently with a 4-wheeled walker. Repeat laboratory tests revealed that the beta 2 microglobulin level decreased to 5 g/L, the erythrocyte sedimentation rate was 45 mm/h, and the IgM was 15 g/L. His renal function was maintained within normal limits, and his calcium level was 2.3 mmol/L. The patient was discharged to home to await his first cycle of targeted therapy. However, the patient did not consent to it, so targeted therapy was not initiated.

Seven months following the initial presentation, the patient remained well and off steroids, a follow-up radiograph showed a slight progression of the HO (Fig. 3). In addition, the patient maintained an acceptable range of motion with stable IgM (14 g/L), hemoglobin (10.8 g/dL), and corrected Ca (2.4 mmol/L) levels and estimated glomerular filtration rate (54 mL/min/1.73 m²), on a wait-and-watch policy, with outpatient visits every 3 months.

Discussion

In the case reported here, the presentation of WM is unusual because our patient presented with hypercalcemia 15 days after 2 major orthopedic surgeries. Among all causes of hypercalcemia,

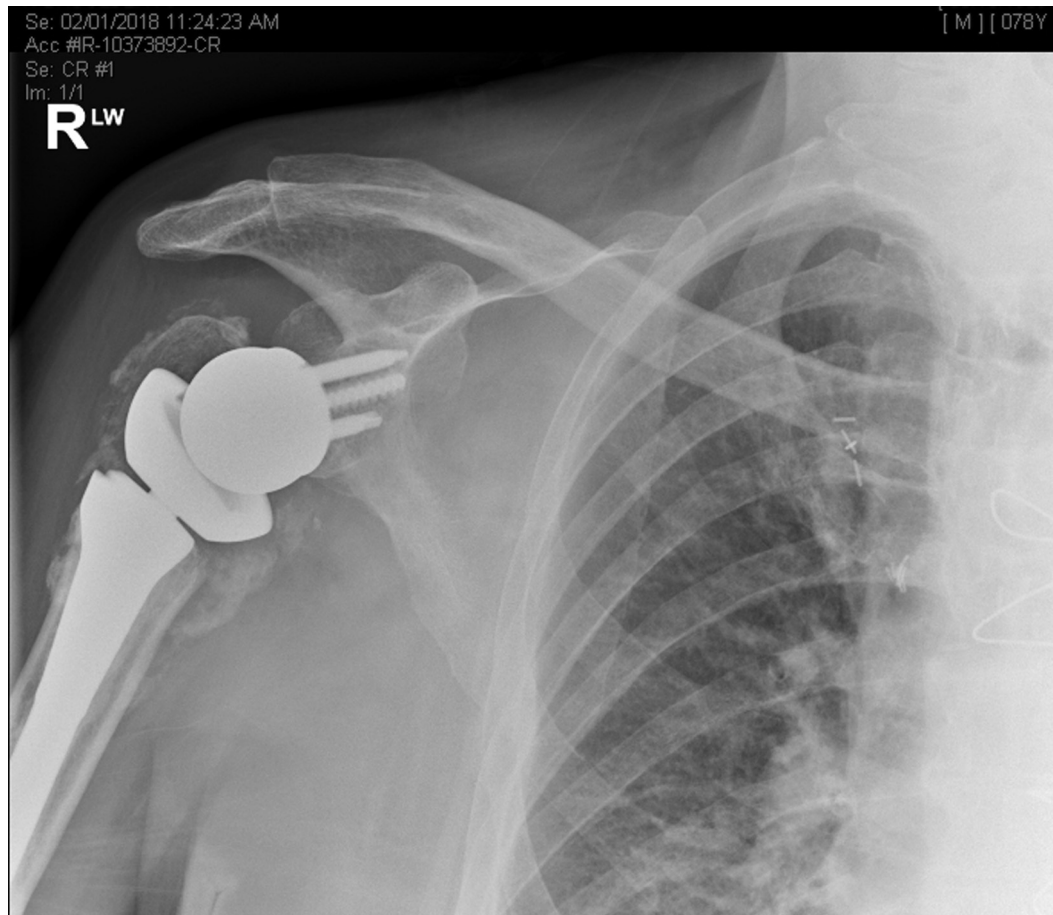


Figure 2 Heterotopic ossification—5 weeks post surgery.

primary hyperparathyroidism and malignancy are the most common, accounting for more than 90% of the cases.⁹ Therefore, the diagnostic approach to hypercalcemia typically involves distinguishing between the two. The initial goal of the laboratory evaluation is to differentiate parathyroid hormone (PTH)-mediated hypercalcemia (primary hyperparathyroidism and familial hyperparathyroid syndromes) from non-PTH mediated hypercalcemia (primarily malignancy, vitamin D intoxication, granulomatous disease). Thus, once hypercalcemia is confirmed, the next step is the measurement of serum PTH.

The PTH level was below the normal range in our patient. Therefore, we did not initiate further investigations, as we believed that the hypercalcemia was not an uncommon finding within the first week following hip and shoulder fractures, and parathyroid hormone can be suppressed within such a short period, secondary to hypercalcemia¹²; we also took into consideration that the calcium level was normal on presentation, with normal renal function. Furthermore, the calcium and parathyroid levels started to normalize by the third week, without intervention.

The complications were more evident by the fifth week post-surgery. The development of anemia and deterioration of renal function, in addition to the marked increase of calcium level (above 3.5 mmol/L) after initial improvement, prompted us to exclude an underlying malignancy as the primary cause of hypercalcemia rather than bone mobilization by the orthopedic surgeries. Therefore, we sent for a multiple myeloma workup, which, to our surprise, revealed lymphoplasmacytic lymphoma.

Lymphoma is the most common hematologic malignancy and is a cancer of the immune system developing from B or T

lymphocytes.¹⁰ However, the incidence of lymphoplasmacytic lymphoma has been estimated at 3 per million cases per year.

Chronic infection and inflammation trigger an immune system response, which may lead to the development of lymphoma.

Only a few case reports exist in the literature describing patients with WM with nephropathy.⁵ We think the current case is rare in the following 2 ways: (1) acute kidney injury was the clinical manifestation that led to the diagnosis of WM, which is in itself a rare event in WM; and (2) hypercalcemia is more often a feature of multiple myeloma rather than WM.

Another relatively unique issue is the extensive HO that developed surrounding the proximal right humerus, representing inflammation surrounding the shoulder implant shortly after surgery. Although there is not enough evidence in the literature to describe HO around shoulder replacement, it is, however, well known and widely described in hip replacements 12 weeks postsurgery.⁶

The scientific literature is scarce on reporting the incidence of WM post prosthetic implant, trauma, or surgery; however, there is available evidence suggesting that breast implant-associated anaplastic large cell lymphoma (BIA-ALCL) develops in the setting of implant-induced chronic inflammation.¹⁴ Also, a traumatic event or surgery may trigger the balance toward tumor growth as a result of associated angiogenesis, cytokine, and growth factors release.¹¹ Several authors have investigated trauma-associated growth of suspected dormant malignancy and incriminated growth factors, cytokines, and angiogenic mechanisms.³

A traumatic event triggers several mechanisms of soft tissue and bone repair of which angiogenesis is part. Dormant cancer cells at the site of tissue trauma and thereby exposed to pro-inflammatory

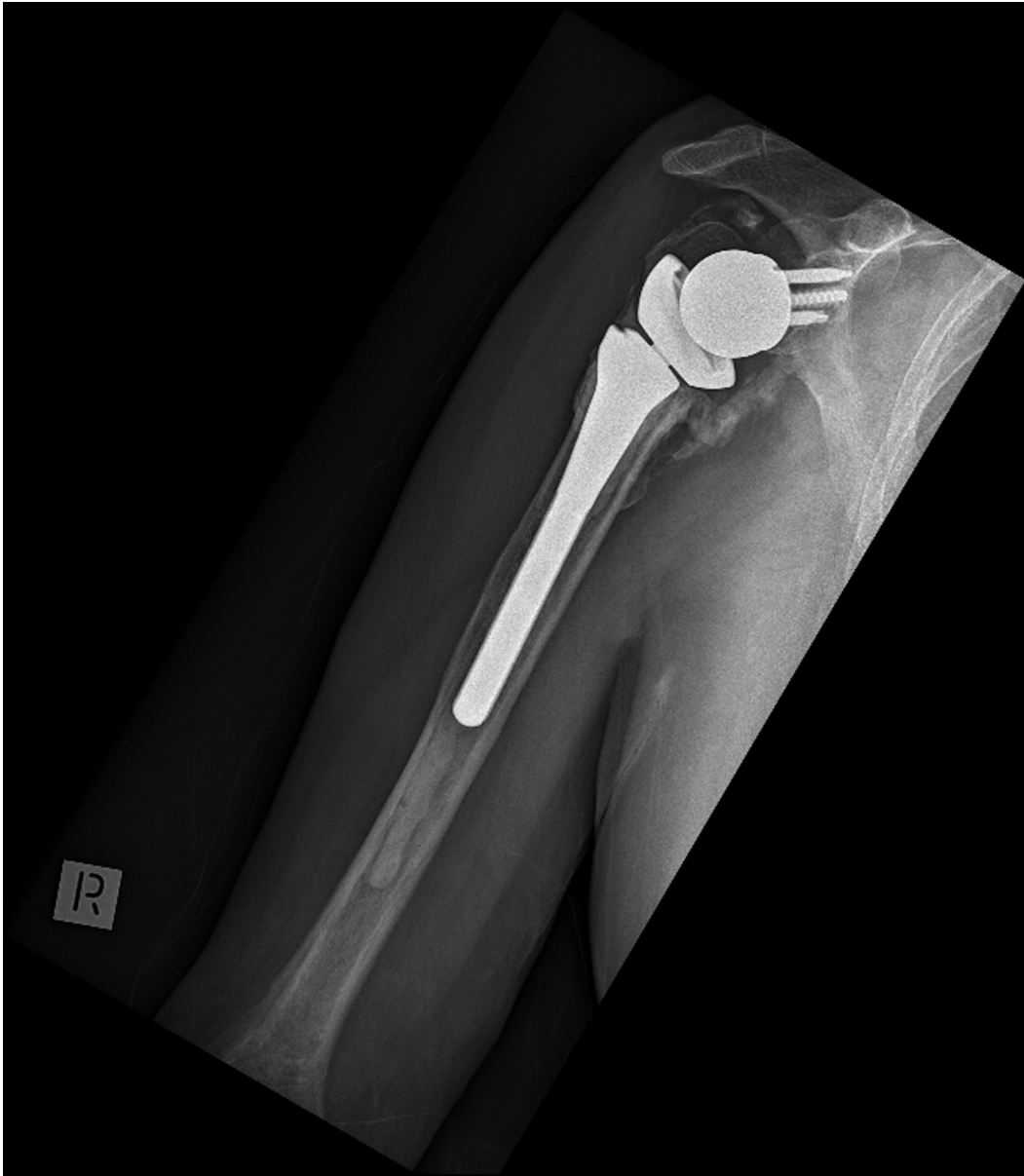

Figure 3 Heterotopic ossification—7 months post surgery.

mediators may be sufficiently stimulated to overcome dormancy.^{3,11}

In our patient, the event may be explained by the presence of a smoldering WM before surgery (albumin/globulin inverse ratio 31/39 g/L) that might have been stimulated by a new environment of stimulatory factors, trauma, major surgeries, and the presence of the shoulder implant. Moreover, it remains to be defined whether the immune system's response to inflammation surrounding the shoulder implant may lead to genetic degeneration and dysplasia in a genetically susceptible patient in the same pathogenesis as that of a silicone implant.⁴

Conclusion

Most traumatic and surgical events in cancer patients do not lead to tumor growth or activation of dormant disease. However,

we suggest that the phenomenon of tumor growth after trauma or surgery, as well as the immune response from a population of clonal B cells to a prosthetic implant, deserves further investigation and study.

Acknowledgments

We thank Dr Mustafa AL-Musawi, who was directly involved in the care and treatment of the patient while in hospital.

Disclaimer

The authors, their immediate families, and any research foundations with which they are affiliated have not received any financial payments or other benefits from any commercial entity related to the subject of this article.

References

1. Bizjak M, Selmi C, Praprotnik S, Bruck O, Perricone C, Ehrenfeld M, et al. Silicone implants and lymphoma: the role of inflammation. *J Autoimmun* 2015;65:64. <https://doi.org/10.1016/j.jaut.2015.08.009>.
2. Campo E, Swerdlow SH, Harris NL, Pileri S, Stein H, Jaffe ES. The 2008 WHO classification of lymphoid neoplasms and beyond: evolving concepts and practical applications. *Blood* 2011;117:5019–32. <https://doi.org/10.1182/blood-2011-01-293050>.
3. El Saghir NS, Elhadj II, Geara FB, Hourani MH. Trauma-associated growth of suspected dormant micrometastasis. *BMC Cancer* 2005;5:94. <https://doi.org/10.1186/1471-2407-5-94>.
4. George EV, Pharm J, Houston C, Al-Quran S, Brian G, Dong H, et al. Breast implant-associated ALK-negative anaplastic large cell lymphoma: a case report and discussion of possible pathogenesis. *Int J Clin Exp Pathol* 2013;6:1631–42.
5. Isaac J, Herrera GA. Cast nephropathy in a case of Waldenstrom's macroglobulinemia. *Nephron* 2002;91:512–5. <https://doi.org/10.1159/000064299>.
6. Kjaersgaard-Andersen P, Pedersen P, Kristensen SS, Schmidt SA, Pedersen NW. Serum alkaline phosphatase as an indicator of heterotopic bone formation following total hip arthroplasty. *Clin Orthop Relat Res* 1988;102–9.
7. Koshiol J, Gridley G, Engels EA, McMaster ML, Landgren O. Chronic immune stimulation and subsequent Waldenstrom macroglobulinemia. *Arch Intern Med* 2008;168:1903–9. <https://doi.org/10.1001/archinternmed.2008.4>.
8. Kristinsson SY, Koshiol J, Björkholm M, Goldin LR, McMaster ML, Turesson I, et al. Immune-related and inflammatory conditions and risk of lymphoplasmacytic lymphoma or Waldenström macroglobulinemia. *J Natl Cancer Inst* 2010;102:557–67. <https://doi.org/10.1093/jnci/djq043>.
9. Lafferty FW. Differential diagnosis of hypercalcemia. *J Bone Miner Res* 1991;6:S51–9; discussion S61.
10. National Cancer Institute. General information about adult non-Hodgkin lymphoma. Available at: <https://www.cancer.gov/types/lymphoma/patient/adult-nhl-treatment-pdq>; 2014. Accessed April 13, 2017.
11. O'Byrne KJ, Dalgleish AG, Browning MJ, Steward WP, Harris AL. The relationship between angiogenesis and the immune response in carcinogenesis and the progression of malignant disease. *Eur J Cancer* 2000;36:151–69.
12. Sato Y, Kaji M, Higuchi F, Yanagida I, Oishi K, Oizumi K. Changes in bone and calcium metabolism following hip fracture in elderly patients. *Osteoporos Int* 2001;12:445–9.