

## A clinical case of equine fungal placentitis with reference to hormone profiles and ultrasonography

Harutaka MURASE<sup>1</sup>, Hidekazu NIWA<sup>2</sup>, Yoshinari KATAYAMA<sup>2</sup>, Fumio SATO<sup>1</sup>,  
Tetsuro HADA<sup>1</sup> and Yasuo NAMBO<sup>3\*</sup>

<sup>1</sup>Equine Science Division, Hidaka Training and Research Center, Japan Racing Association, Hokkaido 057-0171, Japan

<sup>2</sup>Epizootic Research Center, Japan Racing Association, Tochigi 329-0412, Japan

<sup>3</sup>Department of Clinical Veterinary Sciences, Obihiro University of Agriculture and Veterinary Medicine, Hokkaido 080-8555, Japan

---

*Fungal placentitis is an infectious disease inducing abortion in pregnant mares. In the present report, we describe a field case of abortion caused by fungal placentitis with consecutive examinations. The progesterone level and combined thickness of the uterus and placenta (CTUP) were abnormal before the onset of clinical signs. Additionally, the estradiol level started to change before the appearance of clinical signs. Abnormal serum amyloid A values and an abnormal fetal heart rate were observed after the onset of clinical signs. The present report demonstrates that the progesterone level and CTUP may be adequate as early diagnostic markers of fungal placentitis and bacterial infection. Endocrinological evaluation based on cutoff values or serial measurements were also useful for early diagnosis.*

**Key words:** abortion, equine, fungal infection, placentitis

---

**J. Equine Sci.**  
**Vol. 26, No. 4**  
**pp. 129–133, 2015**

Ascending placentitis is a major cause of abortion, stillbirth, and perinatal death in late equine pregnancy, mainly because of bacteria and fungi from the uterine cervix [9]. Most of these infections are caused by bacteria, and there have been only a few reports on fungal placentitis. Regarding diagnosis of placentitis, the blood concentrations of progesterone and estrogen [15, 19], the combined thickness of the uterus and placenta (CTUP) [18], and fetal ultrasonographic indices [4, 16, 17] have been reported as methods of monitoring the fetal and placental conditions. Bacterial placentitis experimental models have been used for research on diagnosis [2, 5, 8, 12] and treatment [3]. Conversely, there are only a few reports on natural cases of infections in the field [7]. This report aimed to describe the history of an abortion caused by natural fungal placentitis with several consecutive examinations, including blood examinations and ultrasonographic examinations prior to clinical signs

of abortion.

The mare was a 12-year-old Thoroughbred that had a history of six births without abortion. The mare aborted at 41 weeks (285 days) of pregnancy. The mare was fed to maintain a body condition score of 6.0–7.0 at the JRA Hidaka Training and Research Center (Urakawa, Japan).

For monitoring of the pregnant mare, we collected blood samples every week to measure progesterone and estradiol levels, the white blood cell (WBC) count, and serum amyloid A (SAA). Ultrasonographic examinations were carried out to measure fetal heart rate (FHR) and CTUP [18]. We examined the mare every week until 26 weeks and then every two weeks. Then we examined the mare every week again after 32 weeks when the CTUP showed abnormal. This monitoring strategy was approved by the Animal Care and Use Committee at Hidaka Training and Research Center. Plasma concentrations of progesterone and estradiol were determined by time-resolved fluoroimmunoassay (TR-FIA) using DELFIA systems (PerkinElmer, Waltham, MA, U.S.A.) according to the manufacturer's protocol with minor modifications [10]. The treatment strategy was based on previous report [11]. Trimethoprim-sulfamethoxazole (15 mg/kg, quaque 12 hora (q12 h), per os (PO)), diclofenac sodium (125–250

---

Received: May 27, 2015

Accepted: September 29, 2015

\*Correspondence author. e-mail: ynambo@obihiro.ac.jp

©2015 Japanese Society of Equine Science

This is an open-access article distributed under the terms of the Creative Commons Attribution Non-Commercial No Derivatives (by-nc-nd) License <<http://creativecommons.org/licenses/by-nc-nd/3.0/>>.

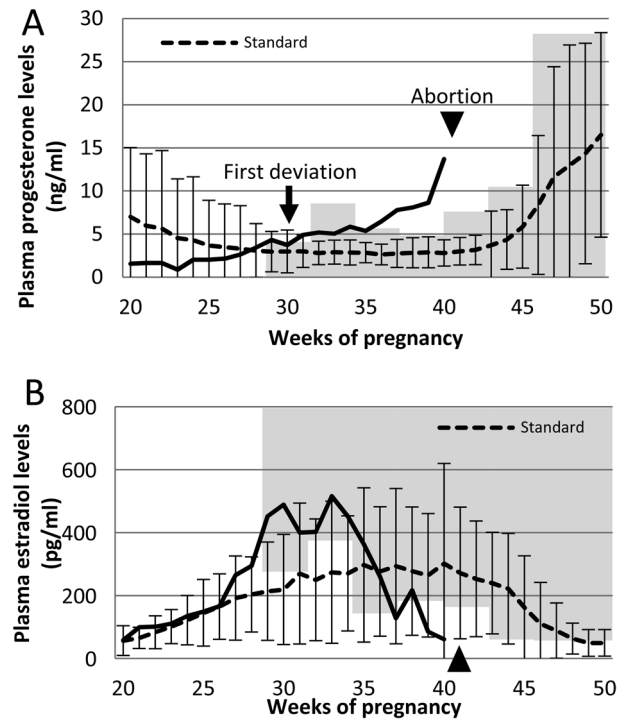
mg, q12 h, PO), ritodrine hydrochloride (0.1 mg/kg, q12 h, PO), and medroxyprogesterone (200–400 mg, q24 h, PO) were prescribed as antimicrobial, anti-inflammatory, and tocolytic medications. Treatment was continued or modified according to clinical findings or results of examinations. Uterine cervical swabs were also collected for identification of pathogens after vaginal discharge onset. Upon abortion, the placenta and fetal organs were pathologically examined.

Standard ranges of progesterone, estradiol, CTUP, and FHR were defined as means  $\pm$  2SD (standard deviation) and were based on normal pregnant mares. The data for progesterone and estradiol were collected from 28 normal pregnant mares (12 mares in 4 years) at our farm (data not published), and those for CTUP and FHR were from our previous report [13]. Values higher (progesterone and CTUP) or lower (estradiol and FHR) than the standard range were regarded as abnormal.

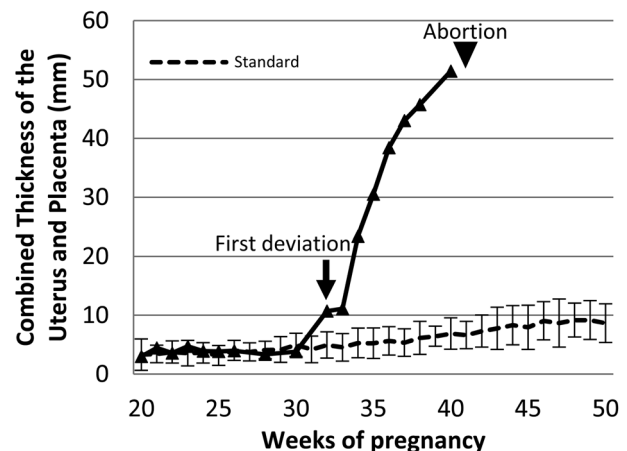
At 32 weeks of pregnancy, abnormal progesterone (5.18 ng/ml, standard range: 1.46–4.17 ng/ml) and CTUP (10.7 mm, standard range: 2.76–7.16 mm) values were observed without any clinical signs (Figs. 1 and 2). Thus, we started administering trimethoprim–sulfamethoxazole. At 34 weeks, vaginal discharge appeared, and *Aspergillus fumigatus* was isolated from uterine cervical swabs (Table 1), so we added tocolytics. The CTUP rapidly increased, and high echogenic pus was observed between the uterine wall and placenta. At 37 weeks, the udder developed, and vaginal discharge increased, so we administered diclofenac sodium. Subsequently, the clinical symptoms subsided, and we gradually decreased the dose of diclofenac sodium (250 to 125 mg) beginning in the 39th week of gestation. FHR decreased from 38 weeks (Fig. 3), and the udder developed further at 40 weeks. The mare aborted at 41 weeks. Red bag delivery (premature placental separation) was observed at abortion. The fetus was already dead when delivered. The fetal crown-rump length was 90 cm, and its body weight was 31 kg. The chorionic membrane around the cervical star was white in color due to calcification, approximately 15 cm toward the cranium, and thick. The allantoic aspect was diffusely bleeding.

*A. fumigatus* was detected repeatedly from uterine cervical swabs (Table 2). Various other bacteria were also detected after 35 weeks of pregnancy, but they were inconsistently detected. *Streptococcus suis*, *Escherichia coli*, and *A. fumigatus* were detected from placenta and uterine cervix swabs when the mare aborted. Histopathologically, mycelia positive for anti-*Aspergillus* sp. antibody (AbD Serotec) and Grocott staining were observed in the placenta (Fig. 4). No microorganisms such as bacteria, fungi, or equine herpesvirus were detected in fetal organs or gastric contents.

While clinical signs (vaginal discharge) appeared at



**Fig. 1.** Plasma progesterone and estradiol levels in the aborting mare and normal pregnant mares. A) Progesterone levels continuously increased after the middle of the 20th week of pregnancy and were abnormal from 32 weeks of pregnancy (arrow). B) Estradiol levels decreased after 33 weeks of pregnancy but were within the standard range. The standard ranges are shown by a dotted line and gray area. The dotted line represents the mean  $\pm$  2SD values (unpublished data), and the gray area is based on the cutoff value reported by Shikichi *et al.*

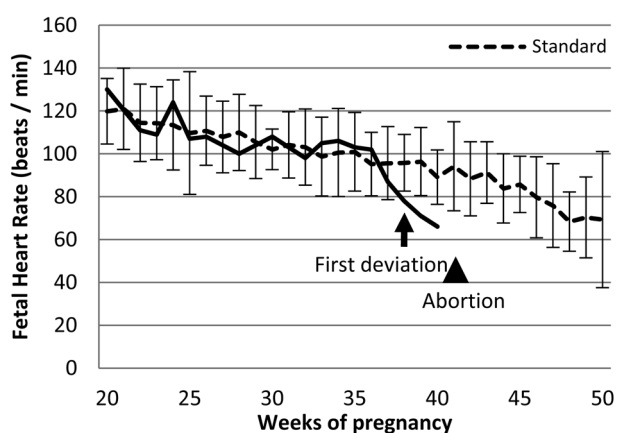


**Fig. 2.** Development of the combined thickness of the uterus and placenta (CTUP) in the aborting and normal pregnant mares. CTUP was thicker from 32 weeks of pregnancy (arrow). The standard range was calculated as the mean  $\pm$  2SD.

**Table 1.** History of clinical signs, examinations, and treatment

Weeks of pregnancy	Clinical signs	Examination results						Treatment			
		CTUP	FHR	WBC	SAA	P4	E2	TMP/SMX	RTD	MPA	DIC
30		3.8	108			3.73	489				
31						4.91	400				
32		10.7	98	8,900	0	5.18	402	Start			
33		11.1	105	8,700	0	5.05	516				
34	Vaginal discharge	23.4	106	7,800	0	5.86	451		Start	Start	
35		30.5	103	6,100	0.8	5.36	363				
36		38.4	102	10,000	288.1	6.47	261				
37	Udder development Vaginal discharge	43	87	7,800	28.3	7.78	128				Start (500 mg)
38	Discharge disappeared	45.7	78	6,800	0	8.1	217				250 mg
39			71	8,600	0	8.64	85.3				125 mg
40	Udder development	51.4	66	9,500	0	13.7	60.8				500 mg
41	Abortion										

Gray shaded areas show abnormal values or administration period. TMP/SMX: Trimethoprim-sulfamethoxazole; RTD: Ritodrine hydrochloride; MPA: Medroxyprogesterone; DIC: Diclofenac sodium.



**Fig. 3.** Changes of fetal heart rate (FHR) in the aborting and normal pregnant mares. FHR was decreased from 37 weeks of pregnancy and decreased to below the standard range (arrow), calculated as mean  $\pm$  2SD, from 38 weeks.

34 weeks of pregnancy, the progesterone level and CTUP were abnormal at 32 weeks. An increase in SAA values and a decrease in FHR were observed at 36 and 38 weeks, respectively. The WBC count was normal until abortion.

Although the pathogens differed between this report and previous studies of experimentally induced bacterial placentitis [2, 5, 8, 12], there were some similarities, such as changes in progesterone, estradiol, and CTUP, and differences, such as changes in SAA and FHR.

Endocrinologically, the progesterone level was higher than normal at 32 weeks of pregnancy and higher than the cutoff value calculated by Shikichi *et al.* [19] based on abnormal pregnancies at 29 weeks. In addition, the onset of

increase was at 26 weeks. These serial changes may indicate the gradual progress of the pathological condition in natural infection. The cutoff value was irregular; for example, the value at 221–240 days of pregnancy was higher than those at 241–260 days and 261–280 days. So the progesterone level in this case was over the cutoff value at 29 weeks and then back in the normal range at 30 and 32–35 weeks of pregnancy. The estradiol levels were within the normal range but showed changes different from those observed in normal pregnant mares, decreasing from 31 to 32 weeks of pregnancy. These levels recovered at 33 weeks but continued to decrease again after 34 weeks. Estradiol stayed within the normal range because the standard range for it was broad due to large individual differences in the normal pregnant mares. Conversely, the estradiol level reached a value below the cutoff value [19] at 37 weeks, suggesting that the drop in estradiol level heralded abortion.

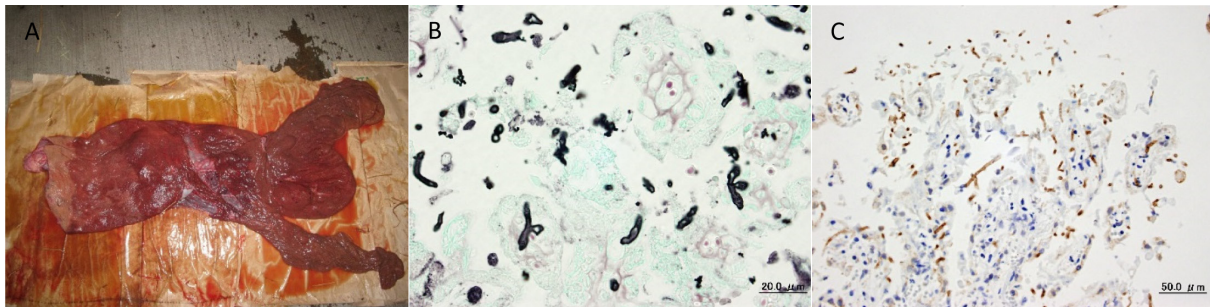
In experimentally induced placentitis, an increased CTUP was observed 3 days after *Streptococcus zooepidemicus* inoculation [2]. In the present case, the CTUP continued to rise beginning at 32 weeks of pregnancy.

SAA was reported to be a useful diagnostic marker for placentitis based on the results of experimentally induced ascending bacterial placentitis [5, 8]. In experimentally induced ascending placentitis, clinical signs appeared after 24 hr of inoculation, and SAA increased after 48 hr of inoculation without treatment [8]. In this study, however, the increase of SAA was only temporary. The reason for this is unclear, but the increase may indicate a second bacterial infection because it coincided with the first detection of bacteria by uterine cervical swab, despite the fact that SAA did not increase with the first fungal infection. Experimentally induced placentitis is also associated with the elevation

**Table 2.** Microbiological findings from cervical swabs

Weeks of pregnancy (Days of pregnancy)	34 (240)	35 (242)	35 (245)	36 (251)	37 (260)	38 (266)	39 (273)	40 (280)	41 (285)	41 (289)	42 (293)	43 (301)
Vaginal discharge	+	+	+	+	+	-	-	-	-	-	-	-
Fungus												
<i>Aspergillus fumigatus</i> *	NA	NA	NA	NA	NA	-	-	NA	NA	-	-	-
<i>Penicillium</i> sp.*	-	-	-	-	-	-	-	NA	-	-	-	-
Gram-positive bacterium												
$\alpha$ -hemolytic <i>Streptococcus</i> sp.	-	-	-	+++++	-	-	-	-	-	-	-	-
<i>Staphylococcus</i> sp.	-	-	-	-	+++	+	-	-	-	++++	-	-
<i>Bacillus</i> sp.	-	-	-	-	+++	-	-	-	-	-	-	-
<i>Streptococcus suis</i>	-	-	-	-	-	-	+++++	-	+++++	-	-	-
<i>Propionibacterium acnes</i>	-	-	-	-	-	-	-	-	-	+++++	-	-
Gram-negative bacterium												
Enterobacteriaceae	-	-	-	-	+++	-	-	-	-	-	-	-
Gram-negative anaerobe	-	-	-	-	++++	-	-	-	-	-	-	-
Gram-negative facultative anaerobe	-	-	-	-	++++	-	-	-	-	-	-	-
<i>Escherichia coli</i>	-	-	-	-	-	++++	-	-	+++++	+++	-	-
<i>Bacteroides fragilis</i>	-	-	-	-	-	+++	-	-	-	-	-	-
<i>Gardnerella vaginalis</i>	-	-	-	-	-	-	-	+++++	-	-	-	-

The number of colonies (CFU/ml) is indicated as follows: -: 0; +: 1–10; ++: 11–100; +++: 101–1,000; ++++: 1,001–10,000; +++++: 10,001 and more. \*Bacterial counting for the organism was not applicable. NA indicates that the sample was positive but that colonies could not be counted.



**Fig. 4.** Gross (A), Grocott staining (B) and immunohistochemical staining (C) images of the placenta. The chorionic aspect around the cervical star was white in color approximately 15 cm toward the cranium, and the wall was thick. Mycelia positive for Anti-*Aspergillus* sp. antibody and Grocott staining were observed in the chorionic tissue.

of other biomarkers in the maternal plasma [6].

In experimentally induced ascending placentitis, there was no difference in FHR between induced and control mares [2]. In our case, the FHR fell below the standard range at 38 weeks of pregnancy (12 days before abortion). In normal fetal development, the FHR declines toward delivery [4, 13, 14]. Fetal bradycardia is often a result of central nervous system (CNS) depression because of hypoxia [4] and has been associated with a poor outcome in pregnant mares [1].

In conclusion, we reported a case of natural fungal placentitis monitored consecutively by microbiological and biochemical analyses. We did not perform any in-depth

comparisons of this case with experimental models because the pattern of infection and the pathogens were different. Progesterone and CTUP appeared to be abnormal before the onset of clinical signs. Additionally, SAA and the FHR also exhibited abnormal values prior to abortion. In this case, the cutoff value shows abnormal prior to the standard range, calculated as the mean  $\pm$  2SD, but the usefulness of the cutoff value was controversial. Blood hormone levels started to change gradually within the standard range before the onset of clinical signs. For early diagnosis of placentitis, it may be important to focus on individual changes in progesterone or estradiol levels in the individual mare.

## References

1. Adams-Brendemuehl, C., and Pipers, F.S. 1987. Antepartum evaluations of the equine fetus. *J. Reprod. Fertil. Suppl.* **35**: 565–573. [[Medline](#)]
2. Bailey, C.S., Heitzman, J.M., Buchanan, C.N., Bare, C.A., Sper, R.B., Borst, L.B., Macpherson, M., Archibald, K., and Whitacre, M. 2012. B-mode and Doppler ultrasonography in pony mares with experimentally induced ascending placentitis. *Equine Vet. J. Suppl.* **43**: 88–94. [[Medline](#)] [[CrossRef](#)]
3. Bailey, C.S., Macpherson, M.L., Pozor, M.A., Troedsson, M.H., Benson, S., Giguere, S., Sanchez, L.C., Leblanc, M.M., and Vickroy, T.W. 2010. Treatment efficacy of trimethoprim sulfamethoxazole, pentoxifylline and altrenogest in experimentally induced equine placentitis. *Theriogenology* **74**: 402–412. [[Medline](#)] [[CrossRef](#)]
4. Bucca, S., Fogarty, U., Collins, A., and Small, V. 2005. Assessment of fetoplacental well-being in the mare from mid-gestation to term: transrectal and transabdominal ultrasonographic features. *Theriogenology* **64**: 542–557. [[Medline](#)] [[CrossRef](#)]
5. Canisso, I.C., Ball, B.A., Troedsson, M.H., Cray, C., Davolli, G.M., Squires, E.L., and Williams, N.M. 2014. Acute phase proteins and total leukocyte counts in blood of mares with experimentally induced ascending placentitis. *J. Equine Vet. Sci.* **34**: 215. [[CrossRef](#)]
6. Canisso, I.F., Ball, B.A., Scoggin, K.E., Squires, E.L., Williams, N.M., and Troedsson, M.H. 2015. Alpha-fetoprotein is present in the fetal fluids and is increased in plasma of mares with experimentally induced ascending placentitis. *Anim. Reprod. Sci.* **154**: 48–55. [[Medline](#)] [[CrossRef](#)]
7. Carrick, J.B., Begg, A.P., Perkins, N., and O'Meara, D. 2010. Ultrasonographic monitoring and treatment of pregnant mares at risk for placentitis. *Anim. Reprod. Sci.* **121**(Suppl.): 331–333. [[CrossRef](#)]
8. Coutinho da Silva, M.A., Canisso, I.F., MacPherson, M.L., Johnson, A.E., and Divers, T.J. 2013. Serum amyloid A concentration in healthy periparturient mares and mares with ascending placentitis. *Equine Vet. J.* **45**: 619–624. [[Medline](#)] [[CrossRef](#)]
9. Giles, R.C., Donahue, J.M., Hong, C.B., Tuttle, P.A., Petrites-Murphy, M.B., Poonacha, K.B., Roberts, A.W., Tramontin, R.R., Smith, B., and Swerczek, T.W. 1993. Causes of abortion, stillbirth, and perinatal death in horses: 3,527 cases (1986–1991). *J. Am. Vet. Med. Assoc.* **203**: 1170–1175. [[Medline](#)]
10. Haneda, S., Nagaoka, K., Nambo, Y., Kikuchi, M., Nakano, Y., Matsui, M., Miyake, Y., Macleod, J.N., and Imakawa, K. 2009. Interleukin-1 receptor antagonist expression in the equine endometrium during the peri-implantation period. *Domest. Anim. Endocrinol.* **36**: 209–218. [[Medline](#)] [[CrossRef](#)]
11. Macpherson, M.L. 2005. Treatment strategies for mares with placentitis. *Theriogenology* **64**: 528–534. [[Medline](#)] [[CrossRef](#)]
12. Morris, S., Kelleman, A.A., Stawicki, R.J., Hansen, P.J., Sheerin, P.C., Sheerin, B.R., Paccamonti, D.L., and LeBlanc, M.M. 2007. Transrectal ultrasonography and plasma progesterin profiles identifies fetoplacental compromise in mares with experimentally induced placentitis. *Theriogenology* **67**: 681–691. [[Medline](#)] [[CrossRef](#)]
13. Murase, H., Endo, Y., Tsuchiya, T., Kotoyori, Y., Shikichi, M., Ito, K., Sato, F., and Nambo, Y. 2014. Ultrasonographic evaluation of equine fetal growth throughout gestation in normal mares using a convex transducer. *J. Vet. Med. Sci.* **76**: 947–953. [[Medline](#)] [[CrossRef](#)]
14. Nagel, C., Aurich, J., and Aurich, C. 2010. Determination of heart rate and heart rate variability in the equine fetus by fetomaternal electrocardiography. *Theriogenology* **73**: 973–983. [[Medline](#)] [[CrossRef](#)]
15. Ousey, J.C. 2006. Hormone profiles and treatments in the late pregnant mare. *Vet. Clin. North Am. Equine Pract.* **22**: 727–747. [[Medline](#)] [[CrossRef](#)]
16. Reef, V.B., Vaala, W.E., Worth, L.T., Sertich, P.L., and Spencer, P.A. 1996. Ultrasonographic assessment of fetal well-being during late gestation: development of an equine biophysical profile. *Equine Vet. J.* **28**: 200–208. [[CrossRef](#)]
17. Renaudin, C.D., Gillis, C.L., Tarantal, A.F., and Coleman, D.A. 2000. Evaluation of equine fetal growth from day 100 of gestation to parturition by ultrasonography. *J. Reprod. Fertil. Suppl.* **56**: 651–660. [[Medline](#)]
18. Renaudin, C.D., Troedsson, M.H., Gillis, C.L., King, V.L., and Bodena, A. 1997. Ultrasonographic evaluation of the equine placenta by transrectal and transabdominal approach in the normal pregnant mare. *Theriogenology* **47**: 559–573. [[Medline](#)] [[CrossRef](#)]
19. Shikichi, M., Iwata, K., Ito, K., Murase, H., Sato, F., Korosue, K., Nagata, S., and Nambo, Y. 2014. Diagnosis of abnormal pregnancy by serum progesterins and estrogens in late pregnant mares. *J. Equine Vet. Sci.* **34**: 231–233. [[CrossRef](#)]