

Knotless Suture Anchor Repair of Anterolateral Meniscus Root After Iatrogenic Injury



Colin M. Robbins, B.A., Colin P. Murphy, B.A., Blake T. Daney, M.D., Anthony Sanchez, B.S., and CAPT Matthew T. Provencher, M.D., M.C., U.S.N.R.

Abstract: In recent years there has been increased attention on preserving the menisci because they perform vital roles in maintaining knee joint homeostasis. The anterolateral (AL) meniscal root is particularly vulnerable during anterior cruciate ligament reconstruction. When the AL root is iatrogenically injured, it is imperative that it is repaired in a timely fashion to prevent early-onset osteoarthritis. In this article we outline our knotless suture anchor repair for AL root tears.

The menisci are crescent-shaped fibrocartilaginous wedges that are crucial to the health and longevity of the knee, playing a critical role in distributing loads through the tibiofemoral joint, maintaining joint stability, and supplying nutrition to cartilage.¹⁻³ The meniscal roots anchor to the tibial plateau anteriorly and posteriorly and function to prevent meniscal extrusion and allow the menisci to act as shock absorbers.⁴ Meniscal root tears can be radial or avulsion-type lesions involving the anterior or posterior root of the lateral or medial meniscus and are shown to be biomechanically equivalent to a total meniscectomy causing increased tibiofemoral contact pressure; however, natural knee kinematics are restored after root repair.⁵

Anatomically, the anterolateral (AL) meniscal root attachment inserts deep to the anterior cruciate ligament (ACL) with an average overlap of 88.9 mm², making up 63.2% of the AL root attachment.⁴ An anatomic study using a scanning electron microscope concluded that there is significant overlap of the AL root and ACL insertions superior to their insertion sites on the tibial plateau.⁶ LaPrade et al.⁷ found that those fibers that run deep to the ACL have a significant role in the function of the AL root, and in a study of 12 cadaveric knees undergoing ACL reconstruction, the AL root was iatrogenically injured in all knees. These studies highlight the vulnerability of the AL root during ACL reconstruction. In the setting of iatrogenic injury to the AL root during ACL reconstruction, refixation of the AL root is performed in the same operation.

Techniques to repair the AL root include knotless suture anchor repair, knotted suture anchor repair, and transtibial double-tunnel technique. In this Technical Note, we outline our preferred knotless suture anchor technique for AL root repair. We prefer this method because it allows the surgeon to fixate the AL root on the tibial plateau in a position that does not interfere with the ACL tibial tunnel, while leaving no intra-articular knot stacks that could cause irritation.

Objective Diagnosis

A tear of the AL root is most commonly an iatrogenic injury that occurs during ACL reconstruction. This should be identified and repaired during initial ACL reconstruction, as missed diagnosis leads to pain in the anterior aspect of the knee and tenderness to palpation over the anterior joint line of the lateral meniscus. Tears of the AL root are best visualized on axial, coronal, and/or sagittal magnetic resonance imaging views. The most

From the Steadman Philippon Research Institute (C.M.R., C.P.M., B.T.D., M.T.P.); Steadman Clinic (B.T.D., M.T.P.), Vail, Colorado; and Oregon Health and Science University (A.S.), Portland, Oregon, U.S.A.

The authors report the following potential conflicts of interest or sources of funding: M.T.P. receives support from the American Orthopedic Society for Sports Medicine, American Shoulder and Elbow Surgeons, Arthrex, Arthroscopy, Arthroscopy Association of North America, International Society of Arthroscopy, Knee Surgery, and Orthopaedic Sports Medicine, the Joint Restoration Foundation (Allosource), Knee, Orthopedics, the San Diego Shoulder Institute, SLACK, and the Society of Military Orthopedic Surgeons. Full ICMJE author disclosure forms are available for this article online, as [supplementary material](#).

Received March 8, 2018; accepted April 13, 2018.

Address correspondence to Captain Matthew T. Provencher, M.D., M.C., U.S.N.R., The Steadman Clinic and Steadman Philippon Research Institute, 181 W Meadow Dr, Ste 1000, Vail, CO 81657, U.S.A. E-mail: mprovencher@thesteadmanclinic.com

© 2018 by the Arthroscopy Association of North America. Published by Elsevier. This is an open access article under the CC BY-NC-ND license (<http://creativecommons.org/licenses/by-nc-nd/4.0/>).

2212-6287/18328

<https://doi.org/10.1016/j.eats.2018.04.012>

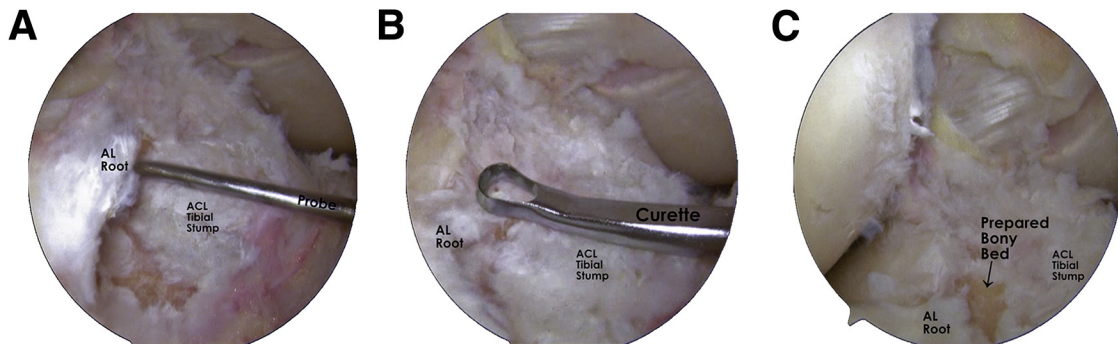


Fig 1. Arthroscopic images of a right knee viewed through the anteromedial portal showing (A) assessment of the detached anterolateral meniscal (AL) root using an arthroscopic probe, (B) use of an open curette to remove tissue on the tibial plateau to prepare the anchor foot bed, and (C) the prepared bony foot bed. Whether iatrogenic injury occurs during anterior cruciate ligament (ACL) stump debridement or tunnel reaming, it is important to make sure the foot bed does not interfere with placement of the tibial tunnel.

reliable magnetic resonance imaging finding of a meniscal root tear is represented by the presence of a “ghost sign”—the absence of an identifiable meniscus on the sagittal or axial sequence.^{2,8} Furthermore, extrusion of the meniscus can be visualized on coronal sections at the level of the medial collateral ligament.^{2,8,9} When patients present with these symptoms and imaging findings following a recent ACL reconstruction, it is recommended that they undergo arthroscopic examination to assess and repair the AL root if necessary.

Surgical Technique

Surgical Indications

When a repairable AL root tear is identified, a knotless suture anchor repair can be performed. Typically, meniscal root repairs are indicated for active patients

with symptomatic extrusion of the meniscus and without advanced arthritis.

Patient Positioning

The patient is placed in the supine position on the operating table. After induction of general anesthesia, a bilateral knee examination is performed to assess for concurrent ligamentous injury and findings compared with the contralateral knee. A well-padded thigh tourniquet is placed on the operative leg, which is then placed into a leg holder (Mizuho OSI, Union City, CA). The contralateral knee is placed in an abduction stirrup (Birkova Products, Gothenburg, NE).

Diagnostic Arthroscopy

Standard anterolateral and anteromedial portals are made, and a diagnostic scope is performed to assess for intra-articular pathology. The 30° arthroscope is then

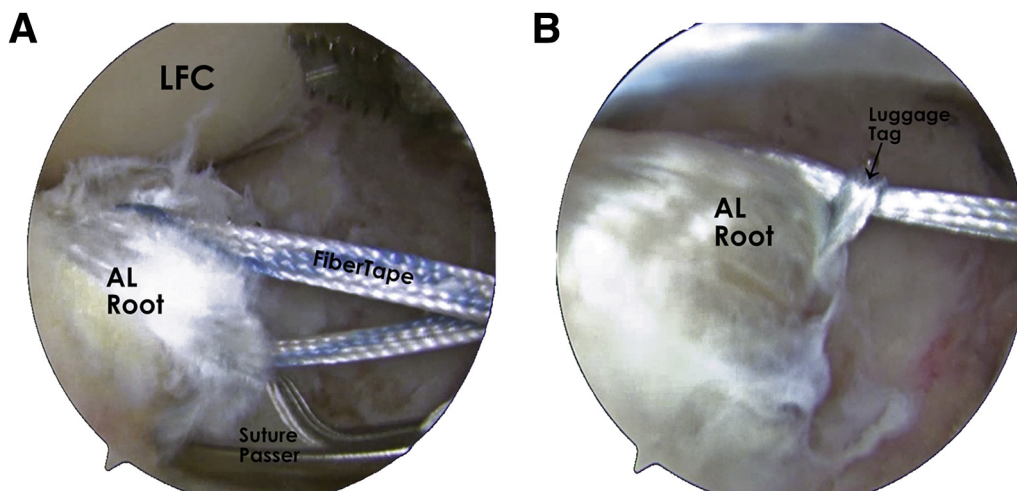


Fig 2. Arthroscopic images of a right knee viewed through the anteromedial portal showing the suture configuration through the anterolateral meniscal (AL) root. (A) Placement of the FiberTape through the AL root; (B) placement of the FiberLink as a luggage-tag construct fixated around the AL root. It is important that there is at least 4 mm of tissue between the suture or tape and the edge of tissue to ensure that the meniscus does not rip. In image B you can see the FiberLink is placed posterior on the AL root as compared with the FiberTape. (LFC, lateral femoral condyle.)

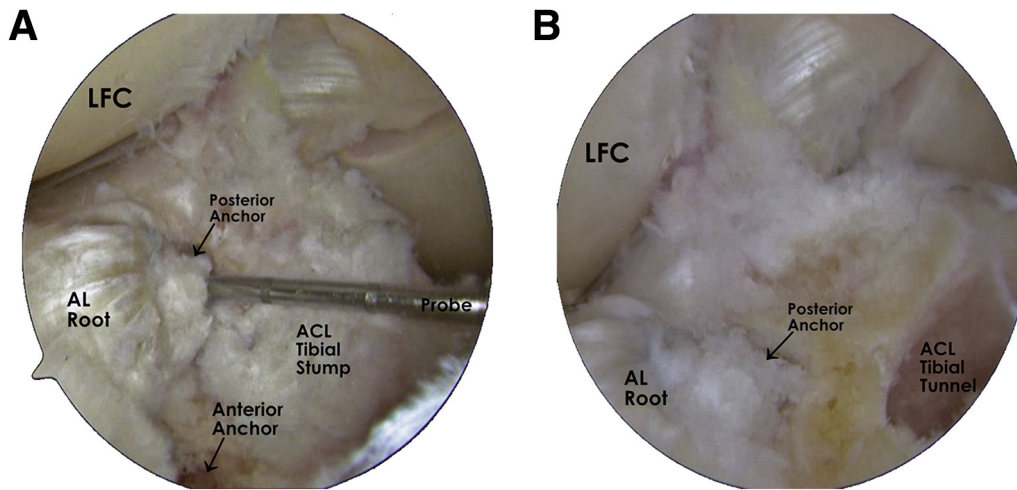


Fig 3. Arthroscopic images of a right knee viewed through the anteromedial portal displaying the final fixation of the anterolateral meniscal (AL) root. Two anchors are placed with FiberLink on the posterior anchor and FiberTape on the anterior anchor. (A) Fixation prior to tibial tunnel reaming; (B) fixation after tunnel reaming. It is important to note that the AL root fixation does not interfere with reaming of the tibial tunnel, so this procedure can be performed before or after tibial tunnel reaming. (ACL, anterior cruciate ligament; LFC, lateral femoral condyle.)

inserted into the anteromedial portal, and a probe is used through the anterolateral portal to assess and confirm the AL root tear.

Knotless Suture Anchor Repair of AL Root

Iatrogenic injury of the AL root occurs in 2 main ways: during debridement of the ACL stump on the tibia or during reaming of the ACL tibial tunnel. In both instances, a knotless suture anchor repair can be performed. We demonstrate a technique that fixates the AL root prior to tibial tunnel reaming, but the ACL tunnel can be reamed prior to performing this technique (Video 1). However, if the root is damaged during ACL tibial tunnel reaming, the AL root foot bed is prepared in a position as close to its anatomic position as possible, while avoiding the tibial tunnel. During the procedure, the arthroscope is placed through the anterolateral portal, while the anteromedial portal is the primary working portal. An open curette is used to prepare the bony bed for the anchor placement (Fig 1)

Table 1. Surgical Pearls

| Surgical Pearls |
|--|
| Ensure that the bony bed for anchor placement is prepared at a spot that does not interfere with anterior cruciate ligament tibial tunnel reaming. |
| Use of a PassPort cannula in the anteromedial portal to prevent suture tangling |
| Aim suture-passing device away from lateral femoral condyles while passing sutures to avoid damaging lateral femoral condyle cartilage. |
| Maintain at least 4 mm between suture and edge of meniscal tissue to avoid tearing. |
| Ensure that knotless anchors are buried at least 1 mm beneath tibial plateau to ensure there is no intra-articular irritation. |

as close to the AL root anatomic footprint as possible, while avoiding the ACL tibial stump, where the tunnel will be reamed. An 8 cm × 3 cm PassPort cannula (Arthrex, Naples, FL) is placed in the anteromedial portal to prevent the formation of soft tissue bridges during suture passage. FiberTape (Arthrex) is loaded onto a Scorpion suture-passing device (Arthrex), and the tape is passed through the lateral meniscus 10 mm anterior to the location of the tear. A no. 2 FiberLink (Arthrex) is loaded onto a Scorpion and then passed through the lateral meniscus posterior to the FiberTape (Fig 2). Care should be taken to maintain at least 4 mm of tissue between the sutures and the tissue edges to avoid ripping. The free end of the FiberLink is passed through its loop end and pulled to create a luggage-tag construct that firmly fixates around the lateral meniscus. A spinal needle is used to assess that appropriate anchor placement can be achieved via the anteromedial portal. If necessary, an accessory anteromedial portal can be made to ensure appropriate placement of the anchor. A 4.75-mm SwiveLock Punch (Arthrex) is used to prepare a hole for placement of a 4.75-mm SwiveLock (Arthrex) anchor. The FiberLink is pulled out of the anteromedial portal with a suture retriever to ensure that it is not tangled with the FiberTape. The free end of the FiberLink is inserted into the SwiveLock eyelet, and the SwiveLock is inserted while holding tension on the FiberLink to ensure appropriate fixation of the root. The anchor is buried beneath the tibial bone surface so there is no intra-articular irritation. The no. 2 FiberWire (Arthrex) preloaded on the SwiveLock is removed, and the FiberLink is cut flush. The second anchor site is prepared in a position anterior to the first anchor. Both free ends of the FiberTape are passed

Table 2. Surgical Risks and Avoidance Strategies

| Surgical Pitfalls | Avoidance Strategy |
|--|--|
| Iatrogenic injury to AL root. Anterior cruciate ligament tibial tunnel reamed at AL root footprint. Shallow angle for anchor placement causing cartilage abrasion. Loss of motion postoperatively. Deep vein thrombosis. | Avoid drilling through AL root with good tibial guide position. Place anchors just lateral to anterior cruciate ligament tunnel. Create a high accessory anteromedial portal to ensure the anchor can be placed at correct angle so that it is buried beneath bone. Implement appropriate range of motion exercises with experienced physical therapist. Use of intraoperative and postoperative prophylaxis as indicated by patient risk factors. |

AL, anterolateral meniscal.

through the eyelet of a second 4.75-mm SwiveLock anchor, and the SwiveLock is inserted with the FiberTape held at tension to ensure proper root fixation. The no. 2 FiberWire preloaded on the SwiveLock is removed, and the FiberTape is cut flush. The AL root is assessed with a probe to ensure satisfactory fixation (Fig 3).

Wound Closure

Excess fluid is drained from the knee, and the wounds are closed with buried 3-0 Monocryl sutures (Ethicon, Somerville, NJ). Steri-Strips (3M, St. Paul, MN) are applied followed by a soft dressing.

Postoperative Recovery and Rehabilitation

After AL root repair with concomitant ACL reconstruction, the patient is placed in a knee immobilizer (Ossur, Reykjavik, Iceland) and remains non-weight bearing for 6 weeks. Physical therapy begins on postoperative day 1 with passive range of motion exercises. Range of motion is restricted at 0° to 90° flexion for the first 6 weeks and then progressed as tolerated. Squat and leg press exercises requiring 70° or more of knee flexion can begin at 12 weeks postop.

Discussion

Our Technical Note provides a detailed description for repair of the AL root due to iatrogenic injury. While literature on the specific biomechanics of AL root tears is limited, there is extensive research showing that posterior meniscal root tears significantly compromise knee homeostasis.^{5,6,8-11} It can be reasoned that similar biomechanical deficiencies will be seen for AL root detachments, and fixation of the root should occur if necessary.

Posterior lateral meniscus root tears often occur during trauma with concomitant ligament tears, while the anterior root is often injured iatrogenically.^{1,8} Steineman and colleagues³ reported early degenerative changes within the synovial fluid, menisci, and tibial subchondral bone in knees where anterior meniscal root tears were left untreated for 8 weeks, indicating that any delay in treatment can significantly alter the natural knee biomechanics.

This knotless suture anchor repair of the AL root provides an option for fixation that is not as technically challenging as the transtibial double-tunnel technique. This can reduce surgery time and the risk of tourniquet-induced nerve injury. This surgical technique is limited by soft bone in the patient, which makes it difficult for an anchor to achieve good purchase. In the case of soft bone, a transtibial double-tunnel technique would be preferred to create adequate fixation of the AL root. Further limitations include limited space on the anterior aspect of the tibial plateau for two 4.75 mm anchors and limited access to AL root. Additional surgical pearls and pitfalls can be found in Tables 1 and 2, respectively.

While more research is still needed to confirm the specific biomechanics and patient outcomes of AL root repair, we recommend use of our surgical technique in the instance of iatrogenic injury to the AL root, and we encourage other groups to critique our presented technique.

References

- Doherty DB, Lowe WR. Meniscal root tears: Identification and repair. *Am J Orthop* 2016;45:183-187.
- Menge TJ, Chahla J, Dean CS, et al. Anterior meniscal root repair using a transtibial double-tunnel pullout technique. *Arthrosc Tech* 2016;5:e679-684.
- Steineman BD, LaPrade RF, Santangelo KS, et al. Early osteoarthritis after untreated anterior meniscal root tears: An in vivo animal study. *Orthop J Sports Med* 2017;5(4):2325967117702452.
- LaPrade CM, Ellman MB, Rasmussen MT, et al. Anatomy of the anterior root attachments of the medial and lateral menisci: A quantitative analysis. *Am J Sports Med* 2014;42:2386-2392.
- Allaire R, Muriuki M, Gilbertson L, Harner CD. Biomechanical consequences of a tear of the posterior root of the medial meniscus: Similar to total meniscectomy. *J Bone Joint Surg Am* 2008;90:1922-1931.
- Steineman BD, Moulton SG, Haut Donahue TL, et al. Overlap between anterior cruciate ligament and anterolateral meniscal root insertions. *Am J Sports Med* 2017;45:362-368.
- LaPrade CM, Smith SD, Rasmussen MT, et al. Consequences of tibial tunnel reaming on the meniscal roots during cruciate ligament reconstruction in a cadaveric

- model. Part 1: The anterior cruciate ligament. *Am J Sports Med* 2015;43:200-206.
8. Bhatia S, LaPrade CM, Ellman MB, et al. Meniscal root tears: Significance, diagnosis, and treatment. *Am J Sports Med* 2014;42:3016-3030.
 9. Kim SB, Ha JK, Lee SW, et al. Medial meniscus root tear refixation: Comparison of clinical, radiologic, and arthroscopic findings with medial meniscectomy. *Arthroscopy* 2011;27:346-354.
 10. Padalecki JR, Jansson KS, Smith SD, et al. Biomechanical consequences of a complete radial tear adjacent to the medial meniscus posterior root attachment site: In-situ pullout repair restores derangement of joint mechanics. *Am J Sports Med* 2014;42:699-707.
 11. Schillhammer CK, Werner FW, Scuderi MG, Cannizzaro JP. Repair of lateral meniscus posterior horn detachment lesions: A biomechanical evaluation. *Am J Sports Med* 2012;40:2604-2609.