

Cite this article as: Abbas S, Purohit M, Cassidy C. Post-mediastinoscopy chylopericardium. *Interact CardioVasc Thorac Surg* 2022;34:1165–7.

## Post-mediastinoscopy chylopericardium

Sherif Abbas \*, Manoj Purohit  and Christopher Cassidy 

Department of Cardiothoracic Surgery and Cardiology, Lancashire Cardiac Centre, Blackpool Teaching Hospital NHS Foundation Trust, Blackpool, UK

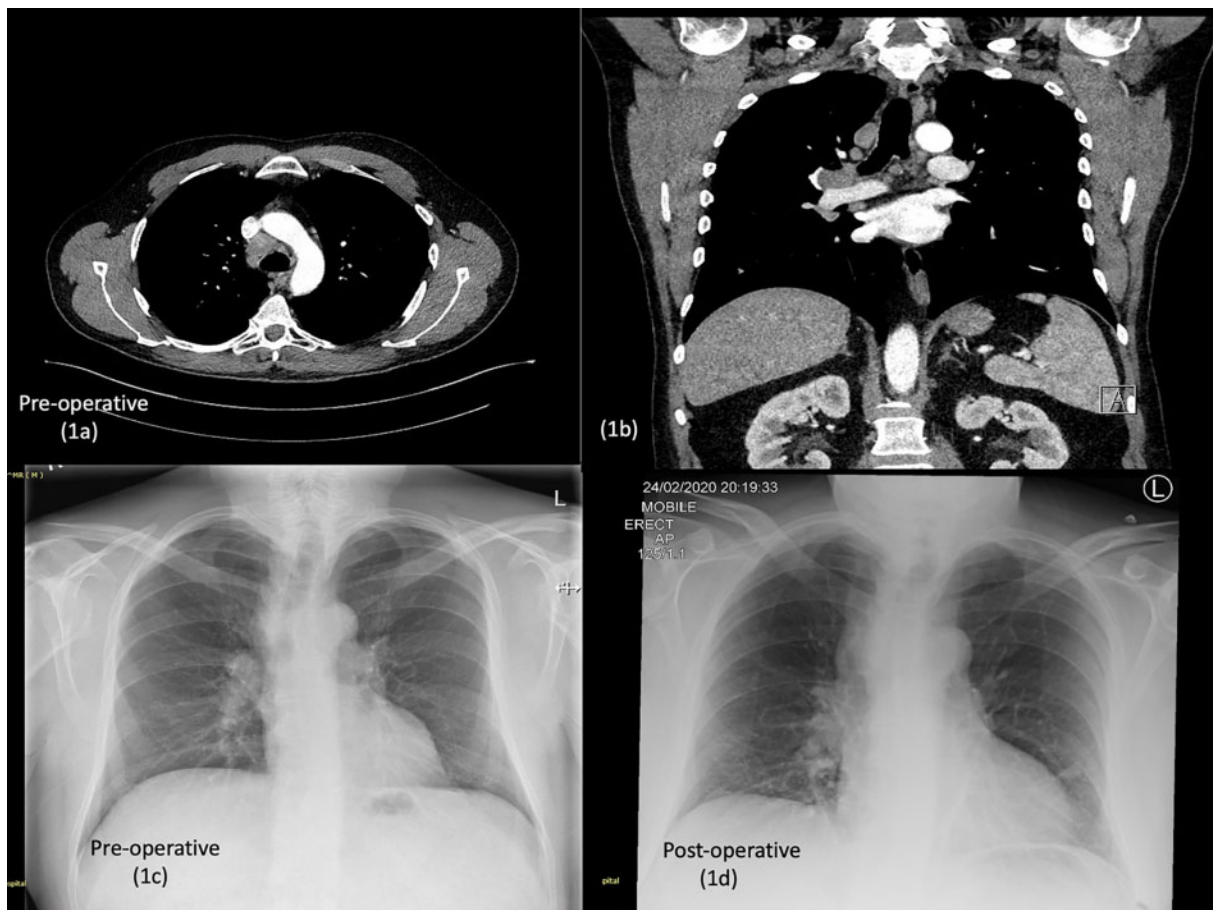
\* Corresponding author. Department of Cardiothoracic Surgery and Cardiology, Lancashire Cardiac Centre, Blackpool Teaching Hospital NHS foundation Trust, Whinney Heys Road, Blackpool FY3 8NR, UK. Tel: 044-7424435388; e-mail: dr.sherif.osama@gmail.com (S. Abbas).

Received 24 July 2021; received in revised form 14 November 2021; accepted 20 November 2021

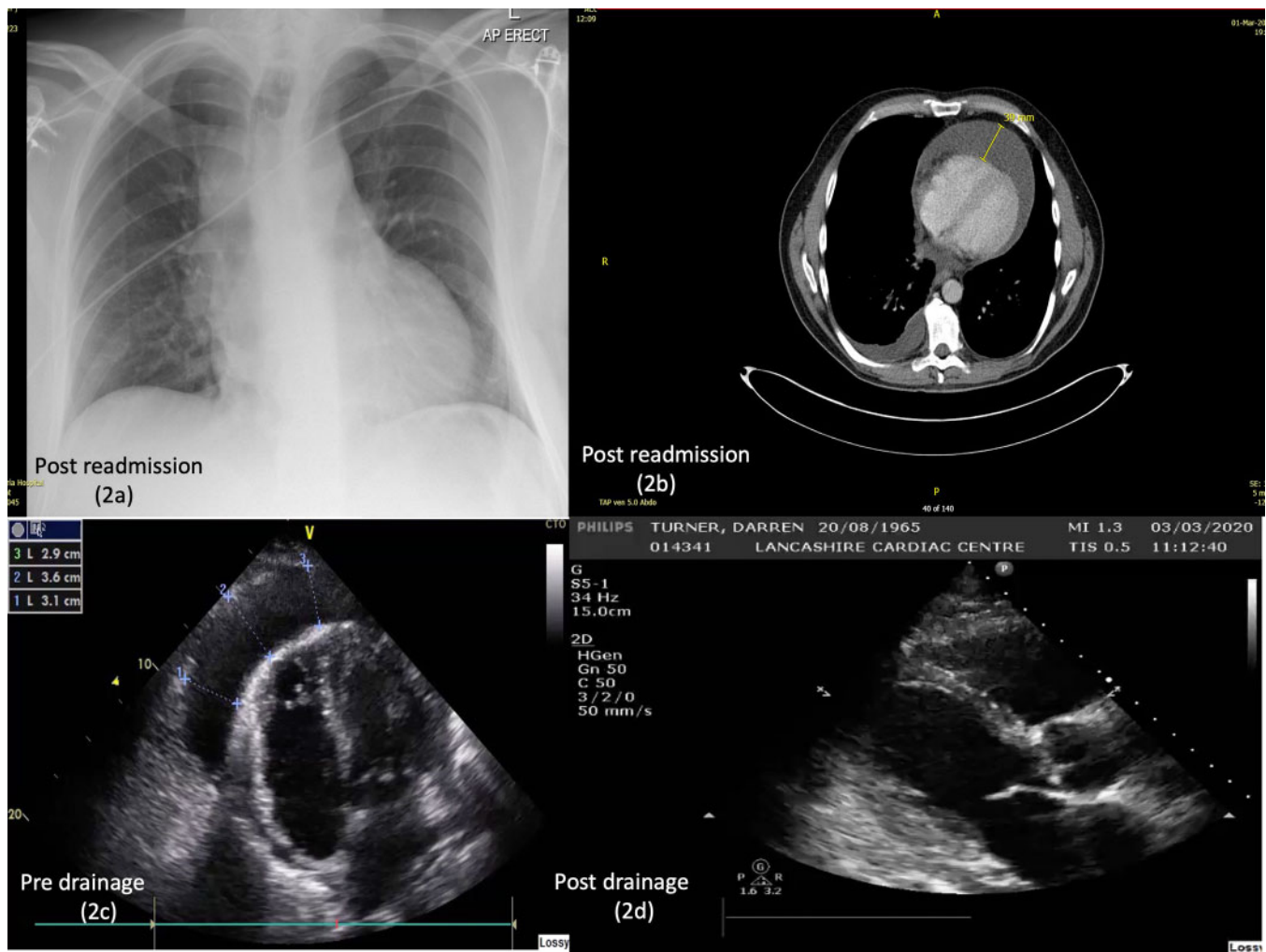
### Abstract

Isolated Chylopericardium (without chylothorax) is a rare clinical disorder that may happen idiopathically or secondary to trauma, radiotherapy, lymphatic anomalies, infections or mediastinal neoplasm. We present a case of middle-aged male with no past medical history of note prior to developing heavy sweating, loss of weight and cough. A series of investigations were done including chest computed tomography which showed enlarged mediastinal lymph nodes leading to uncomplicated mediastinoscopy and lymph node biopsy. Six days after being discharged, he developed dyspnoea and chest pain. Echocardiography revealed massive pericardial effusion. Pericardiocentesis was done and surprisingly revealed milky white chylous fluid. The patient was then successfully managed without the need for further intervention.

**Keywords:** Chylopericardium • Mediastinoscopy • Pericardiocentesis



**Figure 1:** (a,b) CT scan pre-mediastinoscopy showing lymph nodes; (c) CXR pre mediastinoscopy; and (d) CXR post mediastinoscopy.



**Figure 2:** (a) CXR post readmission by pericardial effusion; (b) CT post readmission by pericardial effusion; (c) Echocardiography post readmission by pericardial effusion; and (d) Echocardiography post pericardial drainage.

## BACKGROUND

Chylopericardium is a rare clinical condition in which there is accumulation of chylous fluid in the pericardial sac. Most of the cases happen idiopathically or secondary to cardiac surgery, distortion of thoracic duct drainage either by neoplasms, radiotherapy or injury. It may also happen due to congenital disorders like congenital lymphangiomatosis [1]. Here, we present a case with massive chylous pericardial effusion that developed a few days after mediastinoscopy for lymph node biopsy.

## CASE REPORT

A 54-year-old male, with no past medical history, starts suffering from pain in his right leg and knee while doing his exercises which then developed into swelling and erythema in the same leg. He sought medical advice with a presumptive diagnosis of migratory lymphangitis; ultrasound Doppler scan excluded deep venous thrombosis but possible superficial thrombophlebitis and Dalteparin 5000 units once daily (OD) was prescribed to him. The complaint progressed to heavy sweats, cough and some

weight loss. Haematology referral was done suspecting lymphoma after having chest computed tomography (CT) that showed enlarged right supraclavicular and mediastinal lymph nodes with the largest was the right hilar measuring  $4.5 \times 2.7$  cm (Fig. 1A and B). Clinical examination was unremarkable without any palpable lymph nodes and a bone marrow biopsy did not reveal anything abnormal. The case was discussed in the multi-disciplinary team and referred to thoracic surgery for mediastinoscopy for difficult lymph nodes access through CT guided biopsy or by Ear, Nose and Throat surgical team.

A Mediastinoscopic lymph node biopsy for stations 2R and 4R was done without any complications and the patient discharged safely on the next day after having Chest X-ray (CXR) which was unremarkable from preoperative one (Fig. 1C and D). Histological analysis of the biopsies showed granulomatous inflammation with no incidence of lymphoma.

Six days after discharge, the patient presented to the emergency department with dyspnoea, vomiting and chest pain. Blood samples showed deranged liver and kidney functions, CXR and chest CT suspected a pericardial effusion (Fig. 2A and B) for which a bedside echocardiography was performed. A global pericardial effusion with the largest point 4.2 cm at the right ventricular free wall (Fig. 2C) was identified.

Multi-disciplinary team discussion between the radiology, cardiology and thoracic surgery teams recommended percutaneous pericardiocentesis. The drain was inserted successfully after admitting the patient to the critical care unit. Six hundred millilitres of milky white fluid drained initially and then minimal volume in the following days. Biochemistry of the drained fluid revealed triglycerides of 1.4 mmol (>1.24 mmol diagnostic).

The drain left *in situ* for 5 days during which dietician consulted who recommended fat-free diet and Octreotide.

After 5 days, the patient's condition stabilized, drain removed after an Echocardiogram (Fig. 2D) to rule out any residual pericardial collection and diet management has been stopped on discharge. The patient was discharged safely and remained asymptomatic at 16 weeks of follow-up clinic.

## DISCUSSION

Regardless the cause of Chylopericardium, conservative management is the first line of treatment including pericardiocentesis, middle chain triglycerides diet and Octreotide administration. This is mainly to relief symptoms and prevents cardiac tamponade. Surgical management which includes pericardial window and thoracic duct ligation is preserved for resistant cases. Also, there is thoracic duct embolization for patients who are unfit for surgery [1].

In our case, the first aim was to relief the patient's symptom with the least invasive procedure, so pericardiocentesis was done first which showed milky white fluid. The differential diagnosis for this fluid was either pus or chyle, but infection was ex-

cluded as the patient did not present with any signs of infection in terms of fever, increased inflammatory markers or infected wound, so that's why we did not do culture for the fluid. The laboratory finding of the fluid showed high triglycerides 1.4 mmol which is diagnostic to chyle as if the level is more than 1.24 there is 99% of this fluid to be chyle without further laboratory investigations [2]. The right-sided pleural effusion in the CT was not sampled as it was very minimal that did not appear in the CXR and did not increase in the follow-up CXRs as well.

To our knowledge, this is the first case report to be published on isolated Chylopericardium as a complication after cervical mediastinoscopy. The patient was managed in line with the same plan of idiopathic and post-cardiac surgery cases with success for a follow-up period of 16 weeks.

**Conflict of interest:** There was no funding either directly or indirectly to this case report.

## Reviewer information

Interactive CardioVascular and Thoracic Surgery thanks Ayten Kayi Cangir, Ludwig Lampl and the other anonymous reviewers for their contribution to the peer review process of this article.

## REFERENCES

- [1] Yu X, Jia N, Ye S, Zhou M, Liu D. Primary chylopericardium: a case report and literature review. *Exp Ther Med* 2018;15:419–25.
- [2] McGrath EE, Blades Z, Anderson PB. Chylothorax: aetiology, diagnosis, and therapeutic options. *Respir Med* 2010;104:1–8.