



Published in final edited form as:

Am J Med Case Rep. 2019 ; 7(4): 59–61. doi:10.12691/ajmcr-7-4-2.

Cocaine-Induced Brugada Pattern

Mohammed Al-Sadawi¹, Hassan Alkhawam², Angeleque Hartt¹, Aron Soleiman¹, Samy I. McFarlane^{1,*}

¹Department of Internal Medicine, State University of New York: Downstate Medical Center, Brooklyn, New York, United States

²Department of Cardiology, Saint Louis University, Missouri, Saint Louis, United States

Abstract

Background: Brugada phenocopies are clinical entities etiologically distinct from congenital Brugada syndrome; differentiation is crucial for management.

Case: A 29 year-old male with a history of cocaine abuse, brought in by Emergency Medical Services (EMS) after he was found unresponsive and given naloxone. He was found altered but arousable with verbal stimuli. He reported snorting a white powder to get “high”. He denied family history of sudden death or previous history of syncope. His ECG on presentation showed coved, 2 mm ST elevation with T-wave inversion in V2 consistent with Brugada EKG pattern (Figure 1). His troponin was trending up with elevated creatinine 1.6 mg/dl, liver enzymes and lactic acid, and urine toxicology was positive for cocaine.

Decision-making: The presentation of altered mental status is multifactorial: metabolic derangement, drugs misuse and Brugada. Finding Brugada EKG pattern should be investigated to differentiate congenital Brugada syndrome and Brugada phenocopies. This patient has no family history of sudden death and no prior history of syncope. Serial EKG showed a gradual resolution of the coved and ST elevation in V2.

Conclusion: our case demonstrates the importance of careful history taking including family history, as well as serial ECGs and treating the possible underlying etiology such as drugs abuse or electrolytes abnormality. It is also warranted to differentiate between Brugada phenocopies from congenital Brugada syndrome because therapeutic strategies are quite different with each diagnosis.

Keywords

Cocaine; Brugada phenocopy; drug-induced Brugada phenocopy

1. Introduction

Brugada electrocardiographic findings represent a distinct ECG pattern in leads V1-V3 with three different types [1]. When Brugada electrocardiographic pattern is present, it should be investigated to differentiate congenital Brugada syndrome and Brugada phenocopies which defined as clinical conditions associated with Brugada electrocardiographic pattern caused by other factors including myocardial ischemia and metabolic derangements such as hypokalemia; and normalizes after resolution of the associated condition [2]. Differentiation Brugada phenocopies from congenital Brugada syndrome is crucial as the management is different. Here we presented a case of young male with history of recent cocaine use presented with altered mental status and found to have Brugada electrocardiographic pattern type I.

2. Report of the Case

A 29 year-old male with a history of cigarette smoking and cocaine use, brought in by Emergency Medical Services (EMS) from a correctional facility after he was found unresponsive, he was given naloxone and brought to Emergency Department (ED). In the ED, he was found to have depressed conscious level but arousable with verbal stimuli. His blood pressure and oxygen saturation were initially low after receiving naloxone. The patient reported that he was snorting a white powder in effort to get “high”. He denied chest pain but he stated having chest congestion after he inhaling the white powder. He denied family history of cardiac disease or sudden death, or prior history of syncope. His electrocardiogram showed coved-type, downsloping, 2 mm ST segment elevation with T-wave inversion among lead V2 consistent with Brugada electrocardiographic pattern without ischemic changes (Figure 1A). Laboratory results were notable for troponin I elevated to 0.7 ng/L [Normal <0.04 ng/L] at presentation and increased to 2 ng/L 8 hours later, creatinine 1.6 mg/dl [Normal 0.5–1.2 mg/dl], white blood cells 19,000/cmm 4,000–9,000/cmm], Aspartate Aminotransferase (AST) 449 U/L [Normal 10 to 35 U/L], Alanine Aminotransferase (ALT) 370 U/L [Normal 10 to 42 U/L], lactic acid of 6.2 mmol/L [Normal 0.5–1 mmol/L], pH 7.13 [Normal 7.35–7.45], and urine toxicology was positive for cocaine. Transthoracic echocardiography revealed an estimated ejection fraction of 70% and concentric remodeling of the left ventricle without regional wall motion abnormalities. He was admitted to critical care unit giving these findings. The presentation of altered mental status might be related to metabolic derangement, respiratory failure, active drugs misuse and Brugada. Ischemic work-up didn't show any evidence of supply ischemia. He was treated conservatively with intravenous fluids and electrolytes repletion. Serial EKG showed a gradual resolution of the coved and ST elevation in V2 (Figure 1B).

3. Discussion

Brugada electrocardiographic pattern is a distinct ECG pattern in leads V1-V3 with three types: type I is characterized by coved ST-segment elevation that is 2 mm followed by a down-sloping concave with a negative symmetric T-wave, type II is defined as saddle-back convex ST segment elevation with variable T wave in V1, and type III is similar to type II but with positive or flat T wave in lead V2 [1]. Finding Brugada electrocardiographic pattern

should be investigated to differentiate congenital Brugada syndrome which is an inherited cardiac channelopathy in cardiomyocytes characterized by Brugada electrocardiographic pattern that predisposes to malignant ventricular arrhythmias, particularly ventricular fibrillation, and sudden death; and Brugada phenocopies which defined as clinical conditions associated with Brugada electrocardiographic pattern but elicited by myocardial ischemia, pulmonary embolism, mediastinal compression, and metabolic derangements such as hypokalemia and adrenal insufficiency; and normalizes after resolution of the associated condition with low pretest probability of congenital Brugada syndrome determined by lack of family history and symptoms, and negative provocative test [2]. High clinical pretest probability is defined as a documented personal history of cardiac arrest, recurrent nonvagal syncope or/and family history of sudden cardiac death [1]. Provocative test is done by using sodium channel blocker as ajmaline, flecainide or procainamide to provoke Brugada electrocardiographic pattern which is negative in Brugada phenocopies. Genetic testing for Sodium channel voltage-gated type V alpha subunit (SCN5A) is not mandatory for Brugada syndrome diagnosis as it is only found in 20% to 30% of confirmed Brugada syndrome patients [3].

Acknowledgements

This work is supported, in part, by the efforts of Dr. Moro O. Salifu M.D., M.P.H., M.B.A., M.A.C.P., Professor and Chairman of Medicine through NIH Grant number S21MD012474.

References

- [1]. Bayes de Luna A, Brugada J, Baranchuk A, Borggreffe M, Breithardt G, Goldwasser D, Lambiase P, Riera AP, Garcia-Niebla J, Pastore C, Oreto G, McKenna W, Zareba W, Brugada R, Brugada P. Current electrocardiographic criteria for diagnosis of Brugada pattern: a consensus report. *J Electrocardiol.* 2012 9; 45(5): 433–42. [PubMed: 22920782]
- [2]. Anselm DD, Baranchuk A. Brugada phenocopy: redefinition and updated classification. *Am J Cardiol.* 2013; 111: 453. [PubMed: 23317529]
- [3]. Baranchuk A, Anselm DD. Brugada Phenocopy - More Questions than Answers. In: MacFarlane PW, editor. *Proceedings of the 40th International Congress on Electrocardiology*; 2013 pp. Aug 7–10; Glasgow, Scotland 2013 (In press).

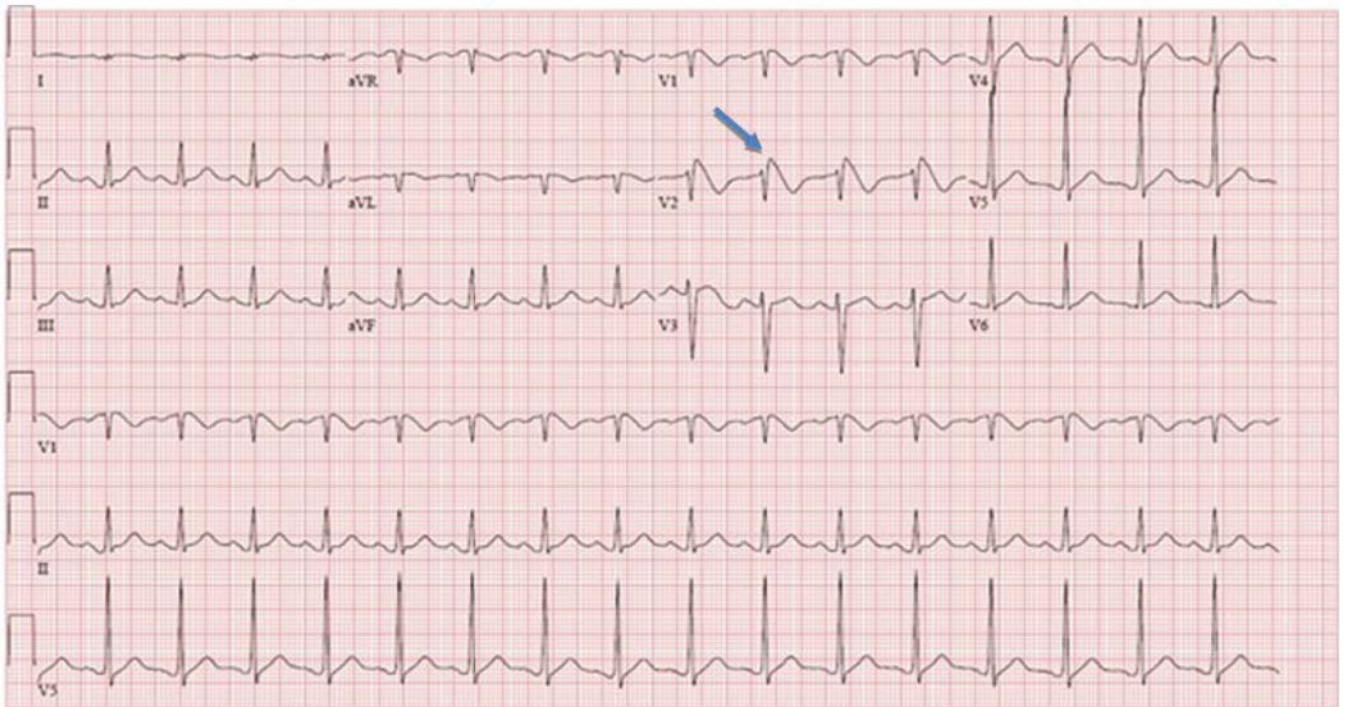


Figure 1A.
EKG on presentation showing coved-type, downsloping, 2 mm ST segment elevation with T-wave inversion among lead V2 consistent with Brugada pattern without ischemic changes

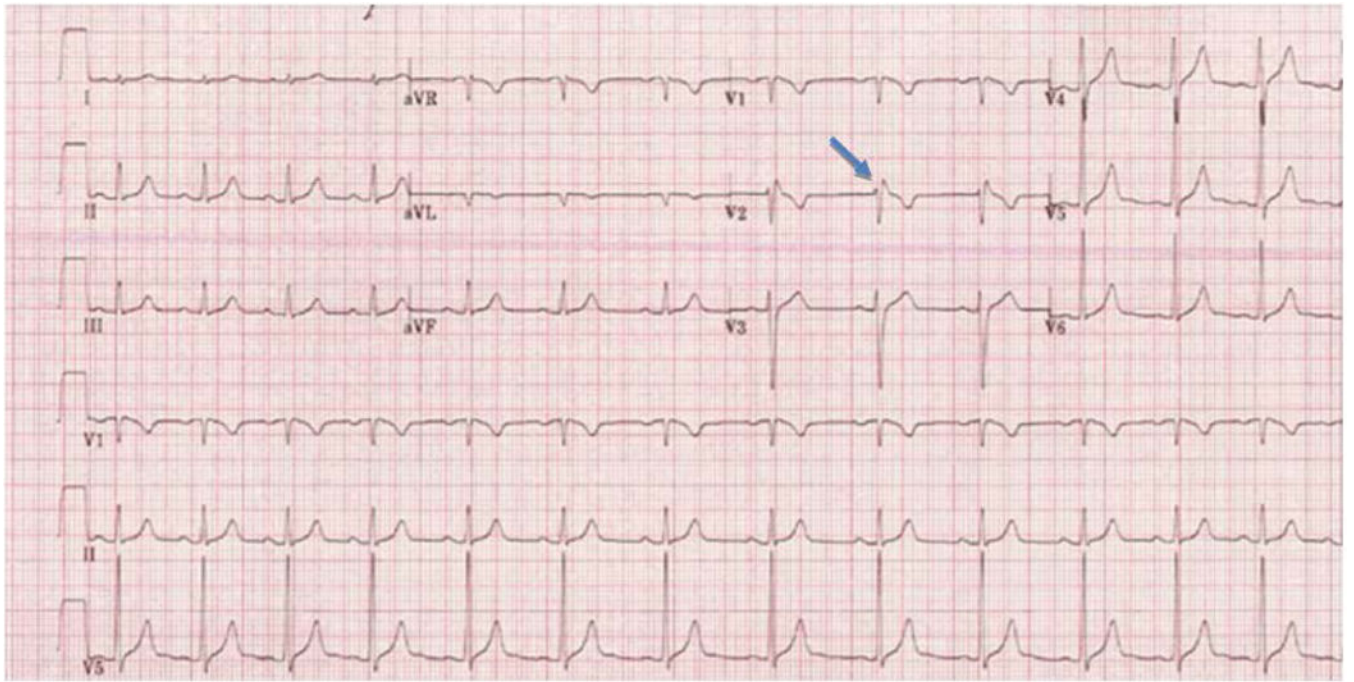


Figure 1B.
EKG few hours after after initial presentation, showing resolution of the Brugada pattern to normalization