

A clinical prospective randomized comparative study on osteosynthesis of mandibular anterior fractures following open reduction using lag screws and miniplates

ABSTRACT

Introduction: The aim of the present study was to compare fixation of mandibular anterior fractures following open reduction using lag screws or miniplates.

Materials and Methods: This prospective study was conducted on 20 patients diagnosed with cases of displaced mandibular anterior fractures treated with open reduction and internal fixation. The patients were then randomly allocated to either of two groups – Group A: two 2.5 mm stainless steel lag screws were placed in 10 patients. Group B: two 2.5 mm miniplates were placed in 10 patients for the fixation of fractures. Subsequent follow-up was done on the 1st day, 1st, 4th, and 36th week postoperatively. During every follow-up, patient was assessed clinically for infection, malocclusion, loosening of plate/screw, malunion/nonunion, and masticatory efficiency. Radiographs (orthopantomogram) were taken preoperative, 1st, 4th, and 36th postoperative week to compare the osteosynthesis between the two groups. Pain was objectively measured using a visual analog scale. The data collected was subjected to unpaired *t*-test and paired *t*-test for statistical analysis.

Result: It was found that lag screw placement was rapid in comparison of miniplate placement. 3rd month postoperative assessment revealed Lag screw group to have better biting efficiency, and better bone healing which was statistically significant when compared with miniplate group.

Conclusion: Our study suggests that lag screw osteosynthesis can be advocated as a valid treatment modality in the management of mandibular symphysis and parasymphysis fractures.

Keywords: Lag screw, mandibular anterior fracture, miniplates

INTRODUCTION

Management of trauma has always been one of the surgical subsets in which oral and maxillofacial surgeons have excelled over the years. Fractures of the mandible are common, and prevalence rates reported by epidemiological studies are between 60% and 81%.^[1] Although there is a wide variance in the reported percentage of fractures of mandible anterior region, aggregate analysis places this at 17% of all the mandibular fractures.^[2]

Given the unique anatomy of the mandible, Champy *et al*.^[3,4] described an ideal osteosynthesis line for the mandibular body which corresponds to the course of tension line at the base of the alveolar process. The directions of forces that are distributed through the anterior mandible vary

with the activity of the mandible. This means that the classical zones of tension on the superior and compression on the inferior surfaces of the mandible are not absolute. Instead, the anterior mandible undergoes shearing and torsional (twisting) forces during functional activities. When a force is directed along the parasymphysis-body region of the

GAURAV MITTAL, ANMOL AGRAWAL, RITESH GARG, SIDDHARTH SHARMA, ABHISHEK RATHI, VISHNU SHARMA


Department of OMFS, Institute of Dental Studies and Technologies, Modinagar, Uttar Pradesh, India

Address for correspondence: Dr. Gaurav Mittal, Department of OMFS, Institute of Dental Studies and Technologies, Modinagar, Uttar Pradesh, India.
E-mail: drgauravmittal@rediffmail.com

This is an open access article distributed under the terms of the Creative Commons Attribution-NonCommercial-ShareAlike 3.0 License, which allows others to remix, tweak, and build upon the work non-commercially, as long as the author is credited and the new creations are licensed under the identical terms.

For reprints contact: reprints@medknow.com

How to cite this article: Mittal G, Agrawal A, Garg R, Sharma S, Rathi A, Sharma V. A clinical prospective randomized comparative study on osteosynthesis of mandibular anterior fractures following open reduction using lag screws and miniplates. *Natl J Maxillofac Surg* 2017;8:110-6.

Access this article online	
Website: www.njms.in	Quick Response Code 
DOI: 10.4103/njms.NJMS_38_17	

mandible, compressive strain develops along buccal aspect, whereas tensile strain develops along the lingual aspect. This produces a fracture that begins in the lingual region and spreads toward the buccal aspect. These vector forces separate the inferior border of the mandible at the site of the fracture. Application of fixation devices must, therefore, take these factors into consideration.^[2] As with other surgical advances, modalities for treatment of mandibular anterior fracture have evolved based on the patients need and scientific advances and disadvantages, side by side comparison of them for repair of mandibular anterior fracture do not exist in the surgical literature.^[3]

Hence, the purpose of this study was to compare the outcomes of osteosynthesis of mandibular anterior fracture by two different modalities of open reduction, i.e., stainless steel lag screw and miniplate. This study aims to compare the clinical and radiologic outcome of the open treatment of the less explored mandibular anterior fracture.

MATERIALS AND METHODS

This is a randomized prospective study conducted on patients who reported in the Department of Oral and Maxillofacial

Surgery, Institute of Dental Studies and Technologies, Modinagar, with diagnosis of anterior mandibular fractures during November 2014–July 2016. All the patients were treated on inpatient basis.

Patients with no significant medical history were involved in the study. The selected cases were treated by open reduction and internal fixation. The study was designed to evaluate the versatility of osteosynthesis in the anterior mandibular fracture, using stainless steel lag screw in comparison with conventional stainless steel miniplate fixation. One group was treated with lag screw and other with miniplates fixation. Inclusion criteria were age > 15 years and noncomminuted unilateral and bilateral isolated fractures of the mandible. Exclusion criteria were comminuted mandibular fractures, panfacial fractures, infected fractures, patients in whom general anesthesia and/or open reduction is contraindicated, and medically compromised patients.

Method and collection of data

Informed consent was obtained in writing from all patients participating in the study. The patients were randomly allocated to either of two groups Group A (osteosynthesis by lag screw fixation) and Group B [Figures 1-4] (osteosynthesis by miniplate fixation) and treated accordingly [Figures 5-8].

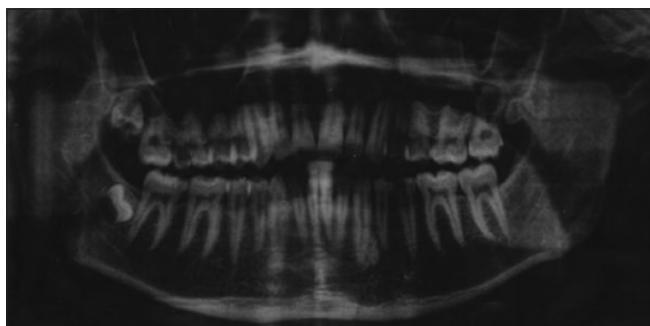


Figure 1: Pre operative opg showing left para symphysis fracture

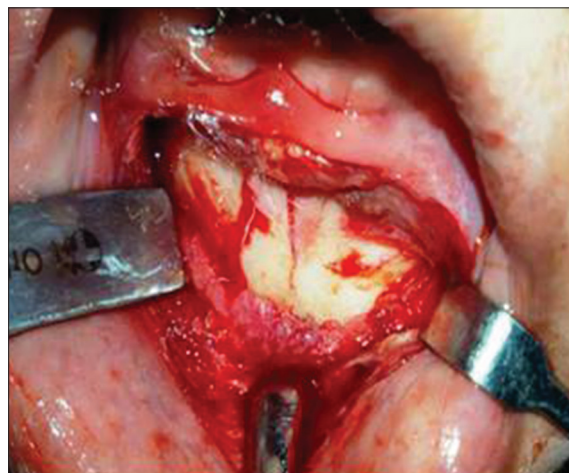


Figure 2: Exposure of fracture site

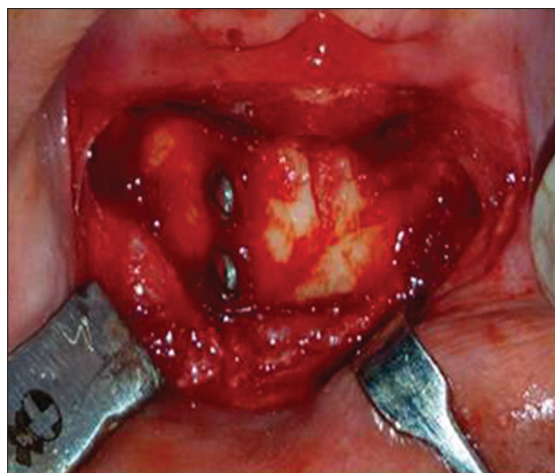


Figure 3: Lag screw placed

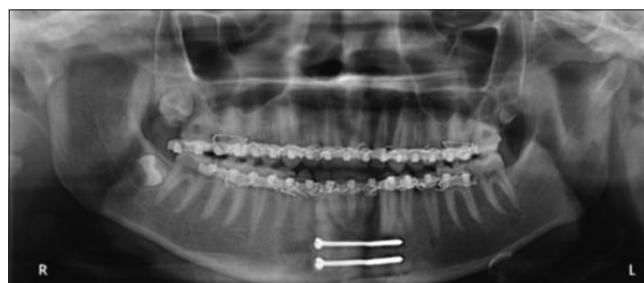

Figure 4: Post op opg with lag screw

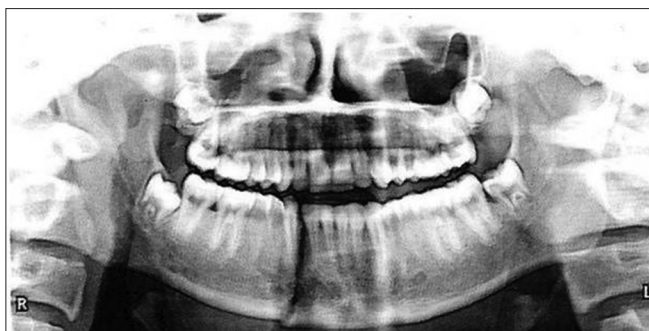

Figure 5: Pre operative showing right para symphysis fracture

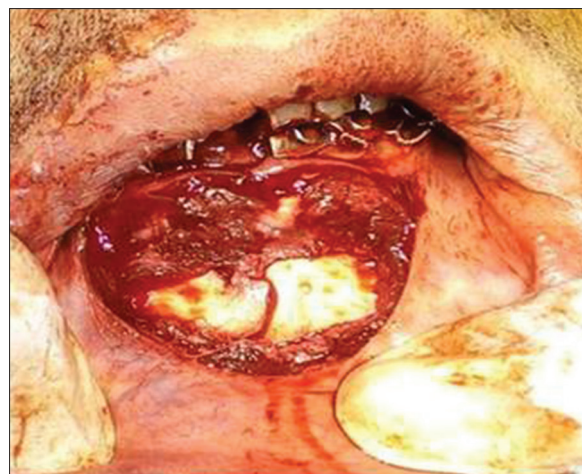


Figure 6: Exposure of fracture site

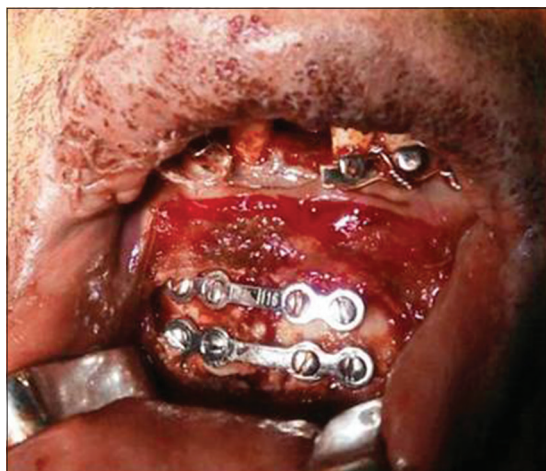

Figure 7: Miniplate fixation

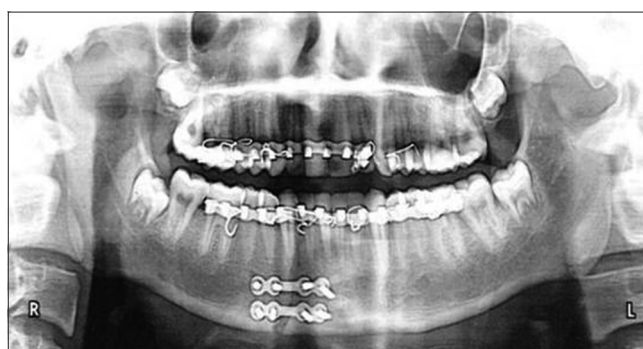

Figure 8: Post op showing miniplate

In all cases, open reduction and internal fixation were performed under general anesthesia.

Variables studied

Surgical duration for miniplate fixation/lag screw placement, occlusion, interincisal mouth opening, facial symmetry, distraction of lower border assessed radiographically, postoperative complications, need for postoperative intermaxillary fixation, biting efficiency.

RESULTS

Pain

Statistically significant difference between both groups was only found in the 1st postoperative week ($P = 0.045$) [Graph 1].

Edema

Statistically significant difference between both groups was only found in 1st postoperative week ($P = 0.05$) [Graph 2].

Interincisal mouth opening

1st week, 1st month, and 3rd month showed the statistically significant result. Values revealed improvement in both

the groups with time, but more improvement was seen in Group A than Group B [Graph 3].

Biting efficiency

There was no statistically significant difference among any period in both groups [Graph 4].

Occlusion

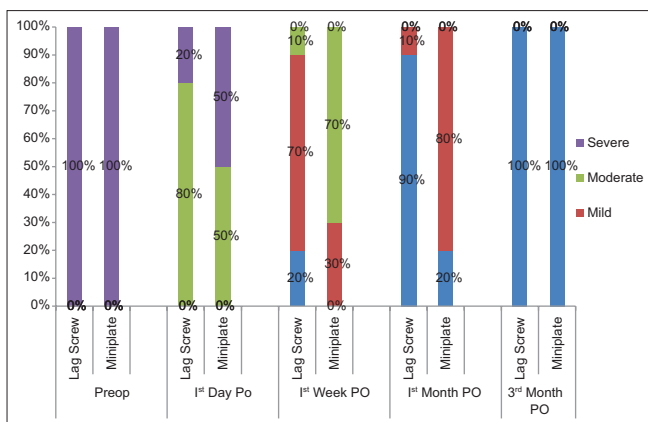
Preoperatively occlusion was dearranged in all the patients, occlusion was obtained by mandibular maxillary fixation using arch bar. There were no occlusal discrepancies throughout the period of 1st postoperative day to 3rd postoperative month in Group A, whereas in Group B, very mild occlusal discrepancies were noted in 4 cases (40%) 1st postoperatively day with $P = 0.171$ and in 3 cases (30%) 1st postoperatively month with $P = 0.317$. There was no statistically significant difference among any period in both groups [Graph 5].

Facial symmetry

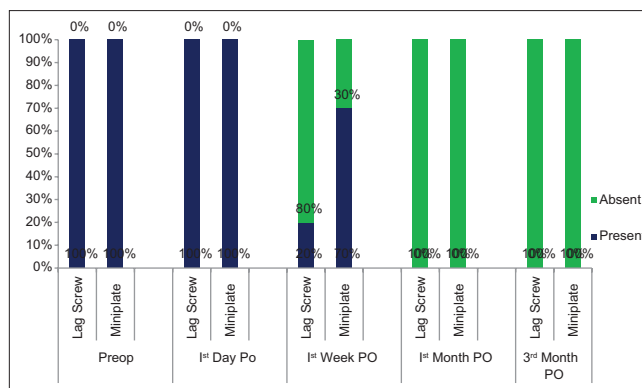
There was no statistically significant difference among any period in both groups [Graph 6].

Time for plate/lag screw placement

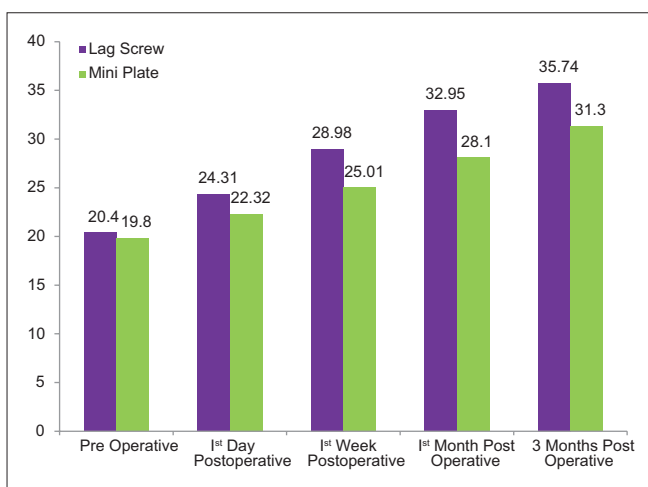
It was found that the mean time taken for implant



Graph 1: Pain-visual analog scale score



Graph 2: Comparison of edema in both the group at different follow-up



Graph 3: Interincisal mouth opening

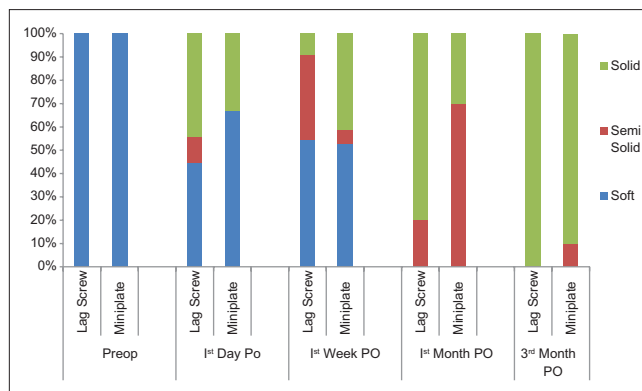
placement in Group A (13.34 ± 1.95) was less than the mean time taken for implant placement in the Group B (17.50 ± 2.24), which was highly significant ($P = 0.048$) [Graph 7].

Complication

Wound dehiscence, infection, paraesthesia, non-/mal-union, implant exposure, mobility at mentioned specific follow-up interval. On the whole, the complication rate was statistically significant on the 1st postoperative day and 1st postoperative week ($P = 0.025$). At 1st month and 3rd month postoperative, no complication was seen in both the groups [Graph 8].

Assessment of bone healing at fracture site

On comparative analysis of 3rd postoperatively month, no case was noted with radiolucent line in Group A, whereas statistically significant result was noted in Group B 2 (20%) cases with radiolucent gap and 8 cases with the radiolucent line ($P = 0.001$) [Graph 9].

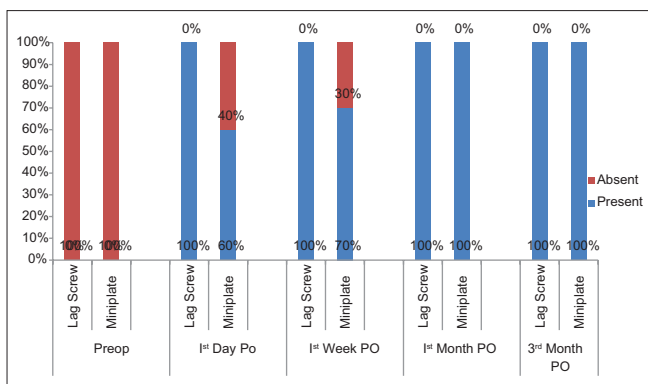


Graph 4: Biting efficiency

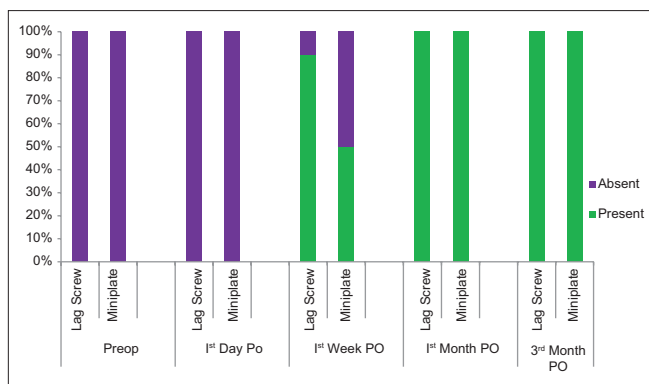
DISCUSSION

The therapeutic goal of fracture management is to restore form and function as soon as possible without any morbidity. The management of mandibular fractures should be guided by AO principles.^[5] This includes restoration of premorbid occlusion along with anatomic reduction of the fractured fragments. This is followed by rigid immobilization which facilitates the healing between the fragments for better healing and hence preventing infection, malunion and/or nonunion. On the other hand, rigid internal fixation obviates the need for maxillomandibular fixation (MMF), meets the principles of fracture management, achieves absolute stability of fracture fragments, and permits primary bone healing by causing interfragmentary compression.^[6] The rigidity of direct fixation can range from a simple osteosynthesis wire across the fracture (i.e., nonrigid fixation) to a miniplate at the area of fracture tension (i.e., semi-rigid fixation) or a compression bone plate (i.e., rigid fixation) to compression screws alone (lag screw).

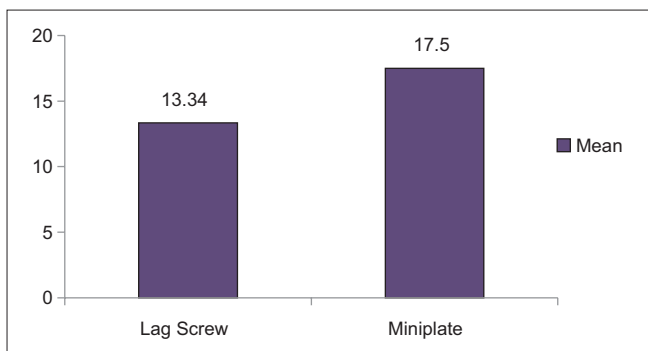
Although there is a universal agreement as to the treatment goals and basic therapeutic principles of reduction, stabilization, and fixation, a variety of currently accepted treatment modalities indicate a lack of consensus.^[7] Hence,



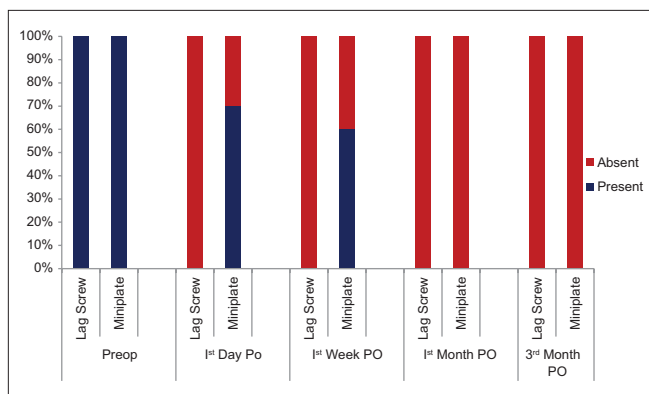
Graph 5: Comparison of occlusion in both groups at different follow-up



Graph 6: Comparison of facial symmetry in both groups at different follow-up



Graph 7: Mean time taken for placement of plate/lag screw



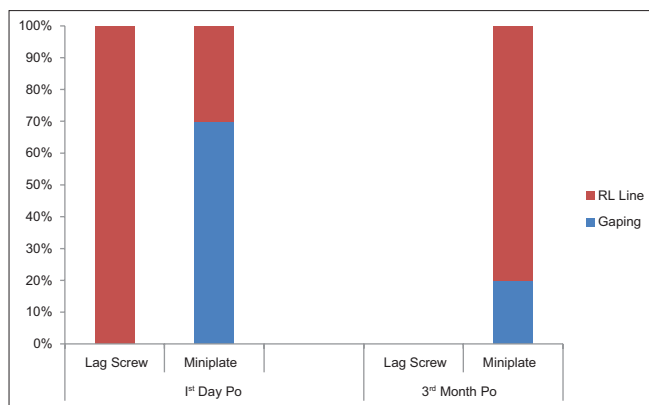
Graph 8: Comparison of complication (%) seen in both the groups

in our study, we compared the efficacy of two load-sharing type of osteosynthesis (by Group A lag screw and by Group B miniplate) in the management of oblique anterior mandibular fracture. Within the mandibular symphysis, the tractional and compressive forces produce torsional movements that increase in strength toward the midline.^[5] Champy *et al.* studied these movements with regard to a mathematical model and as a result was able to determine the ideal line of osteosynthesis to overcome these displacing forces. Champy *et al.*^[5,8] advocated the use of one bone plate in most regions of the mandible except symphysis and parasymphysis region where two bone plates needed which prevents torsional movement in the anterior mandible.

In accordance to Champy’s principle, in our study, two lag screw and two miniplates have been used for treating symphysis and parasymphysis fracture. With this technique, excellent stability and restoration of function of the reduced fracture was achieved. The results of this study, wherein no maxillomandibular fixation was given to supplement symphyseal fractures, go in favor of the retrospective study by Ellis and Ghali.^[9] Kushner and Alpert^[10] stated that most elegant form of stabilization by compression is the use of lag screw fixation in symphysis fractures. The procedure requires minimal time, hardware, and intraoral incisions for the maximum cosmetic benefit. After placing the patient

into MMF with either arch bars or Ernst ligatures, the symphysis is exposed using an anterior mandible vestibular incision (genioplasty incision). Compression can be applied to the fracture using a towel clip or reduction forceps with holes on either side of the fracture. Screws should be at least 30 mm in length (i.e., 15 mm on either side of the fracture). Goyal *et al.*^[11] compared the efficacy and surgical outcome of treatment of anterior mandibular fracture using either 2.0 mm × 4 hole with gap titanium miniplate and 2.4 mm × 26 mm titanium lag screw. They concluded that lag screw fixation of anterior mandibular fracture is a simple and successful method of rigid fixation across fracture segments. Ellis and Ghali^[9] had used lag screws ranging from 12 to 40 mm in length for providing rigid internal fixation of mandibular symphysis and parasymphysis fractures. They stated that lag screw length up to 40 mm should be available before attempting to treat the different site of fracture in the mandible. In the present study, lag screws of lengths 2.5 mm × 24 mm were used for all the patients in Group A, and adequate stability of the fracture was achieved.

In our study, the duration of surgery was measured from the time at incision was placed till the closure of the wound. The mean duration of surgery (hours) was 13.34 ± 1.95 min



Graph 9: Assessment of bone healing at fracture site

in case of lag screw, whereas 17.50 ± 2.24 min in case of miniplate. This difference was found to be statistically significant ($P = 0.048$). Lag screw fixation is relatively quicker as the time-consuming task of plate bending, and adaptation is obviated. There are many advantages of a short surgical procedure as elucidated by various authors such as brief hospitalization and decreased incidence of infectious complications, which significantly lowers the financial burden.^[4,12,13]

Forrest,^[14] who used lag screw fixation in 5 parasymphysis fractures, encountered fractured drill bit in one case. The author relates this complication to the flexibility of the extra long drill bits and the tendency of extra long drill bits to bend when they encounter the inner surface of the distal cortex at an oblique angle. In our study, we did not encounter any intraoperative complications such as fracturing of the drill bit or lag screw. In the study conducted by Ellis and Ghali,^[9] out of 41 patients treated by lag screw fixation, MMF was released postoperatively. They encountered slight mobility of the fracture fragments in one case 3 weeks postoperatively, and it was due to the infected tooth in the line of fracture. In a study conducted by Kallela *et al.*^[15] who used lag screw fixation for seven angle and seventeen parasymphysis fractures. MMF was released postoperatively in all the patients. Out of 23 patients, instability of the fracture fragments in three cases due to infection was encountered. In our study, intraoperatively stability was obtained in all the 20 (100%) cases after fixation. No patients were kept on MMF postoperatively. Two weeks postoperatively, one case (10%) in Group B showed mild mobility due to infection leading to screw loosening, which was treated by MMF for 3 weeks. After 3-month period postoperatively, stability was present in all the 20 (100%) cases.

Their biting efficiency was evaluated, and a general trend toward intake of soft diet was seen in both the groups for the first 2 weeks. On follow-up interval between 1st week to

3 months patients of Group A showed a tendency toward chewing solid food, whereas patients in Group B still had difficulty in chewing solid food items but were able to chew their regular meals.

Good primary stability and improved biting efficiency postoperatively have been also attributed to pain experienced by the patients. Pain score was recorded for all the patients in both the groups on visual analog scale (VAS) during specific follow-up intervals. The pain score reduced in both the groups from preoperative value and was statistically significant. In this study, immediate postoperatively visible radiolucent line was noted in 10 (100%) cases in Group A, whereas in Group B, radiolucent gap was noted in 7 (70%) cases and 3 (30%) cases noted with radiolucent line. On comparative analysis, 3 months postoperatively, no case noted with radiolucent line in Group A, whereas in Group B, 2 (20%) cases noted with radiolucent gap, 4 cases noted with radiolucent line, and rest showed no demarcation. This result shows that rigid internal fixation is associated with primary bone healing. In a study conducted by Kallela *et al.* in patients with only parasymphysis fractures, no neurosensory disturbances were noted before surgery. After surgery, there were 8 (68%) patients who showed neurosensory disturbances due to stretching of the mental nerve and soft tissues during operation.^[15]

There are several different factors that may result in sensory disturbances. Nerve injury can be not only caused by the trauma but also caused by the treatment. During the operative procedure, the nerve may be involved in traction and/compression. Manipulation of fragments during reduction and stabilization of the fracture or extraction of a third molar also could cause injury to the inferior alveolar nerve. In addition, a bicortical screw placed near the mandibular canal might irritate or damage the nerve.^[11,15-17] In our study, no patients had preoperative neurosensory disturbances. Immediate postoperatively, mental nerve paresthesia was encountered with 3 (30%) cases in Group A and 5 (50%) cases in Group B, which resolved postoperatively. 3-month follow-up postoperatively, none of the patients had any signs of paraesthesia. None of the screws used in our study was found to damage inferior alveolar nerve canal radiographically. Hence, we relate our two cases of neurosensory disturbances to stretching of the mental nerve and soft tissues during operation.

CONCLUSION

Lag screw enables the surgeon to achieve optimal stability and function with a minimum of material and time. The possible postoperative complications of an extraoral

approach are avoided, and the length of hospital stay and patient discomfort are drastically reduced. In view of the multiple advantages, it offers the surgeon, anesthesiologists, and patient, and lag screw osteosynthesis can be advocated as a valid treatment modality in the management of mandibular symphysis and parasymphysis fractures. The application of lag screw is a practical, effective, and inexpensive way of treating mandibular anterior fracture. However, very less has been reported about the mechanics and use of lag screws in definite management of maxillofacial trauma in literature. The result of our study provides a firm basis for further studies to be done with larger sample size and longer follow-ups to enhance the application of lag screw osteosynthesis in the management of anterior mandible fractures.

Financial support and sponsorship

Ethical clearance from Institute of Dental Studies and Technologies Institutional Ethical Board.

Conflicts of interest

There are no conflicts of interest.

REFERENCES

1. Agnihotri A, Prabhu S, Thomas S. A comparative analysis of the efficacy of cortical screws as lag screws and miniplates for internal fixation of mandibular symphyseal region fractures: A randomized prospective study. *Int J Oral Maxillofac Surg* 2014;43:22-8.
2. Bhatnagar A, Bansal V, Kumar S, Mowar A. Comparative analysis of osteosynthesis of mandibular anterior fractures following open reduction using 'stainless steel lag screws and mini plates'. *J Maxillofac Oral Surg* 2013;12:133-9.
3. Champy M, Wilk A, Schnebelen JM. Treatment of mandibular fractures by means of osteosynthesis without inermaxillary immobilization according to Michelet technique. *J Maxillofac Oral Surg* 1975;63:339-43.
4. Champy M, Loddé JP, Schmitt R, Jaeger JH, Muster D. Mandibular osteosynthesis by miniature screwed plates via a buccal approach. *J Maxillofac Surg* 1978;6:14-21.
5. Schilli W. Compression osteosynthesis. *J Oral Surg* 1977;35:802-8.
6. Prein J, Kellman RM. Rigid internal fixation of mandibular fractures – Basics of AO technique. *Otolaryngol Clin North Am* 1987;20:441-56.
7. Ajmal S, Khan MA, Jadoon H, Malik SA. Management protocol of mandibular fractures at Pakistan institute of medical sciences, Islamabad, Pakistan. *J Ayub Med Coll Abbottabad* 2007;19:51-5.
8. Ellis E 3rd. Is lag screw fixation superior to plate fixation to treat fractures of the mandibular symphysis? *J Oral Maxillofac Surg* 2012;70:875-82.
9. Ellis E 3rd, Ghali GE. Lag screw fixation of mandibular angle fractures. *J Oral Maxillofac Surg* 1991;49:234-43.
10. Kushner GM, Alpert B. Open reduction and internal fixation of acute mandibular fractures in adults. *Facial Plast Surg* 1998;14:11-21.
11. Goyal M, Jhamb A, Chawla S, Marya K, Dua JS, Yadav S, *et al.* A comparative evaluation of fixation techniques in anterior mandibular fractures using 2.0 mm monocortical titanium miniplates versus 2.4 mm cortical titanium lag screws. *J Maxillofac Oral Surg* 2012;11:442-50.
12. Leonard MS. The use of lag screws in mandibular fractures. *Otolaryngol Clin North Am* 1987;20:479-93.
13. Schwimmer AM, Greenberg AM. Management of mandibular trauma with rigid internal fixation. *Oral Surg Oral Med Oral Pathol* 1986;62:630-7.
14. Forrest CR. Application of minimal-access techniques in lag screw fixation of fractures of the anterior mandible. *Plast Reconstr Surg* 1999;104:2127-34.
15. Kallela I, Ilzuka T, Laine P, Lindqvist C. Lag-screw fixation of mandibular parasymphyseal and angle fractures. *Oral Surg Oral Med Oral Pathol Oral Radiol Endod* 1996;82:510-6.
16. Islamoglu K, Coskunfirat OK, Tetik G, Ozgentas HE. Complications and removal rates of miniplates and screws used for maxillofacial fractures. *Ann Plast Surg* 2002;48:265-8.
17. Tiwana PS, Kushner GM, Alpert B. Lag screw fixation of anterior mandibular fractures: A retrospective analysis of intraoperative and postoperative complications. *J Oral Maxillofac Surg* 2007;65:1180-5.