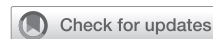

Totally endoscopic, robotic-assisted papillary muscles cryoablation and mitral valve repair



Andrea Amabile, MD,^a Michael LaLonde, MHA, PA-C,^a Syed Usman Bin Mahmood, MBBS,^a Irbaz Hameed, MD,^a Alyssa Morrison, BS,^a Christina Waldron, BS,^a Wei-Guo Ma, MD, PhD,^a Markus Krane, MD,^b and Arnar Geirsson, MD,^a New Haven, Conn, and Munich, Germany

From the ^aDivision of Cardiac Surgery, Department of Surgery, Yale School of Medicine, New Haven, Conn; and ^bDepartment of Cardiovascular Surgery, Institute Insure, German Heart Center Munich, Technical University of Munich, Munich, Germany.

Read at *The American Association for Thoracic Surgery Mitral Conclave Workshop, New York, New York, May 4-5, 2023.*

IRB #2000020356 “Outcomes of Cardiac Surgery” (Approved October 19, 2021).

Informed written consent was obtained.

Received for publication June 17, 2023; revisions received Aug 23, 2023; accepted for publication Sept 16, 2023; available ahead of print Sept 26, 2023.

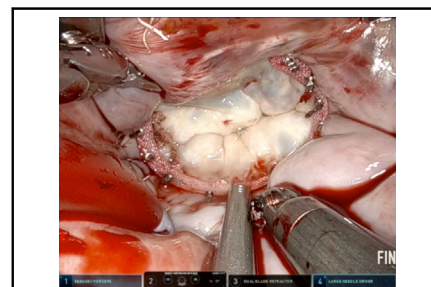
Address for reprints: Arnar Geirsson, MD, Division of Cardiac Surgery, Department of Surgery, Yale School of Medicine, 330 Cedar St, New Haven, CT 06510 (E-mail: ag4877@cumc.columbia.edu).

JTCVS Techniques 2023;22:86-7

2666-2507

Copyright © 2023 The Author(s). Published by Elsevier Inc. on behalf of The American Association for Thoracic Surgery. This is an open access article under the CC BY-NC-ND license (<http://creativecommons.org/licenses/by-nc-nd/4.0/>).

<https://doi.org/10.1016/j.jtc.2023.09.022>



Intraoperative image after mitral valve repair.

CENTRAL MESSAGE

Using a robotic approach for the treatment of bileaflet arrhythmic mitral regurgitation is safe and effective.

▶ Video clip is available online.

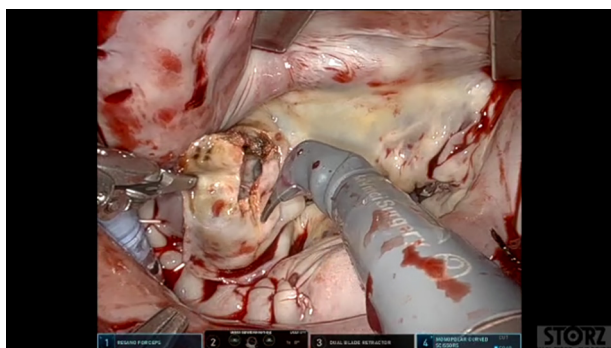
In patients with arrhythmogenic mitral valve prolapse, both ablation¹ and surgical correction of the underlying valvulopathy^{2,3} have been described as beneficial approaches to reduce the arrhythmogenic burden. Although centers have increasingly adopted robotic assistance as part of their mitral valve repair armamentarium,^{4,5} the technical nuances of a robotic approach for arrhythmogenic mitral valve prolapse remain underreported.

We present the case of a 67-year-old man with severe, symptomatic, bileaflet mitral valve prolapse and history of ventricular tachycardia with prior ablation attempt and implantable cardioverter defibrillator implantation performed at an outside hospital. Ports configuration consisted of the working port and camera placed in the third intercostal space at the right anterior axillary line; the left robotic arm port placed in the second intercostal space, halfway between the anterior axillary line and the midclavicular line; the right robotic arm port placed in the fifth intercostal space, slightly below the anterior axillary line; and the left atrial retractor placed in the fourth intercostal space 2 cm medial to the midclavicular line. Cardiopulmonary bypass was achieved by percutaneous femoral cannulation. Aortic crossclamp

and cardioplegia delivery were provided using the endoaortic balloon occlusion device. After exposure through the Waterston's groove (Video 1), the mitral valve was inspected and had myxomatous degenerative changes leading to bileaflet prolapse and severe annular dilatation. We closed the left atrial appendage and performed a 2-minute cryoablation of both papillary muscles (from the tip to midshaft height) using the Atricure cryoablation probe. We then repaired the mitral valve: we excised the thickened, disjunct basal portion of P1 and P2 with subsequent sliding plasty, we placed 2 neochords to P2, and we completed the repair with a 38-mm annuloplasty band. Cardiopulmonary bypass and aortic crossclamp times were 193 and 148 minutes, respectively. After the procedure, transesophageal echocardiography revealed trace mitral regurgitation and a mean gradient of 3 mm Hg. The patient had an uneventful postoperative recovery, with no subsequent ventricular arrhythmic events.

CONCLUSIONS

Using a totally endoscopic, robotic-assisted approach is safe and effective for the treatment of bileaflet arrhythmogenic mitral regurgitation.



VIDEO 1. Narrated case video. Video available at: [https://www.jtcvs.org/article/S2666-2507\(23\)00368-1/fulltext](https://www.jtcvs.org/article/S2666-2507(23)00368-1/fulltext).

Conflict of Interest Statement

Dr Amabile receives consulting fees from JOMDD/Sanamed. Mr LaLonde receives consulting fees from Edwards Lifesciences and Intuitive Surgical. Dr Krane is a physician proctor and a member of the medical advisory board for JOMDD/Sanamed, a physician proctor for Peter Duschek, a medical consultant for EVOTEC and Moderna, and has received speakers' honoraria from Medtronic and Terumo. Dr Geirsson receives consulting fees for being a member

of the Medtronic Strategic Surgical Advisory Board and from Edwards Lifesciences. All other authors reported no conflicts of interest.

The *Journal* policy requires editors and reviewers to disclose conflicts of interest and to decline handling manuscripts for which they may have a conflict of interest. The editors and reviewers of this article have no conflicts of interest.

References

1. Rivera S, Ricapito Mde L, Tomas L, Parodi J, Bardera Molina G, Banega R, et al. Results of cryoenergy and radiofrequency-based catheter ablation for treating ventricular arrhythmias arising from the papillary muscles of the left ventricle, guided by intracardiac echocardiography and image integration. *Circ Arrhythm Electrophysiol*. 2016;9:e003874.
2. Vaidya VR, DeSimone CV, Damle N, Naksuk N, Syed FF, Ackerman MJ, et al. Reduction in malignant ventricular arrhythmia and appropriate shocks following surgical correction of bileaflet mitral valve prolapse. *J Interv Card Electrophysiol*. 2016;46:137-43.
3. El-Eshmawi A, Pandis D, Miller MA, Boateng P, Dukkupati SR, Reddy VY, et al. Surgical cryoablation of papillary muscle pvc's during mitral valve surgery: therapeutic consideration for malignant MVP. *J Am Coll Cardiol*. 2020;76:3061-2.
4. Mori M, Parsons N, Krane M, Guy TS, Grossi EA, Dearani JA, et al. Robotic mitral valve repair for degenerative mitral regurgitation. *Ann Thorac Surg*. August 16, 2023 [Epub ahead of print]. <https://doi.org/10.1016/j.athoracsur.2023.07.047>
5. Amabile A, Morrison A, LaLonde M, Agarwal R, Mori M, Hameed I, et al. Two hundred robotic mitral valve repair procedures for degenerative mitral regurgitation: the Yale experience. *Ann Cardiothorac Surg*. 2022;11:525-32.