

## Sanitizer aerosol-driven ocular surface disease (SADOSD)—A COVID-19 repercussion?

Rohit Shetty, Chaitra Jayadev, Aishwarya Chabra, Sonia Maheshwari, Sharon D'Souza, Pooja Khamar, Swaminathan Sethu, Santosh G Honavar

Since the onset of the COVID-19 pandemic, there has been an advisory for regular and thorough cleaning of hands besides other measures such as social distancing and self-isolation. The rationale for the same is to prevent the transfer of the virus from hands that have come in contact with fomites. While both alcohol-based hand rubs (ABHR) or washing with soap and water are claimed to have been effective, hand sanitizers have gained more popularity due to the ease of use. The increased frequency of ABHR use and the aerosols generated pose a potential threat to the skin and exposed mucosal surfaces, especially that of the eye due to the proximity of use. The adverse effects of alcohol in these sanitizers can be manifold. An allergic or inflammatory response can occur depending on the predisposing or preexisting conditions. This article describes the risks, underlying mechanisms, and preventive measures for sanitizer aerosol-driven ocular surface disease.

**Key words:** Alcohol-based hand rubs, COVID, sanitizer aerosol-driven ocular surface disease

A 26-year-old mother of a toddler consulted us on a teleophthalmology platform a week ago. She had been having episodic redness, irritation, and a burning sensation past few weeks in both her eyes, which sometimes occurred 6–7 times a day. With the apprehension of visiting a doctor during the lockdown, she opted for the video consultation. While speaking to her, she appeared agitated. Since her husband was stranded in another country due to travel restrictions, she has been independently taking care of her little one. There was mild conjunctival congestion, but no discharge or lid edema. She did not report any drop in vision or photophobia. As there was no obvious infection on video examination, the patient was further asked if there was any recent change in toiletries or cosmetics. While this history was negative, the patient confided that she was using a hand sanitizer spray almost hourly.

Likewise, close to 60% of our teleophthalmology consultations so far have been for red-eye. A quarter of these was infective, while a majority was nonspecific. Ranging from mild to severe with significant congestion and chemosis, all were of recent origin and after the lockdown with a fifth of them being less than 18 years of age. Nearly 40% of the more severe presentation was in health care workers and those involved in coronavirus disease (COVID) care. Infective conjunctivitis was ruled out based on symptomatology, duration, the severity of signs, and poor response to topical antibiotics. Toxic or allergic conjunctivitis secondary to the chemical components of hand sanitizers is looming large

with the sudden spurt in frequent usage. But with personal hygiene and protection being mandatory to curb the spread of infection, we need to be armed with the knowledge and possible treatment options for sanitizer aerosol-driven ocular surface disease (SADOSD).

ABHRs are recommended for hand hygiene and have shown good activity against most pathological bacteria and viruses. The chemical constituents of hand sanitizers normally include ethyl alcohol, isopropyl alcohol, glycerol, and other chemical ingredients that are added to either deter oral consumption or provide fragrance. Many commercially available ABHRs contain around 70% by weight of ethanol and isopropanol.<sup>[1,2]</sup>

These constituents often get aerosolized due to vigorous and frequent rubbing while using them for disinfection purposes. It has also been shown that overuse of these ABHRs can result in allergic and irritant contact dermatitis<sup>[3]</sup> and a small amount can also be absorbed through the skin although not enough to cause systemic toxicity.<sup>[4]</sup> There are several *in-vivo* and *in-vitro* studies on the toxicity of these products.<sup>[5]</sup> Of particular interest is the Draize rabbit eye and skin irritancy tests, which evaluated the *in-vivo* irritation potential of these products on the skin and eye. Another important finding was that the eye is more sensitive to the toxic/allergic effects of ABHRs than the skin.<sup>[6,7]</sup>

This is an open access journal, and articles are distributed under the terms of the Creative Commons Attribution-NonCommercial-ShareAlike 4.0 License, which allows others to remix, tweak, and build upon the work non-commercially, as long as appropriate credit is given and the new creations are licensed under the identical terms.

**For reprints contact:** reprints@medknow.com

**Cite this article as:** Shetty R, Jayadev C, Chabra A, Maheshwari S, D'Souza S, Khamar P, et al. Sanitizer aerosol-driven ocular surface disease (SADOSD)—A COVID-19 repercussion? Indian J Ophthalmol 2020;68:981-3.

### Access this article online

#### Website:

www.ijo.in

#### DOI:

10.4103/ijo.IJO\_1308\_20

### Quick Response Code:



Narayana Nethralaya Eye Institute, 121/C, Chord Road, Rajajinagar, Bengaluru, Karnataka, India

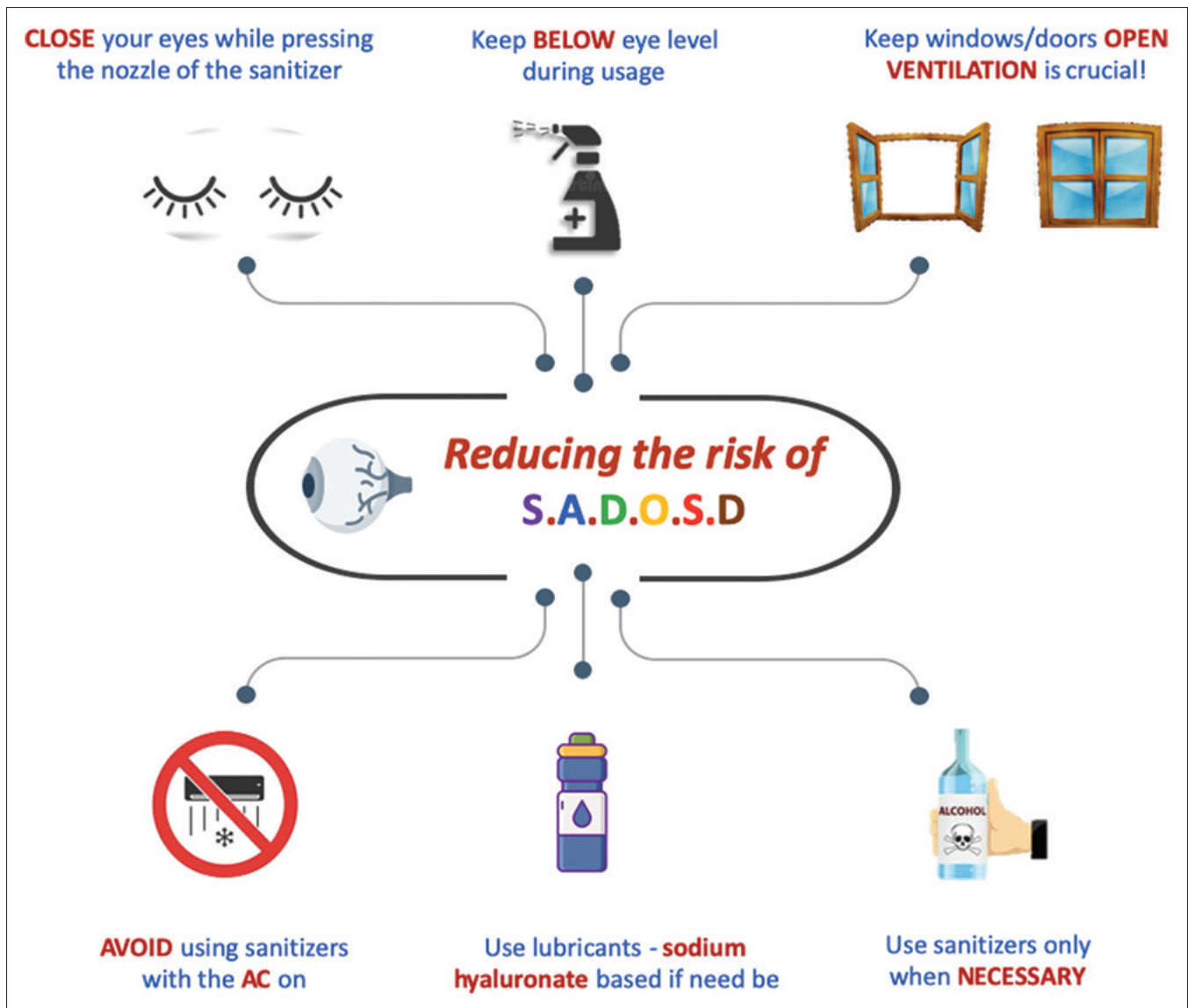
**Correspondence to:** Dr. Chaitra Jayadev, Narayana Nethralaya Eye Institute, 121/C, Chord Road, Rajajinagar, Bengaluru - 560 010, Karnataka, India. E-mail: drchaitra@hotmail.com

Received: 04-May-2020

Revision: 05-May -2020

Accepted: 05-May-2020

Published: 25-May-2020



**Figure 1:** Precautionary measures to prevent sanitizer aerosol-driven ocular surface disease

Ocular surface discomfort and precorneal tear film changes have been reported to indoor air pollutants including aerosolized chemicals.<sup>[8,9]</sup> The amount of exposure is proportionate to the frequency of usage which could range from 5 to 30 times per day and can be cumulative as well.<sup>[3]</sup> It can serve as an irritant, thus, inducing a temporary mild to moderate inflammatory effect, akin to allergic conjunctivitis.<sup>[10]</sup> Allergic conjunctivitis is provoked by IgE-mediated immediate hypersensitivity with mast cell degranulation and consequent release of pro-inflammatory mediators such as histamine, IL-13, IL-6, and tumor necrosis factor (TNF)-alpha, which results in clinical signs of allergy.<sup>[11,12]</sup> In chronic ocular allergy, the ocular surface can be compromised with altered levels of various ocular surface mucins like the MUC5AC, MUCs 1, 2, and 4 compared with controls. This is due to damage to goblet cells secondary to ocular surface inflammation in chronic allergy which results in further damage to the ocular surface, increased tear film instability, and epithelial changes.<sup>[13]</sup> Those who are predisposed to ocular allergy or have a compromised ocular

surface can develop ocular symptoms even with relatively lower usage of ABHRs.

Alcohol, known for its dehydrating properties, can result in desiccating stress in cells and tissues. Ocular surface and desiccation stress is well documented in the context of dry eye disease.<sup>[14]</sup> Desiccation stress also increases the inflammatory factors' level in human ocular surface epithelial cells.<sup>[15,16]</sup> These factors can serve as an itch stimulus further perpetuating eye rubbing and amplify the inflammatory response to result in a clinical presentation of ocular surface inflammation with noninfectious or unknown etiology. Besides reducing the proliferative capacity and inducing apoptosis,<sup>[10]</sup> alcohol can reduce the mucosal immune response on the ocular surface due to its immune-suppressive properties.<sup>[17]</sup> Alcohol is known to alter nociception by reducing the pain threshold and this would amplify with the corneal nerve endings' cumulative exposure to alcohol-based aerosols.<sup>[18]</sup> Though these reported effects have been studied in a one-time high exposure of alcohol, the same can occur consequent to cumulative short

exposures of high concentrations of alcohol. Another concern that is often associated with an excessive disinfection process is the disruption of the commensal microbiome balance which can alter the homeostasis and predispose to opportunistic microbiome colonization.<sup>[19]</sup>

Hence, responsible use of hand sanitizers would be prudent [Fig. 1]. To reduce direct contact with the ocular surface

1. CLOSE your eyes while pressing the nozzle of the sanitizer
2. Keep the sanitizer BELOW the eye level during usage
3. Use sanitizers only if and when NECESSARY
4. Keep windows and doors OPEN, as VENTILATION is crucial!
5. AVOID using sanitizers with the air-conditioner on
6. Use sodium hyaluronate-based lubricants if there is a preexisting ocular surface disease.

The use of soap and running water for hand cleansing should be encouraged in the susceptible. The use of protective goggles or a face shield would be beneficial when frequent hand cleansing is unavoidable, such as in an outpatient department. Most importantly, we should not let the situation overwhelm us. Over cautious behavior or needless panic may only serve to aggravate the vicious cycle. Judicious and appropriate use of hand sanitizers will prevent the worsening of the ocular surface disease.

#### Financial support and sponsorship

Nil.

#### Conflicts of interest

There are no conflicts of interest.

## References

1. Boyce JM. Using alcohol for hand antisepsis: Dispelling old myths. *Infect Control Hosp Epidemiol* 2000;21:438-41.
2. Boyce JM, Pittet D; Healthcare Infection Control Practices Advisory Committee; HICPAC/SHEA/APIC/IDSA Hand Hygiene Task Force. Guideline for Hand Hygiene in Health-Care Settings. Recommendations of the Healthcare Infection Control Practices Advisory Committee and the HICPAC/SHEA/APIC/IDSA Hand Hygiene Task Force. Society for Healthcare Epidemiology of America/Association for Professionals in Infection Control/Infectious Diseases Society of America. *MMWR* PMID: 12418624.
3. Maier A, Ovesen JL, Allen CL, York RG, Gadagbui BK, Kirman CR, *et al.* Safety assessment for ethanol-based topical antiseptic use by health care workers: Evaluation of developmental toxicity potential. *Regul Toxicol Pharmacol* 2015;73:248-64.
4. Bessonneau V, Thomas O. Assessment of exposure to alcohol vapor from alcohol-based hand rubs. *Int J Environ Res Public Health* 2012;9:868-79.
5. Abo T, Yuki T, Xu R, Araki D, Takahashi Y, Sakaguchi H, *et al.* Expansion of the applicability domain for highly volatile substances on the short time exposure test method and the predictive performance in assessing eye irritation potential. *J Toxicol Sci* 2018;43:407-22.
6. Ahn J, Eum K, Kim Y, Oh SW, Kim YJ, Lee M. Assessment of the dermal and ocular irritation potential of alcohol hand sanitizers containing aloe vera with *in vitro* and *in vivo* methods. *Mol Cell Toxicol* 2010;397-404.
7. Bertholf RL, Bertholf AL, Reisfield GM, Goldberger BA. Respiratory exposure to ethanol vapor during use of hand sanitizers: Is it significant? *J Anal Toxicol* 2011;35:319-20.
8. Wolkoff P. Ocular discomfort by environmental and personal risk factors altering the precorneal tear film. *Toxicol Lett* 2010;199:203-12.
9. Opiekun RE, Smeets M, Sulewski M, Rogers R, Prasad N, Vedula U, *et al.* Assessment of ocular and nasal irritation in asthmatics resulting from fragrance exposure. *Clin Exp Allergy* 2003;33:1256-6.
10. Oh JY, Yu JM, Ko JH. Analysis of ethanol effects on corneal epithelium. *Invest Ophthalmol Vis Sci* 2013;54:3852-6.
11. Kittaka H, Tominaga M. The molecular and cellular mechanisms of itch and the involvement of TRP channels in the peripheral sensory nervous system and skin. *Allergol Int* 2017;66:22-30.
12. Aydin E, Gokhale M, Azizoglu S, Suphioglu C. To see or not to see: A systematic review of the importance of human ocular surface cytokine biosignatures in ocular allergy. *Cells* 2019;8. doi: 10.3390/cells8060620.
13. Dogru M, Matsumoto Y, Okada N, Igarashi A, Fukagawa K, Shimazaki J, *et al.* Alterations of the ocular surface epithelial MUC16 and goblet cell MUC5AC in patients with atopic keratoconjunctivitis. *Allergy* 2008;63:1324-34.
14. Bron AJ, de Paiva CS, Chauhan SK, Bonini S, Gabison EE, Jain S, *et al.* TFOS DEWS II pathophysiology report. *Ocul Surf* 2017;15:438-510.
15. Panigrahi T, Shivakumar S, Shetty R, D'souza S, Nelson EJR, Sethu S, *et al.* Trehalose augments autophagy to mitigate stress induced inflammation in human corneal cells. *Ocul Surf* 2019;17:699-713.
16. Shivakumar S, Panigrahi T, Shetty R, Subramani M, Ghosh A, Jeyabalan N. Chloroquine Protects Human Corneal Epithelial Cells from Desiccation Stress induced Inflammation without Altering the Autophagy Flux. *Biomed Res Int* 2018;2018:7627329.
17. Sarkar D, Jung MK, Wang HJ. Alcohol and the immune system. *Alcohol Res* 2015;37:153-5.
18. Hegarty DM, Hermes SM, Yang K, Aicher SA. Select noxious stimuli induce changes on corneal nerve morphology. *J Comp Neurol* 2017;525:2019-31.
19. Edmonds-Wilson SL, Nurinova NI, Zapka CA, Fierer N, Wilson M. Review of human hand microbiome research. *J Dermatol Sci* 2015;80:3-12.