



King Saud University

Saudi Journal of Biological Sciences

www.ksu.edu.sa
www.sciencedirect.com



ORIGINAL ARTICLE

Protective effects of fennel oil extract against sodium valproate-induced hepatorenal damage in albino rats



Wael M. Al-Amoudi

Department of Biology, Faculty of Applied Sciences, Umm Al-Qura University, Post Box 6055, Makkah 21955, Saudi Arabia

Received 16 August 2016; revised 16 October 2016; accepted 23 October 2016

Available online 5 November 2016

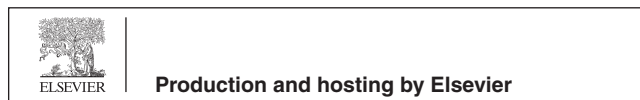
KEYWORDS

Sodium valproate;
Fennel oil;
Liver;
Kidney;
Histology;
Antehole;
Biochemistry

Abstract *Foeniculum vulgare* (Apiaceae) is commonly known as fennel. This herb is well-known worldwide and traditionally used as curative herbal therapy for the treatment of epileptic disease, seizurescarminative, digestive, lactagogue, diuretic, treating respiratory and gastrointestinal disorders. The aim of present study is to investigate the possible effect of fennel oil against the toxicity of Sodium-Valproic (SVP) in albino rats. In order to assess the protection of fennel oil on SVP induced hepato- and nephro-toxicity, male albino rats were treated with 1 ml/kg b.w fennel oil 3 days/week for 6 weeks. The biochemical analyses of hepatic enzymes were evaluated by estimating blood biomarkers of liver and renal damage along with histological examination. The results obtained from this work showed that treating animals with SVP lead to many histopathological alterations in the liver and kidney tissues. The effect appeared in the liver tissue include leukocyte infiltrations, cytoplasmic vacuolization of the hepatocytes, fatty degeneration and congestion of blood vessels. This commonly used chemical (SVP) caused some unwanted effects on the kidney cortex which histologically observed as degeneration in renal tubules, atrophy of the glomeruli and edema. Biochemical results also revealed an abnormal increase in the enzyme level of AST, SAT, ALP, bilirubin, creatinine and urea-nitrogen, with a noticed decrease in total protein content. However, the results of treated rats with SVP plus fennel oil showed some positive histopathological changes in both the liver and kidney tissues. These results have confirmed that fennel oil has positive effects on the histological structure of the liver and kidney and the biochemical levels of AST, ALT, ALP, bilirubin, total proteins, creatinine and urea. It is concluded that fennel oil has various pharmacological properties including antioxidant, anti-cancer activity, anti-inflammatory. These valu-

E-mail address: wmalamoudi@hotmail.com

Peer review under responsibility of King Saud University.



<http://dx.doi.org/10.1016/j.sjbs.2016.10.021>

1319-562X © 2016 The Author. Production and hosting by Elsevier B.V. on behalf of King Saud University.

This is an open access article under the CC BY-NC-ND license (<http://creativecommons.org/licenses/by-nc-nd/4.0/>).

able effects might be due to the presence of aromatic compounds *trans*-anethole. This useful properties of fennel plant could be due to its antioxidant activity that prevents the toxicity of SVP.

© 2016 The Author. Production and hosting by Elsevier B.V. on behalf of King Saud University. This is an open access article under the CC BY-NC-ND license (<http://creativecommons.org/licenses/by-nc-nd/4.0/>).

1. Introduction

It is generally believed that prevention is better than treatment. Fennel plants (*Foeniculum vulgare*) have been widely used as a source of folk medicine since immortal time. Fennel is a medicinal plant belongs to the family Apiaceae (*Umbelliferae*) (Rather et al., 2012). This herb is traditionally used as treatment for colic, wind, irritable bowel, kidneys, spleen, liver, lungs, suppressing appetite, breast enlargement, promoting menstruation, improving digestive system, milk flow and increasing urine flow (Delaram et al., 2011).

This medicinal plant may be beneficial to humans as they have several phytoconstituents to cure diseases (Kooti et al., 2014). Essential oil of this herbal plant was found to have different medicinal and antioxidant properties against some diseases (Wesam et al., 2015; Mirabolghasemi and Alizadeh, 2014). It has been shown that the fennel oil with hexane extract of fennel and anethole components illuminate the effect of probiotic bacteria and used as antimicrobial agent against other species (Ostad et al., 2001). Pai et al. (2010) has also reported that oil extracted from fennel plant has effect against *Candida albicans* and some other bacterial infections. Different pharmacological experiments in a number of *in vitro* and *in vivo* models have convincingly demonstrated the ability of Fennel to exhibit antifungal, antibacterial and as antioxidant agent. In addition, It has been suggested that fennel essential oil could inhibit contraction of an isolated uterus that was induced by oxytocin and prostaglandin E₂ (Ostad et al., 2001).

Trans-Anethole, [1-methoxy-4-(1-propenyl) benzene], is a chief constituent of fennel plant, anise, clove, cinnamon, thyme and camphor. Anethole containing oils are widely used in the food and liquor industries (Castro et al., 2010). It has been suggested that the anethole may play a major role in blocking both inflammation and carcinogenesis (Bharat et al., 2008). This compound and related ones have been reported to strike metabolic effects (Singh and Kale, 2008). Stohs et al. (1986) and Mohamad et al. (2011) have demonstrated that fennel oil acts like antioxidants due to its ability to inhibit lipid peroxidation. Moreover, it has been revealed that oil extracted from this fennel herb has a protective affect against the toxicity induced by carbon tetrachloride in rat liver (Ozbek et al., 2003). In other study, it has been reported that fennel extract caused a significant improvement against hepatic fibrosis patients with fibrosis, liver tissue inflammation and excessive fat degradation (Wang et al., 2012). Although, this medicinal herb has few side effects than synthetic drugs, it is still widely and medicinally used due to its antioxidant properties (Asadi-Samani et al., 2013). Also, it has been illustrated that the components of the fennel plant have a positive effects to reduce drugs toxicity in some biological system (Asadi-Samani et al., 2013; Kooti et al., 2014).

Valproic acid (VPA) is a medicine widely prescribed as an anticonvulsant and mood stabilizer. It has been commonly used in the treatment of epilepsy and bipolar disorder

(Henry, 2003 and Johannessen, 2000). VPA has been prescribed as anti-epileptic drugs (AEDs) over the past 40 years (Chang et al., 2016). It has been reported by Jessberger et al. (2007) that SVP treatment could cause a neuronal abnormality and contributes to the aberrant neurogenesis associated with epileptic activity in adult rodents. In other study, a wide range of side effects have been reported in patients exposed to SVP treatment such as; gastrointestinal disturbances, tremor and weight gain (Brandt et al., 2006).

Sodium valproate (SVP) has been associated with a number of serious unwanted effects affecting the blood, pancreas, liver and kidney (Chang et al., 2016). Ornoy (2006) has revealed that SVP is a teratogen agent causing an induction of neural tube defects, heart abnormalities, craniosynostosis, and cause abnormalities to the skeletal malformations, such as ectrodactyly and syndactyly. Moreover, rare serious complications may occur in some patients receiving SVP chronically, including fatal haemorrhagic, pancreatitis, bone marrow suppression and *Hyperammonemic encephalopathy* (Sztajnkrycer, 2002). Also, it has been documented that patients undergoing VPA therapy for a period of time often show changes and instability in mood reaction, cognition and behavior (Senturk et al., 2007). Nadebaum et al. (2011) has reported that VPA can noticeably develop cognitive dysfunction in epileptic patients. Furthermore, VPA could alter hepatic triacylglycerol (TAG) and cholesterol biosynthesis, fatty acid catabolism, and lipid transport-related gene expression patterns (Lee et al., 2007). Stephens and Levy (1992) have reported that SVP may cause liver damage and led to pancreatitis, which occasionally progress to bleeding and death. It has been also suggested that liver dysfunction is one of the common negative side effect of SVP treatment. Morán-Salvador et al. (2011) has demonstrated that liver biopsy revealed portal inflammation, severe bile duct loss, and cholestasis as result of SVP effect. Clinical record have reported that more than 40% of patients who received VPA also developed unexpected obesity and fatty liver disease (Saleh et al., 2012). However, how VPA affects hepatic lipid metabolism to induce fatty liver remains unclear.

Coyle et al. (2005) has reported that in three cases, the valproic acid was found to be associated with leukemia. Moreover, Janneke et al. (2010) has also demonstrated that there was a significant association between exposure of the unborn child to valproic acid monotherapy and Spina bifida, arterial septa defects, cleft palate, hypospadias, polydactyl and craniosynostosis. In addition, VPA was also documented to be a major cause leading to degenerative changes in kidney of pregnant rats (Aktas et al., 2010). Gokee et al. (2010) has noticed that valproic acid-associated vanishing bile duct syndrome in an 8-year old girl treated with valproic acid. These results have of the above mentioned authors stimulated us to study the possible preventive effect of According to these scientific knowledge found and reported about the fennel plant and its effective components, The aim of this study was to investigate the positive antioxidant properties of fennel oil against valproic acid (SVP) exposed to liver and kidney organs

2. Experimental methods

Albino male rats (Sprague–Dawley strains) weighting 150 ± 10 g were used in this study. Rats were housed in standard cages and kept under constant temperature (24 ± 2 °C) at laboratory condition throughout the experimental period. The rats were maintained on a standard rodent pellets and water. Environmental conditions of animals and experimental procedures were approved by the animal ethical committee in accordance with the guide for care and use of laboratory animals. Animals were divided into 4 experimental groups:

Group I. Animals of this group (10 rats) were served and treated as controls under optimum conditions.

Group II. Animals of this group (10 rats) were orally given 1 ml/kg b.w fennel oil 3 days/week for 6 weeks (Rabeh and Aboraya, 2014). The fennel oil was obtained from a local pharmacy, Jeddah, KSA.

Group III. Animals of this group (10 rats) were orally given 25 mg/kg b.w of sodium valproate (Okdah and Ibrahim, 2014) 3 days/week for 6 weeks. The SVP was purchased from a local pharmacy as tablets with trade name Depakine and dissolved in distilled water.

Group VI. Animals of this group (10 rats) were given the same dose of Sodium valproate given to animal of group III, followed by fennel oil, 3 days/week for 6 weeks.

3. Histological study

In this study, histological staining technique was conducted to investigate the possible effect of fennel oil against SVP. At the end of the experimental period, animals were fasted overnight and then the treated and untreated (control) groups were weighted and sacrificed by cervical decapitation after 6 weeks of treatment course. Blood samples were collected then animals were dissected and liver and kidney organs were removed followed by immediate fixation in a 10% formalin to prevent decay and preserve cells and tissues in a “life-like” state. Small pieces of specimens were dehydrated in an ascending series of alcohol and processed for paraffin section preparation. The tissues were cleared in two changes of xylene and then were embedded in fresh molten paraffin. Paraffin sections were cut at a thickness of 3–5 μ m using rotary microtome and mounted on clean slides. For histopathological observations, sections were cut and stained with Ehrlich’s hematoxylin and counterstained with eosin (H&E).

4. Biochemical study

Blood samples were collected from animals groups after 6 weeks of treatment. The blood samples were withdrawn from the retro-orbital venous plexus into serum tubes and left to clot and followed by centrifuging at 3000g for 15 min at 4 °C where the clear sera were separated for the blood analysis. Samples were kept in a specific order to avoid cross-contamination of additives between tubes. Blood samples were processed for determination of Aspartate aminotransferase (AST), Alanine aminotransferase (ALT), Alkaline phosphatase (ALP), Bilirubin, Total proteins, Creatinine and Urea. These were measured

using a fully automated Hitachi 911 analyzer (Tokyo, Japan). A commercial randox kits (Randox Laboratories, LTD, Ardmore, Crumlin, United Kingdom) were used for the biochemical analysis.

5. Statistical analysis

The results of different groups were expressed as mean \pm SD. The differences between the mean values were evaluated by ANOVA. Data was analyzed using the computer program SPSS/version 15.

6. Results

6.1. Histopathological examination

6.1.1. Liver

The light microscopical examination of liver sections from the control rats revealed normal hepatocytes, normal branching cords of hepatocytes around the portal tract and central vein separated by blood sinusoids, the hepatocytes were found arranged in strands around the central vein. The cords appeared to be intermingled by blood sinusoids containing normal kupffer cells as shown in (Fig. 1A). Also, in the liver section of the rats group treated with fennel oil similar histological structure was observed with more or less healthy hepatocytes architecture and congested blood vessels (Fig. 1B). In contrast, the liver sections obtained from the SVP treated rats revealed clear hepatocytes disorganization and hepatocytes nuclei were shrunked, pyknotic or apoptotic. The most remarkable changes was the congestion of the intrahepatic blood veins (Fig. 1C). Moreover, infiltrations by masses of leukocyte inflammatory cells were also observed in this section of SVP-treated group as shown in (Fig. 1C). It is noteworthy that after 6 weeks of exposition to SVP most of the hepatocytes appeared to have cytoplasmic vacuolation with pyknotic nuclei, congestion, fibrosis and bile duct necrosis around the portal tract, (Fig. 2A), also, fatty infiltrations was noticed in the SVP group as shown in (Fig. 2B). However, in the liver of animals treated with SVP and fennel oil a remarkable improvement was observed and regeneration in the periportal zone was noticed (Fig. 1D and Fig. 2C). The same figure showed some hepatocytes appeared acidophilic with granular cytoplasm and central vesicular nuclei were similar to the normal, but few leukocyte inflammatory (Fig. 2C).

6.1.2. Kidney

Normal histological structure of the kidney was observed in the control sections and no histopathological changes was noticed as shown in (Fig. 3A). The kidney architecture is composed of a large number of nephrons and hematopoiesis. Each nephron contains renal corpuscles and renal tubules. The renal corpuscles contain a vascular capillary glomerulus that is enclosed by Bowman’ capsule. Also, the renal tubule is connected the renal corpuscle to a large collected duct and composed of proximal and distal tubules. The kidney sections from animals given fennel oil showed normal structure with no histopathological changes (Fig. 3B). However, the *microscopical* examination of kidney cortex of the animals treated with SVP showed congested and enlarged renal veins and vac-

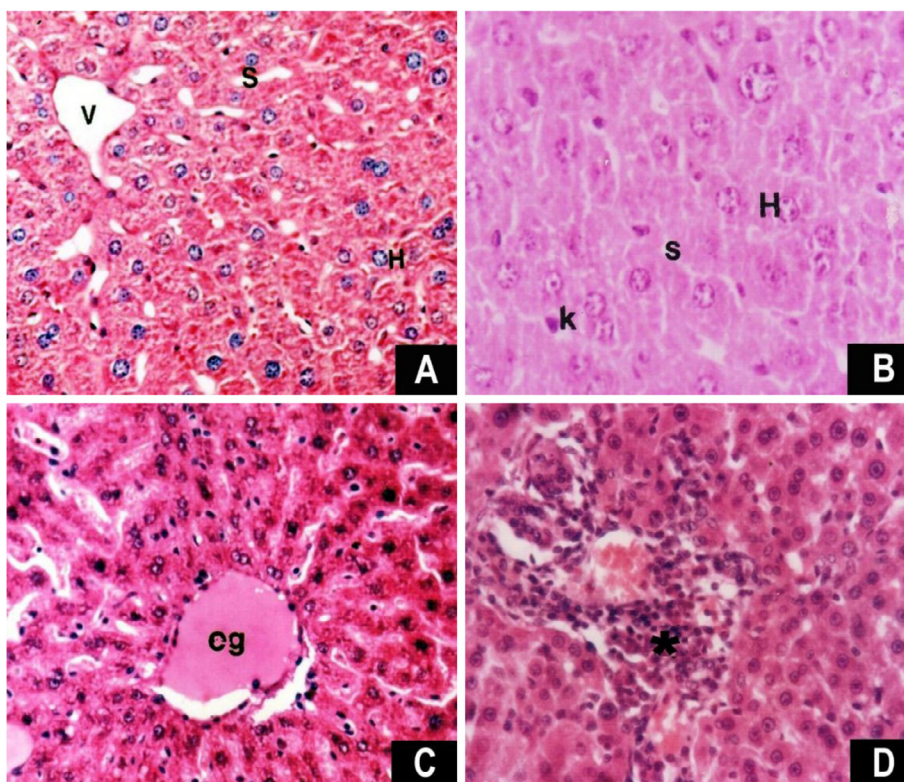


Figure 1 (A) Photomicrograph of liver section of a control rats showing the normal branching cords of hepatocytes (H) around the portal tract and central vein (V) separated by blood sinusoids (S), (HE, $\times 200$); (B) liver section of fennel oil treated rats showing normal architecture hepatocytes (H), kupffer cell (K) and blood sinusoid (S) ($\times 250$). (C) liver section of SVP treated rat showing congestion (Cg), hepatocytes disorganization. The hepatocytes nuclei are shrunk and pyknotic or apoptotic. Areas of hemorrhages in blood vessels and in between hepatocytes ($\times 200$); (D) liver section of SPV plus fennel oil showing some leucocyte infiltrations (*); ($\times 200$).

ular degeneration in some tubular epithelial cells, some cell debris scattered in tubular lumina. The renal tubules showed cytoplasmic vacuolation of epithelial lining and their lumen filled with proteinaceous casts (Fig. 3C). Also, edematous lesion was observed between the tubules as shown in (Fig. 3D). The renal tubules appeared severely injured and the glomeruli were fragmented and degenerated (Fig. 4A). In the animals group given SVP and fennel oil, the histological structure of kidney cortex was more or less improved and nearly restoring to its normal structure. In comparison to the histopathological changes shown in the SPV treated sections these changes slightly held and improved in the group treated with SVP plus fennel oil. Also, the tubules and glomeruli appeared to be normal (Fig. 4B).

6.2. Biochemical results

SVP treatment resulted in a significant increase in hepatic enzymes level, total-bilirubin, creatinine and urea nitrogen after six weeks of administration, concomitant with a significant decline in total- proteins content as compared to control rats (Figs. 5–7). However, the administration of fennel oil alone revealed insignificant changes in the mentioned parameters when compared to control rats except in rats treated with SPV and fennel oil where a significant decrease toward the normal values of the controls in hepatic enzymes, total-bilirubin, creatinine and urea nitrogen was observed.

The selected and specialized serum markers of liver functions among the different groups are shown in (Figs. 5–7). It is clearly indicated that fennel oil had no effect on AST, ALT, and ALP activities as well as bilirubin, creatinine, urea nitrogen and total protein levels when compared with the control group. The treatment of rats with SVP alone resulted in significant increases the activity of AST (Fig. 5A), ALT (Fig. 5B), and ALP (Fig. 5C) bilirubin (Fig. 6A), creatinine (Fig. 7A) and urea (Fig. 7B) levels and a non-significant increase in total proteins level (Fig. 6b). However, the administration of SVP together with fennel oil to rats succeeded significantly in preventing the SVP-induced changes in the above mentioned parameters (Figs. 5–7).

7. Discussion

SVP is a common medicine used as treatment for epilepsy and bipolar disorder different diseases (Henry, 2003; Johannessen, 2000). However, SVP use has been complicated by a high incidence of hepatic injury which was found to be associated with oxidative damage (Chang et al., 2016). Fennel was reported to have antioxidant effects. Therefore, in this study, the aim was to investigate the protective effects of fennel oil, as natural products, against SVP-induced liver and kidney injury. The results of this study have revealed that SVP has caused different histopathological and biochemical changes. The treated liver with SVP showed a remarkable degeneration of hepato-

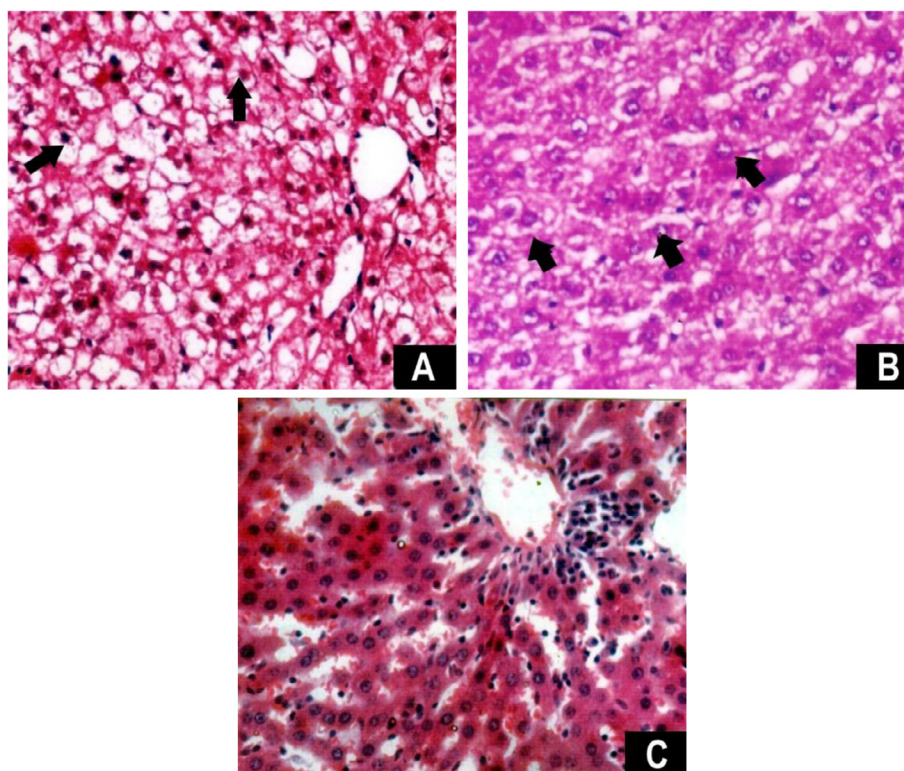


Figure 2 Photomicrographs of liver sections showing (A) congestion, fibrosis and bile duct necrosis around the portal tract, the hepatocytes are disorganized with pyknotic nuclei, cytoplasmic vacuolation of hepatocytes in the SVP treated rat, (arrows), (HE, $\times 200$). (B) Liver with fatty infiltrations (arrow head), (HE, $\times 200$). (C) Liver section of a rat treated with SVP and fennel oil showing normal hepatocytes architecture areas and few leucocyte infiltrations, (HE, $\times 200$).

cytes, aggregation of inflammatory cells infiltration, congested blood vessels and fatty infiltration. Also, the kidney result of SVP treated rats revealed some abnormality in the renal tubular structure. The results obtained from this study uniquely compared to other studies in this context. It is confirming that SVP has an effect on liver and kidney histological structure and hepatic enzymes into the bloodstream, which can result in elevated liver enzymes on blood tests.

It has been documented that microvesicular, fatty changes are associated with necrosis appeared in liver of patients given valproate (Mathis et al., 1979). Lewis et al. (1982) and Powell-Jackson et al. (1984) have reported that administration of SVP to rats produced a dose dependent microvesicular hepatic steatosis and causing abnormality to the liver tissue. Stephens and Levy (1992) have also showed that depakene (SVP) can cause liver damage and cause pancreatitis which occasionally lead to bleeding and death. Raza et al. (2000) reported that treating mice with valproic acid induces fatty degeneration of hepatocyte, swelling and increased number of kupffer cells. Other study showed that steatosis and necrosis of hepatocyte are the main histopathological changes in liver of albino rat induced by toxic dose of valproic acid (Khan et al. (2005). These changes are consistent with the results revealed in this work. Moreover, vacuolar degenerative changes, hypertrophied nucleus with fragmented chromatin, inflammatory cells aggregates and congested vasculature were observed in liver of mice treated with valproic acid (Ibrahim, 2012).

The biochemical analyses showed that SVP has affected the normal concentration of some hepatic enzymes. Transami-

nases (ALT, AST and ALP), bilirubin were significantly increased in the sera of SVP-treated animals. These enzymes, AST, ALT and bilirubin are biomarkers in the diagnosis of hepatic damage, because they are released into the circulation after cellular damage. Alkaline phosphatase (ALP) and gamma-glutamyl transferase (GGT) are well-known as markers of an obstruction in the bile flow cholestasis pressure (Kumar et al., 2008). The changes of these enzymes activities may be mainly due to the leakage from the liver cytosol into the blood. Bilirubin and creatinine levels are also related to the status and function of hepatic cells. The increase in serum ALP is due to increased synthesis in the presence of biliary pressure (Kumar et al., 2008). Bilirubin has been used in several studies as biomarker to evaluate chemically-induced hepatic injury (Mannaa et al., 2015). This is one of the most useful clinical clues to the severity of necrosis, and its accumulation is a measure of binding, conjugation, and excretory capacity of hepatocytes (Naik et al., 2004) and (Mannaa et al., 2015). These facts indicate that although, SVP is widely used as a treat mania (episodes of frenzied, abnormally excited mood), it also lead to some abnormalities in liver and kidney tissues. It has been reported by (Spiller et al., 2000) that the side effect of valproic acid on the hepatic tissue is associated with dose dependent rise in serum liver enzymes. Felker et al. (2003) has notice through retrospective studies a transient elevation of liver ALT and AST in epileptic patients treated with valproic acid. In addition, Powell-Jackson et al. (1984) and Okdah and Ibrahim (2014) have reported that AST and bilirubin increased in serum of animal given SVP. This due

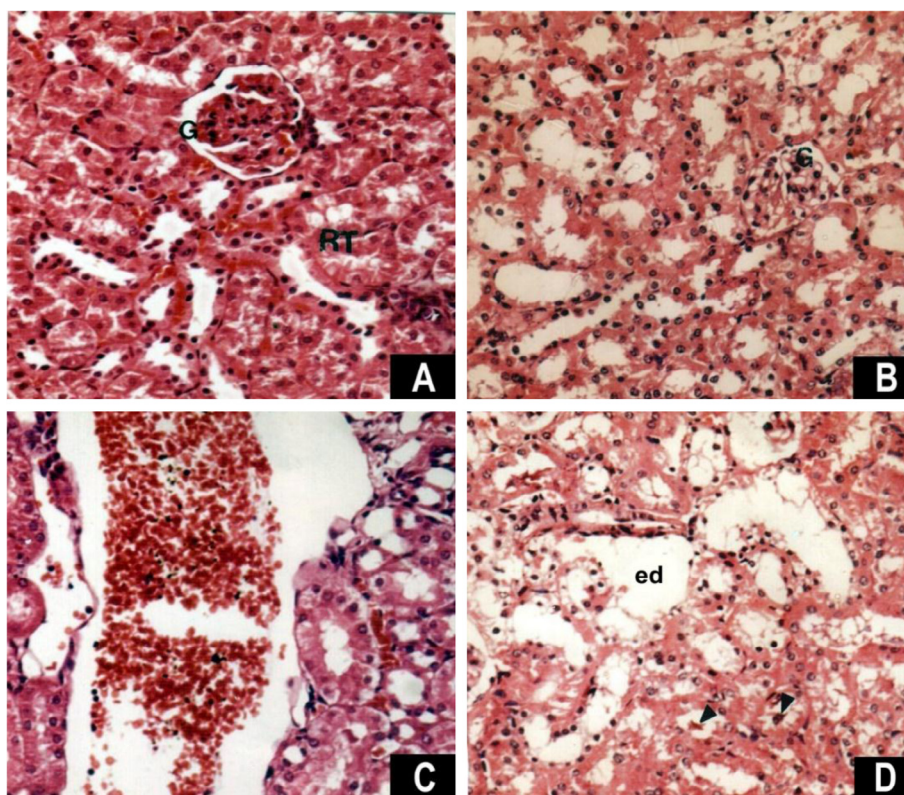


Figure 3 Photomicrograph of kidney section showing (A) Kidney cortex of a control rat showing glomerulus (G) and renal tubules (RT), (HE, $\times 200$). (B) Kidney cortex of fennel oil treated rat showing normal tubules and glomerulus (G), ($\times 200$). (C) Kidney section of SVP treated rat showing enlarged and congested renal vein (HE, $\times 200$). (D) Kidney section of a rat treated SVP showing degeneration of renal tubules with lumen filled with proteinaceous casts (arrow heads) and edema (ed), (HE, $\times 200$).

to its oxidative stress which has been recognized to be involved in etiology of several liver diseases (Okdah and Ibrahim, 2014). The histopathological and biochemical results shown in this investigation are consistent with these reported the negative side effect of SVP.

The results also showed that SVP has a notable effect on kidney tissue of treated rats. These effects appeared as atrophy of the glomeruli, degeneration of renal tubules and edema. Renal damage, such as interstitial nephritis and proximal renal tubule were observed. Some of these dysfunction has been previously intimated following administration of sodium valproate (Lenoir et al., 1981; Ching-Yuang and Chiang, 1988). In other study, it has been reported that tubulointerstitial nephritis is a major side effect of VPA (Yoshikawa et al., 2002). Raza et al. (2000) has recognized some significant epithelial necrosis, sloughing of tubules, and mild lymphocytic infiltrate after 21-days administration of 0.71% VPA in drinking water of mice. Gezinci-Oktayoglu et al. (2016) has also observed tubular disruption especially in proximal tubules, necrosis in the glomerular and tubular areas, accumulation of collagen fibers in the necrotic areas, and mononuclear cell infiltration in renal tissue of rats treated with VPA (500 mg/kg/day) for 15 days. The present results also showed that creatinine and urea nitrogen were increased in sera of SVP-treated animals. These facts are similar to the observations reported by Fukuda et al. (1996) and Watanabe et al. (2005), since they had noticed some abnormalities in serum urea and creatinine levels in animal and patients

treated with SVP. These biochemical results together with histological observations mentioned in this study indicate that SVP has caused renal damage and lead to dysfunction of kidney architecture.

As regards the effect of fennel oil, the present results revealed that it attenuates SVP induced histological changes in the liver and kidney. Moreover, the fennel oil has improved the biochemical levels of AST, ALT, ALP, bilirubin, total proteins, creatinine and urea and maintained these levels to be normal. The results are in agreement with those of other investigators who studied the protective effect of fennel oil. Ozbek et al. (2003) has indicated that fennel essential oil could inhibit the CCl_4 induced acute hepatotoxicity by decreasing levels of serum aspartate amino-transferase (AST), alanine aminotransferase (ALT), alkaline phosphatase (ALP) and bilirubin. The noticed reduction of bilirubin level in the serum of fennel oil given to treated animals with comparison to the administration of SVP alone might indicate that the conjugating function of the liver was improved due to fennel oil which increased the bile flow in rats (Rafatullah et al., 2006).

It has been reported that fennel extract contains different polyphenolic compounds (Faudale et al., 2008; Chang et al., 2013). These, Polyphenolic compounds are known to have tremendous antioxidant activity and it is likely that the activity of fennel extracts could be due to these active compounds (Chatterjee et al., 2012; Choi and Hwang, 2004). This activity is believed to be mainly as a result of their redox properties,

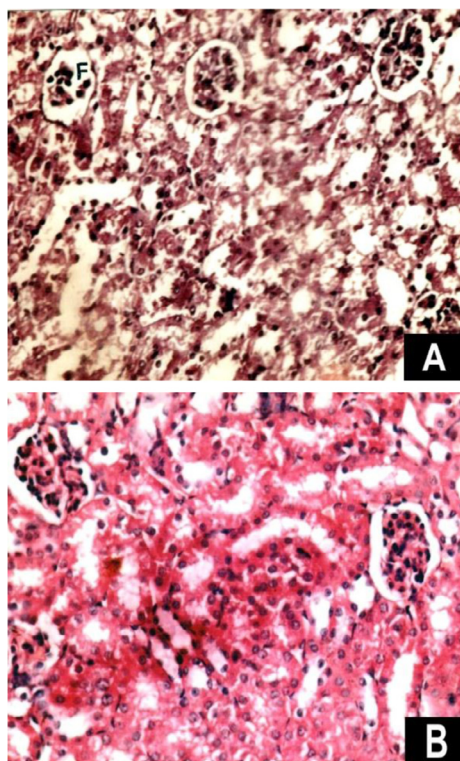


Figure 4 Photomicrographs of kidney sections showing (A) Kidney section of 6 weeks treated rat with SVP showing cortex and tubules degeneration with fragmented glomerulus (F), ($\times 200$). (B) Kidney section of a rat treated with SVP and fennel oil showing marked improvement in the cortex and regeneration of tubules with healthy glomeruli, ($\times 200$).

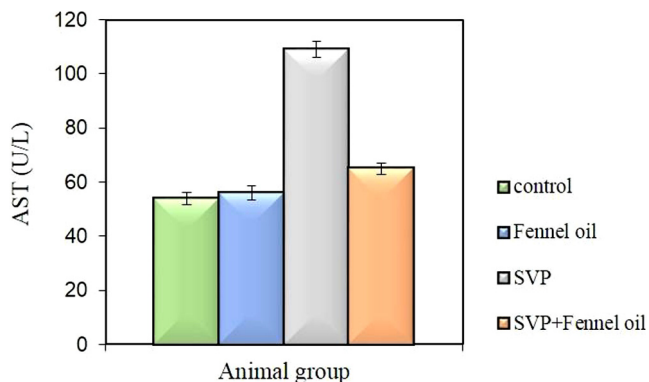


Figure 5(A) (A) Showing changes in AST enzyme catalytic activity are presented as relative activities in comparison to control group values. The control and fennel oil treated groups show normal AST activity level. However, the animal group treated with SVP shows a significant increase in AST enzyme activity. The group treated with SVP plus fennel oil shows a marked decline in the AST level in comparison to the group treated with SVP.

which plays an important role in adsorbing and neutralizing free radicals, quenching singlet and triplet oxygen, or decomposing peroxides (Sofowora, 1993; Singh et al., 2006).

Many diseases develop as a result of a process which involves the formation of reactive oxygen species (ROS). In

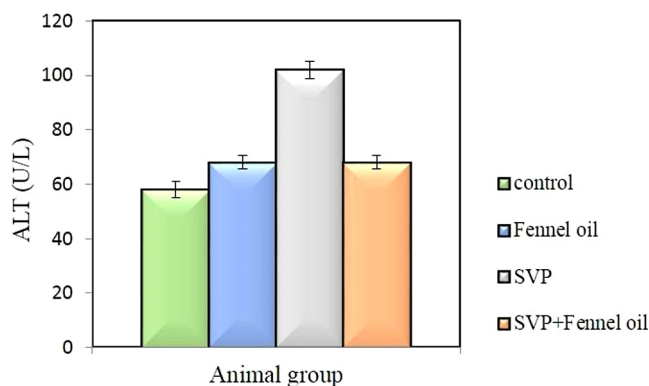


Figure 5(B) Showing changes in ALT enzyme catalytic activity are presented as relative activities in comparison to control group values. The control and fennel oil treated groups show normal ALT activity level with a slight increase in the fennel group over the control group. However, the animal group treated with SVP show significant increase in ALT enzyme activity. The group treated with SVP plus fennel oil shows a significant decline in the ALT level in comparison to the group treated with SVP.

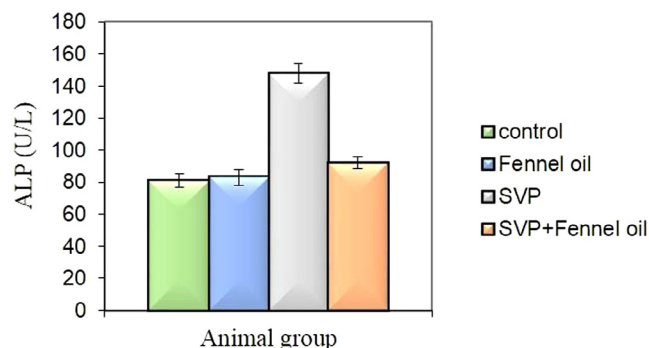


Figure 5(C) Showing changes in ALP enzyme catalytic activity are presented as relative activities in comparison to control group values. The control and fennel oil groups show normal ALP activity level. However, the animal group treated with SVP shows a significant increase in ALP enzyme activity. The group treated with SVP plus fennel oil shows a significant decline in the ALP level, similar to the control group in comparison to the group treated with SVP.

recent years, there has been an increased interest in the possible role of reactive oxygen species (ROS) in the pathogenesis of tissue injury (Tung and Winn, 2011). According to several investigators, ROS are the main mediator of VPA toxicity. For instance, VPA-induced ROS generation has been observed to cause hepatotoxicity (Tong et al., 2005), neurotoxicity (Auinger et al., 2009), teratogenicity (Tung and Winn, 2011), and renal toxicity (Chaudhary et al. 2015). In addition, it has been suggested that free radical scavengers such as SOD and CAT were depleted in VPA-receiving patients (Graf et al., 1998). Cotariu et al. (1990) has reported that depletion of the antioxidant glutathione (GSH) was proposed as one of the mechanisms leading to valproic acid-associated toxicity. Thus, the recorded toxicity of SVP in this work may be attributed to its oxidative stress.

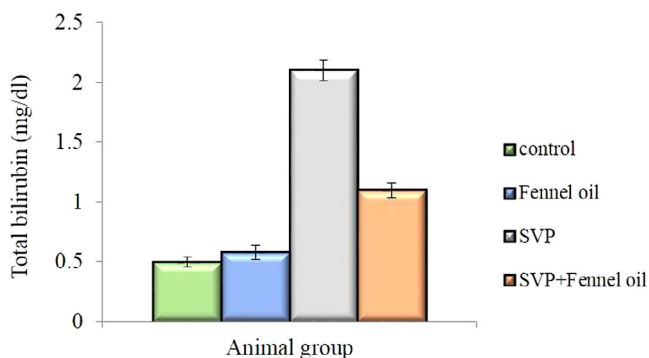


Figure 6(A) Showing changes in total-bilirubin presented as relative activities in comparison to control group values. The control and fennel oil groups show normal bilirubin activity level. However, the animal group treated with SVP shows a significant increase in bilirubin activity. The group treated with SVP plus fennel oil shows a marked decline in the bilirubin level in comparison to the group treated with SVP.

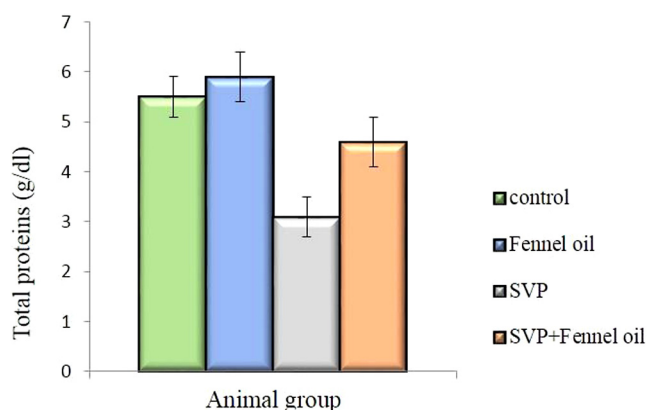


Figure 6(B) Showing changes in total proteins presented as relative activities in comparison to control group values. The control and fennel oil groups show normal total proteins content activity level. However, the animal group treated with SVP shows a significant reduction in total proteins content. The group treated with SVP plus fennel oil shows a marked increase in the total proteins level in comparison to the group treated with SVP.

Several volatile organic compounds, sometimes referred to as VOCs found in fennel seed extracts have been found including; trans-anethole, fenchone, methylchavicol, limonene, α -pinene, camphene, β -pinene, β -myrcene, α -phellandrene, 3-carene, camphor and cisanethole could affect the toxicity caused by chemical treatments (Simandi et al., 1999). Some of these component; D-limonene and β -myrcene have been documented to affect liver function and D-limonene has been suggested to increase the concentration of reduced glutathione level in the liver (Reicks and Crankshaw, 1993; Rodwell, 1993). Singh et al. (2006) have found that more than 80% of the essential oil components of fennel is composed of trans-anethole component. Thus, with regard to these valuable reports the protective effect of fennel oil against toxicity of SVP recorded in this work may be due to its antioxidant activity.

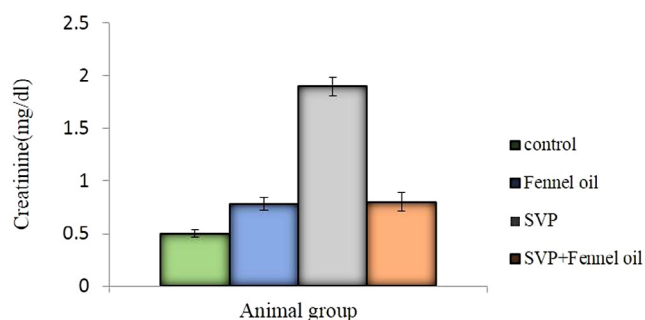


Figure 7(A) Showing changes in Creatinine level presented as relative activities in comparison to control group values. The control and fennel oil groups show normal total Creatinine level activity level. However, the animal group treated with SVP show significant increase in Creatinine level. The group treated with SVP plus fennel oil shows a significant decline in the Creatinine level in comparison to the group treated with SVP.

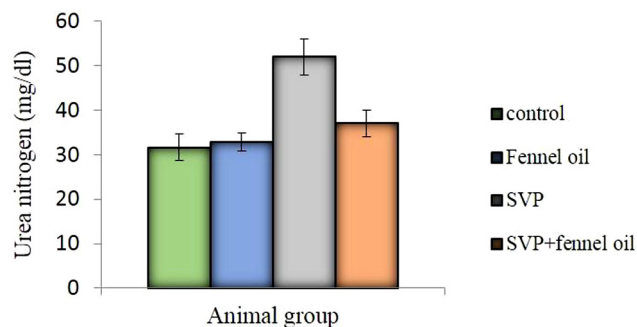


Figure 7(B) Showing changes in Urea nitrogen level presented as relative activities in comparison to control group values. The control and fennel oil groups show normal total urea nitrogen level activity level. However, the animal group treated with SVP show significant increase in urea nitrogen level. The group treated with SVP plus fennel oil shows a significant decrease in the urea nitrogen level in comparison to the group treated with SVP.

References

- Aktas, A., Nergiz, Y., Akkus, M., Nasir, Y., 2010. The effects of valproic acid on renal corpuscle of pregnant rats and protective role of folic acid and vitamin E. *Afr. J. Biotechnol.* 9 (34), 5605–5610.
- Asadi-Samani, M., Rafeian-Kopaei, M., Azimi, N., 2013. Gundelia: a systematic review of medicinal and molecular perspective. *Pak. J. Biol. Sci.* 16, 1238–1247.
- Auinger, K., Müller, V., Rudiger, A., Maggiorini, M., 2009. Valproic acid intoxication imitating brain death. *Am. J. Emerg. Med.* 27, 1177.
- Brandt, C., Gastens, A.M., Sun, M.Z., Hausknecht, M., Loscher, W., 2006. Treatment with valproate after status epilepticus: effect on neuronal damage, epileptogenesis, and behavioral alterations in rats. *Neuropharmacology* 51, 789–804.
- Aggarwal, Bharat B., Kunnumakkara, Ajaikumar B., Harikumar, Kuzhuvilil B., Tharakan, Sheeja T., Sung, Bokyung, Anand, Preetha, 2008. Potential of spice-derived phytochemicals for cancer prevention. *Planta Med.* 74 (13), 1560–1569.
- Chang, Sh, Bassiri, A., Jalali, H., 2013. Evaluation of antioxidant activity of fennel (*Foeniculum vulgare*) seed extract on oxidative stability of olive oil. *J. Chem. Health Risks.* 3 (2), 53–61.

- Chang, Renin, Chou, Mei-Chia, Hung, Li-Ying, Wang, Mu-En, Hsu, Meng-Chieh, Chiu, Chih-Hsien, 2016. Study of Valproic Acid-Enhanced Hepatocyte Steatosis. *BioMed Research International*. Article ID 9576503, 11 pages.
- Chatterjee, S., Goswami, N., Bhatnagar, P., 2012. Estimation of phenolic components and *in vitro* antioxidant activity of fennel (*Foeniculum vulgare*) and ajwain (*Trachyspermum ammi*) seeds. *Adv. Biores.* 3 (2), 109–118.
- Chaudhary, S., Ganjoo, P., Raiusddin, S., Parvez, S., 2015. Nephro-protective activities of quercetin with potential relevance to oxidative stress induced by valproic acid. *Protoplasmata* 252 (1), 209–217.
- Ching-Yuang, L., Chiang, H., 1988. Sodium valproate-induced interstitial nephritis. *Nephron* 48 (1), 43–46.
- Choi, E.M., Hwang, J.K., 2004. Antiinflammatory, analgesic and antioxidant activities of the fruit of *Foeniculum vulgare*. *Fitoterapia* 75 (6), 557–565.
- Cotariu, D., Evans, S., Zaidman, J.L., Marcus, O., 1990. Early changes in hepatic redox homeostasis following treatment with a single dose of valproic acid. *Biochem. Pharmacol.* 40, 589–593.
- Coyle, T.E., Bair, A.K., Stein, C., Vajpayee, N., Mehdi, S., Wright, J., 2005. Acute leukemia associated with valproic acid treatment: a novel mechanism for leukemogenesis. *Am. J. Hematol.* 78, 256–260.
- Delaram, M., Kheiri, S., Hodjati, M.R., 2011. Comparing the effects of echinop hora-platyloba, fennel and placebo on pre-menstrual syndrome. *J. Reprod. Infertil.* 12 (3), 221–226.
- Faudale, M., Viladomat, F., Bastida, J., Poli, F., Codina, C., 2008. Antioxidant activity and phenolic composition of wild, edible, and medicinal fennel from different Mediterranean countries. *J. Agric. Food Chem.* 56 (6), 1912–1920.
- Felker, B.L., Sloan, K.L., Dornitz, J.A., Barnes, R.F., 2003. The safety of valproic acid use for patients with hepatitis C infection. *Am. J. Psychiatry* 160, 174–178.
- Fukuda, Y., Watanabe, H., Ohtomo, Y., Yabuta, K., 1996. Immunologically mediated chronic tubulo-interstitial nephritis caused by valproate therapy. *Nephron* 72, 328–329.
- Gezginci-Oktayoglu, S., Turkyilmaz, I., Ercin Yanardag, R., Bolkent, S., 2016. Vitamin U has a protective effect on valproic acid-induced renal damage due to its anti-oxidant, anti-inflammatory, and antifibrotic properties. *Protoplasmata* 253, 127–135.
- Graf, W.D., Oleinik, O.E., Glauser, T.A., Maertens, P., Eder, D.N., Pippenger, C.E., 1998. Altered antioxidant enzyme activities in children with a serious adverse experience related to valproic acid therapy. *Neuropediatrics* 29, 195–201.
- Gokee, S., Durmaz, Z., Coskun, E., Aydogan, A., Goglu, Mine S., Semra, C., 2010. Valproic acid-associated vanishing bile duct syndrome. *J. Child Neurol.* 25 (7), 909.
- Castro, Hans T., Martíne, Jairo René, Stashenko, Elena, 2010. Anethole isomerization and dimerization induced by acid sites or UV irradiation. *Molecules* 15, 5012–5030.
- Henry, T.R., 2003. The history of valproate in clinical neuroscience. *Psychopharmacol. Bull.* 37 (Suppl. S2), 5–16.
- Ibrahim, M.A., 2012. Evaluation of hepatotoxicity of valproic acid in albino mice, histological and histochemical studies. *Life Sci.* J. 9 (4), 153–159.
- Janneke, J., Maria, A.L., Dolk, H., Barisic, I., Garne, E., Morris, J.K., Lolkje, T.W., 2010. Valproic acid monotherapy in pregnancy and major congenital malformations. *N. Engl. J. Med.* 362, 2185–2193.
- Jessberger, S., Nakashima, K., Clemenson, G.D., Mejia, E., Mathews, E., Ure, K., Ogawa, S., Sinton, C.M., Gage, F.H., Hsieh, J., 2007. Epigenetic modulation of seizure-induced neurogenesis and cognitive decline. *J. Neurosci.* 27, 5967–5975.
- Johannessen, C.U., 2000. Mechanisms of action of valproate: a commentary. *Neurochem. Int.* 37, 103–110.
- Khan, S.K., Shakoor, K.A., Jan, M.A., Khattak, A.M., Shah, S.H., 2005. Study of histopathological changes in the liver of albino rats, induced by toxic dose of valproic acid. *Gomal J. Med. Sci.* 3, 15–18.
- Kooti, W., Ghasemiboroon, M., Asadi-Samani, M., Ahangarpour, A., Abadi, A., Noori, M., 2014. The effects of hydro-alcoholic extract of celery on lipid profile of rats fed a high fat diet. *Adv. Environ. Biol.* 8 (9), 325–330.
- Kumar, R.S., Manivannan, R., Balasubramaniam, A., Raj Kapoor, B., 2008. Antioxidant and hepatoprotective activity of ethanol extract of *Indigofera trita* Linn. on CCl4 induced hepatotoxicity in rats. *J. Pharmacol. Toxicol.* 3, 344–350.
- Lee, M.H., Hong, I., Kim, M., Lee, B.H., Kim, J.H., Kang, K.S., Kim, H.L., Yoon, B.I., Chung, H., Kong, G., Lee, M.O., 2007. Gene expression profiles of murine fatty liver induced by the administration of valproic acid. *Toxicol. Appl. Pharmacol.* 220 (1), 45–59.
- Lewis, J.H., Zimmerman, H.J., Garrett, C.T., Rosenberg, E.V., 1982. Valproate-induced hepatic steatogenesis in rats. *Hepatology* 2, 870–873.
- Lenoir, G.R., Perignon, J.L., Gubler, M.C., Broyer, M., 1981. Valproic acid: a possible cause of proximal tubular renal syndrome. *J. Pediatr.* 98 (3), 503–504.
- Mathis, R.K., Lindhal, J.A., Freese, D.K., Sharp, H.L., 1979. Valproic acid and hepatocyte failure in children. *Paediatr. Res.* 13, 527.
- Rather, Manzoor A., Dar, Bilal A., Sofi, Shah Nawaz N., Bhat, Bilal A., Qurishi, Mushtaq A., 2012. *Foeniculum vulgare*: a comprehensive review of its traditional use, phytochemistry, pharmacology, and safety. *Arab. J. Chem.* <http://dx.doi.org/10.1016/j.arabj.2012.04.011>.
- Mannaa, F.A., Ibrahim, N.A., Ibrahim, S.S., Abdel-Wahhab, K.G., Hassan, N.S., Mohammed, S.G., 2015. Preventive role of chamomile flowers and fennel seeds extracts against liver injury and oxidative stress induced by an immunosuppressant drug in rats. *Hepatoma Res.* 1, 125–135.
- Mirabolghasemi, G., Alizadeh, F., 2014. The effect of hydroalcoholic extract of fennel (*Foeniculum vulgare*) seed on serum levels of sexual hormones in female wistar rats with polycystic ovarian syndrome (PCOS). *Arak Med. Univ. J.* 17 (5), 70–78.
- Mohamad, R.H., El-Bastawesy, A.M., Abdel-Monem, M.G., 2011. Antioxidant and anticarcinogenic effects of methanolic extract and volatile oil of fennel seeds (*Foeniculum vulgare*). *J. Med. Food* 14 (9), 986–1001.
- Morán-Salvador, E., López-Parra, M., García-Alonso, V., 2011. Role for PPAR γ in obesity-induced hepatic steatosis as determined by hepatocyte- and macrophage-specific conditional knockouts. *FASEB J.* 25 (8), 2538–2550.
- Rabeh, Naeem M., Aboraya, Alaa O., 2014. Hepatoprotective effect of dill (*Anethum graveolens* L.) and Fennel (*Foeniculum vulgare*) oil on hepatotoxic rats. *Pak. J. Nutr.* 13 (6), 303–309.
- Nadebaum, C., Anderson, V., Vajda, F., Reutens, D., Wood, Barton S., 2011. Australian brain and cognition and antiepileptic drugs study: IQ in school-aged children exposed to sodium valproate and polytherapy. *J. Int. Neuropsychol. Soc.* 17, 133–142.
- Naik, R.S., Mujumdar, A.M., Ghaskadbi, S., 2004. Protection of liver cells from ethanol cytotoxicity by curcumin in liver slice culture *in vitro*. *J. Ethnopharmacol.* 95, 31–37.
- Okdah, Y., Ibrahim, S., 2014. Effect of aqueous saffron extract (*Crocus sativus* L.) on sodium valproate-induced histological and histochemical alterations in liver of albino rats. *Int. J. Adv. Res.* 2 (7), 735–745.
- Ornoy, A., 2006. Neuroteratogens in man: an overview with special emphasis on the teratogenicity of antiepileptic drugs in pregnancy. *Reprod. Toxicol.* 22, 214–226.
- Ostad, S.N., Soodi, M., Shariffzadeh, M., Khorshidi, N., Marzban, H., 2001. The effect of fennel essential oil on uterine contraction as a model for dysmenorrhea, pharmacology and toxicology study. *J. Ethnopharmacol.* 76 (3), 299–304.
- Ozbek, H., Uğraş, S., Dülger, H., Bayram, I., Tuncer, I., Oztürk, G., Oztürk, A., 2003. Hepatoprotective effect of *Foeniculum vulgare* essential oil. *Fitoterapia* 74, 317–319.
- Pai, M.B., Prashant, G.M., Murlikrishna, K.S., Shivakumar, K.M., Chandu, G.N., 2010. Antifungal efficacy of *Punica granatum*,

- Acacia nilotica*, *Cuminum cyminum* and *Foeniculum vulgare* on *Candida albicans*: An *in vitro* study. *Indian J. Dent. Res.* 21 (3), 334–336.
- Powell-Jackson, P.R., Tredger, J.M., Williams, R., 1984. Hepatotoxicity to sodium valproate: a review. *Gut* 25, 673–681.
- Rafatullah, S., Al-Yahya, M., Mossa, J., Galal, A., El-Tahir, K., 2006. Preliminary phytochemical and hepatoprotective studies on Turinip *Brassica rapa* L. *Int. J. Pharmacol.* 2, 67–73.
- Raza, M., Al-Shabanah, O.A., Al-Bekairi, A.M., Qureshi, S., 2000. Pathomorphological changes in mouse liver and kidney during prolonged valproate administration. *Int. J. Tissue React.* 22, 15–21.
- Reicks, M.M., Crankshaw, D., 1993. Effects of D-limonene on hepatic microsomal monooxygenase activity and paracetamol-induced glutathione depletion and fractionation of Fennel oil. *J. Agric. Food Chem.* 47, 1635–1640.
- Rodwell, V.W., 1993. Peptides. In: Murray, R.K., Granner, D.K., Mayes, P.A. (Eds.), *Harper's Biochemistry*. 24th ed. Appleton & Lange, USA, pp. 33–40.
- Saleh, D.A.A., Ismail, M.A., Ibrahim, A.M., 2012. Nonalcoholic fatty liver disease, insulin resistance, dyslipidemia and atherogenic ratios in epileptic children and adolescents on long term antiepileptic drug therapy. *Pak. J. Biol. Sci.* 15 (2), 68–77.
- Senturk, V., Goker, C., Bilgic, A., Olmez, S., Tugcu, H., Oncu, B., Atbasoglu, E.C., 2007. Impaired verbal memory and otherwise spared cognition in remitted bipolar patients on monotherapy with lithium or valproate. *Bipolar Disord.* 9 (Suppl. S1), 136–144.
- Stephens, R., Levy, H., 1992. Valproate hepatotoxicity syndrome: hypothesis of pathogenesis. *Pharm. Weekbl. Sci.* 14, 118–121.
- Stohs, S.J., Lawson, T.A., Anderson, L., Bueding, E., 1986. Effects of oltipraz, BHA, ADT and cabbage on glutathione metabolism, DNA damage and lipid peroxidation in old mice. *Mech Ageing Dev.* 37, 137–145.
- Simandi, B., Deck, A., Ronyani, E., Yanxiang, G., Veress, T., Lemberkovic, E., Then, M., SassKiss, H., Vomos-Falusi, Z., 1999. Supercritical carbon dioxide extraction in mouse. *Xenobiotica* 23 (7), 80–91.
- Singh, B., Kale, R.K., 2008. Chemomodulatory action of *Foeniculum vulgare* (Fennel) on skin and forestomach papillomagenesis, enzymes associated with xenobiotic metabolism and antioxidant status in murine model system. *Food Chem Toxicol.* 46 (12), 3842–3850.
- Singh, Gurdip, Maurya, Sumitra, de-Lampasona, M.P., Catalan, C., 2006. Chemical constituents, antifungal and antioxidative potential of *Foeniculum vulgare* volatile oil and its acetone extract. *Food Control.* 17, 745–752.
- Sofowora, E.A., 1993. *Medicinal Plants and Traditional Medicine in Africa*. John Willey and Sons, Chichester, p. 178.
- Spiller, H.A., Spiller, H., Krenzelok, E.P., Klein-Schwartz, W., Winter, M., Weber, J.A., 2000. Multicenter case series of valproic acid ingestion: serum concentrations and toxicity. *J. Toxicol. Clin. Toxicol.* 38 (7), 755–760.
- Sztajnkrzyer, M.D., 2002. Valproic acid toxicity: overview and management. *J. Toxicol. Clin. Toxicol.* 40, 789–801.
- Tong, V., Teng, X.W., Chang, T.K., Abbott, F.S., 2005. Valproic acid II: effects on oxidative stress, mitochondrial membrane potential, and cytotoxicity in glutathione-depleted rat hepatocytes. *Toxicol. Sci.* 86, 436–443.
- Tung, E.W., Winn, L.M., 2011. Valproic acid increases formation of reactive oxygen species and induces apoptosis in postimplantation embryos: a role for oxidative stress in valproic acid-induced neural tube defects. *Mol. Pharmacol.* 80, 979–987.
- Watanabe, T., Yoshikawa, H., Yamazaki, S., Abe, Y., Abe, T., 2005. Secondary renal Fanconi syndrome caused by sodium valproate therapy. *Pediatr. Nephrol.* 20, 814–817.
- Wang, L., Zhang, T., Zhang, J.L., Yu, Y., Gan, Z.M., 2012. Experimental study of Chinese herb *Foeniculum vulgare* Mill on liver hepatic fibrosis and potassium supplement in rats. *J. Xinjiang Med. Univ.* 9, 12.
- Wesam, Kooti, Maryam, Moradi, Sara, Ali-Akbari, Naim, Sharafi-Ahvazi, Majid, Asadi-Samani, Damoon, Ashtary-Larky, 2015. Therapeutic and pharmacological potential of *Foeniculum vulgare* Mill: a review. *J. Herb. Med. Pharmacol.* 4 (1), 1–9.
- Yoshikawa, H., Watanabe, T., Abe, T., 2002. Tubulo-interstitial nephritis caused by sodium valproate. *Brain Dev.* 24, 102–105.