

Bile duct drainage: Terminology

Majid Abdularahman Almadi^{1,2}

¹Division of Gastroenterology, King Khalid University Hospital, King Saud University, Riyadh, Saudi Arabia; ²Division of Gastroenterology, The McGill University Health Center, Montreal General Hospital, McGill University, Montreal, Canada

INTRODUCTION

EUS has become an essential component in the management of pancreaticobiliary disorders. One of the recent applications of EUS is EUS-guided biliary drainage (EUS-BD). During the earliest applications of EUS-BD, different techniques and approaches have been used, as the procedure evolved, and as such there has been variability in the nomenclature used to describe these procedures.

The importance of unifying the terminology used when describing these procedures goes beyond the convenience of communication between endoscopists and other health-care providers on which procedure was used, but also allows a better description of the optimal indications of each procedure and comparison between their outcomes.

The Asian EUS group has proposed a nomenclature describing EUS-BD that was based on whether EUS is used as an “access” procedure or as a primary drainage method [Figure 1]. It also takes into account whether the intervention restores biliary flow through the normal anatomy or results in new transluminal connections. This classification also depends on the aim of the intervention (*e.g.* biliary stone removal) as well

as the access point used.^[1] A comprehensive guideline on the optimal management in interventional EUS procedures has been published by the same group.^[2]

We describe each of these EUS-BD procedures using the standardized nomenclature that has been proposed by the Asian EUS group.

EUS-GUIDED BILIARY ACCESS

In the strict manner, EUS-guided biliary access is not considered a BD procedure, but rather a procedure that facilitates ERCP instead of the usual percutaneous rendezvous technique (RV) where an interventional radiologist inserts a wire through the skin into the biliary system and through the papilla in an antegrade fashion [Figure 2].

EUS RENDEZVOUS TECHNIQUE

EUS-RV is used when there is a possibility to reach the ampulla with a regular duodenoscope. The point of puncture and introduction of the wire could be through the stomach (transhepatic), in which case the procedure is coined as EUS Rendezvous transhepatic (EUS-RV/TH) approach, or from the bulb or second part of the duodenum (extrahepatic), in which case the procedure

Access this article online	
Quick Response Code: 	Website: www.eusjournal.com
	DOI: 10.4103/eus.eus_54_19

This is an open access journal, and articles are distributed under the terms of the Creative Commons Attribution-NonCommercial-ShareAlike 4.0 License, which allows others to remix, tweak, and build upon the work non-commercially, as long as appropriate credit is given and the new creations are licensed under the identical terms.

How to cite this article: Almadi MA. Bile duct drainage: Terminology. *Endosc Ultrasound* 2019;8:S3-6.

Address for correspondence

Dr. Majid Abdularahman Almadi, Division of Gastroenterology, King Khalid University Hospital, King Saud University, Riyadh, Saudi Arabia. E-mail: maalmadi@ksu.edu.sa

Received: 2019-06-11; **Accepted:** 2019-07-15; **Published online:** 2019-11-28

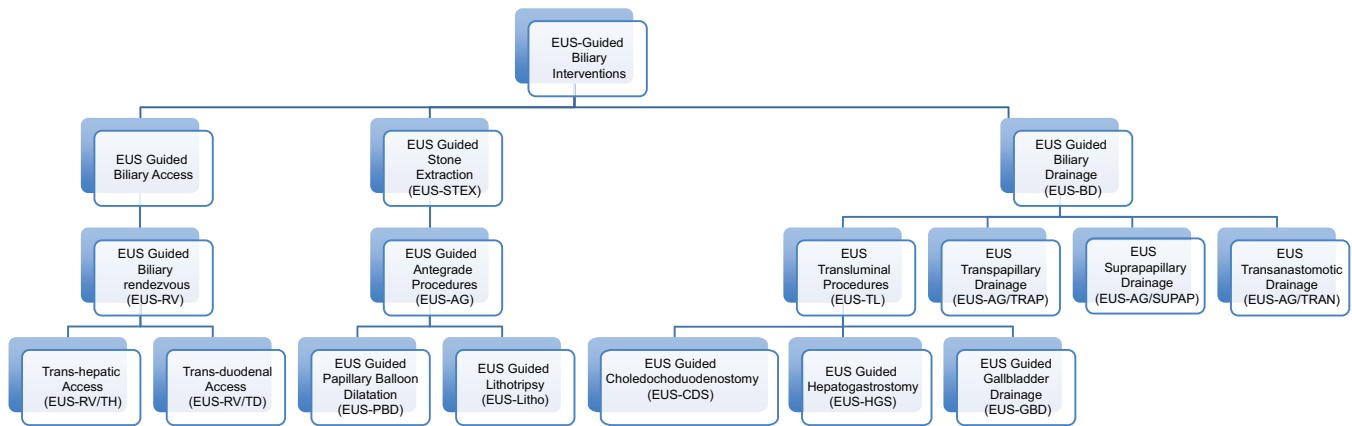


Figure 1. EUS-guided biliary interventions

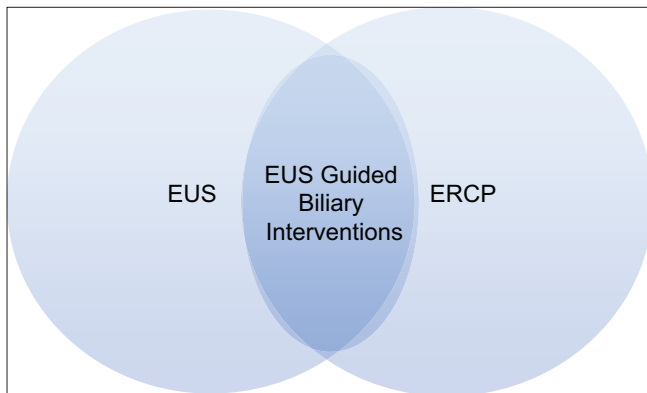


Figure 2. EUS can be used as a facilitator to access the biliary system while continuing the procedure by ERCP

would be called as EUS-RV/transduodenal (EUS-RV/TD) approach.^[3] The choice of the site of puncture is governed by multiple factors, including the suspected level of obstruction and which site is more favorable technically [Figure 3].

EUS-GUIDED BILIARY DRAINAGE

These comprise proper EUS-guided decompression procedures where the primary instrument of BD is an echoendoscope. These can be EUS transluminal procedures where a stent is inserted from the gastrointestinal lumen through the gastrointestinal wall into the biliary system or the gallbladder (*i.e.*, creating an artificial conduit), and bile would flow from the biliary tree to the gastrointestinal lumen through this artificial conduit. Another form of EUS-BD is EUS-guided antegrade interventions where the echoendoscope is used to puncture the biliary tree from the gastrointestinal lumen and insert a guidewire and then a stent through the wall and eventually traverse the site of obstruction, and bile would flow through the normal physiological route [Figure 1].

TRANSLUMINAL EUS-GUIDED BILIARY DRAINAGE

These procedures are used when an ERCP has failed or is not possible due to anatomical considerations or procedure-related difficulties.

EUS-GUIDED HEPATOGASTROSTOMY

In this procedure, the biliary system is punctured from the cardia or the lesser curvature of the stomach, and a stent is inserted between the liver and the stomach achieving biliary decompression. This procedure is utilized in cases of hilar biliary obstruction when a rendezvous or antegrade procedure is not possible.

EUS-GUIDED CHOLEDOCODUODENOSTOMY

In this procedure, the echoendoscope is used to puncture the extrahepatic biliary tree from either the duodenal bulb or the second part of the duodenum and a stent is inserted traversing the duodenal wall above the level of the papilla.

EUS-GUIDED GALLBLADDER DRAINAGE

The traditional approach in patients who are nonsurgical candidates for any reason when there is acute cholecystitis has been percutaneous cholecystostomies. As a substitute for this procedure, EUS-guided gallbladder drainage has been utilized with good outcomes and has the advantage of avoiding a cholecystostomy tube that might affect the quality of life of the patient as well as a burden on the caregiver. The echoendoscope is used to insert a stent from the duodenum into the gallbladder and achieve BD. Frequently, a double-pigtail plastic

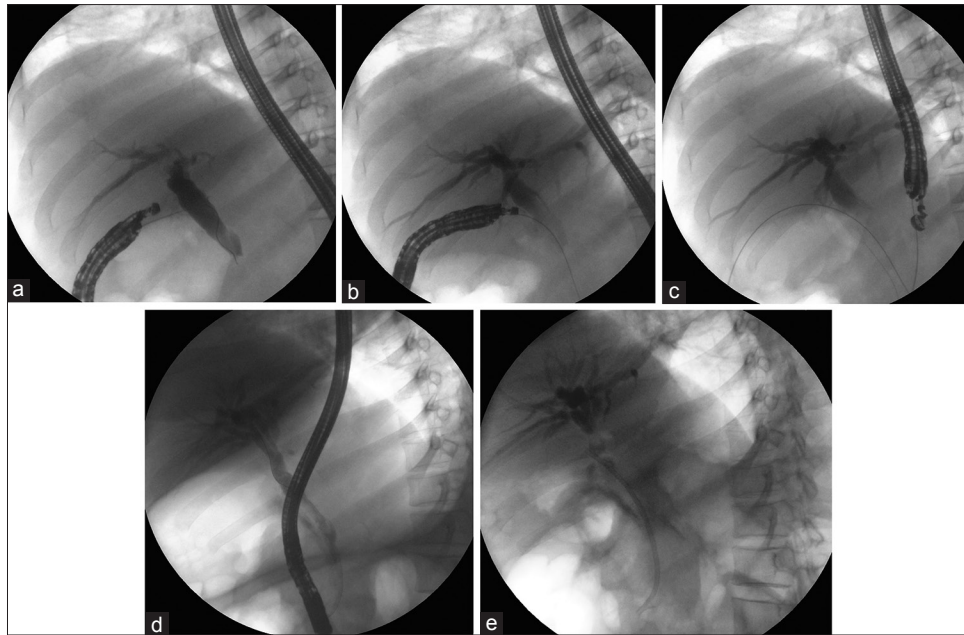

Figure 3. EUS rendezvous. (a) The biliary tree is punctured from the second part of the duodenum, and a guidewire is passed toward the duodenum through the papilla. (b) The wire is successfully passed through the papilla into the duodenum. (c) The echoendoscope is withdrawn while the wire is kept in place. (d) The stent is inserted into the biliary system through an ERCP in a retrograde fashion. (e) The final image depicting the stent in place

stent is used or a self-expandable metal stent as well as double-pigtail stents and/or a nasobiliary tube is inserted into the gallbladder.

EUS-GUIDED ANTEGRADE INTERVENTIONS

This has the theoretical advantage of preserving the normal flow of the biliary system in a similar fashion to an ERCP without creating artificial conduits between the biliary system and the gastrointestinal lumen through the gastrointestinal wall.

EUS-GUIDED ANTEGRADE TRANSPAPILLARY DRAINAGE

After achieving access into the biliary system, a stent is inserted through the gastrointestinal wall and traverses the obstruction, and the stent extends from the common bile duct, with the proximal edge of the stent above the level of the obstruction and the distal end of the stent in the duodenal lumen through the papilla [Figure 4].

EUS-GUIDED ANTEGRADE SUPRAPAPILLARY DRAINAGE

In this case, a stent is inserted through the gastrointestinal wall and traversing the location of

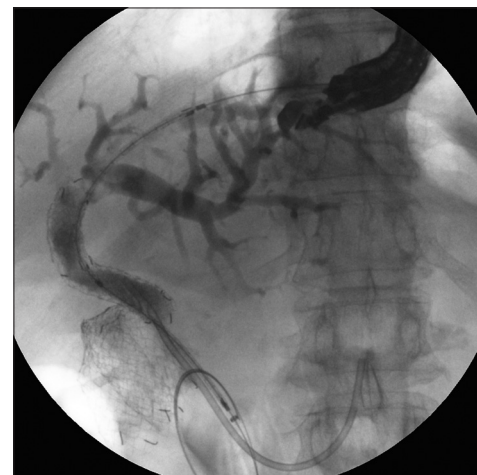

Figure 4. EUS-guided antegrade transpapillary drainage in a patient with a blocked biliary metal stent and a migrated plastic biliary stent that was inserted after that and who has a duodenal metal stent for gastric outlet obstruction

obstruction within the biliary tree (similar to EUS-guided antegrade transpapillary drainage), but the distal end of the stent does not traverse the papilla and rather remains within the biliary system. This technique can be used in patients who have proximal biliary obstruction.

EUS-GUIDED ANTEGRADE TRANSANASTOMOTIC DRAINAGE

This is used in patients who have a surgically created choledocho- or hepaticojejunostomy and

develop obstruction. The stent is inserted with an echoendoscope through the gastrointestinal wall and into the remnant biliary system, and the stent drains through the anastomosis site.

CONCLUSION

EUS-guided biliary interventions are an exciting and attractive new option for patients, which can avoid numerous disadvantages which are associated with our conventional methods of biliary interventions when ERCP fails. Using this unifying nomenclature aids in standardizing the reporting of clinical trials and thus enables aggregating data and comparing

outcomes and better stratifying therapies to appropriate patient settings.

Conflicts of interest

There are no conflicts of interest.

REFERENCES

1. Dhir V, Isayama H, Itoi T, *et al.* Endoscopic ultrasonography-guided biliary and pancreatic duct interventions. *Dig Endosc* 2017;29:472-85.
2. Teoh AY, Dhir V, Kida M, *et al.* Consensus guidelines on the optimal management in interventional EUS procedures: Results from the Asian EUS group RAND/UCLA expert panel. *Gut* 2018;67:1209-28.
3. Dhir V, Bhandari S, Bapat M, *et al.* Comparison of transhepatic and extrahepatic routes for EUS-guided rendezvous procedure for distal CBD obstruction. *United European Gastroenterol J* 2013;1:103-8.