

# Case report: Combined transarterial and direct approaches for embolization of a large mandibular arteriovenous malformation

Chiramel George Koshy, Shyamkumar N Keshava, Vinu Moses, Sudipta Sen<sup>1</sup>

Departments of Radiology and <sup>1</sup>Pediatric Surgery, Christian Medical College, Vellore, Tamil Nadu, India

**Correspondence:** Dr. Shyamkumar N Keshava, Department of Radiology, Christian Medical College, Vellore, Tamil Nadu - 632004, India.  
E-mail: aparna\_shyam@yahoo.com

## Abstract

Arteriovenous malformations (AVMs) that involve the mandible are difficult lesions to treat, with traditional options being surgery and embolization. This article describes a large mandibular AVM that was treated with embolization using transarterial as well as direct puncture approaches. Follow-up imaging showed thrombosis of the vascular spaces of the malformation. There were no complications. The patient is doing well and is on follow-up.

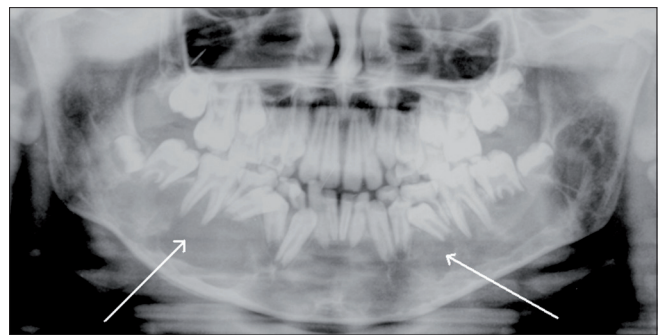
**Key words:** Arteriovenous malformation; embolization; mandible

## Introduction

Arteriovenous malformations (AVMs) of the mandible are rare lesions that have a variety of presentations, including gingival bleeding, dental loosening, swelling, and life-threatening hemorrhage.<sup>[1]</sup> This article describes a large mandibular AVM that was embolized using both transarterial and direct puncture approaches.

## Case Report

An 11-year-old boy presented with a few years' history of gradual generalized enlargement of the mandible. An orthopantomogram [Figure 1] showed a large, well-defined, osteolytic lesion with sclerotic margins within the body of the mandible. A CT scan confirmed the presence of an expansile osteolytic lesion involving the body of the



**Figure 1:** Orthopantomogram shows a large expansile osteolytic lesion (arrows) involving both sides of the body of the mandible

mandible [Figure 2], with enhancement of the lesion. The Doppler study revealed high-velocity blood flow within the vascular spaces of the lesion, suggesting the presence of an AVM. MRI studies were also carried out [Figure 3A and B].

Digital subtraction angiography demonstrated a large AVM within the body of the mandible supplied by branches of both external carotid arteries and draining via a large intraosseous venous sac into the left internal jugular vein [Figure 4]. The feeding arteries were superselectively cannulated and 33% N-butyl cyanoacrylate glue (Histoacryl, B. Braun, Germany) was injected [Figure 5]. Doppler

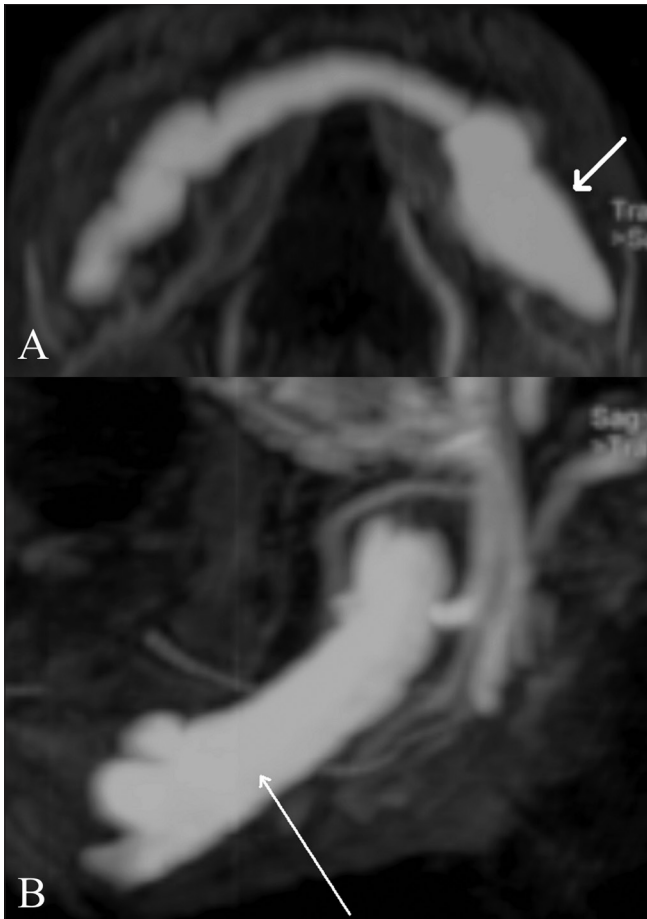
### Access this article online

#### Quick Response Code:

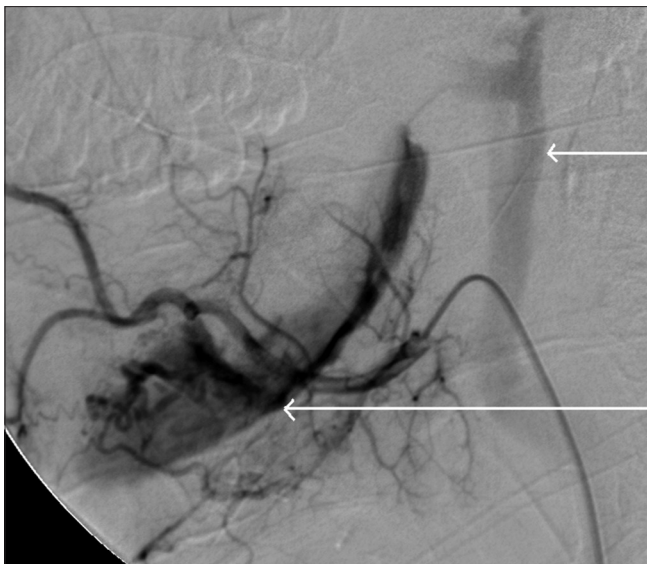


**Website:**  
www.ijri.org

**DOI:**  
10.4103/0971-3026.76044

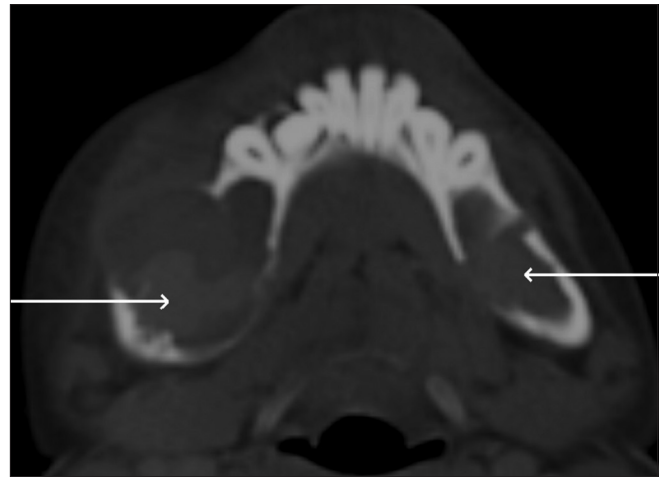


**Figure 3 (A,B):** Axial (A) and sagittal (B) contrast enhanced T1W MR images show the arteriovenous malformation (AVM) (arrows) involving the whole of the body of the mandible

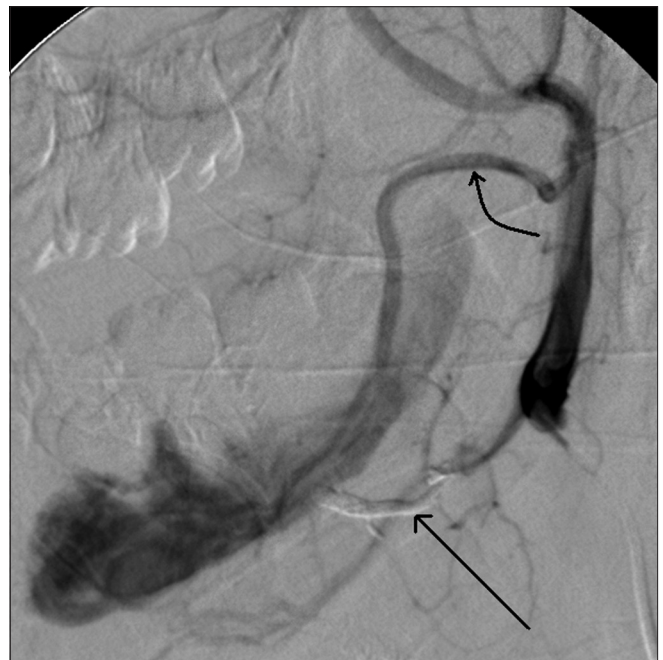

**Figure 4:** Lateral DSA image shows venous drainage of the AVM (long arrow) into the left internal jugular vein (short arrow)

evaluation could demonstrate a reduction in the blood flow into the venous sac. The venous sac was then directly



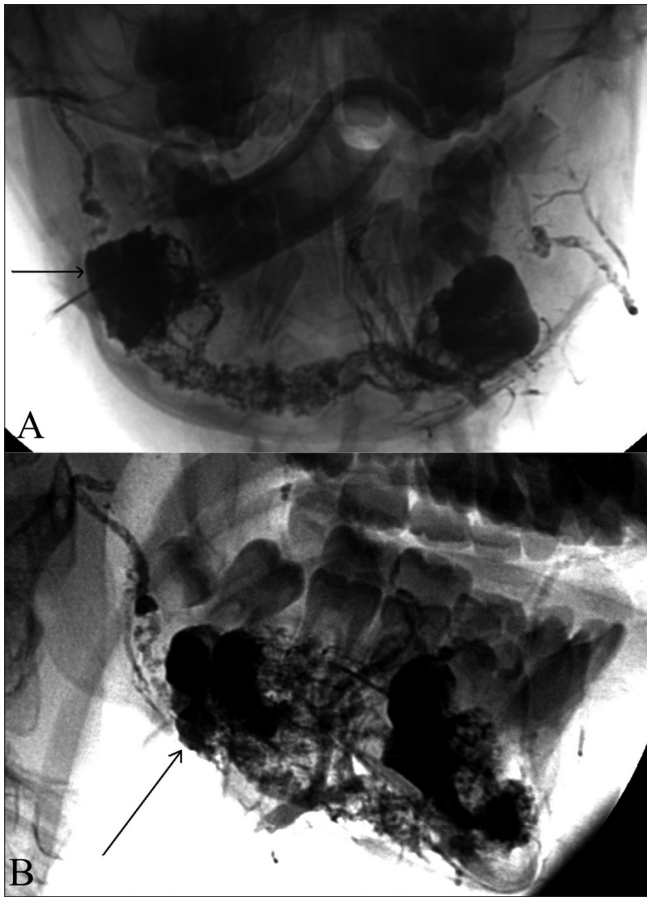
**Figure 2:** Axial, non-enhanced CT scan shows the expansile and osteolytic nature of the lesion, with hyperdense areas within (arrows) signifying partial thrombosis



**Figure 5:** Lateral representative DSA image, of the left external carotid artery shows the embolized branch of the lingual artery seen as a glue-cast (straight arrow) and a hypertrophied anterior branch (curved arrow) from the terminal external carotid artery, supplying the AVM.

punctured under USG guidance through a defect in the bone using a 22G needle. Three milliliters of 20% Histoacryl glue was injected through this needle using fluoroscopic guidance [Figure 6].

The patient did well after the embolization procedure and had no complications. An MRI scan of the mandible performed a few days later showed thrombosis within the vascular spaces of the AVM [Figure 7]. The patient has been asymptomatic since then and is on follow-up.



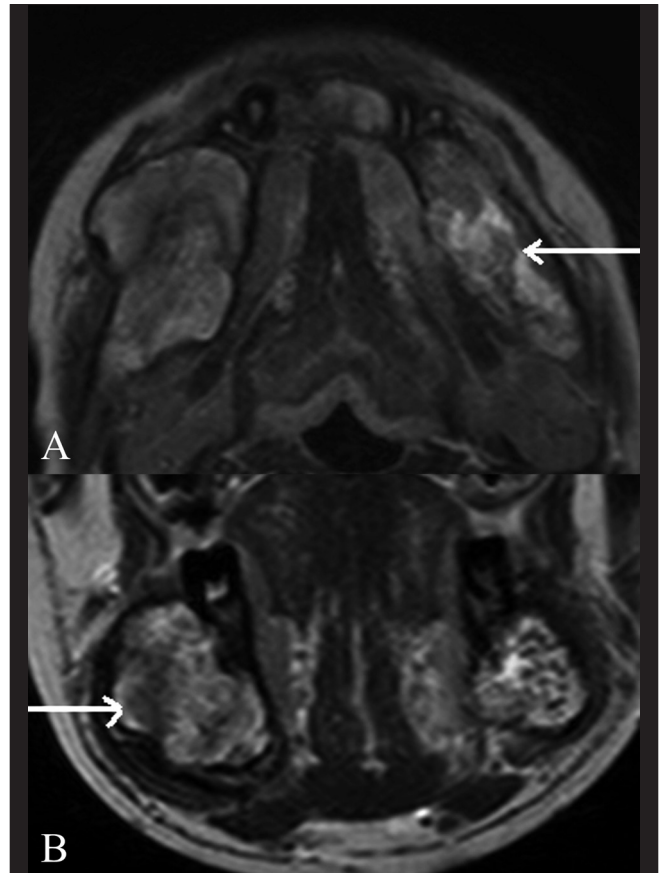
**Figure 6 (A,B):** Frontal (A) and lateral (B) post-embolization radiographs after direct percutaneous glue injection show complete filling of the AVM (arrow) in the mandible with a mixture of N-butyl cyanoacrylate glue and radioopaque contrast agent (Lipiodol)

## Discussion

Mandibular AVMs are rare high-flow vascular malformations that can present with mandibular enlargement, asymmetry, pain, increased mobility of the teeth and hemorrhage that can be life-threatening.<sup>[1]</sup> It is difficult to treat these lesions, the options being surgery and embolization. Complete or partial resection of the mandible after transarterial embolization has been suggested,<sup>[2]</sup> but surgery could potentially result in malocclusion or disfiguration.<sup>[3]</sup>

Embolization of the nidus of the AVM using polyvinyl alcohol particles or N-butyl cyanoacrylate can result in a permanent cure, although treatment failures secondary to recanalization and rebleeding from collaterals have been described.<sup>[4-6]</sup> Embolization of the proximal segments of the feeding arteries should be avoided as the lesion can gradually recruit further arterial feeders from the internal carotid and vertebral arteries. Furthermore, this restricts access for later sessions of transarterial embolization.

Direct puncture of the nidus or the draining varix followed



**Figure 7 (A,B):** Post-embolisation T2W axial (A) and coronal (B) MRI images show thrombosis (arrow) of the AVM in the mandible and the absence of flow voids

by embolization with N-butyl cyanoacrylate or coils has been described.<sup>[5,7-9]</sup> Although direct puncture of the venous varix could provide a simple access, care should be taken to avoid radiation to the operator's hands. Embolization of the venous varix without first embolizing the arterial feeders could potentially raise the intranasal pressure and lead to hemorrhage. Transvenous embolization of the venous varix using the femoral vein route has been described.<sup>[3]</sup>

MRI can be used for follow-up imaging due to its ability to detect flow voids, thrombus, and reossification.<sup>[3]</sup> MRI was used instead of an angiogram for follow-up due to concerns regarding the additional radiation dose.

## Conclusion

Intraosseous AVMs are rare lesions that can be treated using endovascular methods on a case-to-case basis. In the treatment of a mandibular AVM, a combined approach with transarterial followed by venous embolization using a direct puncture of the venous sac is an effective strategy.

## References

1. Chen W, Wang J, Li J, Xu L. Comprehensive treatment of arteriovenous malformations in the oral and maxillofacial region. *J Oral Maxillofac Surg* 2005;63:1484-8.
2. Motamedi MH, Behnia H, Motamedi MR. Surgical technique for the treatment of high-flow arteriovenous malformations of the mandible. *J Craniomaxillofac Surg* 2000;28:238-42
3. Beek FJ, ten Broek FW, van Schaik JP, Mali WP. Transvenous embolisation of an arteriovenous malformation of the mandible via a femoral approach. *Pediatr Radiol* 1997;27:855-7
4. Guibert-Tranier F, Piton J, Riche MC, Merland JJ, Caille JM. Vascular malformations of the mandible (intraosseous haemangiomas). The importance of preoperative embolization. A study of 9 cases. *Eur J Radiol* 1982;2:257-72.
5. Chiras J, Hassine D, Goudot P, Meder JF, Guilbert JF, Bories J. Treatment of arteriovenous malformations of the mandible by arterial and venous embolization. *AJNR Am J Neuroradiol* 1990;11:1191-4
6. Larsen PE, Peterson LJ. A systematic approach to management of high-flow vascular malformations of the mandible. *J Oral Maxillofac Surg* 1993;51:62-9.
7. Doppman JL, Pevsner P. Embolization of arteriovenous malformations by direct percutaneous puncture. *AJR Am J Roentgenol* 1983;140:773-8.
8. Resnick SA, Russell EJ, Hanson DH, Pecaro BC. Embolization of a life-threatening mandibular vascular malformation by direct percutaneous transmandibular puncture. *Head Neck* 1992;14:372-9
9. Fan X, Zhang Z, Zhang C, Tang Y, Hu Y, Mao Q, Qiu W. Direct-puncture embolization of intraosseous arteriovenous malformation of jaws. *J Oral Maxillofac Surg* 2002;60:890-6.

**Source of Support:** Nil, **Conflict of Interest:** None declared.