

# Ipsilateral Fracture Shaft Femur with Neglected Dislocation of Prosthesis: A Case Report

Mantu Jain<sup>1</sup>, Amar Jyoti Bihari<sup>1</sup>, Bhavna Sriramka<sup>2</sup>

## What to Learn from this Article?

*An unique decision making scenario highlighting an equally important role of surgeons skills and Patients Preferences in Clinical Decision Making*

### Abstract

**Introduction:** Neglected hip dislocation is rare in today's world and after prosthesis replacement even rarer finding. However such patients may not report to surgeons until they develop secondary complications. Management of such patient's is a challenge to the treating surgeon and need to be tailored suiting to patient's demands, expectations and constraints of financial resources. We did not find a similar case in the electronic and print media and therefore report this case which was innovatively managed.

**Case Report:** A 60 year farmer presented with fracture shaft femur and ipsilateral dislocation prosthesis of right hip. He had a hemiarthroplasty done for fracture neck of femur in the past but used to walk with a lurch since he started to ambulate after discharge. However he was satisfied despite "some problems" which had caused shortening of his limb. The patient was informed of the various treatment options and their possible complications. He expressed his inability to afford a Total Hip Arthroplasty (THA) at any stage and consented for other options discussed with him. The patient was positioned supine and adductor tenotomy done. Next he was positioned laterally and the fracture was fixed with heavy duty broad dynamic compression plate and screws. The wound was temporarily closed. Now through the previous scar via posterior approach the hip was exposed. The prosthesis was found to be firmly fixed to the proximal femur. The acetabulum was cleared with fibrous tissue. All attempts the prosthesis to relocate the prosthesis failed after several attempts and it was best decided to leave alone. Post operatively period was uneventful. At follow up he refused for any further manoeuvre in future inform of heavy traction and attempts to reduce the same. At one year when he was walking unaided and his X-rays showed that fracture had well united his SF-36 score was PCS-49.6 and MCS-51.9.

**Conclusion:** Ipsilateral shaft femur fracture in chronically dislocated prosthesis, done for fracture neck of femur is a rare clinical entity. Increased stress transfers due to dislocation compounded with osteoporosis makes the shaft vulnerable to fracture even with low velocity injury as in our case. Though fixation of fracture shaft femur is clear and straightforward; management of neglected prosthesis dislocation have to be guided by patient's level of expectations and subjective contentment to adaptation to the altered hip state which influence the overall functional outcome.

**Keywords:** Neglected dislocation, ipsilateral femoral fracture, hip arthroplasty

<sup>1</sup>Department of Orthopaedics, Hitec medical college and Hospital, Rourkela, Odisha, India.

<sup>2</sup>Department of Anesthesia, Ispat General Hospital, Rourkela, Odisha, India.

#### Address of Correspondence

Dr Mantu Jain,  
347/J, Janata Colony, Gudiyari, Raipur, Chhattisgarh. India.  
E mail: montu\_jn@yahoo.com

#### Author's Photo Gallery



Dr. Mantu Jain



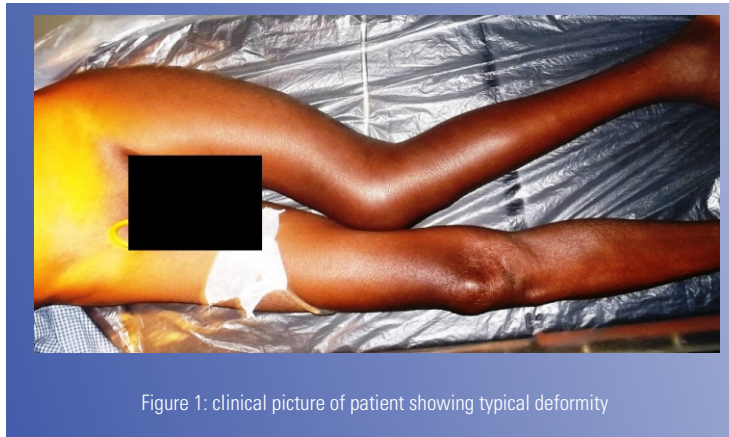
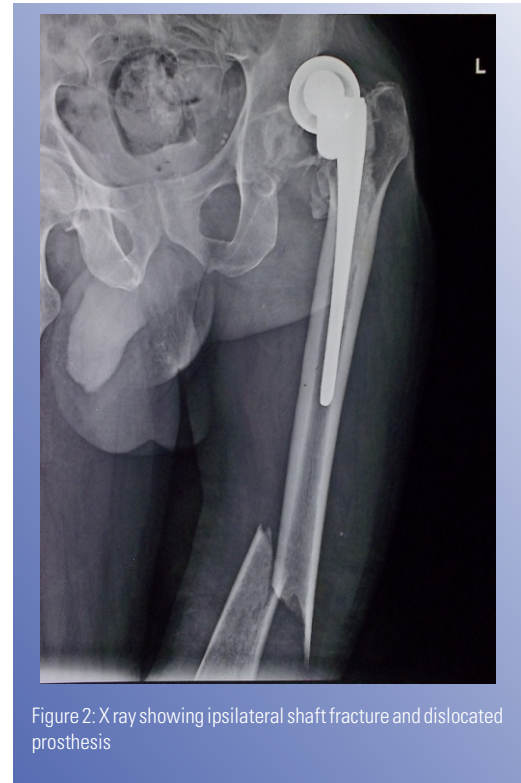Dr. Amar Jyoti Bihari



Dr. Bhavna Sriramka

<p><b>PLAN A</b></p> <p>prosthesis reducible and stable</p> <p>↓</p> <p>reduce and abductor brace</p>	<p><b>PLAN B</b></p> <p>prosthesis reducible and loose</p> <p>↓</p> <p>re cementing the same prosthesis and abductor brace</p>	<p><b>PLAN C</b></p> <p>prosthesis not reducible but loose</p> <p>↓</p> <p>girdlestone arthroplasty</p>	<p><b>PLAN D</b></p> <p>prosthesis not reducible, not loose</p> <p>↓</p> <p>leave it as such</p>
---	--	---	--

Table 1: plan of management



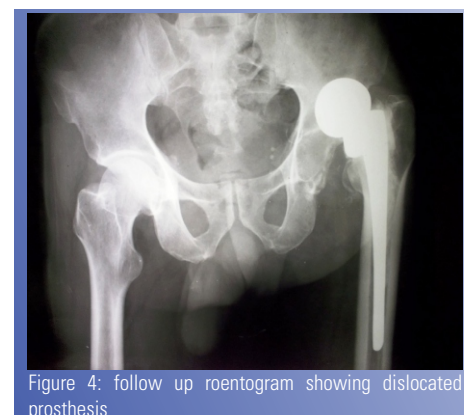**Introduction**

Primary prosthetic replacement is an acceptable treatment option for fracture neck of femur in elderly ambulatory patients. However prosthetic dislocation is a devastating complication [1,2] with reported rate up to 6.5% and those having posterior approaches being 3× more likely to dislocate [3]. Neglected dislocation of hip is a rare in today's world and after prosthesis replacement is even rarer finding. We are not aware of any published reports about neglected posterior dislocation of prosthesis with ipsilateral shaft femur fracture. Here we report a case of this rare type of fracture.

**Case Report**

A 60 year male, farmer by profession presented to casualty

with ipsilateral shaft femur fracture and dislocation of prosthesis in right hip (Fig 1, 2). His past history revealed that he had sustained fracture neck of femur 9 months back for which he had a hemiarthroplasty done. The patient was not sure whether the prosthesis had dislocated recently or was chronic. However he did admit that he always used to walk with a lurch ever since he started to ambulate after discharge. A careful review of his old records revealed that the patient had dislocated his prosthesis at first follow up at 1 month but neglected it due to financial constraints. He was satisfied despite “some problems” which had caused shortening of his limb. He was able to lead his functional life and this was his expectations from the outcome of present surgery (to be

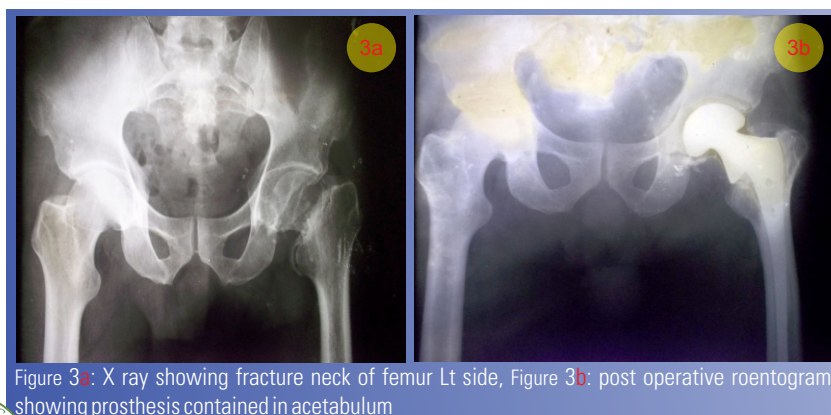

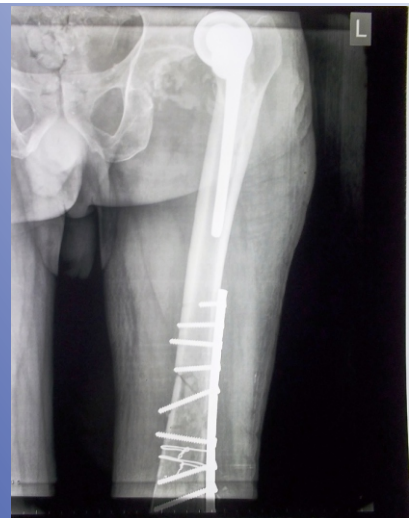


Figure 5: Final ray after fixation of fracture. Prosthesis still remains out of socket

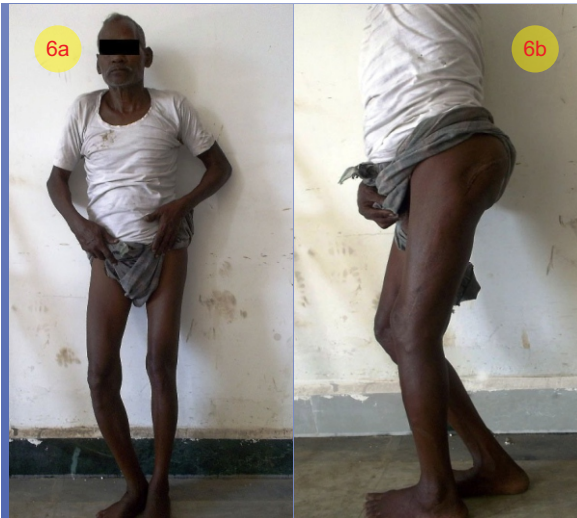

Figure 6a, 6b: Clinical picture of patient at follow up showing unaided weight bearing

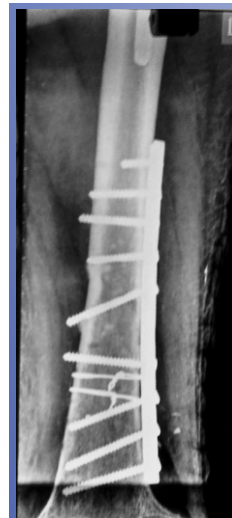

Figure 7: Final X ray showing fracture showing union

able to regain his same life).

His first X-ray (in past hospitalisation) immediate postoperative to hemiarthroplasty showed that the prosthesis was well centred and cemented (fig 3a, b). Subsequent follow up roentogram at 1 month showed the prosthesis out of acetabulum and tip displaced towards the lateral cortex (fig 4). This raised the doubt of possible loosening of prosthesis, though it could have been due to retroversion of prosthesis. We discussed with the parent surgeon to find out any significant intraoperative findings but were none. The patient was informed of the various treatment options and their possible complications. He expressed his inability to afford a Total Hip Arthroplasty (THA) at any stage and consented for other options discussed with him. A plan was formulated to operate the patient as shown in the table 1.

The patient was initially positioned supine on operation table under spinal anesthesia and adductor tenotomy done. Next he was positioned laterally and the fracture was fixed with heavy duty broad dynamic compression plate and screws. The wound was temporarily closed. Then through the previous scar the hip was approached. Sciatic nerve could not be isolated but we presumed it to be lying posterior and we went meticulously till we reached the inferior of prosthetic head and true acetabulum. The prosthesis was found to be firmly fixed to the proximal femur. The acetabulum was filled with fibrous tissue which was excised and the cavity was prepared. The proximal femur was released up to 1 cm below lesser trochanter and the prosthesis was tried to reduce but failed after several attempts. We decided to go ahead with plan D and come out. Both wounds were closed over suction drain. Post operatively patient's sciatic

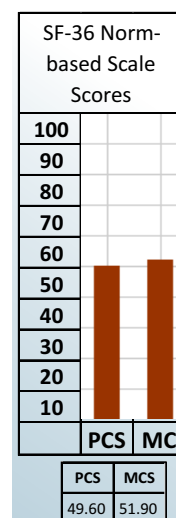
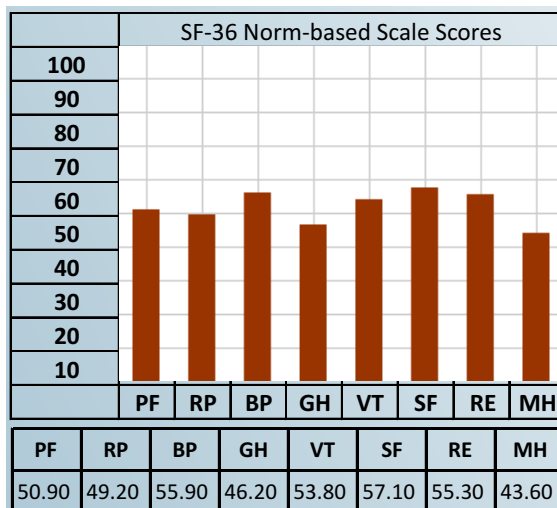
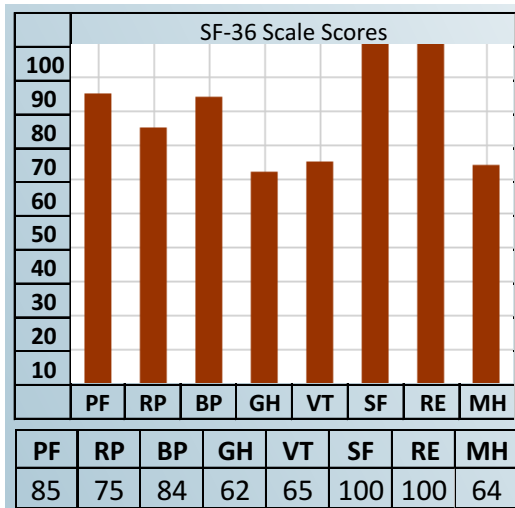
nerve function was confirmed and he was subsequently discharged after 10 days with uneventful recovery. His postoperative X ray is shown in fig 5.

At first follow up, he refused for any further manoeuvre in future in form of heavy traction and attempts to reduce the same. He was subsequently followed upto 1 year when he was walking unaided (fig 6a, b) and his X-rays showed that fracture had well united (fig 7). His SF-36 score was PCS - 49.6 & MCS - 51.9. He was satisfied with his mobility and did not wish for any further intervention

### Discussion

Hemiarthroplasty is a common surgical procedure in elderly patients as a primary treatment for displaced femoral neck fracture. When bipolar hip hemiarthroplasty was introduced, one of its proposed advantages was that the double joint within the implant would reduce the risk of dislocation [4]. However, these arguments for preferential use of bipolar over unipolar hemiarthroplasty have been questioned by several articles [5, 6]. The factors predisposing to dislocation after hemiarthroplasty are multiple [7] but in particular, a posterolateral approach is associated with a significantly increased risk of prosthetic dislocation and has largely been attributed to deficient soft-tissue coverage [3]. In our patient the insertion of prosthesis was approached posteriorly though there were no other contributing factors as discussed with the parent surgeon.

There was no associated trauma as patient was completely unaware regarding the dislocation at first follow up. Again at the time of presentation he had trivial injury in form of twisting when his foot was caught walking on uneven surface. The X-ray findings confirm



the fracture configuration to be rotational low velocity injury as oblique fracture. Decreased motion in the hip joint transfers stress to the femoral shaft, much as in a hip arthrodesis [8]. This compounded with age and osteoporosis makes them vulnerable to fracture [9]. McElfresh and Coventry have identified risk factors associated with late postoperative femoral shaft fractures after total hip arthroplasty and separated stress fractures from fractures caused by trauma violent enough to fracture a normal limb [10].

We made a thorough search of literature and electronic media to formulate treatment protocol for this patient. However we did not find a similar case. Fracture shaft of femur was Vancouver type C and plating was the best and easy option. Neglected prosthesis was akin to neglected dislocation of head of femur except that we had no risks of avascular necrosis. We encountered three peculiar problems pertaining to the case which were-

1. Chronic dislocation had caused shortening and contraction of the pelvi-femoral muscles and thus there was a high chance of failure apart from problems of exposure (to protect the sciatic nerve) and recurrence (proper soft tissue coverage).
2. The traction and abduction technique for chronic dislocation described by Gupta et al [11] could not be applied because of associated ipsilateral femur fracture.
3. Patient consented that he could not afford a total hip arthroplasty (either at present situation or in future if there was a recurrence).

Thus keeping all these considerations into account and patient's preoperative functional status; we proceeded with the surgery.

In literature total hip arthroplasty (THA) has been described for failed bipolar prosthesis [12]. These procedures are challenging and highly demanding

particularly on high hip dislocations. The distortion of the local anatomy, especially considering the proximity of the sciatic nerve, caused by the persistent posterior dislocation of the femoral head/ prosthesis has been well described by Yue et al [13]. This deformation contributes to the difficulty of intraoperative repair. For Crowe III and IV hips, which are dislocated 4 cm above the level of the acetabulum, shortening of the femur is necessary to bring the prosthetic head to the level of the true acetabulum without sciatic nerve injury [14,15,16]. The subtrochanteric osteotomy can be done in different ways [17,18,19]. It can be transverse or step-cut in order to achieve rotational stability, it can be oblique or chevron shaped. However, the other methods are technically more difficult than the transverse osteotomy. The osteotomy is usually performed at approximately 2 cm below the bottom of the lesser trochanter with attention to minimize the damage of periosteum. With trial hip reduction with the proximal part of the femur is then performed, the distal part of the femur is pulled down (so as not to stretch the sciatic nerve under direct observation and palpation) and the point, of the cut in the distal part of the femur determined. A prior electrocauterization in the segments before osteotomy can be made for rotational alignment. Girdlestone resection arthroplasty has also been described as effective salvage procedure, following failed operative treatment for hip trauma [20]. With revolution in revision total hip arthroplasty the indications of this procedure has been limited to medically suboptimal and functionally compromised patients, who may not be suited for any further major interventions. In a developing country like ours where affordability and economic constraints do play a role, the procedure still remains a viable option.



### Conclusion

Ipsilateral shaft femur fracture in chronically dislocated prosthesis, done for fracture neck of femur is a rare clinical entity. Increased stress transfers due to dislocation compounded with osteoporosis makes the shaft vulnerable to fracture even with low velocity injury as in our case. Though fixation of fracture shaft femur is clear and straightforward; management of neglected prosthesis dislocation have to be guided by patient's level of expectations and subjective contentment to adaptation to the altered hip state which influence the overall functional outcome.

### Clinical Message

With advances in the technique of THA and training of more surgeons, hip arthroplasty offers an attractive bailout solutions in most difficult cases. In peripheral parts of developing country like ours where financial constraints and patients lifestyle modulate the management of such patients, one must be aware of all possible options. This article highlights such the various modes of treatment and suggests that plan for every patient must be tailored suiting to patient's demands, expectations and constraints of financial resources.

### References

1. Blewitt N, Mortimore S. Outcome of dislocation after hemiarthroplasty for fractured neck of the femur. *Injury*. 1992; 23:320-322.
2. Paton RW, Hirst P. Hemiarthroplasty of the hip and dislocation. *Injury*. 1989; 20:167-169.
3. Unwin AJ, Thomas M. Dislocation after hemiarthroplasty of the hip: a comparison of the dislocation rate after posterior and lateral approaches to the hip. *Ann R Coll Surg Engl*. 1994; 76:327-329.
4. Nozawa M, Nishiura T, Maezawa K, Matsuda K, Morio H. Dislocation after Hemiarthroplasty due to Insufficiency Fracture of the Superior Acetabulum: A Case Report. *Case Reports in Medicine* Volume 2009, Article ID 257136, 3 pages doi:10.1155/2009/257136
5. Phillips TW. The Bateman bipolar femoral head replacement. A fluoroscopic study of movement over a four-year period. *J Bone Joint Surg Br*. 1987; 69:761-764.
6. Verberne GH. A femoral head prosthesis with a built-in joint. A radiological study of the movements of the two components. *J Bone Joint Surg Br*. 1983; 65:544-547.
7. Joshi A, Lee CM, Markovic L, Vlatis G, Murphy JCM. Prognosis of dislocation after total hip arthroplasty. *J Arthroplasty* 1998;13(1):17-21.
8. Canale ST, Beaty JH. *Campbell's Operative Orthopaedics*, 11th edition, Mosby Philadelphia 2008; chapter 7: 407.
9. Lindahl H, Eisler T, Oden A, et al. Risk factors associated with the late periprosthetic femoral fracture. In: Lindahl H, editor. *The periprosthetic femur fracture: a study from the Swedish National Hip Arthroplasty Register*. Goteberg: Department of Orthopaedics, Sahlgrenska Academy, Goteberg University; 2006.
10. McElfresh EC, Coventry MB. Femoral and pelvic fractures after total hip arthroplasty. *J Bone Joint Surg Am* 1974; 56:483-92.
11. Gupta and Shrivast, 1977. Gupta RC, Shrivast VP: Reduction of neglected traumatic dislocation of the hip by heavy traction. *J Bone Joint Surg* 1977; 59A:249.
12. Diwanji SR, Kim SK, SEon JK, Park SJ, Yoon TR. Clinical result of total hip arthroplasty after failed bipolar arthroplasty. *J Arthroplasty* 2008, 23; 7: 1009-15.
13. Yue JJ, Wilber JH, Lipuma JP. Posterior hip dislocations: a cadaveric angiographic study. *J Orthop Trauma* 1996;10:447-454.
14. Paavilainen T, Hoikka V, Paavilainen P: Cementless total hip arthroplasty for congenitally dislocated or dysplastic hips. *Clin Orthop* 297:71, 1993
15. Symenoides PP, Pournaras J, Petsatodes G, et al: Total hip arthroplasty in neglected congenital dislocation of the hip. *Clin Orthop* 341:55, 1997
16. Hartofilakidis G, Stamos K, Karachalios T, et al: Congenital hip disease in adults. *J Bone Joint Surg Am* 78:683, 1996.
17. Papagelopoulos PJ, Trousdale RT, Lewallen DG. Total hip arthroplasty with femoral osteotomy for proximal femoral deformity. *Clin Orthop* 1996; 332: 151-162
18. Reikeraas O, Lereim P, Gabor I, Gunderson R, Bjerkreim I. Femoral shortening in total arthroplasty for completely dislocated hips. *Acta Orthop Scand* 1996; 67(1):33-36
19. Becker DA, Gustilo RB. Double-chevron subtrochanteric shortening derotational femoral osteotomy combined with total hip arthroplasty for the treatment of complete congenital dislocation of the hip in the adult. Preliminary report and description of a new surgical technique. *J Arthroplasty* 1995; 10:313-318
20. Sharma H, Kakar R. Outcome of Girdlestone's resection arthroplasty following complications of proximal femoral fractures. *Acta Orthop. Belg.*, 2006, 72, 555-559.

Conflict of Interest: Nil  
Source of Support: None

#### How to Cite this Article:

Jain M, Bihari AJ, Sriramka B. Ipsilateral Fracture Shaft Femur with Neglected Dislocation of Prosthesis: A Case Report. *Journal of Orthopaedic Case Reports* 2013 Oct-Dec; 3(4): 26-30