

Laugier–Hunziker syndrome in endocrine clinical practice

Tanja Miličević¹, Ivan Žaja², Deša Tešanović³ and Maja Radman¹

Departments of ¹Endocrinology, Diabetes and Metabolic Diseases, ²Gastroenterology and Hepatology, University Hospital Center Split, University of Split Medical School, Split, Croatia, and ³University of Split Medical School, Split, Croatia

Correspondence
should be addressed
to T Miličević
Email
tanja.milicevic2@gmail.com

Summary

Laugier–Hunziker syndrome (LHS) is a rare, benign and acquired disorder characterized by hyperpigmentation of the oral cavity and lips along with longitudinal melanonychia. No underlying systemic abnormalities or malignant predisposition is associated with it. In everyday clinical practice, an endocrinologist encounters certain endocrine conditions (e.g. Addison's disease, McCune–Albright syndrome) that present with, inter alia, mucocutaneous hyperpigmentation. Even though LHS is easily distinguished from endocrine entities mentioned earlier, diagnostic evaluation usually requires skilled and thorough practitioner. Since it is the diagnosis of exclusion, a number of systemic conditions must be ruled out prior to making the final diagnosis. However, its major differential diagnosis is primarily Peutz–Jeghers syndrome, which carries an increased risk of cancer. Here, we report a case of a young woman who was referred to the endocrinologist for diagnostic evaluation of dark-colored lesions of the oral cavity and nails. All performed laboratory tests were within reference range. Endoscopic gastrointestinal evaluation did not reveal neoplastic formations. Owing to an adult-onset, asymptomatic clinical course and negative diagnostic findings, we made a final diagnosis. In this case, target diagnostic evaluation notably reduced the need for additional expensive and invasive procedures and treatments.

Learning points:

- Laugier–Hunziker syndrome is a rare, acquired cause of asymptomatic, benign mucocutaneous hyperpigmentation.
- Prior to making a final diagnosis, certain medical entities with overlapping clinical features must be excluded.
- Endocrine conditions that usually present with the hyperpigmentation of the skin and mucous membranes (e.g. Addison's disease, McCune–Albright syndrome) can be easily ruled out based on clinical and laboratory findings.
- Its major differential diagnosis, Peutz–Jeghers syndrome is characterized by melanotic macules of the face and mouth, intestinal polyposis and significantly increased risk of different types of cancer, especially gastrointestinal.
- Anamnesis, physical examination and target diagnostic evaluation reduce the need for additional invasive and expensive procedures and treatment.

Background

Laugier–Hunziker syndrome (LHS) is a rare, acquired disorder characterized by a varying number of asymptomatic, lenticular or linear, brown to black mucocutaneous macules. The hyperpigmentation occurs spontaneously in the adulthood and is considered

permanent. Pathophysiology of this syndrome is still unknown. It is considered benign with no systemic manifestation or malignant potential. Prior to making the final diagnosis, it is important to exclude other systemic conditions that require further investigation

and treatment. In the endocrine clinical practice, patients with Addison's disease and McCune–Albright syndrome can present with various types of skin hyperpigmentation but are easily differentiated based on supporting clinical and laboratory findings. This case highlights similar clinical presentation of two medical conditions one of which is benign and negligible while the other one is potentially fatal if not diagnosed on time and properly treated.

Case presentation

During a routine dental check-up, a 38-year-old Caucasian woman was noted to have hyperpigmented areas on the anterior gingiva (Fig. 1). She reported having these changes for the last 4 years without any symptoms. She had recently noticed hyperpigmented stripes on her nails. Dermatologist referred her to see an endocrinologist in order to exclude Addison's disease. The general physical examination was normal. She appeared to be a healthy looking young woman. During the full body skin examination, she was found to have distinct darkened lesions in the inner aspect of the lower lip along with longitudinal hyperpigmented lines of the first left fingernail and the fourth right toenail (Figs 2 and 3). The alteration on her nails appeared to have recently and gradually lost the intensity. Besides, our patient had always been healthy and had not been taking any medication. There were no clinical signs suggestive of endocrine dysfunction. Her menarche occurred at 14 years of age, and her menstrual cycles had been regular. She denied a history of trauma, bone fractures, sexually transmitted diseases or exposures to heavy metals. However, she was a smoker. Her family history was notable for leukemia and breast cancer in her maternal aunt and pancreatic adenocarcinoma in her paternal aunt. There was no knowledge of intestinal polyposis or stomach, intestine or colon cancer in her family.

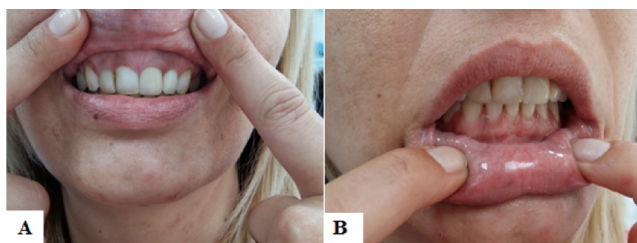

Figure 1
(A) Hyperpigmented brownish areas on the anterior gingiva of the upper jaw. (B) Longitudinal hyperpigmentation on the anterior gingiva of the lower jaw.

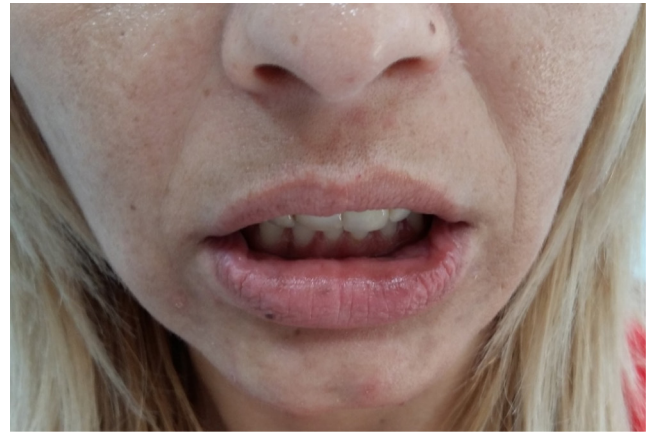

Figure 2
Darkened lesions in the inner aspect of the lower lip.

Investigation

Performed laboratory tests were all within reference range. They included complete and differential blood count, renal and liver biochemistry, serum levels of glucose, amylase, lipase, lactate dehydrogenase, electrolytes, urinalysis, tumor markers – carcinoembryonic antigen and carbohydrate antigen (CA 19-9). Hemocult test was negative. Microbiological stool examination was negative. There was no evidence of endocrine gland dysfunction, based on the physical examination, thyroid-stimulating hormone, thyroxine, tri-iodothyronine, morning serum adrenocorticotropic hormone (ACTH) and cortisol, follicle-stimulating hormone, luteinizing hormone, estradiol and prolactin levels (Table 1). Owing to the fact that McCune–Albright syndrome can present with Cushing's syndrome our patient underwent low-dose dexamethasone suppression test. Urinary free cortisol levels also were measured. Both tests showed negative results. Chest X-ray and abdominal ultrasound showed no pathologic findings except small hepatic hemangioma located in the right lobe. The gynecological examination showed normal result. Upper gastrointestinal endoscopy

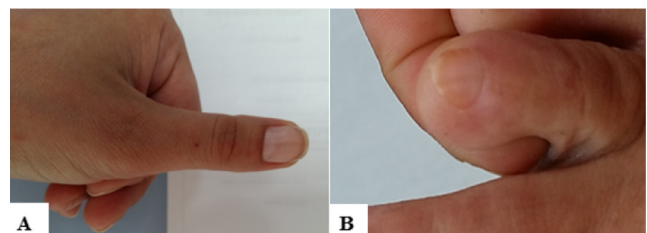


Figure 3
(A) Longitudinal hyperpigmentation of the fingernail. (B) Longitudinal hyperpigmentation of the toenail.



Table 1 Summary of endocrine tests performed in our patient.

Date	Time	Test	Result	Reference range	Unit
06/19/2017	08:00	TSH	0.974	0.34–5.6	mIU/L
06/19/2017	08:00	T ₃	1.60	1.34–2.73	nmol/L
06/19/2017	08:00	T ₄	95.7	78–157	nmol/L
06/19/2017	08:00	ACTH	5.2	1.6–13.9	pmol/L
06/19/2017	08:00	Serum cortisol	231.7	171–536	nmol/L
06/22/2017	08:00	Serum cortisol after LDDST	35.3	<50	nmol/L
06/25/2017		UFC	145.50	100–379	nmol/L
06/19/2017	08:00	PRL	289.5	102–496	mIU/L
06/29/2017	Follicular phase	FSH	9.3	3.5–12.5	IU/L
06/29/2017	Follicular phase	LH	5.7	2.4–12.6	IU/L
06/29/2017	Follicular phase	E ₂	394.35	98.1–571	pmol/L

ACTH, adrenocorticotrophic hormone; E₂, estradiol; FSH, follicle-stimulating hormone; LDDST, low-dose dexamethasone suppression test; LH, luteinizing hormone; PRL, prolactin; TSH, thyroid-stimulating hormone; T₃, tri-iodothyronine; T₄, thyroxine; UFC, urinary free cortisol.

and colonoscopy did not reveal any potential neoplastic formation in these parts of the gastrointestinal tract.

Outcome and follow-up

By excluding endocrine and other systemic disorders, we made a diagnosis of LHS. In order to set the histopathological diagnosis, we proposed biopsy of the oral lesions, which our patient declined.

Discussion

To date, more than hundred cases of LHS are described mainly affecting whites and female gender in a ratio 2:1. However, it is likely that the syndrome is even more common than the reported cases (1). The hyperpigmentation occurs spontaneously during early to middle adulthood and is considered permanent (2, 3). Pathophysiology of LHS is still unknown. Since the specific mucocutaneous lesions are similar to those appearing in more severe conditions, other systemic conditions and abnormalities must be ruled out prior to making a diagnosis. Biopsy is usually required for accurate diagnosis of a focal pigmented lesion. Oral pigmentation caused by systemic diseases is usually diffuse and multifocal and has no specific histologic features (2). The histopathological findings in LHS demonstrate normal numbers and normal morphologic appearance of melanocytes with increased basal pigmentation due to melanin deposition without hyperplasia of melanocytes (4). The nails are affected in approximately 50–60% of the cases and usually present as single or double stripes or as homogeneous pigmentation on one-half of the nail or complete nail (melanonychia) (2, 3, 4). The cause

of these pigmentary stripes in LHS is unknown, but it is supposed to be similar to the involvement of the oral cavity (1, 5). Various differential diagnoses considered for LHS can be ruled out based on patient's history, physical examination findings, laboratory findings, clinical course and a known or suspected cause of hyperpigmentation. Drug-induced pigmentation will usually occur after months or years of chronic use and tends to resolve once the drug is discontinued. The clinical features of drug-induced skin pigmentation are very variable according to the drug involved. A large range of patterns and shades may be formed. Drug groups related to skin pigmentation are antipsychotics (chlorpromazine and related phenothiazines), anticonvulsants (phenytoin), antimalarials (chloroquine and hydroxychloroquine), cytotoxic drugs (busulfan, cyclophosphamide, bleomycin, adriamycin), amiodarone and nonsteroidal anti-inflammatory drugs (NSAIDs) (6). Acquired immune deficiency syndrome (AIDS) patients show hyperpigmentation secondary to the medications taken. Smoking could result in oral mucosal pigmentation called smoker's melanosis and is predominantly seen in anterior gingiva. In addition, smoking is not associated with linear hyperpigmentation of the nails. Other differential diagnoses include acute cutaneous lupus erythematosus, McCune–Albright syndrome, cutaneous melanoma, dermatologic aspects of various diseases (Addison's disease, hemochromatosis, neurofibromatosis type 1), lentigo, lichen planus, melanocytic nevi, Peutz–Jeghers syndrome. From the point of view of a clinical endocrinologist, it is important to exclude Addison's disease and McCune–Albright syndrome. A quick review of the clinical presentation, physical examination findings and laboratory findings heightens the index



of suspicion and can lead to more appropriate tests and diagnosis. Almost all patients with Addison's disease complain of fatigue, progressive weakness, poor appetite and weight loss. They present with low blood pressure, hyponatremia, hyperkalemia, hypoglycemia, secondary to adrenocortical insufficiency. In laboratory findings, random serum cortisol levels are low with elevated ACTH levels. In patients with Addison disease, both cortisol and aldosterone show minimal or no change in response to ACTH, even with prolonged ACTH stimulation tests (7). Another endocrine entity presenting with skin hyperpigmentation is McCune–Albright syndrome that generally emerges at a much earlier age. It consists of at least two of three features: polyostotic fibrous dysplasia associated with multiple pathologic fractures, café-au-lait skin pigmentation and endocrine hyperfunction (most often gonadotropin-independent precocious puberty in females). Skin changes often display a segmental distribution, usually predominating on one side of the body without crossing the midline. Full endocrine studies should be performed in order to exclude endocrine hyperfunction (8). Peutz–Jeghers syndrome (PJS) is a major differential diagnosis of LHS. It is characterized by melanotic macules of the face and mouth along with intestinal polyposis and an increased risk of intestinal (esophageal, stomach, small intestine, colon) and extraintestinal (pancreatic-biliary, breast, gynecologic, testicular and thyroid papillary) cancer (9). Multiple melanotic macules resembling ephelides on the lips and periorally are characteristic feature of the syndrome (2, 4). PJS is inherited in an autosomal dominant pattern with a high degree of penetrance. Usually it has its onset during first few years of life; however, 40% of reported cases have late sporadic onset. Overlapping clinical features in both LHS and PJS may cause diagnostic problems, especially when PJS occurs with mucosal and cutaneous macules without intestinal polyposis. The pigmented lesions of the LHS are usually confined to the oral mucosa, lips and nails, whereas PJS is often seen on the hands and feet (10). On the other hand, in the absence of both family and personal history of intestinal polyposis, a definitive diagnosis of PJS can hardly be made.

LHS is mostly unknown among the practitioners who are likely to notice these changes first – general dentists, oral pathologists and other oral health care providers. Most text books on oral pathology and oral medicine do not include LHS as a cause of oral hyperpigmentation probably because of its benign nature and uncomplicated course (10). In endocrine clinical practice, two entities

merit consideration – Addison's disease and McCune–Albright syndrome. However, they both are easily ruled out based on patient's history, physical examination findings and endocrine studies. The importance of recognizing LHS is to perform adequate work-up and to avoid further unnecessary and expensive investigations and treatment.

Declaration of interest

The authors declare that there is no conflict of interest that could be perceived as prejudicing the impartiality of the research reported.

Funding

This research did not receive any specific grant from any funding agency in the public, commercial or not-for-profit sector.

Patient consent

Written informed consent was obtained from the patient for publication.

Author contribution statement

M Radman is the patient's main physician and is a co-author.

References

- 1 Mignogna MD, Lo Muzio L, Ruoppo E, Errico M, Amato M & Satriano RA. Oral manifestations of idiopathic lenticular mucocutaneous pigmentation (Laugier–Hunziker syndrome): a clinical, histopathological and ultrastructural review of 12 cases. *Oral Diseases* 1999 **5** 80–86. (<https://doi.org/10.1111/j.1601-0825.1999.tb00068.x>)
- 2 Siponen M & Salo T. Idiopathic lenticular mucocutaneous pigmentation (Laugier–Hunziker syndrome): a report of a case. *Oral Surgery, Oral Medicine, Oral Pathology, Oral Radiology* 2003 **96** 288–292. (<https://doi.org/10.1016/S1079210403002956>)
- 3 Pereira PM, Rodrigues CA, Lima LL, Reyes SA & Mariano AV. Do you know this syndrome? *Anais Brasileiros de Dermatologia* 2010 **85** 751–753. (<https://doi.org/10.1590/S0365-05962010000500029>)
- 4 Rangwala S, Doherty CB & Katta R. Laugier–Hunziker syndrome: a case report and review of the literature. *Dermatology Online Journal* 2010 **16** 9.
- 5 Montebugnoli L, Grelli I, Cervellati F, Misciali C & Raone B. Laugier–Hunziker syndrome: an uncommon cause of oral pigmentation and a review of the literature. *International Journal of Dentistry* 2010 **2010** 525404. (<https://doi.org/10.1155/2010/525404>)
- 6 Dereure O. Drug-induced skin pigmentation. Epidemiology, diagnosis and treatment. *American Journal of Clinical Dermatology* 2001 **2** 253–262. (<https://doi.org/10.2165/00128071-200102040-00006>)
- 7 Bornstein SR, Allolio B, Arlt W, Barthel A, Don-Wauchope A, Hammer GD, Husebye ES, Merke DP, Murad MH, Stratakis CA, et al. Diagnosis and treatment of primary adrenal insufficiency: an Endocrine Society Clinical Practice Guideline. *Journal of Clinical Endocrinology and Metabolism* 2016 **101** 364–389. (<https://doi.org/10.1210/jc.2015-1710>)



- 8 Dumitrescu CE & Collins MT. McCune-Albright syndrome. *Orphanet Journal of Rare Diseases* 2008 **3** 12. (<https://doi.org/10.1186/1750-1172-3-12>)
- 9 Giardiello FM, Brensinger JD, Tersmette AC, Goodman SN, Petersen GM, Booker SV, Cruz-Correa M & Offerhaus JA. Very high

- risk of cancer in familial Peutz-Jeghers syndrome. *Gastroenterology* 2000 **119** 1447–1453. (<https://doi.org/10.1053/gast.2000.20228>)
- 10 Nayak RS, Kotrashetti VS & Hosmani JV. Laugier–Hunziker syndrome. *Journal of Oral and Maxillofacial Pathology* 2012 **16** 245–250. (<https://doi.org/10.4103/0973-029X.99079>)

Received in final form 10 April 2018

Accepted 13 April 2018